

Brief Communication

TERT promotor status does not add prognostic information in IDH-wildtype glioblastomas fulfilling other diagnostic WHO criteria: A report of the RANO *resect* group

Philipp Karschnia[○], Jacob S. Young, Antonio Dono[○], Levin Häni, Stephanie T. Juenger, Tommaso Sciortino, Francesco Bruno[○], Nico Teske, Ramin A. Morshed, Alexander F. Haddad, Yalan Zhang, Sophia Stoecklein, Michael A. Vogelbaum, Juergen Beck, Nitin Tandon[○], Shawn Hervey-Jumper, Annette M. Molinaro[○], Roberta Rudà, Lorenzo Bello, Oliver Schnell, Yoshua Esquenazi[○], Maximilian I. Ruge, Stefan J. Grau, Martin van den Bent, Michael Weller[○], Mitchel S. Berger[○], Susan M. Chang, and Joerg-Christian Tonn

Department of Neurosurgery, Ludwig-Maximilians-University, Munich, Germany (P.K., Ni.Te., J.-C.T.); German Cancer Consortium (DKTK), Partner Site Munich, Munich, Germany (P.K., Ni.Te., J.-C.T.); Department of Neurosurgery & Division of Neuro-Oncology, University of San Francisco, San Francisco, California, USA (J.S.Y., R.A.M., A.F.H., Y.Z., S.H.-J., A.M.M., M.S.B., S.M.C.); Department of Neurosurgery, McGovern Medical School at UT Health Houston, Houston, Texas, USA (A.D., Ni.Ta., Y.E.); Department of Neurosurgery, University of Freiburg, Freiburg, Germany (L.H., J.B., O.S.); Department of Neurosurgery, University of Cologne, Cologne, Germany (S.T.J., S.J.G.); Division for Neuro-Oncology, Department of Oncology and Hemato-Oncology, University of Milan, Milan, Italy (T.S., L.B.); Division of Neuro-Oncology, Department of Neuroscience, University of Turin, Turin, Italy (F.B., R.R.); Department of Radiology, University Hospital, LMU Munich, Munich, Germany (S.S.); Department of NeuroOncology, Moffitt Cancer Center, Tampa, Florida, USA (M.A.V.); Division of Neurology, Castelfranco Veneto and Treviso Hospital, Treviso, Italy (R.R.); Department of Stereotactic and Functional Neurosurgery, Centre for Neurosurgery, University Hospital Cologne, Cologne, Germany (M.I.R.); Klinikum Fulda, Academic Hospital of Marburg University, Fulda, Germany (S.J.G.); Department of Neurology, Erasmus MC Cancer Institute, Rotterdam, The Netherlands (M.v.d.B.); Department of Neurology, University Hospital and University of Zurich, Zurich, Switzerland (M.W.)

Corresponding Author: Joerg-Christian Tonn, MD, Department of Neurosurgery, Ludwig-Maximilians-University Munich, Marchioninistrasse 15, 81377 Munich, Germany (Joerg.Christian.Tonn@med.uni-muenchen.de).

In IDH-wildtype glioblastomas which meet the histopathological or molecular diagnosis criteria, it remains unclear whether the presence of TERT promotor mutations provides additional prognostic information. Based on a multicenter cohort of 466 IDH-wildtype glioblastomas (including 396 with and 70 patients without TERT promotor mutations), we found that TERT promotor mutations were neither associated with progression-free survival nor overall survival. This held true in various treatment-based or molecular subgroups. This argues against standardized analysis for TERT promotor mutation status for the purpose of prognostic or therapeutic relevance in newly diagnosed IDH-wildtype glioblastoma that otherwise meets the histopathological and molecular diagnosis criteria.

The WHO 2021 classification restricts the diagnosis of “glioblastoma WHO grade 4” to IDH-wildtype astrocytic gliomas either with (1) classical histopathological hallmarks or (2) qualifying molecular features.¹ The latter include EGFR amplification, +7/-10 genotype, and TERT promotor mutation which

are all associated with less favorable outcome when observed in combination with IDH-wildtype status.^{2,3} The presence of one of these three markers allows the diagnosis of “molecular” glioblastoma even when tumors appear histologically lower grade, and 80% of glioblastomas exhibit TERT promotor mutations.⁴ Whether TERT promotor mutations are of prognostic value in IDH-wildtype glioblastomas which otherwise yet fulfill the diagnostic (histopathological or molecular) criteria for glioblastoma is unclear. Here, we explored such an association based upon a well-annotated glioblastoma cohort from 7 international neuro-oncological centers participating in the RANO *resect* group.

With approval of the ethics committee of the Ludwig-Maximilians-University (Munich, Germany; AZ-21-0996), the RANO *resect* group compiled a retrospective database of newly diagnosed IDH-wildtype glioblastomas treated between 2003 and 2022 with a follow-up of ≥ 3 months.⁵ For the current study, individuals were selected when information on

TERT promotor mutation status was available for review. Demographics, molecular information, clinical data, and outcome were extracted; and date of progression was determined *per RANO* criteria.

Among 1008 *IDH*-wildtype glioblastomas WHO grade 4, *TERT* promotor status was available in 466 patients including 396 individuals with ($IDH^{wt}/TERT^{mut}$) and 70 patients without *TERT* promotor mutations ($IDH^{wt}/TERT^{wt}$). Diagnosis rested upon *IDH*-wildtype combined with histopathological findings in 372 $IDH^{wt}/TERT^{mut}$ (93.9%) and 65 $IDH^{wt}/TERT^{wt}$ patients (92.9%); and was established based on the molecular signature (*TERT* promotor mutation for $IDH^{wt}/TERT^{mut}$; *EGFR* amplification for $IDH^{wt}/TERT^{wt}$) in the absence of classical histological findings in the remaining patients. Three hundred and fifty-eight $IDH^{wt}/TERT^{mut}$ (90.4%) and 63 $IDH^{wt}/TERT^{wt}$ patients (90%) underwent microsurgical resection, whereas the remaining had biopsy for tissue-based diagnosis. There were no differences in *MGMT* promotor methylation status, first-line therapy, or pre- and postoperative tumor volumes (both for contrast-enhancing and noncontrast-enhancing tumor) between $IDH^{wt}/TERT^{mut}$ and $IDH^{wt}/TERT^{wt}$ patients (Figure 1A and B). Median progression-free survival was 8 months and overall survival was 18 months at a median follow-up

time of 36 months ($IDH^{wt}/TERT^{mut}$ vs $IDH^{wt}/TERT^{wt}$: 33 vs 52 months; HR: 1.50, CI: 1.0–2.3). When patients were stratified according to *TERT* promotor mutation status, no outcome differences were detected for progression-free survival ($IDH^{wt}/TERT^{mut}$ vs $IDH^{wt}/TERT^{wt}$: 7 vs 8 months; HR: 1.03, CI: 0.8–1.4) or overall survival ($IDH^{wt}/TERT^{mut}$ vs $IDH^{wt}/TERT^{wt}$: 18 vs 17 months; HR: 0.97, CI: 0.7–1.3) (Figure 1C). Also, no association between survival and *TERT* promotor mutation status was found in the subgroups of patients with *MGMT* promotor methylation (HR for $IDH^{wt}/TERT^{wt}$: 0.99, CI: 0.6–1.8), unmethylated *MGMT* promotor status (HR for $IDH^{wt}/TERT^{wt}$: 0.92, CI: 0.5–1.7), first-line radiochemotherapy *per* EORTC 26981/22981 (HR for $IDH^{wt}/TERT^{wt}$: 1.00, CI: 0.7–1.4), or classical histopathological findings of glioblastoma (HR for $IDH^{wt}/TERT^{wt}$: 1.06, CI: 0.8–1.5).

We did therefore not find evidence that *TERT* promotor status adds prognostic information in *IDH*-wildtype glioblastomas exhibiting classical histopathological hallmarks (or other mutations) sufficient for glioblastoma diagnosis. This is in line with previous reports on *IDH*-wildtype glioblastomas,^{4,6,7} although these studies have either not controlled for clinical and molecular confounders^{4,6} or were substantially limited in sample size.^{4,7} Notably, $IDH^{wt}/TERT^{wt}$ glioblastomas may identify a subset with a distinct

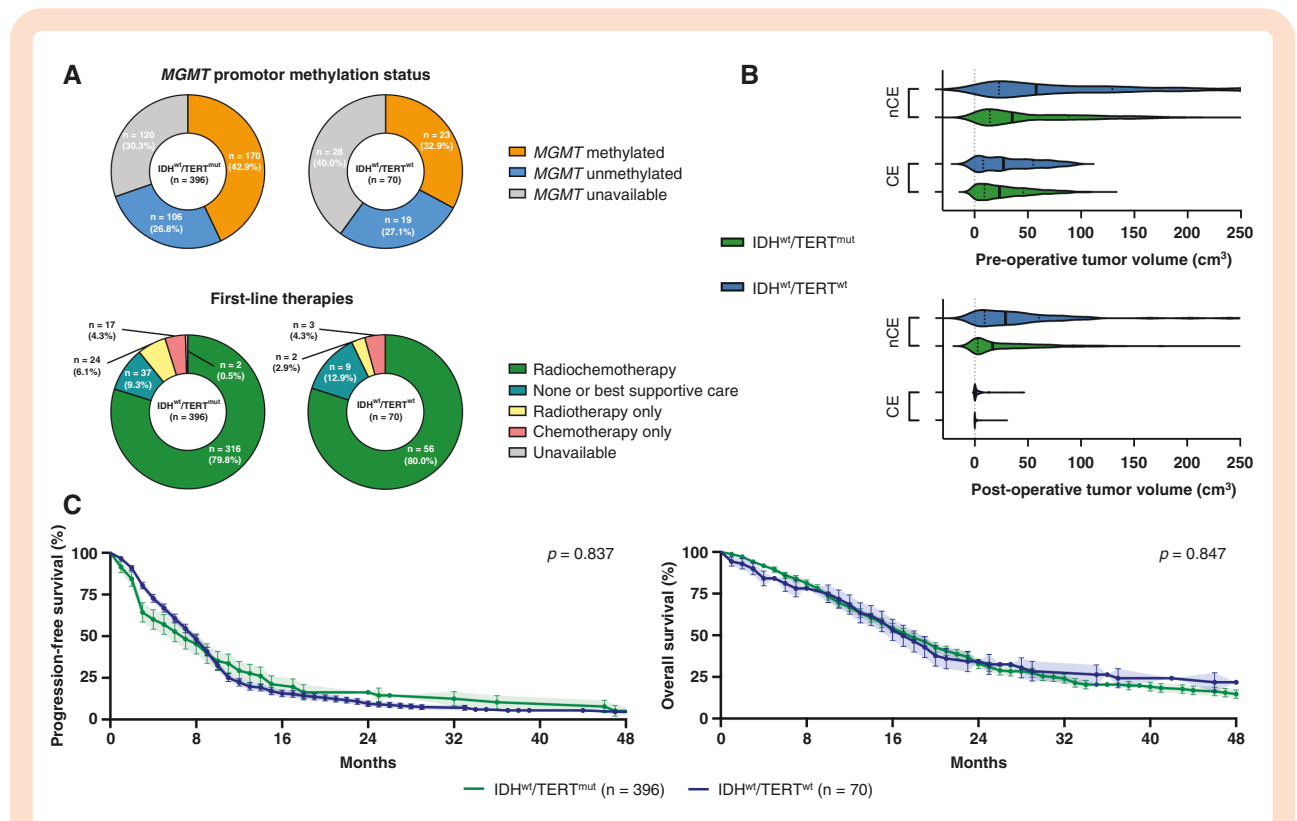


Figure 1. Clinico-molecular markers and outcome in *IDH*-wildtype glioblastoma with or without *TERT* promotor mutations. (A) Distribution of *MGMT* promotor methylation status (upper panel) and first-line therapies following surgery (lower panel) in *IDH*-wildtype glioblastomas with ($IDH^{wt}/TERT^{mut}$; $n = 396$) or without *TERT* promotor mutations ($IDH^{wt}/TERT^{wt}$; $n = 70$). (B) Pre- (upper panel) and postoperative tumor volumes (lower panel) in cm³ among *IDH*-wildtype glioblastomas undergoing microsurgical tumor resection with ($IDH^{wt}/TERT^{mut}$; $n = 358$; green) or without *TERT* promotor mutations ($IDH^{wt}/TERT^{wt}$; $n = 63$; blue). Volumes are indicated for contrast-enhancing (CE) and noncontrast-enhancing (nCE) tumor tissue. Median \pm interquartile range. (C) Kaplan–Meier estimates of progression-free survival (left) and overall survival (right) for *IDH*-wildtype glioblastomas with (green line) or without *TERT* promotor mutations (blue line). Points indicate deceased or censored patients; light shadings indicate SEM.

(epi-)genetic and molecular profile compared to IDH^{wild}/TERT^{mut} tumors and may benefit from different, personalized treatment strategies.^{2,4,6} These biological findings, however, to date do not result in different clinical outcomes. Thus, up to now our retrospective data argue against standardized analysis for *TERT* promotor mutation status for the purpose of prognostic or therapeutic relevance in newly diagnosed *IDH*-wildtype glioblastoma that otherwise meets the histopathological and molecular diagnosis criteria. This might change in the future whenever *TERT*-directed therapies emerge.

Funding

No funding to report.

Acknowledgments

The authors thank all the patients who contributed to the results of this study.

Conflict of interest statement. M.W.—research grants: Quercis and Versameb. Honoraria/advisory board participation/consulting: Bayer, Medac, Merck (EMD), Nerviano, Novartis, Novocure, Orbus, and Philogen. M.A.V.—indirect equity/patient royalty interests: Infuseon Therapeutics. Honoraria: Celgene, Tocagen, and Blue Earth Diagnostics. Ni.Ta.—research grants: Medtronic; founder: BrainDynamics; advisory board: Nervonik and BrainGrade. R.R.—honoraria/advisory board/consulting: UCB, Bayer, Novocure, and Genenta. M.v.d.B.—consultant: Celgene, BMS, Agios, Boehringer, AbbVie, Bayer, Carthera, Nerviano, and Genenta. J.-C.T.—research grants: Novocure and Munich-Surgical-Imaging; royalties: Springer Publisher Intl. P.K., J.S.Y., A.D., L.H., T.S., F.B., S.T.J., Ni.Te., R.A.M., A.F.H., Y.Z., S.S., J.B., S.H.-J., A.M.M., L.B., O.S., Y.E., M.I.R., S.J.G., M.S.B., and S.M.C.—none.

Authorship Statement. Study concept/design: P.K. and J.-C.T. Data collection: P.K., J.S.Y., A.D., L.H., T.S., F.B., S.T.J., Ni.Te., R.A.M., A.F.H., Y.Z., S.H.-J., M.I.R., R.R., L.B., O.S., Y.E., S.J.G., A.M.M., M.S.B., S.M.C., and J.-C.T. Analysis/interpretation: P.K., S.M.C., M.v.d.B., and J.-C.T. Manuscript drafting: P.K., M.W., S.M.C., M.v.d.B., and J.-C.T. Manuscript revising: P.K., J.S.Y., A.D., L.H., T.S., F.B., S.T.J., Ni.Te., R.A.M., A.F.H., Y.Z., S.S., M.W., M.A.V., J.B., Ni.Ta., S.H.-J., A.M.M., R.R., L.B., O.S., Y.E., M.I.R., S.J.G., M.S.B., S.M.C., M.v.d.B., and J.-C.T.

References

1. Louis DN, Perry A, Wesseling P, et al. The 2021 WHO classification of tumors of the central nervous system: a summary. *Neuro Oncol.* 2021;23(8):1231–1251.
2. Stichel D, Ebrahimi A, Reuss D, et al. Distribution of EGFR amplification, combined chromosome 7 gain and chromosome 10 loss, and TERT promoter mutation in brain tumors and their potential for the reclassification of IDHwt astrocytoma to glioblastoma. *Acta Neuropathol.* 2018;136(5):793–803.
3. Arita H, Yamasaki K, Matsushita Y, et al. A combination of TERT promoter mutation and MGMT methylation status predicts clinically relevant subgroups of newly diagnosed glioblastomas. *Acta Neuropathol Commun.* 2016;4(1):79.
4. Diplas BH, He X, Brosnan-Cashman JA, et al. The genomic landscape of TERT promoter wildtype-IDH wildtype glioblastoma. *Nat Commun.* 2018;9(1):2087.
5. Karschnia P, Young JS, Dono A, et al. Prognostic validation of a new classification system for extent of resection in glioblastoma: a report of the RANO resect group. *Neuro Oncol.* 2022. doi:10.1093/neuonc/noac193
6. Liu EM, Shi ZF, Li KK, et al. Molecular landscape of IDH-wild type, pTERT-wild type adult glioblastomas. *Brain Pathol.* 2022:e13107.
7. Gramatzki D, Felsberg J, Hentschel B, et al. Telomerase reverse transcriptase promoter mutation- and O(6)-methylguanine DNA methyltransferase promoter methylation-mediated sensitivity to temozolomide in isocitrate dehydrogenase-wild-type glioblastoma: is there a link? *Eur J Cancer.* 2021;147:84–94.