






REVIEW ARTICLE

How to avoid intraoperative and postoperative complications in maxillary sinus elevation

Tiziano Testori^{1,2,3,4}  | Lorenzo Tavelli⁴  | Riccardo Scaini^{1,2}  | Alberto Maria Saibene⁵ | Giovanni Felisati⁵ | Shayan Barootchi⁶  | Ann Marie Decker⁶ | Matteo Antonio Deflorian^{1,2}  | Gabriele Rosano^{7,8} | Stephen S. Wallace^{9,10} | Giovanni Zucchelli^{6,11} | Luca Francetti^{2,12} | Hom-Lay Wang⁶

¹IRCCS Galeazzi -Sant'Ambrogio Hospital, Dental Clinic, Section of Implant Dentistry and Oral Rehabilitation, Milan, Italy

²Department of Biomedical, Surgical and Dental Sciences, Università degli Studi di Milano, Milan, Italy

³Department of Periodontics and Oral Medicine, School of Dentistry, University of Michigan, Ann Arbor, Michigan, USA

⁴Division of Periodontology, Department of Oral Medicine, Infection, and Immunity, Harvard School of Dental Medicine, Boston, Massachusetts, USA

⁵Otolaryngology Unit, Santi Paolo e Carlo Hospital, Department of Health Sciences, Università degli Studi di Milano, Milan, Italy

⁶Department of Periodontics and Oral Medicine, University of Michigan School of Dentistry, Ann Arbor, Michigan, USA

⁷Academy of Craniofacial Anatomy, Como, Italy

⁸Lake Como Institute Implant Advanced Training Center, Como, Italy

⁹Department of Periodontics, Columbia University College of Dental Medicine, New York City, New York, USA

¹⁰Private Practice, Waterbury, Connecticut, USA

¹¹Department of Biomedical and Neuromotor Sciences, University of Bologna, Bologna, Italy

¹²IRCCS Galeazzi -Sant'Ambrogio Hospital, Dental Clinic, Dean of the Dental Clinic, Milan, Italy

Correspondence

Riccardo Scaini, IRCCS Orthopedic Institute Galeazzi, Dental Clinic, Section of Implant Dentistry and Oral Rehabilitation, Milan, Italy.

Email: riccardoscaini@me.com

1 | INTRODUCTION

Maxillary sinus elevation surgery is considered the most predictable of the bone augmentation procedures currently employed.¹ The reported outcome criteria from evidence-based reviews include measures of both procedural success and implant survival, which have been shown to be remarkably high.²⁻⁶ Notably, complications are infrequent, and those that occur after sinus grafting are usually localized and readily solved; however, they can sometimes be serious in nature.^{7,8} It should be appreciated that many reported complications arise from an incorrect preoperative diagnosis. The recognition of preexisting sinus pathologies and the myriad of existing internal sinus anatomic variations are factors that should be incorporated into preliminary surgical decisions.

Another determining factor in the success of a surgery is the human factor.⁹ In each surgical procedure, the specific training

and the number of procedures performed by an operator correlate strongly with clinical outcome. Importantly, the data discussed within the context of the literature often refer to research hospitals or highly trained clinicians as principal operators. Toward this end, these data may not accurately reflect outcomes experienced by the general body of clinicians conducting these procedures.

Moreover, even a highly experienced surgeon could underperform in some specific situations. Principal operator performance is optimized further with well-trained surgical team members, patient selection, and available resources (ie, the type of surgical facility and surgical instruments). To increase safety, improve efficiency, and reduce operative error, some have advocated for preoperative "time-outs" and "checklists," which signal collective awareness to the operative team of known factors of complications before/during/after each sinus augmentation procedure (Figure 1). Thus, checklists

Luca Francetti and Hom-Lay Wang share the last position.

[Correction added on August 10, 2023, after first online publication: The affiliation for the author Giovanni Zucchelli has been updated.]

This is an open access article under the terms of the [Creative Commons Attribution-NonCommercial-NoDerivs](https://creativecommons.org/licenses/by-nc-nd/4.0/) License, which permits use and distribution in any medium, provided the original work is properly cited, the use is non-commercial and no modifications or adaptations are made.

© 2023 The Authors. *Periodontology 2000* published by John Wiley & Sons Ltd.

provide a means to safeguard patients and minimize risk through increased team cohesion and coordination¹⁰ (Table 1).

2 | PATIENT SELECTION

Maxillary sinus elevation is a procedure that modifies the local anatomy of the sinus and may temporarily impair sinus homeostasis. Though no controlled clinical trials have been performed to assess the correlation of complications following maxillary sinus elevation and initial anatomic-physiologic status of the maxillary sinus, it is reasonable to speculate that the success rate of the procedure could be partially related to the baseline condition of the maxillary sinus.¹¹ It is therefore mandatory to perform a thorough preoperative evaluation of the sinus to reduce intra- and postoperative complications prior to planning a maxillary sinus elevation.¹²

Patients in need of maxillary sinus surgery should undergo appropriate radiologic evaluation with the aim of visualizing not only the upper dental arch but also for evaluation of the osteomeatal complex of the maxillary sinus. For this reason, a proper preoperative evaluation should include not only orthopantomography but also cone beam computed tomography extended to the orbit.^{13,14}

It is extremely important during the first consultation to collect a complete history of potential conditions affecting the maxillary sinus, such as nasal obstructions, facial trauma, sinus infections, allergic symptoms, smell and taste dysfunction, atmospheric pressure changes-related discomfort, chronic respiratory diseases, previous nasosinus surgeries, facial deformities, scars, and mouth breathing.¹⁵ If the anamnesis is positive or there are symptoms of sinusitis, it is advisable to ask for an otorhinolaryngologist consultation.

The same assessment should be made in cases that present radiologic signs of radiopacity, previous sinus treatments, impaired

nasal breathing, and chronic respiratory diseases. Even acute rhinosinusitis could represent a temporary contraindication to sinus surgery since viral and bacterial infection are very often difficult to distinguish. If symptoms regress or the patient improves in less than 5 days without any treatment it is possible to assume that it is a common cold, and analgesics, nasal saline irrigation, decongestant could be used as effective treatment. If symptoms do not regress after 10 days of treatment, an otorhinolaryngology consultation is mandatory before the sinus surgery. After proper treatment of the infection a 30-day waiting period is advisable to obtain adequate mucosal trophism and osteomeatal complex patency.^{14,16}

The recommendations shown in Figure 2 serve as a guide for the implantologist on how to interact with the otorhinolaryngologist to find the appropriate course of treatment regarding radiologic findings in the sinus. Any radiologic findings should be interpreted along with a proper sinus history and after having evaluated any possible clinical symptoms that the patient might have. Notably, mucosal thickening up to 3 mm in the absence of acute rhinosinusitis symptoms does not require any further investigation if the osteomeatal complex is patent. Any mucosal thickening, if related to osteomeatal complex closure, needs a specific otorhinolaryngology evaluation. In addition, a mucous retention cyst does not require any further investigation if the cyst, even after the elevation of the sinus membrane, does not interfere with the osteomeatal complex or if the cyst is located in a different area (ie, distal wall of the sinus).

Other important considerations include treatment planning of adjacent-site dental needs, hard-tissue dehiscence, and assessment of pathologic processes. Any foreign bodies (teeth, implants) should be removed prior to surgery. In addition, a bony wall dehiscence with soft-tissue closure in the context of a healthy sinus is not a contraindication to maxillary sinus elevation. A missing sinus wall with hard-tissue erosion should always be regarded with great suspicion and requires specialist evaluation in order to exclude neoplastic conditions.

3 | PREOPERATIVE DIAGNOSIS, PLANNING, AND EVALUATION OF CASE DIFFICULTY

Patient selection and proper preoperative diagnosis is a fundamental step to avoid intra- and postoperative complications. The patient's facial profile must be evaluated before the surgery: Patients with a short face tend to have a thick sinus wall and a zygomatic process that has a more coronal cant. With these notable characteristics, patients that present with anatomically short facial dimensions are more difficult to treat compared with patients with longer facial dimensions. The dimensions of a patient's mouth, the ease to retract cheeks, and the side that is to be operated also play an important role in operator visibility/accessibility of the surgical field.

Furthermore, the span of the edentulous region and lateral wall thickness are other important factors to be evaluated before the surgery. As a general rule, short-span edentulism is more difficult to treat than long-span edentulous patients (eg, missing bicuspid

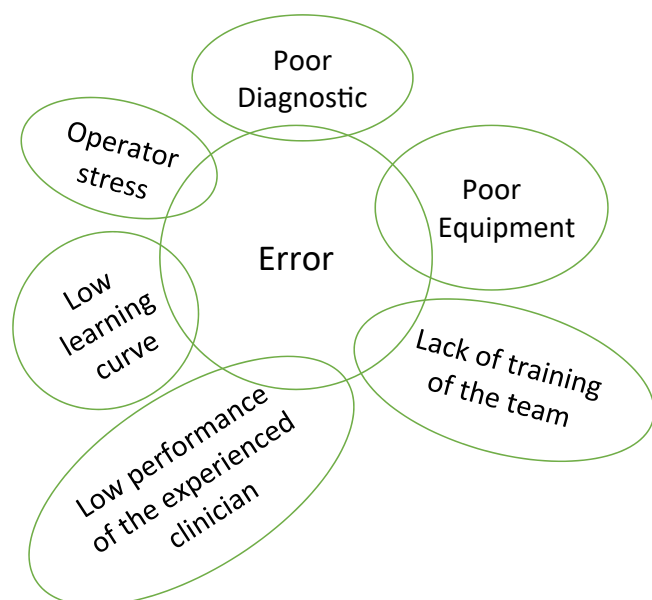


FIGURE 1 Different factors could lead to a clinical error; even the experienced clinician in a stressful environment could underperform

TABLE 1 Maxillary sinus elevation surgical checklist

| | | | |
|---------------------------------|---|------------------------------|-----------------------------|
| Patient: _____ | | Date: _____ | |
| Preoperative | | | |
| 1. | Medical history is properly completed? | YES <input type="checkbox"/> | NO <input type="checkbox"/> |
| 2. | The informed consent is signed | YES <input type="checkbox"/> | NO <input type="checkbox"/> |
| 3. | Radiographs checked and put on display | YES <input type="checkbox"/> | NO <input type="checkbox"/> |
| 4. | Intervention site clearly indicated and confirmed with the patient... | YES <input type="checkbox"/> | NO <input type="checkbox"/> |
| 5. | Sterile disposable materials stock controlled | YES <input type="checkbox"/> | NO <input type="checkbox"/> |
| 6. | Surgical instrumentarium is functioning and set up | YES <input type="checkbox"/> | NO <input type="checkbox"/> |
| 7. | Grafting materials and membranes available | YES <input type="checkbox"/> | NO <input type="checkbox"/> |
| Operating room checklist | | | |
| 8. | Antibiotic prophylaxis properly done | YES <input type="checkbox"/> | NO <input type="checkbox"/> |
| 9. | Appropriate clothing for the operating session | YES <input type="checkbox"/> | NO <input type="checkbox"/> |
| 10. | Vital signs are monitored | YES <input type="checkbox"/> | NO <input type="checkbox"/> |
| 11. | Any premedication administered (ie, chlorhexidine /hydrogen peroxide) | YES <input type="checkbox"/> | NO <input type="checkbox"/> |
| 12. | Peri-oral region properly disinfected? | YES <input type="checkbox"/> | NO <input type="checkbox"/> |
| 13. | Sterile drapes properly placed? | YES <input type="checkbox"/> | NO <input type="checkbox"/> |
| Postoperative | | | |
| 14. | No hemorrhaging present | YES <input type="checkbox"/> | NO <input type="checkbox"/> |
| 15. | Removable denture adjusted and returned to patient | YES <input type="checkbox"/> | NO <input type="checkbox"/> |
| 16. | Postoperative information provided | YES <input type="checkbox"/> | NO <input type="checkbox"/> |
| 17. | Postoperative medications provided/prescribed | YES <input type="checkbox"/> | NO <input type="checkbox"/> |
| 18. | Operative record properly completed | YES <input type="checkbox"/> | NO <input type="checkbox"/> |
| 19. | Postoperative X-ray examination prescribed | YES <input type="checkbox"/> | NO <input type="checkbox"/> |
| COMMENTS _____ | | | |
| Primary Responsible Name: _____ | | Sign: _____ | |

and molars). Preoperative examination of three-dimensional radiographs can provide clinicians with information on the thickness of the lateral wall of the sinus, thickness of the sinus membrane, the presence and direction of sinus septa, the presence and the location of alveolar antral artery, the presence of bone dehiscence, and anatomic variations.

Once a thorough preoperative evaluation and surgical diagnosis are completed, it is possible to assess, within reason, the surgical risk and determine the level of experience/expertise that is necessary to achieve a positive/predictable outcome. The Maxillary Sinus Elevation Difficulty Score worksheet (Table 2) awards difficulty points for a number of clinical situations that may be encountered. By simply adding up the case scores, a clinician can determine if the case falls within the general guidelines of difficulty suggested by the authors. The clinician's experience level should match well to the case difficulty level.

4 | PREOPERATIVE CONTRAINDICATIONS TO MAXILLARY SINUS ELEVATION

If the medical history is positive or there are symptoms of sinusitis, it is advisable to ask for an otorhinolaryngology consultation. A specific maxillary sinus anamnesis has been proposed for a correct

preoperative sinus evaluation (Table 3). Pignataro et al¹⁷ presented a series of clinical recommendations concerning ear, nose, and throat contraindications to maxillary sinus elevation (Table 4). A prospective clinical study evaluated this approach and confirmed its reliability in 34 patients. No one presented with presumably irreversible ear, nose, and throat contraindications, but 38.2% presented presumably reversible ear, nose, and throat contraindications and were consequently treated with no complications after the sinus floor elevation procedure¹⁸ (Table 5).

5 | INTRAOPERATORY COMPLICATIONS

5.1 | Membrane perforation

5.1.1 | Incidence of membrane perforation

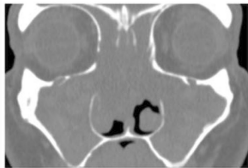
Schneiderian membrane perforation is the most common intraoperative complication during sinus floor elevation.^{7,8,19} Therefore, it is not surprising that the characteristics and mechanical properties of the sinus membrane have been extensively investigated.²⁰⁻²⁴ The Schneiderian membrane is the mucous membrane covering the inner part of the maxillary cavity. It consists of an overlaid periosteum with a thin layer of a pseudo-stratified ciliated epithelium and highly

vascularized connective tissue.²⁵ It has been shown that it contains osteoprogenitor cells, leading some to speculate a possible role of the membrane in bone formation.^{25,26} Therefore, maintaining the integrity of the sinus membrane may be desirable not only for a better stability and blood supply of the graft but also for a possible accelerated bone formation.^{25,27}

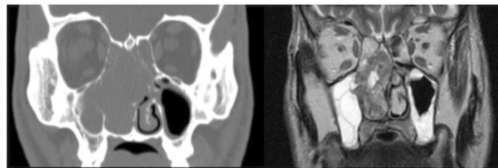There is a high degree of variability reported in the literature for the incidence of perforations. According to a systematic review by Pjetursson et al,⁴ the incidence of membrane perforation ranges from 0% to 58.3%, with a mean occurrence of 19.5%. Another systematic review and meta-analysis reported a weighted perforation incidence rate of 23.5%, ranging from 3.6%

RADIOLOGICAL FINDINGS THAT REQUIRE FURTHER INVESTIGATIONS

COMPLETE SINUS RADIOPACITY

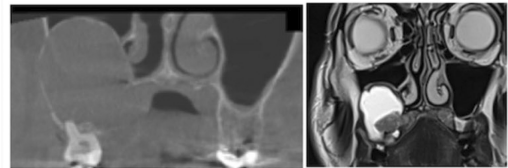


Coronal CT image showing soft tissue material occupying both maxillary sinuses and opacifying some of the ethmoidal cells. This bilateral CT involvement suggests a chronic rhinosinusitis with nasal polyps, which has to be confirmed by clinical inspection or endoscopy.



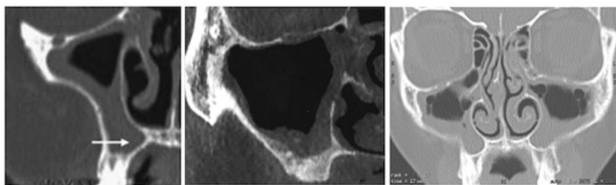
A. Coronal CT image showing an expansive lesion affecting the right nasal cavity. The medial maxillary wall and some of the ethmoidal cells appear eroded by the mass, while the septum has been pushed contralaterally. The left maxillary sinus and the left nasal cavity appear unaffected by the neoplasm. The right lateral maxillary wall, the palate and the right lamina papyracea do not appear involved by the neoplasm, thus suggesting a non-invasive behaviour. B. Contrast-enhanced T1-weighted MR coronal image from the same patient. Mucous content (hyperintense) can be seen in both maxillary sinuses, while the neoplasm affects only the right nasal fossa, without involving the septum. The columnar features characterizing the mass are often a typical diagnostic feature of inverted papilloma, as in this case.

TOTAL OR PARTIAL SINUS RADIOPACITY WITH BONE EROSION NOT DUE TO DENTAL OR PERIODONTAL INFECTION



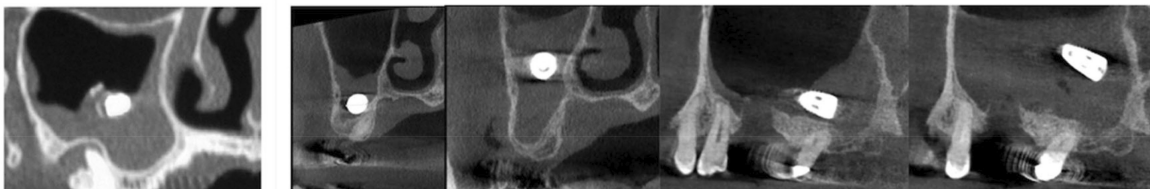Cone beam CT scan image showing a mass located on the right maxillary sinus floor. The cranial portion of the mass protrudes into the sinus with a thin osseous rim, mimicking a cyst. The medial/inferior part of the mass erodes the alveolar process and the hard palate, thus suggesting an infiltrating behaviour which calls for further radiological evaluation. B. Contrast-enhanced T1-weighted MR coronal image from the same patient. The mass appears now composed of two distinct portions: a mucous-filled cranial portion and a solid inferior portion with mild contrast-enhancement that invades the hard palate bone. Further histological evaluations will diagnose a poorly differentiated squamous carcinoma of the maxillary sinus.

MUCOSAL THICKENING WITH NO PATENT OSTIUM



Mucosal thickening and no patent ostium requires an ENT evaluation prior to maxillary sinus surgery. Pharmacological and/or surgical therapy will be evaluated by the ENT specialist.

FOREIGN BODY IN THE SINUS



Calcification and mucosal sinus mucosal thickening most often indicating fungal sinusitis that could be caused by endodontic cement that went inside the sinus during end treatment

Sinus mucosal thickening and implants inside the sinus that can change position over time

FIGURE 2 Radiologic sinus findings that require and does not require further investigations by otorhinolaryngologist. CT, computed tomography; ENT, ear, nose, and throat; MR, magnetic resonance; OMC, osteomeatal complex

RADIOLOGICAL FINDINGS THAT DOES NOT REQUIRES FURTHER INVESTIGATION BY THE OTORHINOLARYGOLOGIST

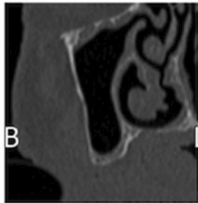



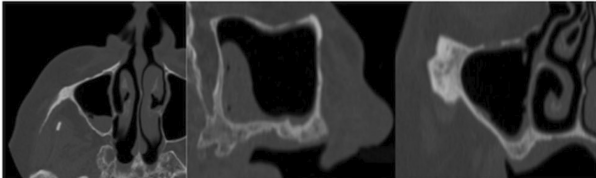

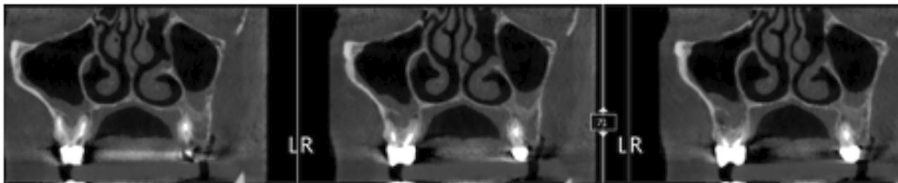
| HEALTHY SINUS | SEPTAL DEVIATION WITH OMC PATENCY | CONCHA BULLOSA WITH OMC PATENCY |
|--|--|---|
|  |  |  |
| <p>In an healthy sinus the sinus membrane is not visible and the OMC is patent</p> | <p>Coronal CT image showing a right cartilaginous septal deviation. A small concha bullosa (i.e. an air-filled pneumatization) is visible in the cranial portion of the left middle turbinate.</p> | <p>Coronal CT image showing a concha bullosa (i.e. an air-filled pneumatization) of both left and right middle turbinates. The right concha bullosa, significantly larger, is biparted.</p> |
| BONE DEHISCENCES AT THE LATERAL / PALATAL WALL OR FLOOR OF THE SINUS WITH SOFT TISSUES CLOSURE | | MUCOSAL CYST THAT DOES NOT INTERFERE WITH SINUS ELEVATION |
|  | |  |
| <p>A bony wall dehiscence with soft tissue closure and health sinus is not a contraindication to maxillary sinus elevation</p> | | <p>A mucosal cyst that does not interfere with the elevation procedures associated to a patent OMC doesn't need further ENT evaluation</p> |
| MUCOSAL THICKENING WITH OMC PATENCY | MUCOSAL THICKENING DUE TO PERIAPICAL INFECTION | |
|  |  | |
| <p>CT coronal image showing a partial opacification of the caudal portion of the right maxillary sinus. In this patient both the maxillary sinus infundibulum and the ostiomeatal complex are nevertheless bilaterally pervious, thus potentially granting a correct sinusal secretion drainage.</p> | <p>A limited mucosal thickening associated to a periodontal, periapical infection with a patent OMC doesn't need further ENT evaluation</p> | |

FIGURE 2 (Continued)

to 41.8%.²⁸ This variability is likely due to anatomic-, surgical-, and patient-related factors that affect the risk of membrane laceration.^{7,19,29,30} It is therefore crucial to know and be aware of the

risk factors for membrane perforation. Multiple risk factors can contribute to increase the incidence of sinus membrane perforations (Table 6).

TABLE 2 Factors associated with maxillary sinus elevation difficulty and the associated scoring system

| Risk factor for perforation | Difficulty scoring | | |
|--|--|--|---|
| | 0 points | 1 point | 2 points |
| <i>Anatomic-related factors</i> | | | |
| Sinus membrane thickness | 1.5-2.0 mm | 0.8-1.49, 2.01-2.99 mm | <0.8, >3 mm |
| Presence of sinus septa | Absence of septa | One septum | Multiple septa or septum |
| Direction of sinus septa | Absence of septa | Mediolateral (transverse) | Anteroposterior (sagittal) |
| Height of sinus septa | Absence of septa | Height <6 mm | Height ≥6 mm |
| Type of edentulism and root position relative to the sinus cavity | Totally missing teeth (from second premolar to second molar) | Two adjacent missing teeth (between first premolar to second molar) | Single missing tooth (between second premolar to second molar)/Presence of teeth at the sinus elevation area and root into/close to the sinus lift area |
| Residual bone height | >4 mm | | <4 mm |
| Sinus width (angle between the lateral and the medial walls) | Wide (angle >60°) | Angle within 30°-60° | Narrow (angle <30°) |
| Palatonasal recess angle | Obtuse (>90°) | | Acute (<90°) |
| Alveolar antra artery | Diameter <1 mm | Diameter 1-2 mm | Diameter >2 mm |
| Buccal wall thickness | <1 mm | 1-2 mm | >2 mm |
| Zygomatic arch location | Apically positioned | | Coronally positioned |
| Bone dehiscence | Absent | Presented at the buccal wall | Presented at the ridge level or the medial wall |
| <i>Patient-related factors</i> | | | |
| Smoking habit | No | | Yes |
| Preoperative chronic sinusitis | No | | Yes |
| Gingival phenotype | Thick (≥1 mm) | | Thin (<1 mm) |
| Surgical access | Wide | | Narrow |
| Surgical access—elevation site relative to the surgeon's dominant hand | Left side for left-handed surgeon or right side for right-handed surgeon | Left side for right-handed surgeon or right side for left-handed surgeon | |
| Simple procedure | 0-8 points in the maxillary sinus elevation difficulty score | | |
| Moderate procedure | 9-16 points in the maxillary sinus elevation difficulty score | | |
| Difficult procedure | 17+ points in the maxillary sinus elevation difficulty score | | |

5.1.2 | Factors increasing perforation rate

Membrane thickness

It has been suggested that membrane thickness may influence the incidence of membrane perforation. An in vitro study by Pommer et al³¹ investigated the mechanical properties of the Schneiderian membrane. They found that the membrane had a mean thickness of $90 \pm 45 \mu\text{m}$ and it can be stretched up to 132.6% of its original size in one-dimensional elongation and up to 124.7% in two-dimensional elongation. Additionally, thicker membranes demonstrated higher load limits than thinner membranes, suggesting that membrane thickness plays a key role on the incidence of perforations during sinus floor augmentation.³¹

A study by Insua et al²⁷ explored the accuracy of cone beam computed tomography in determining the thickness of the membrane,

with histologic analysis that served as comparisons. They concluded that assessment via cone beam computed tomography resulted in 2.6 times more sinus membrane thickness than the histologic examination.²⁷ Similar findings, in terms of overestimation of membrane thickness with cone beam computed tomography, were also reported by Monje et al³² in a systematic review that analyzed 31 studies; the authors also reported that current data were inconclusive to link membrane thickness to the incidence of perforation.³² It has to be mentioned that the results in the literature regarding the influence of Schneiderian membrane thickness on the risk for membrane perforation are inconclusive. This is probably due to the retrospective nature of most studies conducted on this topic. Indeed, it has to be mentioned that histologic specimens may also be prone to shrinkage due to the nature of fixation relative to other measures.³³ A retrospective analysis by Lim et al³⁴ aimed to evaluate whether

TABLE 3 Specific maxillary sinus anamnesis

| | | | |
|----------------------------------|---|------------------------------|-----------------------------|
| Patient: _____ | | Data: _____ | |
| Medical history | | | |
| 1. | Do you suffer from any kind of allergies | YES <input type="checkbox"/> | NO <input type="checkbox"/> |
| 2. | Do you suffer from any chronic respiratory diseases? | YES <input type="checkbox"/> | NO <input type="checkbox"/> |
| 3. | Do you breathe from both nostrils? | YES <input type="checkbox"/> | NO <input type="checkbox"/> |
| 4. | Have you ever had any ear, nose, or throat diseases? | YES <input type="checkbox"/> | NO <input type="checkbox"/> |
| 5. | Do you use any nasal sprays? | YES <input type="checkbox"/> | NO <input type="checkbox"/> |
| 6. | Do you, or have you ever, suffered from sinusitis? | YES <input type="checkbox"/> | NO <input type="checkbox"/> |
| 7. | Have you ever visited an otorhinolaryngology or a maxillo-facial surgeon? | YES <input type="checkbox"/> | NO <input type="checkbox"/> |
| 8. | Do you have problems clearing your ears? (Scuba diving or descending from high altitudes) | YES <input type="checkbox"/> | NO <input type="checkbox"/> |
| 9. | Do you feel a bitter taste or secretion in the posterior part of your mouth? | YES <input type="checkbox"/> | NO <input type="checkbox"/> |
| Radiologic evaluation | | | |
| 10. | Does the computed tomography allow a correct visualization of the osteomeatal complex? | YES <input type="checkbox"/> | NO <input type="checkbox"/> |
| 11. | Is the osteomeatal complex patent | YES <input type="checkbox"/> | NO <input type="checkbox"/> |
| 12. | Are there any signs of radiopacity in the maxillary sinus? | YES <input type="checkbox"/> | NO <input type="checkbox"/> |
| COMMENTS _____ | | | |
| Primary Responsible: Name: _____ | | Sign: _____ | |

TABLE 4 Ear, nose, and throat assessment in the integrated management of candidates for maxillary sinus floor elevation procedure (Adapted from Pignataro et al 2008¹⁷)

1. Preventive-diagnostic step aimed at excluding any nasosinus disease that may lead to failure of the surgery
2. Preventive-therapeutic step aimed at correcting any pathologic findings that represent reversible contraindications to a sinus lift
3. Diagnostic-therapeutic step (if necessary) aimed at ensuring the prompt diagnosis and appropriate treatment of any possible sinus lift-related nasosinus complications

the morphology of the sinus membrane (normal, polypoid, irregular, or complete thickening/obstruction) and its thickness affected the incidence of complications. The authors observed that a membrane thickness of up to 2 mm with an irregular morphology was the most common type of Schneiderian membrane. However, there was no statistically significant association between membrane morphology or thickness and the incidence of perforation or postoperative complications.³⁴ Among the studies that found a significant correlation between membrane thickness and increased risk of perforation, some of them reported that membrane tearing was more frequent in the presence of thin membranes (less than 1 mm),³⁵⁻³⁷ whereas Park et al³⁸ observed that the Schneiderian membrane was significantly thicker in patients with perforations compared with those patients without a perforation. On the other hand, Lim et al³⁴ found that the perforation rate was lowest when membrane thickness was 1-1.5 mm and that membrane thickness less than 1 mm or 2 mm or more was associated with the highest incidence of perforation.

This heterogeneity in the outcomes of studies investigating the influence of membrane thickness on perforation rate during sinus floor elevation is probably due to several reasons, including the

previously mentioned retrospective nature of most studies and possible confounding variables that may also affect the reported perforation rate. Indeed, several other factors, such as residual alveolar ridge height, sinus morphology, lateral wall thickness, presence of sinus pathoses before the surgery, presence of sinus septa, smoking habit, the area of treatment, and osteotomy technique, can also play a role in the incidence of perforations.^{35,36,38-42}

On the other hand, one has to bear in mind that an excessive thickening of the membrane is usually a sign of altered sinus physiology. Rak et al⁴³ noticed an increased risk of sinusitis when membrane thickness was more than 2 mm, whereas others stated that sinus mucosa thicker than 5 mm was correlated to an increased risk of ostium obstruction and sinusitis.^{44,45} In particular, Carmeli et al⁴⁵ classified different grades of mucosal thickening using computed tomography scans. They stated that a rounded sinus mucosa is usually associated with a low risk of complications following sinus floor elevation, whereas an irregular, circumferential, and/or complete thickening is associated with an increased risk of sinus obstruction. Therefore, the preoperative assessment of maxillary sinus with computed tomography can be considered mandatory, as well as referring the patient to an otorhinolaryngologist for further evaluation in case of membrane thickening greater than 4 mm.^{7,19}

Lastly, it is important to mention that an increased thickness of a diseased membrane is usually correlated with a weaker membrane with gelatinous texture, whereas thickening of a healthy membrane occurs at the level of the periosteal layer and may positively contribute to its strength.⁷

Sinus septa

Sinus septa, or Underwood's septa, are not rare findings during sinus floor elevation.^{46,47} Although a high variability has been reported in

TABLE 5 Presumably irreversible and potentially reversible otorhinolaryngology contraindications to maxillary sinus augmentation

| Presumably irreversible otorhinolaryngology contraindications | Potentially reversible otorhinolaryngology contraindications |
|--|--|
| <p><i>Anatomic-structural alterations:</i></p> <ul style="list-style-type: none"> • Serious deformities and posttraumatic, postsurgical, and postradiotherapy scarring on the nasal-sinus walls and/or mucosa lining | <p><i>Anatomic-structural alterations:</i></p> <ul style="list-style-type: none"> • Stenosis of the drainage-ventilation pathways in the maxillary sinus (sustained by one or more of the following anatomic alterations): septal deviation, paradox curve of the middle turbinate bone, conchae bulla, hypertrophy of the agger nasi cell, presence of Haller cell), postsurgical scars or synechiae on the osteomeatal complex, oroantral fistula. All these alterations can be resolved with surgery; the maxillary sinus appears to be well ventilated due to a partial uncinectomy |
| <p><i>Inflammatory-infective processes:</i></p> <ul style="list-style-type: none"> • Reoccurring or chronic sinusitis, with or without polyps, which cannot undergo resolution as they are associated with congenital mucociliary clearance alterations (eg, cystic fibrosis, Kartagener syndrome, Young syndrome), to intolerance of acetylsalicylic acid (triad: nasal polyps, asthma, intolerance to acetylsalicylic acid), to immunologic deficiency (eg, acquired immune-deficiency syndrome, pharmacologic immunosuppression) | <p><i>Inflammatory-infective processes:</i></p> <ul style="list-style-type: none"> • Acute viral or bacterial rhinosinusitis, allergy-related rhinosinusitis, mycotic sinusitis (noninvasive forms), acute repeating and chronic sinusitis sustained by one of the anatomic alterations listed above that obstructs the sinus drainage-ventilation ways, by endoantral foreign bodies, or by nasal polyps. Functional endoscopic surgery is clearly indicated |
| <p><i>Nasal-sinus manifestations of aspecific systemic granulomatous diseases:</i></p> <ul style="list-style-type: none"> • Wegener granulomatosis, "idiopathic midline granuloma" and sarcoidosis | <p><i>Tumor related:</i></p> <ul style="list-style-type: none"> • Nonobstructive nasal-sinus benign tumors, both before and after the procedure, could affect the sinus drainage-ventilation ways or when removal does not affect the mucociliary transportation system (eg, mucosa cysts, cholesterolic granuloma, antrochoanal polyp; all are easily subject to correction by functional endoscopic surgery) |
| <p><i>Tumor-related:</i></p> <ul style="list-style-type: none"> • Locally aggressive benign tumors (eg, inverted papilloma, myxoma, ethmoidal-maxillary fibromatosis) in antrum • Nasal-sinus malignant tumors (epithelium, neuroectodermal, bone, soft tissue, odontogenous, lymphomatous, metastatic-originated) of the maxillary sinus and/or adjacent structures | |

the literature, it has been estimated that the prevalence of sinus septa is approximately 30%.^{7,23,46,48,49} They consist of a bone cortex, usually oriented in a buccopalatal direction (Figure 3A-D), that divides the distal part of the sinus into multiple compartments; mesiodistal septa are less common (Figure 3E,F).⁷ Though primary septa are congenital and arise from development of the maxilla, it has been speculated that secondary septa develop following tooth loss.⁴⁷ It has been shown that primary septa are more often located in the anterior-medium part of the sinus, whereas secondary septa are more commonly found in the posterior area of the sinus.⁵⁰ The presence and the height of septa have also been correlated to variation in membrane thickness.⁵⁰ The prevalence and characteristics of sinus septa are summarized in Table 7.

The orientation of the septa, whether mediolateral (transverse) or anteroposterior (sagittal) also plays a key role in the design of the osteotomy window during sinus elevation.^{30,51} Wen et al⁵¹ identified a 6 mm septum height as the cutoff point for clinicians to carefully address the surgical design, as these cases may be more prone to membrane perforation. Several approaches have been suggested for sinus floor augmentation in the presence of sinus septa, including one window with the wall-off/wall-gone technique, preparation of two windows/antrostomies, or extending the window over the septum.^{7,51,52} Owing to the increased technical difficulties posed by the

presence of septa, it is not surprising that several researchers found a correlation between these anatomic structures and a higher membrane perforation rate.^{41,42,53,54}

Osteotomy technique

In order to reduce the risk of membrane tearing, new instruments have been proposed for performing the antrostomy and replacing the conventional rotary instruments. In a technical note, Torrella et al⁵⁵ described for the first time the use of a periodontal ultrasonic generator to perform a lateral antrostomy. Later on, a novel device specifically designed for piezoelectric bone surgery was introduced with the aim of reducing perforation incidence during sinus floor elevation.⁵⁶ The main advantages of the piezoelectric device are its selective cutting action of mineralized tissue and its precise osteotomies with enhanced surgical control.⁵⁷

Nevertheless, in a randomized clinical trial comparing the performance of rotary instruments and a piezoelectric device during maxillary sinus floor elevation, Barone et al⁵⁸ failed to find any differences in the parameters investigated (perforation rate and time necessary to perform the osteotomy). Similar findings were also found in two other trials.^{59,60} However, a split-mouth randomized controlled study found a significant lower perforation rate in the sites that were assigned to ultrasonic surgery compared with the

TABLE 6 Incidence and risk factors of membrane perforation

| Article | Study design | Sinus augmentation N | Incidence of perforations (%) | Factors associated with increased perforation risk |
|--|-----------------------------|----------------------|--|--|
| Alayan and Ivanovski (2018) ⁹⁴ | Randomized controlled trial | 60 | 13.3 | Not Reported (NR) |
| Barone et al (2008) ⁵⁸ | Randomized controlled trial | 26 | 23.1 with conventional rotary instruments, 30.8 with piezoelectric device | NR |
| Delilbasi and Gurler (2013) ⁶⁰ | Randomized controlled trial | 21 | 10 with conventional rotary instruments, 9.1 with piezoelectric device | NR |
| Kaigler et al (2015) | Randomized controlled trial | 26 | 30.8 | NR |
| Rickert et al (2013) ⁵⁹ | Randomized controlled trial | 72 | 11.1 | NR |
| Scarano et al (2015) ⁶¹ | Randomized controlled trial | 24 | 33.3 with conventional rotary instruments, 0 with piezoelectric device | NR |
| Ardekian et al (2006) ³⁹ | Retrospective study | 110 | 31.8 | Residual ridge height ($P < 0.01$) |
| Beck-Broichsitter et al (2018) ⁹⁶ | Retrospective study | 201 | 20.4 | NR |
| Cho et al (2001) ⁶⁷ | Prospective case series | 49 | 18.4 overall. 37.5 when the angle was $<30^\circ$; 28.6 when the angle was 31° - 60° ; and 0 when the angle was $>61^\circ$ | Sinus anatomy (angle between the lateral and medial walls) |
| Ferreira et al (2017) | Retrospective study | 745 | 31.8 | NR |
| Froum et al (2012) | Retrospective study | 40 | 37.5 | NR |
| Hernández-Alfaro et al (2006) ⁹³ | Retrospective study | 474 | 21.9 | NR |
| Khoury (1999) ⁷² | Retrospective study | 216 | 23.6 | NR |
| Lim et al (2017) ³⁴ | Retrospective study | 29 | 58.6 | NR |
| Lin et al (2015) | Retrospective study | 81 | 17.28 | Membrane thickness ($P < 0.05$) |
| Lum et al (2017) ³⁵ | Retrospective study | 167 | 28.1 | Membrane thickness ($P < 0.001$) and residual alveolar bone height ($P < 0.001$) |
| Marin et al (2019) ³⁶ | Retrospective study | 137 | 13.9 | Maxillary sinus contour ($P < 0.001$), membrane thickness ($P < .005$) |
| Monje et al (2016) ⁴⁰ | Retrospective study | 40 | 12.5 | Lateral wall thickness ($P < 0.001$), residual alveolar bone height ($P < 0.001$) |
| Nolan et al (2014) ⁸⁸ | Retrospective study | 359 | 41 | NR |
| Oh and Kraut (2011) | Retrospective study | 175 | 34.3 | NR |
| Park et al (2019) ³⁸ | Retrospective study | 65 | 39 | Membrane thickness ($P < 0.001$), presence of sinus pathoses before the surgery ($P < 0.05$) |
| Park et al (2019) ⁹⁷ | Retrospective study | 207 | 35.3 | NR |
| Schwarz et al (2015) ⁴¹ | Retrospective study | 407 | 8.6 | Presence of sinus septa (odds ratio 4.7, $P < 0.05$), decreased residual bone height (odds ratio 0.01, $P < 0.001$), smoking (odds ratio 4.8, $P < 0.05$) |
| Shiffler et al (2015) ¹¹⁴ | Retrospective study | 107 | 59.8 | NR |

(Continues)

TABLE 6 (Continued)

| Article | Study design | Sinus augmentation N | Incidence of perforations (%) | Factors associated with increased perforation risk |
|---------------------------------------|-------------------------------------|----------------------|--|--|
| Testori et al (2012) | Retrospective study | 144 | 27.8 | NR |
| Tükel and Tatli (2018) ⁵⁴ | Retrospective study | 120 | 18.3 | Residual bone height 3-6 mm (odds ratio 6.8, $P < 0.05$), presence of sinus septa (odds ratio 4, $P < 0.05$) |
| von Arx et al (2014) ⁴² | Retrospective study | 77 | 27.3 | Smoking habit, simultaneous implant placement, mixed premolar-molar sites, presence of septa, residual alveolar ridge height (however, these trends were showed no statistically significant difference) |
| Wallace et al (2007) | Retrospective study | 100 | 7 | NR |
| Weitz et al (2014) | Retrospective study | 40 | 17.5 | NR |
| Yilmaz and Tozum (2011) ³⁷ | Retrospective study | 44 | 25 | Membrane thickness ($P < 0.001$), residual alveolar ridge height ($P < 0.05$), and gingival phenotype ($P < 0.05$) |
| Ghasemi et al (2017) ¹¹⁸ | Systematic review and meta-analysis | – | NR | NR |
| Al-Dajani (2016) ²⁸ | Systematic review and meta-analysis | – | 23.5 | Reduced membrane thickness, presence of sinus septa and using conventional rotary instruments |
| Jordi et al (2018) ⁶² | Systematic review and meta-analysis | – | 24 with conventional rotary instruments, 8 with piezoelectric device | Using conventional rotary instruments |
| Monje et al (2016) ³² | Systematic review | – | NR | Inconclusive data regarding correlation between membrane thickness and perforation rate |
| Stacchi et al (2017) ⁶³ | Systematic review | – | 15.7 | Using rotary instruments |
| Stacchi et al (2020) ⁵⁷ | Systematic review and meta-analysis | – | 12.5 (with piezoelectric device) and 16.9 (with conventional rotary instruments) | NR |
| Pjetursson et al (2008) ⁴ | Systematic review | – | 19.5 (range 0-58.3) | NR |

contralateral sites, in which rotary instruments were used for the osteotomy.⁶¹ Lastly, two systematic reviews concluded that using rotary instruments for lateral wall osteotomy is a risk factor for sinus membrane perforation.^{62,63}

Other risk factors

Several studies have found a significant correlation between a decreased residual alveolar ridge height and a higher membrane perforation rate.^{35,37,39–41,54} It has been suggested that a reduced residual bone height may limit the maximum elevation that can be achieved without tearing the membrane.^{31,39,41,64,65} On the other hand, it should be mentioned that a study by Avila-Ortiz et al,⁶⁶ aiming at evaluating the influence of residual alveolar bone height on

sinus floor elevation outcomes, failed to find a correlation between remaining bone height, maturation, and consolidation of grafted allograft in the maxillary sinus. Therefore, it is reasonable to assume that the residual alveolar ridge height may play a role only in the difficulty of membrane detachment and elevation during the surgical procedure but may not necessarily affect the outcome of sinus augmentation.

The morphology of the sinus may also influence the incidence of membrane perforation. According to Cho et al,⁶⁷ a narrow sinus anatomy (with an angle of less than 30° between the lateral and medial walls of the sinus) was associated with a higher perforation rate (62.5%) than a sinus with angles between 30° and 60° or even wider sinuses was, where the perforation was 28.6% and 0%, respectively.

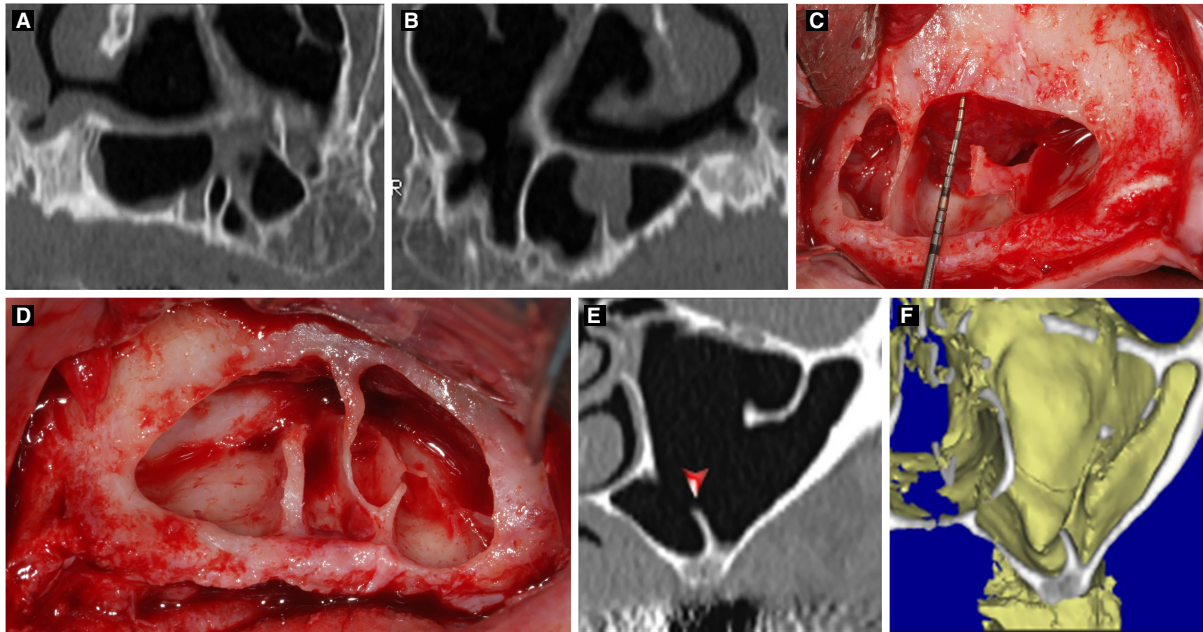


FIGURE 3 A, B, Cone beam computed tomography depicts multiple septa aligned with a buccal/palatal orientation. C, D, Clinical photographs show septal preservation following sinus membrane elevation. E, F Cone beam computed tomography depicts a mesiodistal-oriented septum; three-dimensional rendering of the sinus more clearly denotes septum direction and morphology. A buccal-palatal septum is visible in the posterior recess

It has also been shown that a narrow sinus morphology can more often be found in the second premolar area, where the elevation may be more prone to perforation.⁶⁸ The angle between the roof of the hard palate and the lateral wall of the nasal cavity (defined as “palatonasal recess angle”) can also affect the risk of perforation.⁶⁹ Chan et al⁶⁹ suggested that an acute palatonasal recess angle (90° or less) could pose additional challenges during sinus membrane elevation on the medial wall, increasing the occurrence of membrane perforation. If the angle is acute and located approximately within 10mm from the sinus floor, care must be taken to keep the elevator on the bone surface while not trapping or tearing the membrane.⁷ Similarly, Marin et al³⁶ demonstrated that a narrow, tapered sinus contour was a risk factor for membrane perforation.

According to Monje et al,⁴⁰ a higher perforation rate occurred when the maxillary lateral wall was less than 1.25 mm thick, with the authors suggesting that bone density and quality can also increase the risk of perforation.

Other factors that were found to negatively affect membrane perforation rate include smoking habit⁴¹ and the presence of sinus pathoses (such as membrane thickening, obstruction of ostium, polypoid lesions or cysts) before the surgery.³⁸ Indeed, Park et al³⁸ speculated that the presence of sinus pathoses can lead to poor membrane vasculature and elasticity, secondary necrosis, and less resistance during the elevation. In the cases of sinus pathoses, membrane perforation may cause the leakage of cystic fluid or purulent exudate, and suctioning or washing with saline to prevent contamination of the bone graft is recommended.

Lastly, von Arx et al,⁴² in a retrospective investigation, mentioned that smoking habit, simultaneous implant placement, mixed premolar-molar sites, presence of septa, and residual alveolar ridge height of 4 mm or less seemed to increase the rate of perforation rate, though statistical significance was lacking.

5.1.3 | Difficulty scores based on risk of perforations

Based on the aforementioned factors that can potentially increase the difficulty of the surgery and the risk of perforation, several difficulty scores have been proposed for lateral sinus floor elevation. Tavelli et al¹⁹ introduced a difficulty score based on anatomic factors that can increase the risk of membrane perforation, such as bone dimension and other parameters, in order to presurgically assess the complexity of sinus augmentation. Later on, Testori et al³⁰ further expanded this complexity score by identifying low, moderate, and high risk for complications of each individual anatomic- and patient-related factor. The perforation risk assessment was then defined based on the number of conditions at moderate or high risk of perforation.³⁰ More recently, a complexity score defining maxillary sinus floor elevation as simple, moderate, or difficult has also been proposed by our group, with the aim of promoting a comprehensive presurgical evaluation prior to lateral wall sinus augmentation, as well as for enhancing communication between clinicians and patients regarding the complexity of the case²⁹ (Table 2).

TABLE 7 Prevalence, characteristics, and location of sinus septa.

| Study | Method of assessment | Sinuses N | Prevalence of septa (%) | Septa height (mm) | Location (%) | Orientation (%) |
|--|-------------------------------------|-------------------|-------------------------|--|--|--|
| Ulm et al (1995) | Cadavers | 41 | 31.7 | 7.9 | Premolar: 73.3 First molar: 19.9 Second molar: 6.6 | Not applicable |
| Krennmair et al (1999) | Clinical examination | 122 | 27.8 | 8.6 | Premolars: 70.5 First molar: 29.4 Second molar: 0 | Not applicable |
| Velasquez-Plata et al (2002) ⁴⁸ | Computed tomography | 100 | 14 | 12.2 | Premolars: 57.1 First molar: 42.9 Second molar: 0 | Not applicable |
| Kim et al (2006) | Computed tomography | 200 | 26.5 | Lateral: 1.63 Middle: 3.55 Medial: 5.46 | Anterior: 24 Middle: 41 Posterior: 21 | Not applicable |
| Neugebauer et al (2010) | Cone beam computed tomography | 2058 | 33.2 | NA | Second premolar: 17.1 First molar: 31.6 Second molar: 27.6 | Medial-lateral: 74.7, anterior-posterior: 25.3 |
| Rosano et al (2010) ⁴⁹ | Cadavers | 60 | 33.3 | 8.72 | Second premolar-first molar: 30 First and second molar: 40 | Medial-lateral: 30, anterior-posterior: 70 |
| Park et al (2011) | Computed tomography | 400 | 27.7 | 7.8 | Premolars: 22.5 First and second molar: 45.9 | Medial-lateral: 96.3, anterior-posterior: 3.6 |
| Pommer et al (2012) ²³ | Systematic review and meta-analysis | 8923 (33 studies) | 28.4 | 7.5 on average | Premolar: 24.4 Molar: 54.6 Retromolar: 21 | Medial-lateral: 87.6 |
| Rancitelli et al (2015) ⁵⁰ | Cone beam computed tomography | 228 | 38.1 | Primary septa: 5.5 on average Secondary septa: 3.4 on average | Anterior: 29.4 Middle: 35.7 Posterior: 34.7 | Not applicable |
| Qian et al (2017) | Cone beam computed tomography | 390 | 32.6 | Lateral: 4.39 Middle: 5.56 Medial: 6.44 | Anterior: 35 Middle: 41 Posterior: 24 | Medial-lateral: 93.8 |

5.1.4 | Management of intraoperative perforations

Prevention is always better than therapy; hence, a comprehensive preoperative case assessment together with a thorough knowledge of the three-dimensional sinus anatomy can significantly reduce the incidence of membrane perforation. In any case, perforations do occur, and clinicians should be aware that the fragility of the Schneiderian membrane increases if perforated. A careful elevation of the membrane around the perforation can release the tension on the perforated area, facilitating the elevation of the membrane.

The size and location of the perforation determine whether or not it is possible to continue the surgical procedure and the technique for repairing the laceration. Vlassis and Fugazzotto⁷⁰ were the first to classify membrane perforation in five types, based on their position and extent. Later on, the same authors introduced a simplified classification and repair system for membrane perforation with the aim of providing an easily utilized framework to deal with this complication.⁷¹ Perforations occurring in the most apical part of the window were defined as type I. Vlassis and Fugazzotto suggested to place a collagen membrane below the perforation even though it may be sealed spontaneously with the elevation. Perforations located in the lateral or coronal walls of the window were classified as type II. In these scenarios, clinicians should evaluate whether it is possible to extend the antrostomy 4-5 mm proximal to the perforation (type IIA if possible, type IIB if not). It was suggested to treat type IIA perforation by enlarging the osteotomy until exposing further intact membrane and applying a collagen barrier after membrane elevation. Fixing a collagen membrane to the bone around the osteotomy was recommended for both type IIB and type III perforations (perforations occurring at any location within the body of the prepared sinus window). The authors presented 19 consecutively treated cases with successfully managed sinus perforations, without any negative effects on outcome of the dental implants.⁷¹

Small perforations (less than 5 mm) may not need to be repaired, since the membrane tends to fold on itself when elevated from the floor and the other bony walls. Nevertheless, an absorbable collagen or a platelet-rich fibrin membrane can be applied as a patch below the perforation. Other approaches for managing small or medium-size perforations (from 5 to 10 mm) can include the use of collagen membrane with fibrin glue,⁷² the use of biologic agents, such as plasma rich in growth factors or platelet-rich fibrin,⁷³⁻⁷⁵ autogenous periosteal graft,⁷⁶ or amnion-chorion barriers.⁷⁷ In the case of large perforations, fixating the absorbable collagen membrane with external tacking or internal sutures has been recommended.^{77,78,79} Owing to the rigidity of the material, the use of freeze-dried human lamellar bone sheets has also been suggested as a means of avoiding dispersion of the graft material into the sinus.^{8,80} The "Loma Linda pouch technique" involves the folding of a large absorbable membrane into the sinus in such a way that the particulate graft material is completely contained.⁷⁸ This approach may compromise the vascular

supply for the bone graft, especially if in the case of utilizing non-vital bone replacement grafts. Nevertheless, a study from Testori et al⁷⁹ demonstrated the efficacy of this technique with histologic evidence of vital bone that was not negatively affected by the occurrence of membrane perforation.

However, if the repair of a perforated sinus membrane does not appear to provide a stable result, the surgery should be aborted and the membrane allowed to heal.⁷ According to Watelet et al,⁸¹ complete healing of the sinus membrane may take up to 6 months. After this healing period, it is possible to repeat the sinus augmentation. However, after the abortion of the technique and flap closure, the buccal bony wall of the sinus usually will not reform; hence, the surgeon has to perform a split-thickness flap in order to detach the mucosal flap by the sinus membrane.⁸²

To summarize, the following clinical recommendations have been provided for membrane repair: (a) membrane elevation should not be performed close to a laceration; (b) a small perforation may not need to be repaired, with membranes that fold over themselves after elevation; it is advisable to use collagen membrane or platelet-rich fibrin to protect the elevated membrane that has been perforated (Figure 4A,B); (c) medium- and large-size perforations require the enlargement of the antrostomy, when possible; (d) a bioabsorbable membrane should be stabilized in the case of large perforations⁷⁹ (Figure 4C-I).

5.1.5 | Healing of perforated membranes

Split-mouth animal studies offer the possibility of investigating the effect of membrane perforation repairs as well as the amount of new bone formation.^{83,84} An animal study demonstrated that, after the repair of a perforated membrane with a collagen barrier membrane, the repaired side had a greater percentage of newly formed bone than the nonrepaired side, although no statistically significant difference was found.⁸³ Although, after a 2-week healing period, graft penetration in the sinus was not observed, at the 4-week time point a higher penetration of biomaterial was observed in the group that received a collagen membrane for repairing the perforation. The authors speculated that the collagen membrane could jeopardize the healing of the sinus membrane. After 12 weeks, both groups displayed complete healing of the sinus mucosa without any discontinuity. New bone formation was also observed from the fourth week, starting from the sinus bony wall.⁸³ A recent animal study by Lim et al⁸⁴ demonstrated that new bone formation was significantly delayed at 2 and 4 weeks in the perforated sinus repaired with a collagen membrane compared with a sinus with intact membranes. In particular, new bone formation in the region close to the lateral and medial sinus bone walls was significantly lower in the perforated group at 2 weeks, with no significant differences observed at 4 weeks. Similarly, the microcomputed tomographic and histomorphometric analyses revealed no significant difference in the augmented volume between the two groups. The authors speculated

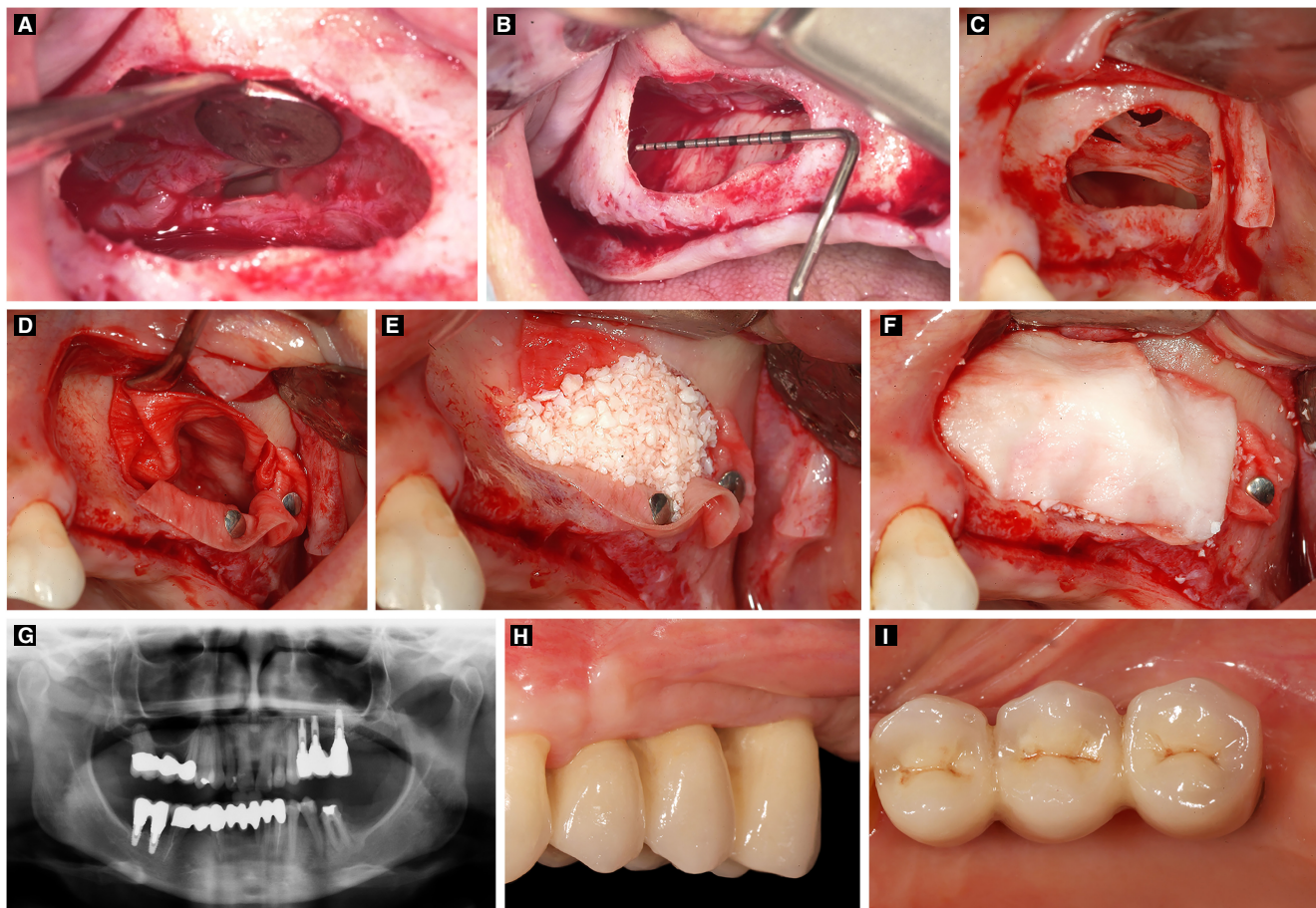


FIGURE 4 A, Small sinus membrane perforation. B, Sinus membrane was elevated to the medial sinus wall. Perforation margins were cohered by elevated sinus membrane foldback and supplemented with an additional platelet-rich fibrin membrane. C, Example of extended sinus membrane perforation (Courtesy of Testori T. With permission Acme, Viterbo, Italy). D, Fixation of resorbable membrane with titanium nails (Frios, Friadent, Mannheim, Germany) was achieved. Bio-Gide (Geistlich Pharma Ag, Wolhusen, Switzerland) was placed on vestibular bone theca (Courtesy of Testori T. With permission Acme, Viterbo, Italy). E, Membrane was reflected inside the sinus with addition of deproteinized bovine bone graft (Bio-Oss Spongy Granules 0.25-1 mm, Geistlich Pharma Ag, Wolhusen, Switzerland) and completed (Courtesy of Testori T. With permission Acme, Viterbo, Italy). F, Collagen membrane (Bio-Gide, Geistlich Pharma Ag, Wolhusen, Switzerland) was placed outside the vestibular wall to cover the antrostomy (Courtesy of Testori T. With permission Acme, Viterbo, Italy). G-I, The 5-year follow up of panorex and clinical photographs (Courtesy of Testori T. With permission Acme, Viterbo, Italy)

that large collagen membranes covering the perforated sinus membrane and the lateral/mesial sinus bony wall may act as a physical barrier to osteogenic sources, delaying bone formation from the sinus bone walls.⁸⁴

According to Öncü and Kaymaz,⁸⁵ membrane repair with platelet-rich fibrin provides similar bone gain, histologic new bone formation, and possibly vasculogenesis, compared with sinus floor augmentation with an intact Schneiderian membrane.

Interestingly, a recent study by Thoma et al⁸⁶ showed that implants coated with recombinant human bone morphogenetic protein-2 had more favorable outcomes than uncoated implants did, with a stronger osteogenic reaction, higher new bone formation, and accelerated healing that may, at the same time, prevent the collapse of the sinus membrane as well. Recombinant human bone morphogenetic protein-2 may have also had a beneficial role in cases with perforations of the sinus membrane. Therefore, future studies are needed to confirm this speculation.

5.1.6 | Long-term outcomes of implants placed in perforated membranes

It has been advocated that membrane perforation can increase the risk for graft failures, sinus infection, peri-implant bone loss, and implant failure.^{72,87-91} Some researchers have reported that the implant survival rate after membrane perforation can drop to 50%-70%.^{72,87,92} According to Hernández-Alfaro et al,⁹³ the survival rate of implants placed under repaired membranes correlated inversely with the size of the perforation. Implants placed in the group of membrane laceration less than 5 mm showed a survival rate of 97%, whereas in cases with a perforation size of 5-10 mm and greater than 10 mm the implant survival rate dropped to 92% and 74%, respectively.⁹³ Nevertheless, most of the available articles in the literature seem to support the notion that membrane perforation does not play a role in an implant's survival rate (Table 8).

TABLE 8 Effect of membrane perforation on the clinical outcomes

| Article | Membrane perforation incidence (%) | Technique for membrane perforation repair | Implant survival rate in the non-membrane perforation group (%) | Implant survival rate in the membrane perforation group (%) | Conclusions |
|--|------------------------------------|---|---|---|---|
| Alayan and Ivanovski (2018) ⁹⁴ | 13.3 | Pouch technique using resorbable collagen membrane fixed with titanium tacks | 100 | 100 | Membrane perforation did not affect the clinical outcomes |
| Ardekian et al (2006) ⁹⁹ | 31.8 | Using a collagen membrane | 93.9 | 94.4 | Membrane perforation did not affect the clinical outcomes |
| Beck-Broichsitter et al (2018) ⁹⁶ | 20.4 | Using a collagen membrane, with additional sutures for 5-10 mm perforations | 98.9 | 100 | Higher trend for peri-implantitis in patients with perforation ($P < 0.001$). No differences in terms of implant survival or bone resorption between the two groups |
| Beck-Broichsitter et al (2020) ⁹⁵ | Not applicable | Using a collagen membrane, with additional sutures for 5-10 mm perforations | Not applicable | 98 | Membrane perforation does not increase the risk for complications |
| Cho et al (2001) ⁶⁷ | 18.4 | NR | 91.1 | 94.4 | Membrane perforation did not affect the clinical outcomes |
| Engelke and Capobianco (2005) ¹⁴⁹ | 16.7 | Using a poly(lactin mesh (Vicryl) | 94.8 | 100 | Membrane perforation did not affect implant survival rate |
| Ferreira et al (2017) | 31.8 | Using resorbable suture or a collagen membrane stabilized with tacks | 97.7 | <ul style="list-style-type: none"> 97.7 for small perforations 97.3 for medium perforations 95.4 for large perforations | The difference in implant survival rate in the perforated and nonperforated groups was not significant, and the size of the perforation did not negatively affect implant survival rate |
| Froum et al (2012) | 37.5 | Using a collagen membrane | 95.5 | 100 | No statistically significant difference in terms of implant failure rates between membrane perforated and nonperforated groups. A significantly higher percentage of vital bone was observed in the perforated/repared sinuses |
| Hernández-Alfaro et al (2006) ⁹³ | 21.9 | Perforation size <5 mm: suturing or collagen membrane Size 5-10 mm: lamellar bone + collagen membrane. >10 mm: lamellar bone with or without buccal fat pad or bone block graft | 100 | 90.81 <ul style="list-style-type: none"> 97.14 in the <5 mm perforation group 91.89 in the 5-10 mm perforation group 74.14 in the >10 mm perforation group | All the 25 implants that failed to integrate were placed under perforated membrane. Statistically significantly higher implant survival rate in perforations <5 mm compared with perforations >10 mm The survival rate of implants placed under reconstructed membranes correlated inversely with the size of the perforations. |
| Karabuda et al (2006) ¹⁵⁰ | 13.2 | Bioabsorbable membrane | 96.2 | 92.3 | Perforation of the sinus membrane did not compromise implant osseointegration or their survival rate |

(Continues)

TABLE 8 (Continued)

| Article | Membrane perforation incidence (%) | Technique for membrane perforation repair | Implant survival rate in the non-membrane perforation group (%) | Implant survival rate in the membrane perforation group (%) | Conclusions |
|---|------------------------------------|--|---|---|--|
| Nolan et al (2014) ⁸⁸ | 41 | Using oxidized cellulose polymer | NR | NR | Significantly higher incidence of sinusitis, infection required antibiotics, and graft failure when the membrane was perforated |
| Oh and Kraut (2011) | 34.3 | Using a collagen membrane | 99 | 97 | Perforation of the membrane does not cause negative long-term effect on sinus bone grafts and dental implants |
| Park et al (2019) ³⁸ | 39 | Nonrepaired | 100 | 100 | Nonrepair of the membrane perforation did not adversely affect the outcomes. Significantly higher complication rate in the membrane perforation group (bleeding, leakage of cystic fluid, purulent exudate from sinus pathoses, graft displacement into the sinus, post-operative nasal bleeding and facial swelling). Bone graft height was stable in both groups |
| Park et al (2019) ⁹⁷ | 35.3 | Using a collagen membrane | 77.7 | 91 | The cumulative implant survival rate of implants placed in perforated versus nonperforated membrane was not statistically significant |
| Pjetursson et al (2008) ^{4, a} | 19.5 | Tissue fibrine glue, suturing or using a collagen membrane | NR | NR | The risk for infection seemed to increase with membrane perforation. |
| Proussaefs et al (2003) ⁹² | 50 | Collagen membrane | 100 | 54.5 | Nonperforated sites had more bone formation and higher implant survival rate than perforated sites |
| Proussaefs et al (2004) ⁸⁷ | 50 | Collagen membrane | 100 | 69.5 | Nonperforated sites had more bone formation and higher implant survival rate than perforated sites |
| Ragucci et al (2019) ^{124, a} | — | — | — | 95.6 | The overall implant survival rate is not affected by the level of penetration into the sinus cavity. The most frequent complications were epistaxis and thickening of the sinus membrane (no statistically significant difference between the different level of penetration into the sinus) |
| Rickert et al (2013) ⁵⁹ | 11.1 | — | 100 | 100 | Implant survival rate is not affected by membrane perforation, and there are no advantages of piezoelectric device over rotative instruments |

TABLE 8 (Continued)

| Article | Membrane perforation incidence (%) | Technique for membrane perforation repair | Implant survival rate in the non-membrane perforation group (%) | Implant survival rate in the membrane perforation group (%) | Conclusions |
|--|------------------------------------|---|---|---|---|
| Schwarz et al (2015) ⁴¹ | 8.6 | Using a collagen membrane | NR | NR | Membrane perforation is associated with higher chance of developing postoperative sinusitis |
| Shiffler et al (2015) ¹¹⁴ | 59.8 | Using collagen tape or without the tape (nonrepaired) | NR | NR | Membrane perforation (or its size) did not affect the incidence of postoperative complications |
| Shlomi et al (2004) ⁸⁰ | 28 | Freeze-dried human lamellar bone sheet | 91 | 90 | No complications were observed in case with membrane perforation |
| Testori et al | 27.8 | Using a collagen membrane | NR | NR | Membrane perforation was not a risk factor for implant survival |
| Tükel and Tatli (2018) ⁵⁴ | 18.3 | Using a collagen membrane | NR | NR | Membrane perforation does not affect the incidence of postoperative sinusitis but can have a negative effect on graft success |
| Viña-Almunia et al (2009) ^a | — | — | 98 | 88.6 | The survival of implants diminishes when they are placed in sinus lifts with perforated membrane |
| Yilmaz and Tozum | 25 | As described by Viassis and Fugazzotto ⁷⁰ | NR | NR | No significant differences in implant failure between perforated and nonperforated membranes |

^aSystematic review.

It can be speculated that the progressive advancement in instruments, materials, and techniques has significantly reduced the incidence of membrane perforation and also has had a positive impact on the success of membrane repair. It is therefore not surprising that recent studies failed to find a correlation between implants placed under a perforated membrane and decreased survival rate, compared with the survival rate of implants placed in nonperforated membranes.⁹⁴⁻⁹⁷ Beck-Broichsitter et al⁹⁶ recently demonstrated that intraoperative membrane perforation can successfully be managed without impairing long-term graft stability and implant survival rate. Interestingly, Park et al³⁸ found that nonrepaired Schneiderian membrane perforations did not adversely affect the clinical and radiographic outcomes of the implants.

Lastly, a systematic review and meta-analysis reported membrane perforation to be significantly associated with postoperative sinusitis but not with implant failure.⁹⁸ Smoking and residual bone height were found to be the only two factors affecting implant survival.⁹⁸

It can be concluded that, although membrane perforation may result in higher risk for postoperative complications, including sinus congestion, infection, and nasal bleeding,^{38,88,99} implant survival rate seems not to be affected by the membrane perforation.

5.2 | Intraoperative bleeding

Intraoperative hemorrhage during sinus floor augmentation commonly results from injury to branches of the vascular supply of the lateral sinus wall during preparation of the lateral wall using rotary instruments. Bleeding may also occur from the soft tissues during flap elevation. Intraoperative bleeding is usually minor, but in some instances it can be difficult to control with decreased visibility. Zijdeveld et al⁸ reported profuse bleeding that compromised the visualization of the antrostomy in 2% of cases.

5.2.1 | Pertinent vascularity in the maxillary sinus area

The hematic contribution to the maxillary sinus is guaranteed by three main arteries, subdivisions of the maxillary artery: the infraorbital artery, the posterior lateral nasal artery, and the posterior superior alveolar artery, all of which may be encountered during lateral approach sinus elevation surgery.

The vascularization of the antero-lateral wall of the sinus, which is involved in sinus lift surgery when the lateral approach is carried out, is characterized by the presence of the alveolar antral artery, an intraosseous anastomosis between the dental branch of the posterior superior alveolar artery and the infraorbital artery.¹⁰⁰

Such an intraosseous anastomosis, although radiographically evident in almost 50% of cases,¹⁰⁰⁻¹⁰² courses halfway up the lateral

sinus wall and is reported in the width of the cortical bone of the lateral wall of the maxillary sinus in 100% of cases.^{100,103,104}

The posterior superior alveolar artery and the infraorbital artery form intraosseous and/or extraosseous anastomoses in the lateral wall of the sinus¹⁰³ (Figure 5A).

According to Rosano et al,¹⁰⁵ the alveolar antral artery can display three different patterns: completely intraosseous, partially intraosseous, or extraosseous (under the periosteum of the lateral sinus wall). This pattern depends on the location as well, with the artery commonly found strictly close to the Schneiderian membrane and partially encased in the lateral sinus wall in the molar region.¹⁰⁵ Solar et al¹⁰³ observed the intraosseous anastomosis in all the specimens examined, with a mean distance of 18.9-19.6 mm from the alveolar bone crest. However, there seems to be a high degree of variability in terms of pattern, course, and distance from the alveolar bone margin of the alveolar antral artery. Though confirming the presence of the intraosseous alveolar antral artery in 100% of the anatomic cases, Rosano et al¹⁰⁵ found a mean distance from the vessel to the alveolar ridge of 11.25 mm.

A narrative review by Valente¹⁰⁶ concluded that the intraosseous alveolar antral artery runs 11.25 to 26.90 mm from the alveolar crest (17.91 mm on average), leading the author to recommend the use of computed tomography to assess its exact location prior to the sinus augmentation procedure.

The vessel usually has a small diameter, less than 1 mm, but vessels with diameter greater than 2.5 mm have also been described.¹⁰⁶⁻¹⁰⁸ The diameter of the vessels can significantly affect the amount of bleeding, with a 0.5-1 mm diameter alveolar antral artery accounting for intraoperative bleeding in about 10% of cases, whereas the likelihood of hemorrhage is around 57% when the diameter of the vessel is 1-2 mm, according to Ella et al.¹⁰⁷

Even if the transection of such an artery is not life threatening, because its hemorrhage mostly resolves itself owing to a reactive contraction, impairment in visualization of the Schneiderian membrane may occur, especially when the alveolar antral artery diameter is relevant, making its elevation far more difficult and interfering with placement of the graft material.¹⁰⁵

When a large-diameter alveolar antral artery is running in the designated area of the antrostomy, it has been suggested either to ligate the vessel (Figure 5B-F)¹⁰⁹ or to isolate it by performing a double window antrostomy.¹¹⁰ Piezoelectric surgery can also be used to perform the antrostomy while preserving the integrity of the blood vessel and membrane.⁵⁶ According to Wallace et al,¹⁴ the utilization of piezoelectric surgery rather than rotary diamond burs led to a dramatic reduction in membrane perforation and intraoperative bleeding.

Concerning the analysis of the medial wall of the sinus, it has been shown how the branches from the anterior ethmoidal artery (branch of the ophthalmic artery) as well as the posterior lateral nasal branches of the sphenopalatine artery (branch of the maxillary artery) have an important role in the vascularization of this anatomic region.

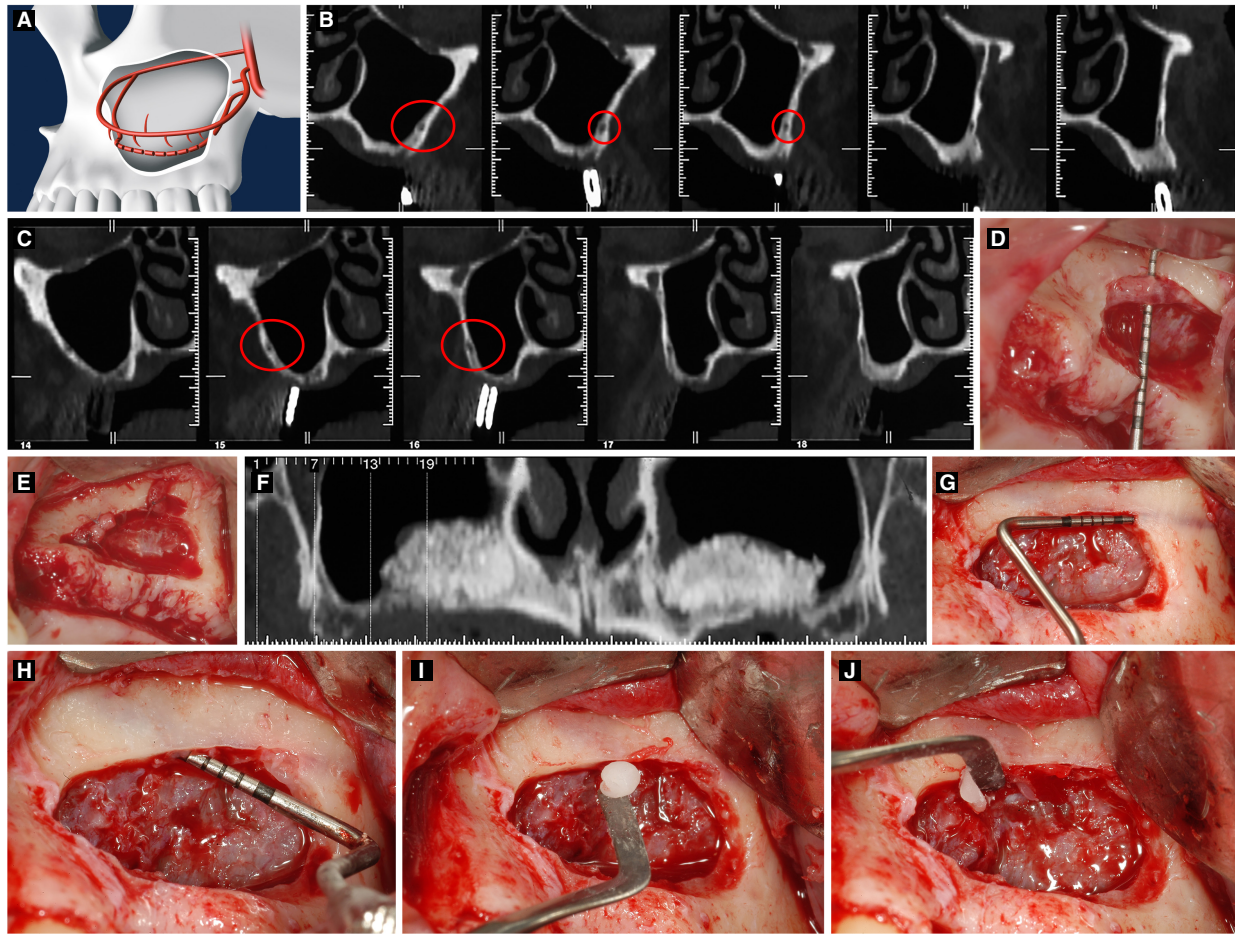


FIGURE 5 A, A vascular system that innervates the maxillary sinus vestibular wall. The infraorbital artery and the posterior superior alveolar artery form an intraosseous anastomosis (dotted line) as present in all cases and an extraosseous anastomosis as present in 40% of cases. (AAPS, posterior superior alveolar artery; AE, extraosseous anastomosis; AI, intraosseous anastomosis; AIO, infraorbital artery; AM, maxillary artery; Courtesy of Testori T. With permission Acme, Viterbo, Italy.) B, C, Preoperative computed tomography scan images. Bony canals (arrows) identified in the right and left lateral antral wall with close proximity to the alveolar ridge (Courtesy of Testori T. With permission Quintessence Publishing Co., Inc. Chicago, USA). D, Detection of the alveolar antral artery during left sinus floor augmentation; measuring nearly 3 mm in diameter (Courtesy of Testori T. With permission Quintessence Publishing Co., Inc. Chicago, USA). E, Alveolar antral artery (arrows) after ligation (Courtesy of Testori T. With permission Quintessence Publishing Co., Inc. Chicago, USA). F, Postoperative computed tomography scan (panoramic view) following bilateral maxillary sinus floor augmentation (Courtesy of Testori T. With permission Quintessence Publishing Co., Inc. Chicago, USA). G, Vessel measured at 0.75 mm in diameter with periodontal probe (Courtesy of Testori T. With permission Acme, Viterbo, Italy). H, Mesial vascular trunk measurements taken with periodontal probe (Courtesy of Testori T. With permission Acme, Viterbo, Italy). I, J, Laceration to the intraosseous anastomosis incurs significant bleeding or hematomas postsurgically following clearance of vasoconstrictive local anesthetics. As such, bone wax can be locally applied to support hemostatic events. (Courtesy of Testori T. With permission Acme, Viterbo, Italy)

Small branches deriving from the posterior lateral nasal arteries have been found to perforate the nasal wall laterally and reach the mucosa of the maxillary sinus.¹⁰⁰ This fact presents the potential for a bleeding complication during a lateral approach to sinus elevation surgery.

5.2.2 | Management of intraoperative bleeding

In the case of excessive intraoperative hemorrhage, it has been suggested to apply direct pressure with a gauze and use a localized vasoconstrictor first. If the bleeding persists and the vessel is intraosseous, then other strategies include the use of bone wax

(Figure 5G-J), crushing the bone channel around the vessel with a hemostat, or electrocauterization.

5.3 | Other intraoperative complications

Other intraoperative complications include tears in the buccal flap and injury to the infraorbital nerve. Injury of the infraorbital neurovascular bundle has been reported occasionally.⁴ This can be due to full-thickness vertical releasing incisions in the premolar area, pressure on the nerve during flap retraction, or sharp dissection during flap releasing.⁷

6 | EARLY POSTOPERATIVE COMPLICATIONS

6.1 | Incidence of early postoperative complications

Early postoperative complications include those that may occur within the first 21 days after sinus augmentation procedures.¹¹¹ Edema, ecchymosis, discomfort, epistaxis, bleeding from the surgical area, and mild congestion are common events that can be considered within normal limits following sinus floor elevation. Major early complications are relatively uncommon and include sinus infection, graft infection, postoperative sinusitis, sinus obliteration, profuse epistaxis, flap dehiscence or necrosis, oroantral communication, loss of graft material, and implant migration into the sinus.

6.2 | Types of postoperative complications

6.2.1 | Sinus or graft infection

According to Testori et al,⁷ postoperative sinus infection is more likely to be due to the infection of the graft rather than a true sinus infection. This complication may be caused by exacerbation of a previously existing asymptomatic and chronic condition or can be due to bacterial contamination.⁷ Seasonal allergy and endodontic or periodontal problems can lead to inflammatory changes that block the osteomeatal complex, with increased risk of acute sinusitis following sinus augmentation. Other etiologic factors for postoperative sinus graft infection include preoperative sinusitis, graft contamination during the surgery or due to membrane perforation, graft migration into the sinus cavity, or blockage of sinus drainage after membrane elevation due to the presence of a mucous retention cyst or excessively thickened sinus membrane.^{7,94,98,112,113} Identifying these contributing factors and treating them accordingly before sinus floor elevation is crucial for reducing the risk for complications.⁷ Membrane perforation has also been associated with increased incidence of postoperative sinusitis,^{41,88,98} although other studies did not confirm this correlation.^{54,80,114}

A systematic review by Pjetursson et al⁴ reported the relatively low incidence of grafted sinus infection (0%-7.4%), which is usually seen between the third and seventh days postoperatively. In particular, the risk for infection seemed to be increased in the case of membrane perforation.⁴ This finding was confirmed by other studies,^{41,88,99} with Nolan et al⁸⁸ reporting that membrane perforation occurred in 85% of the sinuses that developed postoperative infection. Nevertheless, others did not observe a different incidence of postoperative sinus infection for perforated versus nonperforated membranes.^{38,54} Postoperative sinus infection was found to lead to graft failure in a retrospective study by Testori et al.¹⁵

On the other hand, sinus graft infections are probably the most common form of infection following sinus augmentation, with an estimated incidence of 2%-5%. Commonly observed symptoms include

local tenderness, nasal obstruction, pain, swelling, fistula formation, flap dehiscence, and suppuration foul smell and taste. These symptoms may occur within the first 2 weeks or also after a few months. The radiographic appearance of a "black hole" in the central portion of the graft is usually indicative of graft infection.

6.2.2 | Obliteration of the sinus drainage pathway

Although sinus obliteration is a rare complication, the blockage of sinus drainage through the ostium following the elevation of the membrane can occur in the presence of a mucous retention cyst. Mucous retention cysts do not represent an absolute contraindication for sinus floor elevation, as small cysts can be drained during the surgery. Nevertheless, large cysts may need to be treated prior to sinus floor elevation by an otorhinolaryngologist.^{7,115} A cyst occupying two-thirds of the total volume of the sinus is likely to block the drainage of the sinus if the membrane is elevated.⁷ Testori et al¹¹⁶ suggested that aspiration of mucous retention cysts can be performed at the time of the sinus floor augmentation, without a negative effect on the incidence of intra- or postoperative complications. Most of the patients showed radiographic disappearance of the lesions after a mean follow-up of 5 years, but an asymptomatic residual antral cyst of reduced dimensions was observed in three patients. The authors concluded that the cumulative implant survival rate (96.8%) was not affected by the presence (and intrasurgical draining) of mucous retention cysts.¹¹⁶ Another study showed a reoccurrence of the cyst in 3% of the patients following endoscopic cyst removal.¹¹⁷

6.2.3 | Other postoperative complications

Alayan and Ivanovski⁹⁴ focused on complications and patient-reported outcomes following sinus augmentation with different bone graft materials. No major complications were observed within the first 2 weeks postoperatively, with few patients experiencing wound dehiscence, bruising, and edema. Only one patient out of 60 reported symptoms consistent with postoperative sinusitis, such as nasal congestion, postnasal drip, and facial pressure. Another patient reported an isolated minor incident of epistaxis after the first 24 hours.⁹⁴ Mild to moderate pain with interference to daily activities for 48-72 hours was reported and required the use of painkiller medications. Limitation to work and social life was observed on the first day, with minimal limitation after the second day.⁹⁴

Risk for developing wound dehiscence was found to be significantly increased in smokers in other studies,^{41,118} with an odds ratio of 16 according to Schwarz et al.⁴¹ Ritter et al¹¹⁹ investigated the association between preoperative maxillary sinus imaging findings and sinus lift outcomes in asymptomatic patients, showing that postoperative complications did not correlate with radiologic findings. They concluded that abnormal preoperative findings did not confer an increased risk for complications.

6.3 | Management of early postoperative infection

A consensus of experts in different fields, including periodontists, implantologists, maxillofacial surgeons, otorhinolaryngologists, and microbiology specialists, provided guidelines for the treatment of postoperative complications.¹¹¹ If persistence of signs and symptoms of infection beyond 3 weeks is noted, a computed tomography should be taken or sinus endoscopy completed to evaluate the maxillary sinuses. Graft infection can be seen in the computed tomographic scan as a contained lesion under the sinus membrane, accompanied by clinical signs of serum exudate from the surgical incision.¹¹¹ This complication can be managed with pharmacologic treatment orally administered, including 1 g amoxicillin/clavulanic acid three times a day and 500 mg metronidazole three times a day or levofloxacin 400 mg twice a day for 7-10 days. If the symptoms (tenderness, nasal obstruction, pain, purulent discharge from the nose, suppuration, etc) persist beyond 3 weeks, regardless of the pharmacologic therapy, a surgical approach with partial (Figure 6A-K) or total removal (Figure 7A-I) of the bone graft is recommended. In clinical scenarios where the graft is not contained under the sinus membrane with particles dislocated inside the sinus, a multidisciplinary approach is mandatory to manage this complication; usually, a functional endoscopic sinus surgery is performed without/with a simultaneous intra-oral approach¹¹¹ (Figure 8A,B). Clinical guidelines for treating graft infection, sinus infection, and postoperative sinusitis have been summarized by Testori et al¹¹¹ with an algorithm (Figure 9).

7 | LATE POSTOPERATIVE COMPLICATIONS

Late/delayed complications occur, by definition, at least 21 days after the sinus lift augmentation.¹¹¹ They include late infection, sinus obliteration, lack of graft integration, lack of implant osseointegration, and graft/implant migration into the sinus. These complications have been reported sporadically in the literature, and usually as case reports.

Though a lack of implant osseointegration is more likely due to an error that occurred as a result of the surgery (ie, inability to achieve primary stability and/or insufficient residual alveolar ridge dimension), it can also occur as a complication of maxillary sinus floor elevation. Two cases of implant failure with the formation of an oroantral fistula have been described.¹¹⁹ A case of sinus obliteration due to maxillary sinus overpacking has also been reported, with the patient experiencing frequent headaches, congestions, and yellow discharge from the nose from a previous sinus lift performed 1 year previously.¹²⁰ Multiple episodes of fever had also been reported. The computed tomographic scan revealed that the bone graft material occupied approximately 80% of the sinus and was just below the ostium, with possible impairing of the normal fluid movement in the maxillary sinus.¹²⁰

Although the exact cause is not clear, three conditions must be present for implant migration into the sinus: lack of implant

osseointegration, membrane perforation, and a force pushing the implant toward the sinus.¹¹⁵ This complication was more common when cylindrical implants were used in the posterior maxilla, whereas today it is most likely related to the attempt of placing implants simultaneously with sinus augmentation in presence of 1-3 mm of remaining crestal bone, which may increase the risk of implant migration into the sinus.⁷ This complication can be completely asymptomatic or associated with reactive sinusitis and/or with oroantral communication.^{121,122} The implant can be removed with an intra-oral approach (modified Caldwell-Luc procedure), functional endoscopic sinus surgery, or a combination of these two techniques.^{115,121,123} In a retrospective study, Chiapasco et al¹²¹ reported that most of the patients treated with these approaches completely recovered, with only one patient that needed a reintervention due to persistent signs and symptoms of sinusitis and oroantral communication.

When possible, the intra-oral approach is recommended, as it does not alter the intranasal anatomy, since the uncinate process is not removed and the natural ostium is not enlarged. Importantly, following functional endoscopic sinus surgery, some patients complained that water enters the sinus during activities such as swimming or jumping in the water without closing the nostrils. This complication is due to modifications/removal of the uncinate process, which naturally prevents water from entering in the maxillary sinus.

Lastly, implant intrusion into the maxillary sinus perforating the sinus membrane has been associated with sinusitis, nasal bleeding, nasal obstruction, mucopurulent drainage, headache, tenderness, and decreased sense of smell.¹²⁴⁻¹²⁸ The level of implant penetration inside the sinus cavity seems not to affect the incidence of complications.¹²⁴ Nevertheless, it has to be appreciated that these data come from retrospective studies, making any conclusions regarding correlation between implant intrusion into the sinus and increased risk of postoperative complications difficult to assess with accuracy. Recently, an international and multidisciplinary consensus utilizing the Delphi method on the clinical management of implant protrusion into the maxillary sinuses and nasal fossae has been published.¹²⁹ A total of 31 experts participated, of whom 23 were experts in implantology (periodontologists, maxillofacial surgeons, and implantologists), six were otolaryngologists, and two were radiologists. The conclusions of the studies were that osseointegrated implants that are shown to be protruding into the maxillary sinus or nasal fossae on radiographs require monitoring and maintenance as much as implants that are covered fully by bone. In the event of symptoms of sinusitis, collaboration between implant providers and otolaryngologists is recommended. Implant removal should be considered only if pharmacologic and/or surgical treatment of sinusitis fails.

8 | FACTORS AFFECTING IMPLANT LONG-TERM SURVIVAL RATE IN AUGMENTED SINUS

The longevity of outcomes after any procedure is a crucial aspect relative to patient care that has been widely investigated in the periodontal literature.^{5,130-135} Particularly with regard to maxillary sinus

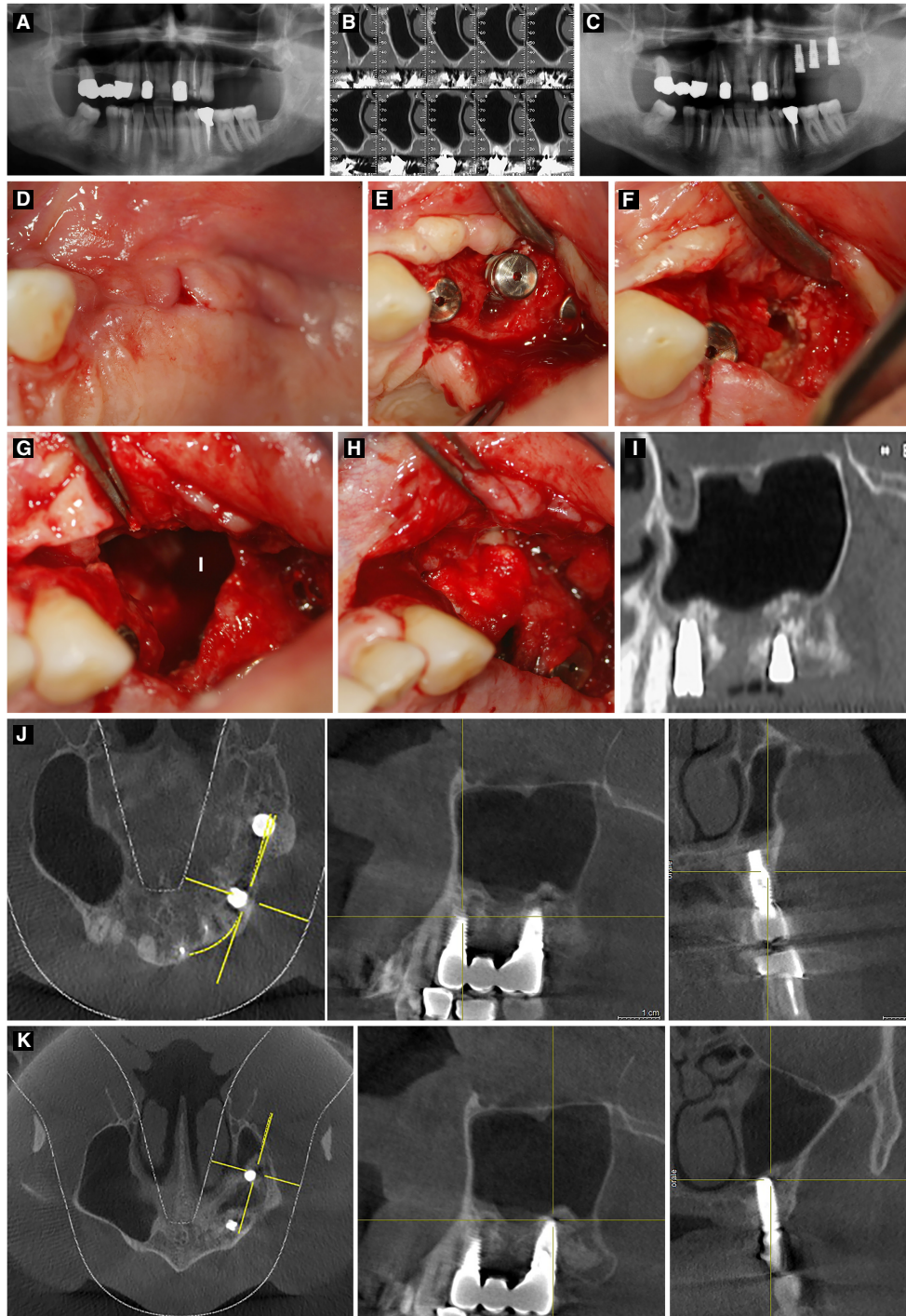


FIGURE 6 A, Preoperative panorex. B, Preoperative cone beam computed tomography depicting no significant anatomic findings; a healthy sinus. C, Immediate postoperative panorex. The surgery was carried out without any intraoperative complication. D, Week 2 postoperatively: Oroantral communication clinically noted, and patient was prescribed an additional round (7 days) of antibiotic therapy. E-H, Week 3 postoperatively: No clinical resolution observed, so partial graft and implant removal was completed via an intraoral approach with patient discussion and consent. Detailed clinical procedure follows. E, Original flap was elevated. Then, F, removal of the implant and, G, removal of loose graft particles was completed under copious saline irrigation. H, Subsequently, curettes were used to position viable graft and collagen sponge adjacent the antrostomy, followed by primary flap closure. I, Immediate postoperative cone beam computed tomography. J, The 11-year follow-up cone beam computed tomography at the level of the mesial implant. K, The 11-year follow-up cone beam computed tomography at the level of the distal implant

augmentation, a large body of evidence demonstrates the efficacy of this approach with simultaneous or delayed implant placement.^{4,5,136} A systematic review by Del Fabbro et al⁵ found that the type of bone

graft used for the sinus augmentation procedures affected the long-term implant survival rate, with 100% bone substitute and block graft+particulate showing the highest survival rate (96.25% and

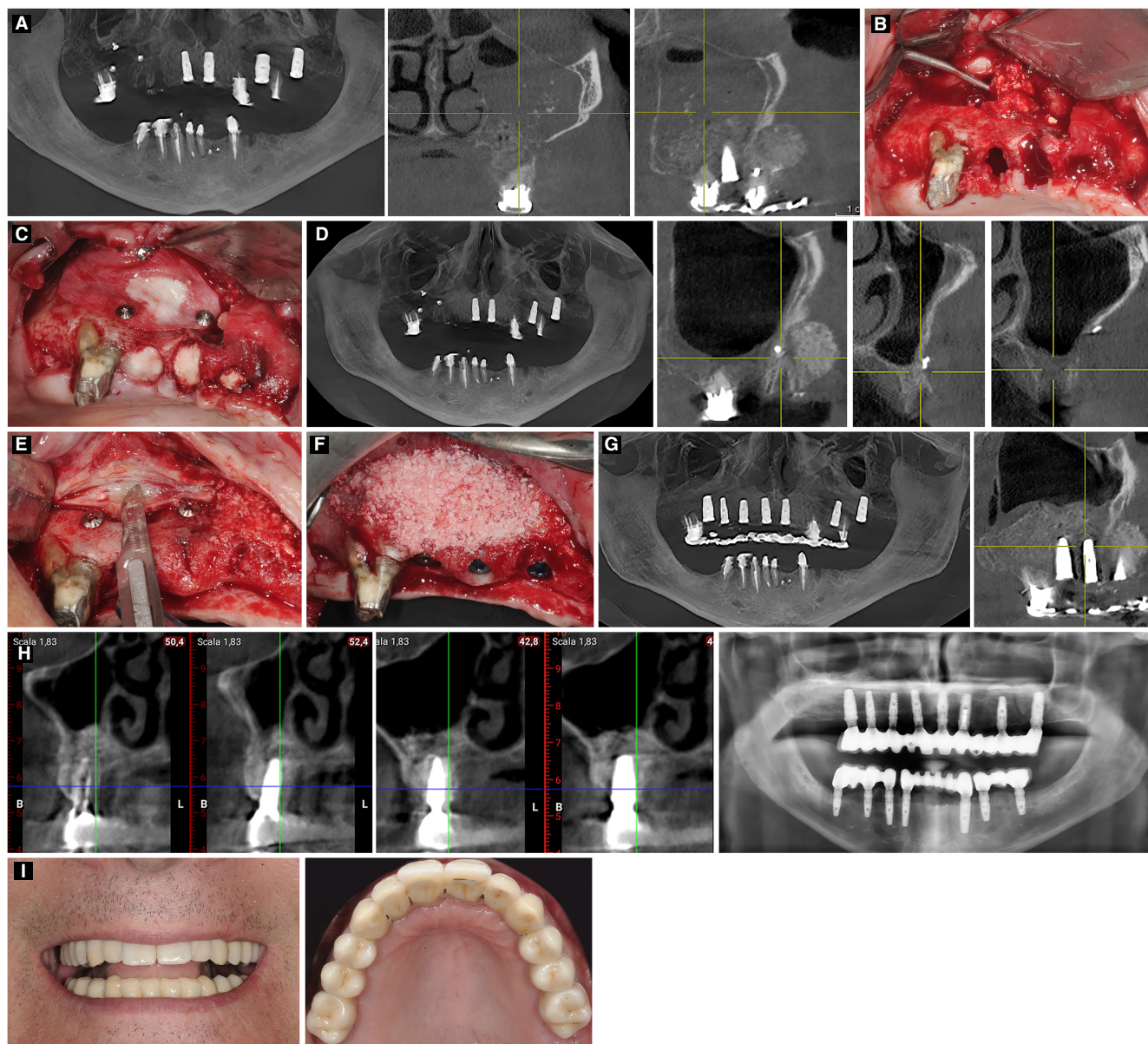


FIGURE 7 A, Patient referred to our institution to address a persistent infection at 3 weeks post-sinus elevation. A second regimen of antibiotics was immediately administered (500 mg levofloxacin twice a day for 7 days) without resolution of the symptoms. Cone beam computed tomography examination revealed a sinus radiopacity with graft particles that seem dispersed into the sinus cavity. Detailed clinical procedure follows. B, A full thickness flap was reflected; the implant and hopeless tooth (strategically kept to anchor a metal-reinforced prosthesis) were removed along with the graft particulate. C, After complete graft removal, a collagen membrane was fixed to the buccal bony wall followed by primary flap closure. D, The 2 months postoperative cone beam computed tomography delineates normal sinus mucous membrane anatomy but identifies a fenestration at the level of the antrostomy. E, At 2 months postoperatively, a split-thickness flap is performed. F, A second sinus elevation is performed, and three additional implants are positioned. G, Immediate postoperative cone beam computed tomography shows a cemented provisional prosthesis supported by three natural abutments that will be replaced after graft consolidation and implant osseointegration. H, The 5-year follow-up. Clinical photographs of the final prosthesis. I, The 5-year follow-up. Panorex of the final prosthesis

98.85%, respectively). The survival rate for implants placed during sinus floor augmentation and in a two-stage procedure was 95.95% and 93.94%, respectively. Interestingly, 80% of the implant failure occurred within the first year of loading, with the risk of implant failure after 3 years of function that was estimated to be 0.43%.⁵ In addition, studies published from 1997 to 2002 obtained a significantly lower implant survival rate than later studies (85.66% versus 96.21%),⁵ suggesting a progressive and substantial improvement

in sinus knowledge, complications management, and surgical techniques and the use of rough implant surfaces over the last decades.

A systematic review and meta-analysis confirmed the high survival rate (97.7%) of implants placed in augmented sinus with a follow-up up to 6 years. Smoking habit was found to potentially play a negative role on implant survival rate.¹³⁷ In line with this result, a retrospective study found an odds ratio of 8.3 for implant failure in smoking patients.¹³⁸ Nevertheless, a review from Chambrone et al¹³⁹

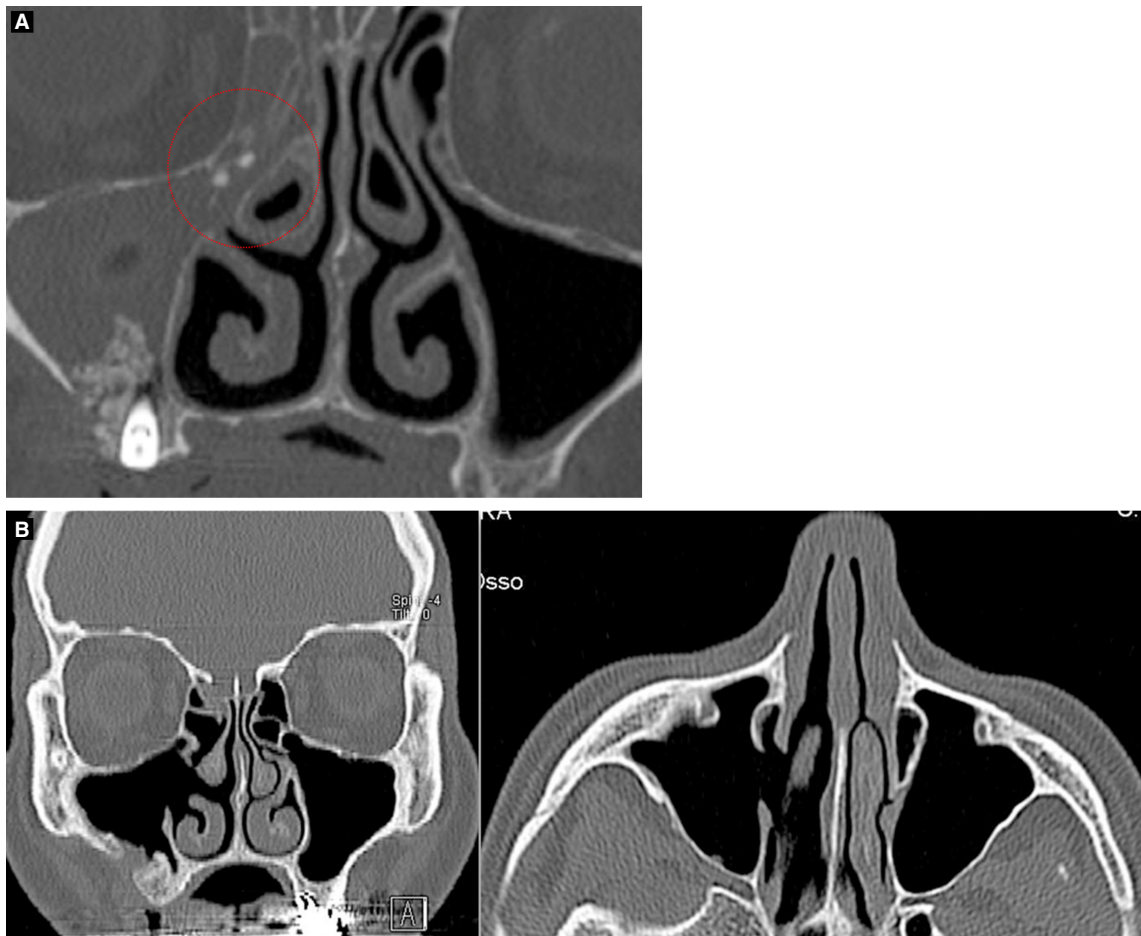


FIGURE 8 A, Cone beam computed tomography depicts graft material migration to the ostium. Clinical exam reveals localized tenderness, edema/swelling, fistula formation, and foul odor/taste. B, Cone beam computed tomography delineates normal/healthy sinus anatomy following functional endoscopic sinus surgery

concluded that though smoking was associated with implant failure in most of the studies included, its detrimental effect was not confirmed when only prospective data were evaluated.

Comparing dental implants placed in augmented versus nonaugmented sinus sites, a 10-year study reported no difference between marginal bone levels.¹⁴⁰

9 | TECHNICAL ERRORS

9.1 | Improper location of the antrostomy

It has been our experience that clinicians new to sinus elevation tend to make the antrostomy in a less than ideal location. Specifically, the antrostomy is made too far superior and too far toward the distal. This most likely results from concerns about inadvertently making the window either anterior to the sinus or below the sinus floor, thereby damaging adjacent roots, devitalizing teeth, or unnecessarily removing useful bone. As the anterior extension of the sinus is generally narrow, concomitant with increased perforation rates, antrostomy windows should be extended to the mesial wall of the sinus floor to reduce the

perforation rate, since the surgeons are not working in a blind area that is created when 3mm of bone distal to the mesial wall is not removed.

This design is called simplified antrostomy design.¹⁴¹ This technique is indicated in fully edentulous and in partially edentulous patients missing premolars and molars in which the sinus does not extend beyond the cuspid root.

The simplified antrostomy design technique is accomplished in a three-step procedure:

1. Measurements are taken on a cone beam computed tomography for opening a small window (3mm wide by 6mm long) just distal to the anterior sinus wall.
2. The window is extended in the anterior (mesial) direction to locate the anterior sinus wall.
3. The antrostomy is enlarged distally as required by the internal anatomy (septa) and the number of implants to be placed, roughly 15-20mm in the anteroposterior direction, and 3mm of bone is left apically to sinus floor.

The simplified antrostomy design technique has two major benefits:

1. To provide the ideal antrostomy location for preventing membrane perforations that mainly occur in narrow mesial recesses by providing the best visual and tactile access for membrane detachment.
2. To guarantee that the anterior sinus compartment could be efficiently and fully grafted.

9.1.1 | Low window

The low window antrostomy design is a further modification of the simplified antrostomy design technique.¹⁴¹ The window is placed as low and mesially as possible. The lower osteotomy line is placed flush

with the sinus floor, and the mesial line is always flush with the sinus anterior wall; like in the simplified antrostomy design technique, the window is usually 6-8mm in height that allows one, in most cases, to avoid any intraosseous anastomosis. The distal osteotomy is positioned to correspond to the most distally planned implant. The position of this osteotomy design provides specific surgical advantages. Placement of the lower horizontal osteotomy flush with the sinus floor eliminates any residual bone wall that could hinder detachment of the sinus membrane, and there are no more “blind spots.” The position of the distal osteotomy line is optimized according to the position of the most distal implant, typically 15-20mm in the mesiodistal direction.

Using dedicated software, sinus surgical guides for the antrostomy can be fabricated to help the clinician to easily locate the

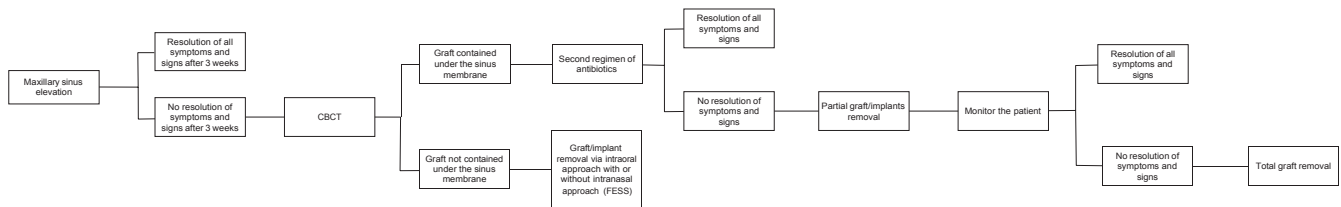


FIGURE 9 Algorithm for treatment of sinus graft infections, sinus infections, and postoperative sinusitis. CBCT, cone-beam computed tomography; FESS, functional endoscopic sinus surgery. (Reprint *Periodontology 2000* Testori et al)

TABLE 9 Clinical recommendations for the management of intra- and postoperative complications

| Problem | Solutions |
|---|--|
| Lack of proper access | <ul style="list-style-type: none"> • Wider flap • Better flap retraction (training of the auxiliary staff) |
| Wrong location of the antrostomy | <ul style="list-style-type: none"> • Preoperative three-dimensional evaluation • Computed guided antrostomy with the use of surgical stents |
| Membrane perforation during the preparation of the antrostomy | <ul style="list-style-type: none"> • Preoperative evaluation of the thickness of the lateral cortical wall of the sinus • Use of efficient (sharp) diamond bur of proper size • Use of efficient (sharp) diamond piezoelectric inserts |
| Membrane perforation during the membrane elevation | <ul style="list-style-type: none"> • Use of a piezoelectric detacher with proper settings • Use of a sharp dedicated detachers (elevators) • Do not lose contact between the detachers and the bone during membrane elevation |
| Membrane perforation during implant site preparation | <ul style="list-style-type: none"> • Protect the sinus membrane with collagen sponges • Protect the sinus membrane with Prichard elevator • Be very careful during drilling phase |
| Lack of implant primary stability | <ul style="list-style-type: none"> • Do not place implant in the same surgical phase if the residual bone height is less than 3mm • Remove the implant and place a new implant at graft integration |
| Excessive bleeding | <ul style="list-style-type: none"> • Careful evaluation of the medical history • Preoperative evaluation of the location of the alveolo-antral artery • Use of bone wax if intrabony bleeding • Use of diathermy if extrabony bleeding |
| Early postoperative infection | <ul style="list-style-type: none"> • Careful preoperative evaluation of maxillary sinus physiologic health • Surgical sterile setting • Proper handling of biomaterials • Proper antibiotic therapy |
| Dehiscence of the wound | <ul style="list-style-type: none"> • Proper flap releasing • Tension-free suture |
| Late postoperative graft infection | <ul style="list-style-type: none"> • Antibiotic therapy • Graft removal |
| Late postoperative sinus infection | <ul style="list-style-type: none"> • Antibiotic therapy • Ear, nose, and throat evaluation |

anatomic reference points, like the sinus floor and mesial wall, to open a correct antrostomy.¹⁴²

9.2 | Maxillary sinus overfilling

Maxillary sinus overfilling could lead to a technical error when a maxillary sinus cyst is present.

The presence of mucous retention cysts is easily detected in the presurgical radiographic work-up. These are benign lesions that are generally asymptomatic. They are radiopaque and of various sizes, typically originating from the sinus floor. They can be distinguished from polyps, which tend to be pedunculated and arise from the sinus walls. Cysts are usually filled with a yellow serous fluid, which is pathognomonic for this lesion. Normally, mucous retention cysts of the maxillary sinus do not impair mucociliary clearance and sinus drainage. However, when the sinus membrane is elevated when performing maxillary sinus elevation, the elevated cyst could impact on the natural ostium, blocking the mucosal drainage and possibly causing inflammatory or infective conditions. If the cyst is deflated before membrane elevation, the sinus floor can be elevated safely.¹¹⁶

10 | CONCLUSIONS

The maxillary sinus elevation procedure using a lateral window approach has been shown to be the most successful bone augmentation procedure that is performed as a preprosthetic procedure prior to implant placement. The high success rate of lateral window sinus floor augmentation procedures (assessed at both biological levels and patient-reported levels) is attributed to minimal complications. Moreover, these minimal complications can be further reduced through the use of specific checklists, knowledge of the possible adverse events, and attention to the clinical recommendations listed in Table 9. With all these tools in our surgical toolbox and the mindfulness of the biological/physiologic/psychologic context surrounding technical approach, we have no doubt the care of our patients with limited posterior alveolar ridge dimensions will exponentially rise.

ACKNOWLEDGMENTS

We would like to thank Dr Erika Benavides, Department of Periodontics and Oral Medicine, University of Michigan, USA, Dr Fabiana Soki, Department of Periodontics and Oral Medicine, University of Michigan, USA, and Dr Juan Carlos Rodriguez, Department of Periodontics and Oral Medicine, University of Michigan, USA, for their valuable contribution to this manuscript for providing clinical cases. Open access funding provided by BIBLIOSAN.

FUNDING INFORMATION

The study was self-supported.

CONFLICT OF INTEREST

The authors declare they have no relevant or material financial interests that relate to the research described in this paper.

DATA AVAILABILITY STATEMENT

Data sharing not applicable—no new data generated.

ORCID

Tiziano Testori  <https://orcid.org/0000-0001-7901-8120>

Lorenzo Tavelli  <https://orcid.org/0000-0003-4864-3964>

Riccardo Scaini  <https://orcid.org/0000-0001-9040-9456>

Shayan Barootchi  <https://orcid.org/0000-0002-5347-6577>

Matteo Antonio Deflorian  <https://orcid.org/0000-0002-0863-4839>

REFERENCES

1. Aghaloo TL, Moy PK. Which hard tissue augmentation techniques are the most successful in furnishing bony support for implant placement? *Int J Oral Maxillofac Implants*. 2007;22:49-70.
2. Wallace SS, Froum SJ. Effect of maxillary sinus augmentation on the survival of endosseous dental implants. A systematic review. *Ann Periodontol*. 2003;8:328-343.
3. Del Fabbro M, Testori T, Francetti L, Weinstein R. Systematic review of survival rates for implants placed in the grafted maxillary sinus. *Int J Periodontics Restorative Dent*. 2004;24:565-577.
4. Pjetursson BE, Tan WC, Zwahlen M, Lang NP. A systematic review of the success of sinus floor elevation and survival of implants inserted in combination with sinus floor elevation. *J Clin Periodontol*. 2008;35:216-240.
5. Del Fabbro M, Wallace SS, Testori T. Long-term implant survival in the grafted maxillary sinus: a systematic review. *Int J Periodontics Restorative Dent*. 2013;33:773-783.
6. Barootchi S, Askar H, Ravida A, Gargallo-Albiol J, Travan S, Wang HL. Long-term clinical outcomes and cost-effectiveness of full-arch implant-supported zirconia-based and metal-acrylic fixed dental prostheses: a retrospective analysis. *Int J Oral Maxillofac Implants*. 2020;35:395-405.
7. Testori T, Weinstein T, Taschieri S, Wallace SS. Risk factors in lateral window sinus elevation surgery. *Periodontol 2000*. 2019;81:91-123.
8. Zijderveld SA, van den Bergh JP, Schulten EA, ten Bruggenkate CM. Anatomical and surgical findings and complications in 100 consecutive maxillary sinus floor elevation procedures. *J Oral Maxillofac Surg*. 2008;66:1426-1438.
9. Renouard F, Amalberti R, Renouard E. Are "human factors" the primary cause of complications in the field of implant dentistry? *Int J Oral Maxillofac Implants*. 2017;32:e55-e61.
10. Gillespie BM, Chaboyer W, Thalib L, John M, Fairweather N, Slater K. Effect of using a safety checklist on patient complications after surgery: a systematic review and meta-analysis. *Anesthesiology*. 2014;120:1380-1389.
11. Timmenga NM, Raghoobar GM, Liem RS, van Weissenbruch R, Manson WL, Vissink A. Effects of maxillary sinus floor elevation surgery on maxillary sinus physiology. *Eur J Oral Sci*. 2003;111:189-197.
12. Torretta S, Mantovani M, Testori T, Cappadona M, Pignataro L. Importance of ENT assessment in stratifying candidates for sinus floor elevation: a prospective clinical study. *Clin Oral Implants Res*. 2013;24:57-62.
13. Harris D, Horner K, Grondahl K, et al. E.A.O. guidelines for the use of diagnostic imaging in implant dentistry 2011. A consensus workshop organized by the European Association for

- Osseointegration at the Medical University of Warsaw. *Clin Oral Implants Res.* 2012;23:1243-1253.
14. Wallace SS, Tarnow DP, Froum SJ, et al. Maxillary sinus elevation by lateral window approach: evolution of technology and technique. *J Evid Based Dent Pract.* 2012;12:161-171.
 15. Testori T, Weinstein RL, Taschieri S, Del Fabbro M. Risk factor analysis following maxillary sinus augmentation: a retrospective multicenter study. *Int J Oral Maxillofac Implants.* 2012;27:1170-1176.
 16. Fokkens WJ, Lund VJ, Mullol J, et al. EPOS 2012: European position paper on rhinosinusitis and nasal polyps 2012. A summary for otorhinolaryngologists. *Rhinology.* 2012;50:1-12.
 17. Pignataro L, Mantovani M, Torretta S, Felisati G, Sambataro G. ENT assessment in the integrated management of candidate for (maxillary) sinus lift. *Acta Otorhinolaryngol Ital.* 2008;28:110-119.
 18. Foreman A, Psaltis AJ, Tan LW, Wormald PJ. Characterization of bacterial and fungal biofilms in chronic rhinosinusitis. *Am J Rhinol Allergy.* 2009;23:556-561.
 19. Tavelli L, Borgonovo AE, Re D, Maiorana C. Sinus presurgical evaluation: a literature review and a new classification proposal. *Minerva Stomatol.* 2017;66:115-131.
 20. Zimmo N, Insua A, Sinjab K, Chan HL, Shaikh L, Wang HL. Impact of sex, age, and season on sinus membrane thickness. *Int J Oral Maxillofac Implants.* 2018;33:175-180.
 21. Insua A, Monje-Gil F, Garcia-Caballero L, Caballe-Serrano J, Wang HL, Monje A. Mechanical characteristics of the maxillary sinus Schneiderian membrane ex vivo. *Clin Oral Investig.* 2018;22:1139-1145.
 22. Insua A, Monje A, Chan HL, Wang HL. Association of inflammatory status and maxillary sinus Schneiderian membrane thickness. *Clin Oral Investig.* 2018;22:245-254.
 23. Pommer B, Ulm C, Lorenzoni M, Palmer R, Watzek G, Zechner W. Prevalence, location and morphology of maxillary sinus septa: systematic review and meta-analysis. *J Clin Periodontol.* 2012;39:769-773.
 24. Gargallo-Albiol J, Sinjab KH, Barootchi S, Chan HL, Wang HL. Microscope and micro-camera assessment of Schneiderian membrane perforation via transcrestal sinus floor elevation: a randomized ex vivo study. *Clin Oral Implants Res.* 2019;30:682-690.
 25. Srouji S, Kizhner T, Ben David D, Riminucci M, Bianco P, Livne E. The Schneiderian membrane contains osteoprogenitor cells: in vivo and in vitro study. *Calcif Tissue Int.* 2009;84:138-145.
 26. Srouji S, Ben-David D, Lotan R, Riminucci M, Livne E, Bianco P. The innate osteogenic potential of the maxillary sinus (Schneiderian) membrane: an ectopic tissue transplant model simulating sinus lifting. *Int J Oral Maxillofac Surg.* 2010;39:793-801.
 27. Insua A, Monje A, Chan HL, Zimmo N, Shaikh L, Wang HL. Accuracy of Schneiderian membrane thickness: a cone-beam computed tomography analysis with histological validation. *Clin Oral Implants Res.* 2017;28:654-661.
 28. Al-Dajani M. Incidence, risk factors, and complications of Schneiderian membrane perforation in sinus lift surgery: a meta-analysis. *Implant Dent.* 2016;25:409-415.
 29. Testori T, Tavelli L, Yu SH, et al. Maxillary sinus elevation difficulty score with lateral wall technique. *Int J Oral Maxillofac Implants.* 2020;35:631-638.
 30. Testori T, Yu SH, Tavelli L, Wang HL. Perforation risk assessment in maxillary sinus augmentation with lateral wall technique. *Int J Periodontics Restorative Dent.* 2020;40:373-380.
 31. Pommer B, Unger E, Suto D, Hack N, Watzek G. Mechanical properties of the Schneiderian membrane in vitro. *Clin Oral Implants Res.* 2009;20:633-637.
 32. Monje A, Diaz KT, Aranda L, Insua A, Garcia-Nogales A, Wang HL. Schneiderian membrane thickness and clinical implications for sinus augmentation: a systematic review and meta-regression analyses. *J Periodontol.* 2016;87:888-899.
 33. Barootchi S, Chan HL, Namazi SS, Wang HL, Kripfgans OD. Ultrasonographic characterization of lingual structures pertinent to oral, periodontal, and implant surgery. *Clin Oral Implants Res.* 2020;31:352-359.
 34. Lim HC, Nam JY, Cha JK, et al. Retrospective analysis of sinus membrane thickening: profile, causal factors, and its influence on complications. *Implant Dent.* 2017;26:868-874.
 35. Lum AG, Ogata Y, Pagni SE, Hur Y. Association between sinus membrane thickness and membrane perforation in lateral window sinus augmentation: a retrospective study. *J Periodontol.* 2017;88:543-549.
 36. Marin S, Kirnbauer B, Rugani P, Payer M, Jakse N. Potential risk factors for maxillary sinus membrane perforation and treatment outcome analysis. *Clin Implant Dent Relat Res.* 2019;21:66-72.
 37. Yilmaz HG, Tozum TF. Are gingival phenotype, residual ridge height, and membrane thickness critical for the perforation of maxillary sinus? *J Periodontol.* 2012;83:420-425.
 38. Park WB, Han JY, Kang P, Momen-Heravi F. The clinical and radiographic outcomes of Schneiderian membrane perforation without repair in sinus elevation surgery. *Clin Implant Dent Relat Res.* 2019;21:931-937.
 39. Ardekian L, Oved-Peleg E, Mactei EE, Peled M. The clinical significance of sinus membrane perforation during augmentation of the maxillary sinus. *J Oral Maxillofac Surg.* 2006;64:277-282.
 40. Monje A, Monje-Gil F, Burgueno M, Gonzalez-Garcia R, Galindo-Moreno P, Wang HL. Incidence of and factors associated with sinus membrane perforation during maxillary sinus augmentation using the reamer drilling approach: a double-center case series. *Int J Periodontics Restorative Dent.* 2016;36:549-556.
 41. Schwarz L, Schiebel V, Hof M, Ulm C, Watzek G, Pommer B. Risk factors of membrane perforation and postoperative complications in sinus floor elevation surgery: review of 407 augmentation procedures. *J Oral Maxillofac Surg.* 2015;73:1275-1282.
 42. von Arx T, Fodich I, Bornstein MM, Jensen SS. Perforation of the sinus membrane during sinus floor elevation: a retrospective study of frequency and possible risk factors. *Int J Oral Maxillofac Implants.* 2014;29:718-726.
 43. Rak KM, Newell JD 2nd, Yakes WF, Damiano MA, Luethke JM. Paranasal sinuses on MR images of the brain: significance of mucosal thickening. *AJR Am J Roentgenol.* 1991;156:381-384.
 44. Shanbhag S, Karnik P, Shirke P, Shanbhag V. Cone-beam computed tomographic analysis of sinus membrane thickness, ostium patency, and residual ridge heights in the posterior maxilla: implications for sinus floor elevation. *Clin Oral Implants Res.* 2014;25:755-760.
 45. Carmeli G, Artzi Z, Kozlovsky A, Segev Y, Landsberg R. Antral computerized tomography pre-operative evaluation: relationship between mucosal thickening and maxillary sinus function. *Clin Oral Implants Res.* 2011;22:78-82.
 46. Underwood AS. An inquiry into the anatomy and pathology of the maxillary sinus. *J Anat Physiol.* 1910;44:354-369.
 47. Krennmaier G, Ulm C, Lugmayr H. Maxillary sinus septa: incidence, morphology and clinical implications. *J Craniomaxillofac Surg.* 1997;25:261-265.
 48. Velasquez-Plata D, Hovey LR, Peach CC, Alder ME. Maxillary sinus septa: a 3-dimensional computerized tomographic scan analysis. *Int J Oral Maxillofac Implants.* 2002;17:854-860.
 49. Rosano G, Taschieri S, Gaudy JF, Lesmes D, Del Fabbro M. Maxillary sinus septa: a cadaveric study. *J Oral Maxillofac Surg.* 2010;68:1360-1364.
 50. Rancitelli D, Borgonovo AE, Ciccio M, et al. Maxillary sinus septa and anatomic correlation with the Schneiderian membrane. *J Craniofac Surg.* 2015;26:1394-1398.
 51. Wen SC, Chan HL, Wang HL. Classification and management of antral septa for maxillary sinus augmentation. *Int J Periodontics Restorative Dent.* 2013;33:509-517.

52. Okada T, Kawana H. Two-step procedure for the treatment of a maxillary sinus with complex sinus septa: a highly predictive method for sinus floor augmentation after perforation of the maxillary sinus membrane. *Int J Periodontics Restorative Dent*. 2019;39:e175-e180.
53. Cakur B, Sumbullu MA, Durna D. Relationship among Schneiderian membrane, Underwood's septa, and the maxillary sinus inferior border. *Clin Implant Dent Relat Res*. 2013;15:83-87.
54. Tükel HC, Tatli U. Risk factors and clinical outcomes of sinus membrane perforation during lateral window sinus lifting: analysis of 120 patients. *Int J Oral Maxillofac Surg*. 2018;47:1189-1194.
55. Torrella F, Pitarch J, Cabanes G, Anitua E. Ultrasonic ostectomy for the surgical approach of the maxillary sinus: a technical note. *Int J Oral Maxillofac Implants*. 1998;13:697-700.
56. Vercellotti T, De Paoli S, Nevins M. The piezoelectric bony window osteotomy and sinus membrane elevation: introduction of a new technique for simplification of the sinus augmentation procedure. *Int J Periodontics Restorative Dent*. 2001;21:561-567.
57. Stacchi C, Troiano G, Berton F, et al. Piezoelectric bone surgery for lateral sinus floor elevation compared with conventional rotary instruments: a systematic review, meta-analysis and trial sequential analysis. *Int J Oral Implantol*. 2020;13:109-121.
58. Barone A, Santini S, Marconcini S, Giacomelli L, Gherlone E, Covani U. Osteotomy and membrane elevation during the maxillary sinus augmentation procedure. A comparative study: piezoelectric device vs. conventional rotative instruments. *Clin Oral Implants Res*. 2008;19:511-515.
59. Rickert D, Vissink A, Slater JJ, Meijer HJ, Raghoobar GM. Comparison between conventional and piezoelectric surgical tools for maxillary sinus floor elevation. A randomized controlled clinical trial. *Clin Implant Dent Relat Res*. 2013;15:297-302.
60. Delilbasi C, Gurler G. Comparison of piezosurgery and conventional rotative instruments in direct sinus lifting. *Implant Dent*. 2013;22:662-665.
61. Scarano A, Mavriqi L, Bertelli I, Mortellaro C, Di Cerbo A. Occurrence of maxillary sinus membrane perforation following nasal suction technique and ultrasonic approach versus conventional technique with rotary instruments. *J Craniofac Surg*. 2015;26:706-708.
62. Jordi C, Mukaddam K, Lambrecht JT, Kuhl S. Membrane perforation rate in lateral maxillary sinus floor augmentation using conventional rotating instruments and piezoelectric device—a meta-analysis. *Int J Implant Dent*. 2018;4:3.
63. Stacchi C, Andolsek F, Berton F, Perinetti G, Navarra CO, Di Lenarda R. Intraoperative complications during sinus floor elevation with lateral approach: a systematic review. *Int J Oral Maxillofac Implants*. 2017;32:e107-e118.
64. Bayar GR, Yildiz S, Gulsels A, Sencimen M, Acikel CH, Comert A. Correlation between the residual ridge height and the perforation limit of sinus membrane in crestal sinus elevation. *Quintessence Int*. 2013;44:689-697.
65. van den Bergh JP, ten Bruggenkate CM, Disch FJ, Tuinzing DB. Anatomical aspects of sinus floor elevations. *Clin Oral Implants Res*. 2000;11:256-265.
66. Avila-Ortiz G, Neiva R, Galindo-Moreno P, Rudek I, Benavides E, Wang HL. Analysis of the influence of residual alveolar bone height on sinus augmentation outcomes. *Clin Oral Implants Res*. 2012;23:1082-1088.
67. Cho SC, Wallace SS, Froum SJ, Tarnow DP. Influence of anatomy on Schneiderian membrane perforations during sinus elevation surgery: three-dimensional analysis. *Pract Proced Aesthet Dent*. 2001;13:160-163.
68. Velloso GR, Vidigal GM Jr, de Freitas MM, Garcia de Brito OF, Manso MC, Groisman M. Tridimensional analysis of maxillary sinus anatomy related to sinus lift procedure. *Implant Dent*. 2006;15:192-196.
69. Chan HL, Monje A, Suarez F, Benavides E, Wang HL. Palatonasal recess on medial wall of the maxillary sinus and clinical implications for sinus augmentation via lateral window approach. *J Periodontol*. 2013;84:1087-1093.
70. Vlassis JM, Fugazzotto PA. A classification system for sinus membrane perforations during augmentation procedures with options for repair. *J Periodontol*. 1999;70:692-699.
71. Fugazzotto PA, Vlassis J. A simplified classification and repair system for sinus membrane perforations. *J Periodontol*. 2003;74:1534-1541.
72. Khoury F. Augmentation of the sinus floor with mandibular bone block and simultaneous implantation: a 6-year clinical investigation. *Int J Oral Maxillofac Implants*. 1999;14:557-564.
73. Malzoni CMA, Nicoli LG, Pinto G, et al. The effectiveness of L-PRF in the treatment of Schneiderian membrane large perforations: long-term follow-up of a case series. *J Oral Implantol*. 2020;47(1):31-35.
74. Taschieri S, Corbella S, Tsesis I, Del Fabbro M. Impact of the use of plasma rich in growth factors (PRGF) on the quality of life of patients treated with endodontic surgery when a perforation of sinus membrane occurred. A comparative study. *Oral Maxillofac Surg*. 2014;18:43-52.
75. Taschieri S, Corbella S, Del Fabbro M. Use of plasma rich in growth factor for Schneiderian membrane management during maxillary sinus augmentation procedure. *J Oral Implantol*. 2012;38:621-627.
76. de Oliveira H, de Moraes RPF, Limirio P, Dechichi P. Repair of a perforated sinus membrane with an autogenous periosteal graft: a study in 24 patients. *Br J Oral Maxillofac Surg*. 2018;56:299-303.
77. Holtzclaw D. Maxillary sinus membrane repair with amnion-chorion barriers: a retrospective case series. *J Periodontol*. 2015;86:936-940.
78. Proussaefs P, Lozada J. The "Loma Linda pouch": a technique for repairing the perforated sinus membrane. *Int J Periodontics Restorative Dent*. 2003;23:593-597.
79. Testori T, Wallace SS, Del Fabbro M, et al. Repair of large sinus membrane perforations using stabilized collagen barrier membranes: surgical techniques with histologic and radiographic evidence of success. *Int J Periodontics Restorative Dent*. 2008;28:9-17.
80. Shlomi B, Horowitz I, Kahn A, Dobriyan A, Chaushu G. The effect of sinus membrane perforation and repair with Lambone on the outcome of maxillary sinus floor augmentation: a radiographic assessment. *Int J Oral Maxillofac Implants*. 2004;19:559-562.
81. Watelet JB, Bachert C, Gevaert P, Van Cauwenberge P. Wound healing of the nasal and paranasal mucosa: a review. *Am J Rhinol*. 2002;16:77-84.
82. Testori T, Yu S-H, Scaini R, et al. Split-thickness flap for the management of a maxillary sinus wall bony fenestration during lateral window sinus augmentation: case reports and technical surgical notes. *Int J Periodontics Restorative Dent*. 2022;42(3):311-318.
83. Favero V, Lang NP, Canullo L, Urbizo Velez J, Bengazi F, Botticelli D. Sinus floor elevation outcomes following perforation of the Schneiderian membrane. An experimental study in sheep. *Clin Oral Implants Res*. 2016;27:233-240.
84. Lim HC, Son Y, Hong JY, Shin SI, Jung UW, Chung JH. Sinus floor elevation in sites with a perforated Schneiderian membrane: what is the effect of placing a collagen membrane in a rabbit model? *Clin Oral Implants Res*. 2018;29:1202-1211.
85. Öncü E, Kaymaz E. Assessment of the effectiveness of platelet rich fibrin in the treatment of Schneiderian membrane perforation. *Clin Implant Dent Relat Res*. 2017;19:1009-1014.
86. Thoma DS, Yoon SR, Cha JK, et al. Sinus floor elevation using implants coated with recombinant human bone morphogenetic protein-2: micro-computed tomographic and histomorphometric analyses. *Clin Oral Investig*. 2018;22:829-837.

87. Proussaefs P, Lozada J, Kim J, Rohrer MD. Repair of the perforated sinus membrane with a resorbable collagen membrane: a human study. *Int J Oral Maxillofac Implants*. 2004;19:413-420.
88. Nolan PJ, Freeman K, Kraut RA. Correlation between Schneiderian membrane perforation and sinus lift graft outcome: a retrospective evaluation of 359 augmented sinus. *J Oral Maxillofac Surg*. 2014;72:47-52.
89. Becker ST, Terheyden H, Steinriede A, Behrens E, Springer I, Wiltfang J. Prospective observation of 41 perforations of the Schneiderian membrane during sinus floor elevation. *Clin Oral Implants Res*. 2008;19:1285-1289.
90. Tavelli L, Borgonovo AE, Ravida A, et al. Analysis of forces applied during transalveolar sinus lift: a preliminary clinical study. *Implant Dent*. 2018;27:630-637.
91. Barootchi S, Ravida A, Tavelli L, Wang HL. Nonsurgical treatment for peri-implant mucositis: a systematic review and meta-analysis. *Int J Oral Implantol*. 2020;13:123-139.
92. Proussaefs P, Lozada J, Kim J. Effects of sealing the perforated sinus membrane with a resorbable collagen membrane: a pilot study in humans. *J Oral Implantol*. 2003;29:235-241.
93. Hernández-Alfaro F, Torradeflot MM, Marti C. Prevalence and management of Schneiderian membrane perforations during sinus-lift procedures. *Clin Oral Implants Res*. 2008;19:91-98.
94. Alayan J, Ivanovski S. A prospective controlled trial comparing xenograft/autogenous bone and collagen-stabilized xenograft for maxillary sinus augmentation-complications, patient-reported outcomes and volumetric analysis. *Clin Oral Implants Res*. 2018;29:248-262.
95. Beck-Broichsitter BE, Gerle M, Wiltfang J, Becker ST. Perforation of the Schneiderian membrane during sinus floor elevation: a risk factor for long-term success of dental implants? *Oral Maxillofac Surg*. 2020;24:151-156.
96. Beck-Broichsitter BE, Westhoff D, Behrens E, Wiltfang J, Becker ST. Impact of surgical management in cases of intraoperative membrane perforation during a sinus lift procedure: a follow-up on bone graft stability and implant success. *Int J Implant Dent*. 2018;4:6.
97. Park WB, Kang KL, Han JY. Factors influencing long-term survival rates of implants placed simultaneously with lateral maxillary sinus floor augmentation: a 6- to 20-year retrospective study. *Clin Oral Implants Res*. 2019;30:977-988.
98. Kim JS, Choi SM, Yoon JH, et al. What affects postoperative sinusitis and implant failure after dental implant: a meta-analysis. *Otolaryngol Head Neck Surg*. 2019;160:974-984.
99. Schwartz-Arad D, Herzberg R, Dolev E. The prevalence of surgical complications of the sinus graft procedure and their impact on implant survival. *J Periodontol*. 2004;75:511-516.
100. Rosano G, Taschieri S, Gaudy JF, Del Fabbro M. Maxillary sinus vascularization: a cadaveric study. *J Craniofac Surg*. 2009;20(3):940-943.
101. Elian N, Wallace S, Cho SC, Jalbout ZN, Froum S. Distribution of the maxillary artery as it relates to sinus floor augmentation. *Int J Oral Maxillofac Implants*. 2005;20(5):784-787.
102. Mardinger O, Abba M, Hirshberg A, Schwartz-Arad D. Prevalence, diameter and course of the maxillary intraosseous vascular canal with relation to sinus augmentation procedure: a radiographic study. *Int J Oral Maxillofac Surg*. 2007;36(8):735-738.
103. Solar P, Geyerhofer U, Traxler H, Windisch A, Ulm C, Watzek G. Blood supply to the maxillary sinus relevant to sinus floor elevation procedures. *Clin Oral Implants Res*. 1999;10:34-44.
104. Traxler H, Windisch A, Geyerhofer U, Surd R, Solar P, Firbas W. Arterial blood supply of the maxillary sinus. *Clin Anat*. 1999;12(6):417-421.
105. Rosano G, Taschieri S, Gaudy JF, Weinstein T, Del Fabbro M. Maxillary sinus vascular anatomy and its relation to sinus lift surgery. *Clin Oral Implants Res*. 2011;22:711-715.
106. Valente NA. Anatomical considerations on the alveolar antral artery as related to the sinus augmentation surgical procedure. *Clin Implant Dent Relat Res*. 2016;18:1042-1050.
107. Ella B, Sedarat C, Da Costa Noble C, et al. Vascular connections of the lateral wall of the sinus: surgical effect in sinus augmentation. *Int J Oral Maxillofac Implants*. 2008;23:1047-1052.
108. Guncu GN, Yildirim YD, Wang HL, Tozum TF. Location of posterior superior alveolar artery and evaluation of maxillary sinus anatomy with computerized tomography: a clinical study. *Clin Oral Implants Res*. 2011;22:1164-1167.
109. Testori T, Rosano G, Taschieri S, Del Fabbro M. Ligation of an unusually large vessel during maxillary sinus floor augmentation. A case report. *Eur J Oral Implantol*. 2010;3:255-258.
110. Maridati P, Stoffella E, Speroni S, Ciccio M, Maiorana C. Alveolar antral artery isolation during sinus lift procedure with the double window technique. *Open Dent J*. 2014;8:95-103.
111. Testori T, Drago L, Wallace SS, et al. Prevention and treatment of postoperative infections after sinus elevation surgery: clinical consensus and recommendations. *Int J Dent*. 2012;2012:365809. doi:10.1155/2012/36
112. Quiney RE, Brimble E, Hodge M. Maxillary sinusitis from dental osseointegrated implants. *J Laryngol Otol*. 1990;104:333-334.
113. Wiltfang J, Schultze-Mosgau S, Nkenke E, Thorwarth M, Neukam FW, Schlegel KA. Onlay augmentation versus sinuslift procedure in the treatment of the severely resorbed maxilla: a 5-year comparative longitudinal study. *Int J Oral Maxillofac Surg*. 2005;34:885-889.
114. Shiffler K, Lee D, Aghaloo T, Moy PK, Pi-Anfruns J. Sinus membrane perforations and the incidence of complications: a retrospective study from a residency program. *Oral Surg Oral Med Oral Pathol Oral Radiol*. 2015;120:10-14.
115. Chan HL, Wang HL. Sinus pathology and anatomy in relation to complications in lateral window sinus augmentation. *Implant Dent*. 2011;20:406-412.
116. Testori T, Scaini R, Deflorian M, et al. Mucosal cyst aspiration in conjunction with maxillary sinus elevation: a clinical cohort study. *Submitted CIDDR Materials*. 2023.
117. Hadar T, Shvero J, Nageris BI, Yaniv E. Mucus retention cyst of the maxillary sinus: the endoscopic approach. *Br J Oral Maxillofac Surg*. 2000;38:227-229.
118. Ghasemi S, Fotouhi A, Moslemi N, Chinipardaz Z, Kolahi J, Paknejad M. Intra- and postoperative complications of lateral maxillary sinus augmentation in smokers vs nonsmokers: a systematic review and meta-analysis. *Int J Oral Maxillofac Implants*. 2017;32:759-767.
119. Ritter A, Rozendorn N, Avishai G, Rosenfeld E, Koren I, Soudry E. Preoperative maxillary sinus imaging and the outcome of sinus floor augmentation and dental implants in asymptomatic patients. *Ann Otol Rhinol Laryngol*. 2020;129:209-215.
120. Maksoud MA. Complications after maxillary sinus augmentation: a case report. *Implant Dent*. 2001;10:168-171.
121. Chiapasco M, Felisati G, Maccari A, Borloni R, Gatti F, Di Leo F. The management of complications following displacement of oral implants in the paranasal sinuses: a multicenter clinical report and proposed treatment protocols. *Int J Oral Maxillofac Surg*. 2009;38:1273-1278.
122. Kluppel LE, Santos SE, Olate S, Freire Filho FW, Moreira RW, de Moraes M. Implant migration into maxillary sinus: description of two asymptomatic cases. *Oral Maxillofac Surg*. 2010;14:63-66.
123. Katranji A, Fotek P, Wang HL. Sinus augmentation complications: etiology and treatment. *Implant Dent*. 2008;17:339-349.
124. Ragucci GM, Elnayef B, Suarez-Lopez Del Amo F, Wang HL, Hernandez-Alfaro F, Gargallo-Albiol J. Influence of exposing dental implants into the sinus cavity on survival and complications rate: a systematic review. *Int J Implant Dent*. 2019;5:6.
125. Jung JH, Choi BH, Jeong SM, Li J, Lee SH, Lee HJ. A retrospective study of the effects on sinus complications of exposing dental

- implants to the maxillary sinus cavity. *Oral Surg Oral Med Oral Pathol Oral Radiol Endod.* 2007;103:623-625.
126. Tabrizi R, Amid R, Taha Ozkan B, Khorshidi H, Langner NJ. Effects of exposing dental implant to the maxillary sinus cavity. *J Craniofac Surg.* 2012;23:767-769.
 127. Abi Najm S, Malis D, El Hage M, Rahban S, Carrel JP, Bernard JP. Potential adverse events of endosseous dental implants penetrating the maxillary sinus: long-term clinical evaluation. *Laryngoscope.* 2013;123:2958-2961.
 128. Kim HY, Yang JY, Chung BY, Kim JC, Yeo IS. Peri-implant bone length changes and survival rates of implants penetrating the sinus membrane at the posterior maxilla in patients with limited vertical bone height. *J Periodontal Implant Sci.* 2013;43:58-63.
 129. Testori T, Clauser T, Saibene AM, et al. Radiographic protrusion of dental implants in the maxillary sinus and nasal fossae: a multidisciplinary consensus utilising the modified Delphi method. *Int J Oral Implantol.* 2022;15(3):265-275.
 130. Barootchi S, Tavelli L, Di Gianfilippo R, et al. Long term assessment of root coverage stability using connective tissue graft with or without an epithelial collar for gingival recession treatment. A 12-year follow-up from a randomized clinical trial. *J Clin Periodontol.* 2019;46:1124-1133.
 131. Buser D, Chappuis V, Kuchler U, et al. Long-term stability of early implant placement with contour augmentation. *J Dent Res.* 2013;92:176S-182S.
 132. Chappuis V, Buser R, Bragger U, Bornstein MM, Salvi GE, Buser D. Long-term outcomes of dental implants with a titanium plasma-sprayed surface: a 20-year prospective case series study in partially edentulous patients. *Clin Implant Dent Relat Res.* 2013;15:780-790.
 133. Shi JY, Qian SJ, Gu YX, Qiao SC, Tonetti MS, Lai HC. Long-term outcomes of osteotome sinus floor elevation without grafting in severely atrophic maxilla: a 10-year prospective study. *J Clin Periodontol.* 2020;47:1528-1535.
 134. Cortellini P, Buti J, Pini Prato G, Tonetti MS. Periodontal regeneration compared with access flap surgery in human intra-bony defects 20-year follow-up of a randomized clinical trial: tooth retention, periodontitis recurrence and costs. *J Clin Periodontol.* 2017;44:58-66.
 135. Wang D, Tian J, Wang Y, Wei D, Lin Y. Clinical and radiographic outcomes of reentry lateral sinus floor elevation after a complete membrane perforation. *Clin Implant Dent Relat Res.* 2020;22:574-581.
 136. Tonetti MS, Hammerle CH, European Workshop on Periodontology Group C. Advances in bone augmentation to enable dental implant placement: consensus report of the sixth European workshop on periodontology. *J Clin Periodontol.* 2008;35:168-172.
 137. Antonoglou GN, Stavropoulos A, Samara MD, et al. Clinical performance of dental implants following sinus floor augmentation: a systematic review and meta-analysis of clinical trials with at least 3 years of follow-up. *Int J Oral Maxillofac Implants.* 2018;33:e45-e65.
 138. Barbato L, Baldi N, Gonnelli A, Duvina M, Nieri M, Tonelli P. Association of smoking habits and height of residual bone on implant survival and success rate in lateral sinus lift: a retrospective study. *J Oral Implantol.* 2018;44:432-438.
 139. Chambrone L, Preshaw PM, Ferreira JD, Rodrigues JA, Cassoni A, Shibli JA. Effects of tobacco smoking on the survival rate of dental implants placed in areas of maxillary sinus floor augmentation: a systematic review. *Clin Oral Implants Res.* 2014;25:408-416.
 140. Mordenfeld A, Albrektsson T, Hallman M. A 10-year clinical and radiographic study of implants placed after maxillary sinus floor augmentation with an 80:20 mixture of deproteinized bovine bone and autogenous bone. *Clin Implant Dent Relat Res.* 2014;16:435-446.
 141. Testori T, Scaini R, Deflorian M, Wallace SS, Tarnow D. Lateral window surgical techniques for sinus elevation. In: Jensen OT, ed. *The Sinus Bone Graft.* 3rd ed. Quintessence Publishing; 2008:59-60.
 142. Zaniol T, Zaniol A, Ravazzolo S, Testori T, Wallace SS. Low window sinus elevation technique: bone gain and postsurgical discomfort. A retrospective case series. *Int J Periodontics Restorative Dent.* 2022;42(4):449-457.

How to cite this article: Testori T, Tavelli L, Scaini R, et al. How to avoid intraoperative and postoperative complications in maxillary sinus elevation. *Periodontol 2000.* 2023;92:299-328. doi:[10.1111/prd.12480](https://doi.org/10.1111/prd.12480)