

Immunomodulatory Treatment Versus Systemic Steroids in Inflammatory Choroidal Neovascularization Secondary to Idiopathic Multifocal Choroiditis



MATTEO AIRALDI, DAVIDE MONTEDURO, GIOVANNI TONDINI, FRANCESCO PICHI, LUCA DE SIMONE, ELISA CORNISH, GIUSEPPE CASALINO, FEDERICO ZICARELLI, MARTA OLDANI, GIOVANNI STAURENGHI, PETER MCCLUSKEY, LUCA CIMINO, AND ALESSANDRO INVERNIZZI

- **PURPOSE:** To evaluate the influence of immunomodulatory therapy (IMT) on visual and treatment outcomes of inflammatory choroidal neovascularization (iCNV) in patients affected by multifocal choroiditis (MFC), and to compare them to patients treated with steroids as needed.
- **DESIGN:** Multicenter retrospective matched cohort study.
- **METHODS:** Patients affected by MFC with iCNV were divided into a IMT group and a “steroids as needed” group and matched according to the time between diagnosis and beginning of systemic treatment. Visual acuity (VA), number of anti-vascular endothelial growth factor (VEGF) intravitreal injections, and number of iCNV reactivations during 2 years of follow-up after treatment initiation were compared between the 2 groups.
- **RESULTS:** A total of 66 eyes of 58 patients were included, equally divided into the 2 groups. Patients in the IMT group had a lower relative risk (RR) of iCNV reactivation (0.64, $P = .04$) and of anti-VEGF intravitreal injection retreatment (0.59, $P = .02$). Relapses of MFC-related inflammation were independently associated with a higher RRs of iCNV reactivation (1.22, $P = .003$). Final VA was higher in the IMT compared to the steroids as needed group (mean [SD], 69.1 [15.1] vs 77.1 [8.9]

letters, $P = .01$), and IMT was associated with greater VA gains over time (+2.5 letters per year, $P = .04$).

- **CONCLUSIONS:** IMT was associated with better visual and treatment outcomes in MFC complicated by iCNV compared to steroids as needed. The better outcomes of the IMT group and the association between MFC-related inflammation and iCNV reactivations highlight the need for tighter control of inflammation to prevent iCNV relapses and visual loss. (Am J Ophthalmol 2024;262: 62–72. © 2024 The Authors. Published by Elsevier Inc. This is an open access article under the CC BY-NC-ND license (<http://creativecommons.org/licenses/by-nc-nd/4.0/>))

INFLAMMATORY CHOROIDAL NEOVASCULARIZATION (iCNV) is a common complication of posterior uveitis, with a reported prevalence of up to 90% in patients diagnosed with multifocal choroiditis (MFC).¹⁻⁴ Neovascularization represents a stereotypic, nonspecific, wound-repair response to a pathological stimulus.^{5,6} In iCNV, inflammation contributes to both the initial angiogenic response to retinal pigment epithelium (RPE) breakthrough and to the exudative activity of the lesion.⁷

Eyes with iCNV respond promptly to anti-vascular endothelial growth factor (anti-VEGF) intravitreal injections and are most commonly managed with reactive, as needed regimens, tailored according to the activity of the individual lesion at the physician's discretion.^{1,8,9} In addition to anti-VEGF injections, systemic anti-inflammatory treatment in MFC aims to prevent relapses of the disease, the formation of new foci of inflammation and subsequent atrophy, and to control the activity of iCNV given its relationship with low-grade chorioretinal inflammation.^{4,7,10}

Small retrospective series have found immunomodulatory therapy (IMT) to be superior to systemic steroids alone in reducing the number of iCNV reactivations.¹¹⁻¹³ In fact, multiple authors recommend aggressive and prolonged IMT in addition to anti-VEGF injections, especially in cases of recurrent or sight-threatening iCNV.¹⁴⁻¹⁷ However, given the low prevalence of the disease, large randomized con-

AJO.com Supplemental Material available at AJO.com.
Accepted for publication January 1, 2024.

From the Eye Clinic (M.A., D.M., G.T., F.Z., M.O., G.S., A.I.), Department of Biomedical and Clinical Science, Luigi Sacco Hospital, University of Milan, Milan, Italy; Department of Molecular and Translational Medicine (M.A.), University of Brescia, Brescia, Italy; Eye Institute (F.P.), Cleveland Clinic Abu Dhabi, Abu Dhabi, United Arab Emirates; Cleveland Clinic Lerner College of Medicine (F.P.), Case Western Reserve University, Cleveland, Ohio, USA; Ocular Immunology Unit (L.D.S., L.C.), Azienda USL-IRCCS di Reggio Emilia, Reggio Emilia, Italy; Save Sight Institute (E.C., P.M., A.I.), Faculty of Medicine & Health, The University of Sydney, Sydney, NSW, Australia; Fondazione IRCCS Cà Granda (G.C.), Ospedale Maggiore Policlinico, University of Milan, Milan, Italy; Department of Surgery, Medicine, Dentistry and Morphological Sciences (L.C.), with Interest in Transplants, Oncology and Regenerative Medicine, University of Modena and Reggio Emilia, Modena, Italy

Inquiries to Alessandro Invernizzi, Eye Clinic, Luigi Sacco Hospital, University of Milan, Milan, Italy; e-mail: alessandro.invernizzi@gmail.com

trolled trials (RCT) comparing the efficacy of different treatment strategies to control iCNV activity in MFC are lacking.⁸ For this reason, many clinicians still favor repeated courses of high-dose systemic steroids along with anti-VEGF to manage iCNV reactivations over prolonged IMT, the former coming with a higher treatment burden and potential serious systemic adverse events.⁷

Because of the challenges of performing a well-balanced RCT, a reasonable approach is to compare the incidence of iCNV relapses among 2 populations of MFC patients matched by clinical features but managed with different systemic treatments.^{18,19} The aim of this cohort study was therefore to compare the relative risk of iCNV reactivation, the number of injections, and the visual outcomes of 2 historical cohorts of MFC patients, one treated with IMT and the other with systemic steroids as needed, over a period of 2 years.

METHODS

The present study has been reported according to the Strengthening the Reporting of Observational Studies in Epidemiology (STROBE) checklist for cohort studies.²⁰

• **STUDY DESIGN AND SETTING:** This matched historical cohort study included patients affected by MFC complicated by iCNV referred to 5 tertiary referring centers: Luigi Sacco Hospital, Milan, Italy; Policlinico Ca' Granda, Milan, Italy; Cleveland Clinic, Abu Dhabi, UAE; Arcispedale Santa Maria Nuova, Reggio Emilia, Italy; and Save Sight Institute, Sydney, Australia.

Local institutional review board approval was obtained, and the study adhered to the tenets of the Declaration of Helsinki. Given its retrospective nature, waiver of informed consent was granted.

• **PARTICIPANTS AND STUDY GROUPS:** Patients affected by MFC complicated by iCNV presenting between 2010 and 2020 with at least 2 years of follow-up after systemic treatment initiation were identified from electronic health records, and the clinical data were collected and analyzed.

Patients were divided into 2 cohorts according to the systemic treatment received: (1) an “immunomodulatory therapy” group, who received long-term systemic treatment with at least 1 immunosuppressive drug other than steroids, or a combination of multiple immunosuppressive drugs; and (2) a “steroids as needed” group who received oral prednisone at every relapse of MFC or iCNV, starting at 1 mg/kg/d then slowly tapered down and interrupted, with no other immunosuppressive drug before or during the study period.

In both groups, anti-VEGF intravitreal injections were administered in the case of iCNV activity at the discretion

of the treating practitioner, following a “as needed” regimen.^{1,2,21}

The study period was 2 years from the beginning of immunosuppressive treatment in the IMT group. Patients in the steroids as needed group were matched with those in the IMT group according to the time elapsed between the iCNV diagnosis and the start of immunosuppressive treatment (± 3 months), to account for the diminishing activity and need for treatment of iCNV over time.^{1,2}

• **INCLUSION AND EXCLUSION CRITERIA:** Inclusion criteria included a clinical diagnosis of MFC, the presence of an iCNV that received anti-VEGF intravitreal injections, a follow-up of at least 2 years after systemic treatment initiation, and at least 3 visits including OCT imaging each year.

Exclusion criteria included iCNV secondary to uveitis other than MFC and treatment with an intravitreal dexamethasone implant and intravitreal or subconjunctival injection of steroids. Low-dose oral prednisone (ie, <7.5 mg/day) during the study period was considered acceptable only in the IMT group in addition to the immunosuppressive treatment.

• **DIAGNOSIS OF MFC AND ICNV:** The diagnosis of MFC was based on the presence of a compatible clinical picture and the exclusion of any infectious or autoimmune uveitis other than MFC possibly causing MFC-like lesions.^{2,10}

The diagnosis of iCNV was based on the presence of an active CNV in eyes affected by MFC. The CNV complex was identified with a multimodal imaging approach including fundus fluorescein angiography, OCT, and at least 1 of either indocyanine green angiography or OCT angiography.^{3,7}

The definition of iCNV activity was based on the identification by the treating physician of 1 or more of the following signs: leakage on fluorescein angiography; intraretinal fluid, subretinal fluid or subretinal hyper-reflective material on OCT; and blood at funduscopic examination.^{1,2,7}

• **VARIABLES AND DATA MEASUREMENT:** The primary outcome was the relative risk (RR) of iCNV reactivation during the 2-year study period between the IMT group and the steroids as needed group.

Secondary outcomes were the number of anti-VEGF injections and the difference in visual acuity (VA) between the 2 groups at 12 and 24 months.

Data collected within 1 month before or after the exact timeframes mentioned above were considered acceptable, given the retrospective nature of the study.

Medical charts of the patients were examined and demographic and clinical features including age, gender/sex, baseline VA, iCNV location, anti-VEGF drug used, number of MFC relapses during the study period, and number of injections and iCNV reactivations before the study period were collected and compared between the 2 groups.

• **STATISTICAL ANALYSIS:** Descriptive data were summarized using the mean (SD), median (25th and 75th quartile range), and number (percentage) where appropriate.

Fisher exact tests and independent *t* tests were used to compare baseline differences between groups. Independent *t* tests or Wilcoxon signed rank tests were used to compare outcomes at 12 and 24 months between the 2 groups. Paired *t* tests were used to compare VA at 12 and 24 months with baseline VA within each group.

The incidence rates of iCNV reactivation and their 95% CI for the 2 treatment groups were calculated over the entire course of follow-up and reported as the number of events per person-year. Kaplan–Meier curves were used to estimate the median time to reinjection after the start of the observation period, and a log-rank test was used to compare survival estimates between the 2 cohorts. The Pearson–Klopper method was used to estimate and compare the 95% binomial CIs of the proportions of visits in which the iCNV was graded as “active” by the treating practitioner.

Generalized linear mixed-effects models with negative binomial distribution were used to test the difference in number of reactivations of iCNV activity and number of injections between the 2 groups at 12 and 24 months. Negative binomial distribution was used instead of the more common Poisson distribution, because it is better suited to model recurrent events²² and because of the high variance of the counts of iCNV reactivations and injections.

Linear mixed-effects models were used to compare VA trends between the 2 groups over 24 months of follow-up.

In all models, the main predictor was the interaction between time point and treatment arm. Covariates in the negative binomial models included age, reactivations of iCNV before the study period, time from iCNV diagnosis to immunomodulatory therapy, number of relapses of MFC during the study period, and location of the iCNV. Covariates in the linear VA model included baseline age, baseline VA, and number of reactivations of iCNV and of MFC. All models included nesting of outcomes within practices and within patients with bilateral disease as random effects.

Relative risks were derived as measures of association of independent variables with iCNV activity and number of injections. Estimated marginal means were used to derive expected values of outcomes at 12 and 24 months, and to compare them between the 2 treatment groups.

A *P* value of less than .05 was considered statistically significant. All analyses were conducted using R software version 4.2.2 (R Project for Statistical Computing) with packages *epiR*, *glmmTMB*, and *emmeans*.

RESULTS

A total of 66 eyes of 58 patients with MFC complicated by iCNV were included in the study, equally divided between the steroids as needed and the IMT groups (33 eyes,

29 patients each). Clinical features and descriptive statistics for the 2 groups are reported in [Table 1](#). Age, gender distribution, and baseline VA were comparable between the 2 groups. Most patients were Caucasian (90% and 83%, respectively). Mycophenolate mofetil was the most commonly used immunosuppressive drug (79%); among patients in the IMT group, 9 patients (27%) had been on multiple drugs during the study period. iCNV location was most frequently sub- or juxtafoveal, with no difference between the 2 groups (*P* = .62). Ranibizumab monotherapy was the most frequently used anti-VEGF drug (61% and 73% in the 2 groups).

• **TIME TO IMMUNOMODULATORY THERAPY:** Seven eyes of 6 patients with a treatment-naïve iCNV started immunosuppressive therapy at presentation. Accordingly, 7 treatment-naïve iCNVs of 6 patients who had instead been treated with steroids as needed were included to match them with the immunosuppressed ones for a total of 14 treatment-naïve iCNVs equally distributed between the 2 groups.

The 2-year study window of the other 26 eyes of 23 IMT patients was matched (± 3 months) with 26 eyes of 23 “steroids as needed” patients based on time between iCNV diagnosis and the beginning of immunosuppressive therapy. The mean (SD) time to the study period was 10.1 (13.2) months in the steroids as needed group and 13.9 (14.1) months in the immunomodulatory therapy group, with no significant difference between groups (*P* = .46). The time to immunomodulatory therapy initiation ranged from 0 to 48 months.

Before the study period, non-treatment-naïve eyes in the 2 groups had similar numbers of iCNV reactivations (median [IQR], 1 [0.5, 2] vs 1 [1, 3], *P* = .19) and injections (median [IQR], 1 [1, 2] vs 2 [1, 6], *P* = .1).

Baseline findings and outcomes at 12 and 24 months are summarized in [Table 2](#).

• **NUMBER OF RECURRENCES AND INJECTIONS:** Patients in the steroids as needed group experienced a greater total number of iCNV recurrences over 2 years of follow-up (median [IQR], 3 [2, 5] vs 1 [1, 3], *P* = .005). Consequently, the overall incidence rate of iCNV reactivation was higher in this group compared to the IMT group (IR [95% CI], 1.5 [1.2, 1.9] vs 0.9 [0.7, 1.2] reactivations per person-year).

Immunomodulatory therapy was significantly associated with a lower risk of iCNV reactivation compared to the steroids as needed regimen (RR [95% CI], 0.64 [0.41, 0.99], *P* = .04) ([Figure 1](#)).

The number of iCNV reactivations decreased in year 2 compared to year 1 in both groups (both *P* < .05) ([Figure 2](#)), as reflected by a significantly lower risk for reactivation in year 2 (RR [95% CI], 0.51 [0.32, 0.8], *P* = .003).

The longer the time elapsed between diagnosis and study period, the lower was the risk of iCNV reactivation (RR [95% CI], 0.75 [0.59, 0.96], *P* = .02). Relapse of MFC-

TABLE 1. Baseline and Demographic Characteristics of Included Subjects

	Steroids as Needed	Immunomodulatory Therapy	P Value
Eyes, n	33	33	
Patients, n	29	29	
Women, n (%)	26 (89.7%)	21 (72.4%)	.18
Baseline age, y, mean (SD)	43.8 (13.8)	39 (11)	.13
Baseline VA, logMAR letters, mean (SD)	66.3 (17.1)	69.1 (13.2)	.46
Practice			.003
Abu Dahbi	0 (0%)	5 (15.2%)	
Milan – Sacco	24 (72.7%)	13 (39.4%)	
Milan – Policlinico	1 (3%)	4 (12.1%)	
Reggio Emilia	2 (6.1%)	8 (24.2%)	
Sydney	6 (18.2%)	3 (9.1%)	
Ethnicity, n (%)			.02
Caucasian	30 (90.9%)	28 (84.8%)	
Arabic	0 (0%)	5 (15.2%)	
Asian	2 (6.1%)	0 (0%)	
Indian	1 (3%)	0 (0%)	
Uveitis, n (%)			
MFC	33 (100%)	33 (100%)	
Immunomodulatory treatment, n (%)			< .001
Prednisone (<7.5 mg/kg/die)		15 (45.5%)	
MMF		26 (78.8%)	
AZA		4 (12.1%)	
MTX		3 (9.1%)	
CSA		8 (24.2%)	
IFX		1 (3%)	
Combined		9 (27.3%)	
iCNV location, n (%)			.62
Subfoveal	16 (48.5%)	14 (42.4%)	
Juxtafoveal	16 (48.5%)	19 (57.6%)	
Extrafoveal	1 (3%)	0 (0%)	
Anti-VEGF injection, n (%)			.35
Ranibizumab	20 (60.6%)	24 (72.7%)	
Aflibercept	1 (3%)	3 (9.1%)	
Bevacizumab	7 (21.2%)	4 (12.1%)	
Switch	5 (15.2%)	2 (6.1%)	

Anti-VEGF = anti-vascular endothelial growth factor; AZA = azathioprine; CSA = cyclosporine; iCNV = inflammatory choroidal neovascularization; IFX = infliximab; MFC = multifocal choroiditis; MMF = mycophenolate mofetil; MTX = methotrexate; VA = visual acuity.

related chorioretinal inflammation was instead associated with a higher risk of iCNV reactivation (RR [95% CI], 1.22 [1.07, 1.38], $P = .003$).

Patients in the steroids as needed group also received a higher number of injections both in the first year (median [IQR], 1 [1, 3] vs 1 [0, 2], $P = .02$) and in the second year (median [IQR], 1 [0, 1] vs 0 [0, 1], $P = .01$) of follow-up compared to those treated with IMT.

In accordance with the iCNV relapse pattern, both groups received significantly fewer injections in year 2 compared to year 1 (both $P < .05$), as shown in Figure 2. A lower risk for injections was significantly associated with immunomodulatory therapy (RR [95% CI], 0.59 [0.38, 0.9], $P = .02$), time to study period (RR [95%

CI], 0.75 [0.59, 0.95], $P = .02$), and year 2 (RR [95% CI], 0.54 [0.35, 0.82], $P = .004$), as shown in Figure 1. Conversely, relapses of MFC (RR [95% CI], 1.21 [1.08, 1.37], $P = .002$) were associated with a higher number of injections.

Relative risks with 95% CIs for all variables examined for iCNV reactivation and number of injections are displayed in Supplemental Table 1.

- **VISUAL ACUITY:** VA was similar in the 2 groups at baseline (mean [SD], 66.3 [17.1] vs 69.1 [13.2], $P = .46$). VA improved significantly in the IMT group from baseline at 12 months (mean [SD], +6 [9.8] letters, $P = .003$) and at 24 months (mean [SD], +8 [11] letters, $P = .001$), with vision

TABLE 2. Twelve- and 24-Month Visual and Treatment Outcomes

	Steroids as Needed	Immunomodulatory Therapy	P Value
Baseline			
Baseline VA, logMAR letters, mean (SD)	66.3 (17.1)	69.1 (13.2)	.46
Follow-up before study period, mo, mean (SD)	10.1 (13.2)	13.9 (14.1)	.28
Previous iCNV recurrences, median (IQR)	1 (0.5, 2)	1 (1, 3)	.19
Previous injections, median (IQR)	1 (1, 2)	2 (1, 6)	.10
Year 1			
VA, logMAR letters, mean (SD)	69.9 (15.5)	75.1 (11.2)	.12
VA change, logMAR letters, mean (SD)	3.6 (8.9)	6 (9.8)	.30
Number of iCNV recurrences, median (IQR)	1 (1, 2)	1 (0, 2)	.06
Number of injections, median (IQR)	2 (1, 3)	1 (0, 2)	.02
Number of MFC reactivations, median (IQR)	1 (1, 1)	0 (0, 1)	.06
Year 2			
VA, logMAR letters, mean (SD)	69.1 (15.5)	77.1 (8.9)	.01
VA change, logMAR letters, mean (SD)	2.7 (12.3)	8 (11)	.07
Number of iCNV recurrences, median (IQR)	1 (0, 1)	0 (0, 1)	.01
Number of injections, median (IQR)	1 (0, 2)	0 (0, 1)	.01
Number of MFC reactivations, median (IQR)	1 (0, 1)	0 (0, 1)	.06
24-Month Total			
Number of iCNV recurrences, median (IQR)	3 (2, 4)	1 (1, 3)	.005
Number of injections, median (IQR)	3 (2, 5)	1 (1, 3)	.001
Number of MFC reactivations, median (IQR)	2 (1, 3)	1 (0, 2)	.05

iCNV = inflammatory choroidal neovascularization; IQR = interquartile range; MFC = multifocal choroiditis; VA = visual acuity.

stabilizing after the first year of treatment (year 1 vs year 2 mean [SD] difference, +2 [68.9] letters, $P = .11$) (Figure 3).

Albeit improved from baseline, VA changes in the steroids as needed group at 12 months (mean [SD], +3.6 [8.9] letters, $P = .08$) and at 24 months (mean [SD], +2.7 [12.3] letters, $P = .42$) were not statistically significant.

Final VA was significantly higher in the IMT group compared to the steroids as needed group (mean [SD], 69.1 [15.5] vs 77.1 [8.9] letters, $P = .01$).

In the linear mixed-effects model, baseline VA, baseline age, and the interaction between time and treatment arm were significantly associated with overall VA and VA change: greater values of baseline age and lower values of baseline VA were associated with lower final VA and VA gain, whereas the IMT group was associated with greater VA gains over time, with an expected increase of +2.5 (95% CI, 0.1-5) letters per year compared to the steroids as needed group (Figure 3). β -Coefficients and 95% CIs of all variables examined are displayed in Supplemental Table 2.

• **TIME TO RETREATMENT AND ICNV ACTIVITY:** On average, the time to retreatment with anti-VEGF agents after the start of the observation period was greater in the IMT group compared to the steroids as needed group, as shown in Figure 4. In fact, estimates from a Kaplan–Meier survival curve showed that the median time to reinjection was sig-

nificantly higher in the IMT group compared to the steroids as needed group (median [95% CI], 7.1 [3.4, 13.3] vs 3.2 [1.8, 10] months, $P = .01$).

Further corroborating this result, the proportion of visits in which the iCNV was graded as “active” by the treating practitioner was also significantly lower in the IMT group (proportion of visits with active iCNV [95% CI], 11.3% [8.1%, 15.3%] vs 25.8% [21.3%, 30.7%], $P < .001$).

DISCUSSION

In this historical cohort study, patients with MFC complicated by iCNV who were treated with IMT had a significantly lower risk of reactivation of iCNV compared to patients treated exclusively with courses of high-dose systemic steroids as needed. The cohort of patients treated with IMT had fewer reactivations of iCNV, received fewer anti-VEGF injections, and had a significantly higher gain and maintenance of BCVA over the course of 2 years of follow-up compared to the steroids as needed cohort.

MFC is an idiopathic inflammatory choroidopathy with a pathogenesis that remains poorly characterized. Plausible associations with specific *TNF* and *IL10* gene variants have been suggested.²³ In a recent genome-wide association

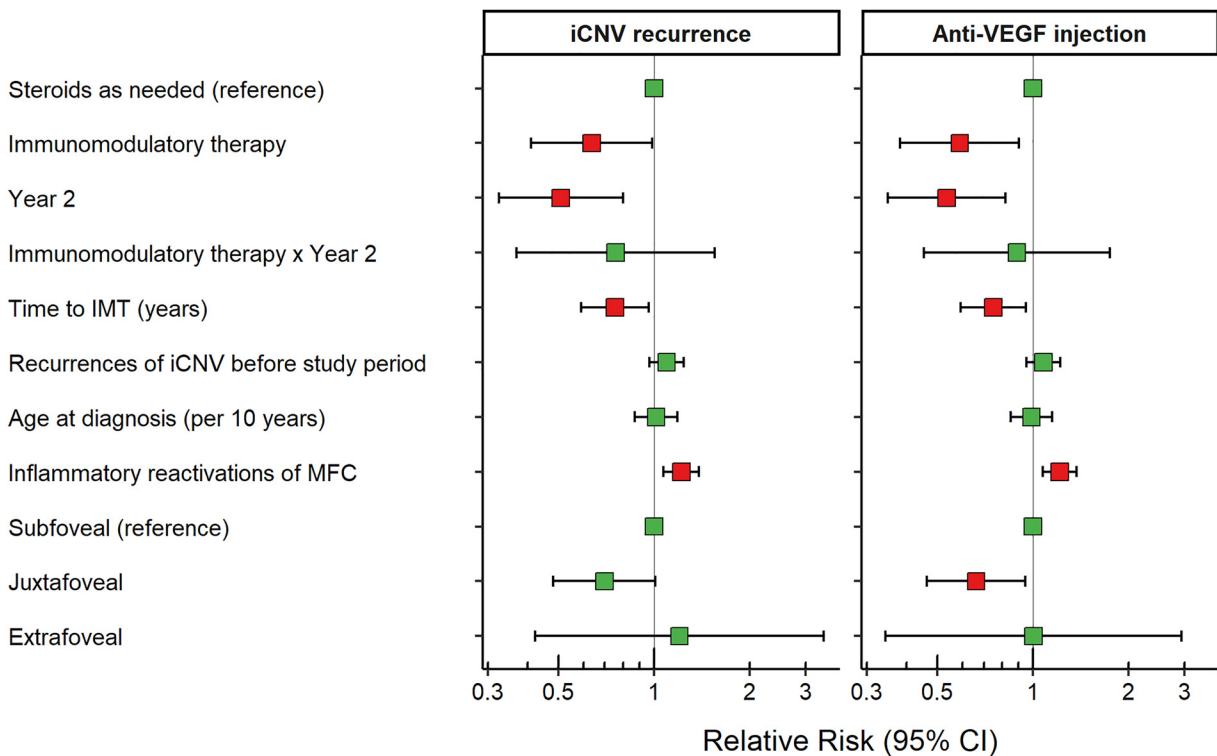


FIGURE 1. Relative risks (RR) for inflammatory choroidal neovascularization (iCNV) recurrence and anti-vascular endothelial growth factor (anti-VEGF) injection. The squares represent the point estimates of the relative risks (RRs) and the error bars span the 95% CIs of the estimates. Significant RRs are highlighted in black. Estimates are reported on the log scale. Estimates have been derived from generalized linear mixed models with nesting of outcomes within practices and within patients, with bilateral disease as random effect. Among fixed effects, treatment with immunomodulatory therapy, the second year of treatment, the time between diagnosis and the start of treatment, and inflammatory reactivations of multifocal choroiditis (MFC) during the study period independently affected the RRs for iCNV reactivation and anti-VEGF injection. The juxtafoveal location also had a significantly lower risk of anti-VEGF injection compared to the subfoveal location. See Supplemental Table 1 for detailed RRs and 95% CIs.

study, de Groot et al found that a locus in the *CFH* gene was associated with the development of idiopathic MFC.²⁴ These results suggest that multiple inflammatory pathways might play a key role in the development and sustainment of choriocapillaris inflammation and hypoperfusion, retinal pigment epithelium loss, and most likely in the development of iCNV, highlighting the complexity of the underlying inflammatory process.^{23,24} The regulation of these inflammatory cascades achieved with IMT can avoid the “saw-tooth” fluctuation of inflammatory mediators associated with MFC flare-ups that can trigger iCNV reactivations.^{7,10,12,13,15-17,24,25} High-dose oral steroids, albeit very effective in the short-term control of inflammation, cannot be maintained in the long term because of their severe systemic side effects, and their tapering eventually leads to an increase in inflammatory mediators that can predispose patients to MFC and iCNV relapses.^{7,25,26}

As expected, in our study the IMT cohort experienced significantly fewer reactivations of iCNV activity during the first 2 years of treatment compared to the matched co-

hort of patients treated with oral steroids as needed. Reactivations decreased during the follow-up in both groups, due to the diminishing activity of iCNV after its onset.¹ The matched design of our study allowed us to counter this effect by pairing patients according to the time elapsed between iCNV diagnosis and start of IMT. The finding of lower reactivation rates in the IMT group is in line with what reported by Neri et al in a cohort of patients affected by iCNV, caused by different underlying inflammatory choroidopathies, treated either with prompt or delayed IMT.¹³ The authors found that patients treated promptly with IMT had fewer reactivations of iCNV and better final VA compared to patients started on high-dose oral steroids, which were then tapered down followed by the patients being treated with IMT later on.

In our study, IMT was not only associated with a lower risk of iCNV reactivations and with the need for anti-VEGF injections, but also with better VA gains over the period of follow-up. In fact, while starting from comparable baseline VA, patients in the IMT cohort experienced

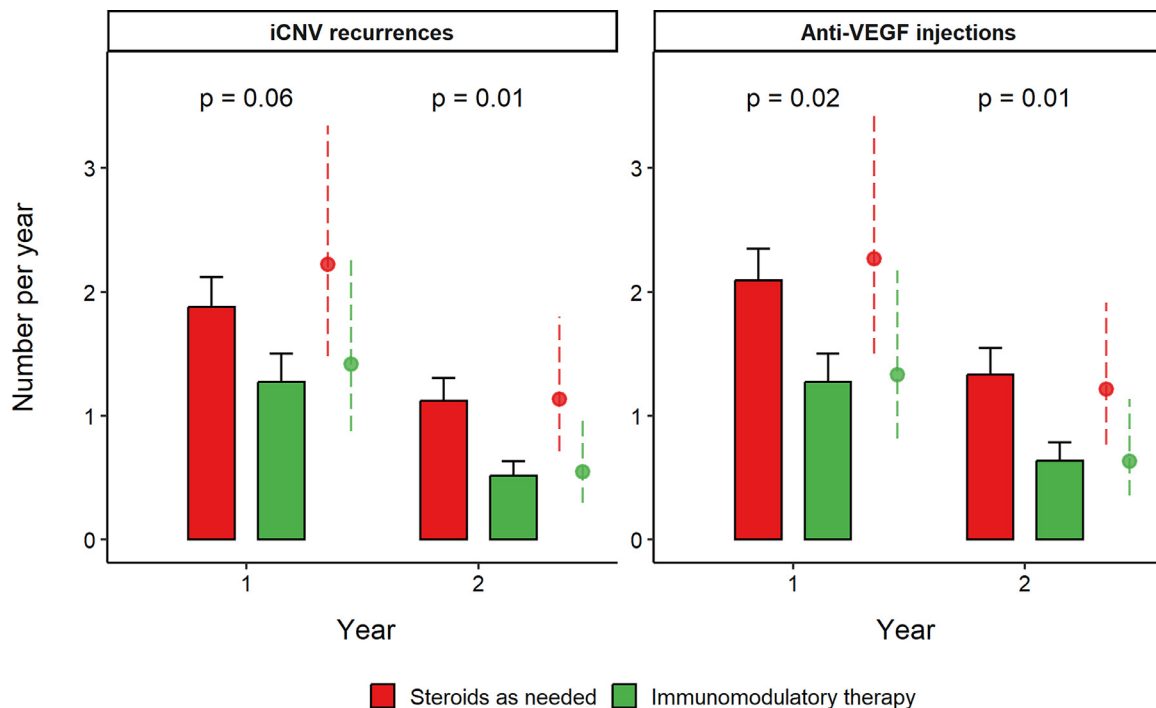


FIGURE 2. Annual inflammatory choroidal neovascularization (iCNV) recurrences and anti-vascular endothelial growth factor (anti-VEGF) injections. Bar plots represent the average number of iCNV recurrences (left) and anti-VEGF injections (right) per year in the steroids as needed and immunomodulatory therapy (IMT) group. Error bars extend to 1 standard error of the mean. P values for Wilcoxon signed rank tests comparing the average count between the 2 groups at each year are reported. The shaded, dashed point ranges represent the expected count of iCNV recurrences and anti-VEGF injections adjusted for the confounding variables detailed in the Methods section and in Figure 1. Expected counts as calculated with estimated marginal means show significant between-groups and within-group differences, with lower expected counts in the IMT group compared to the steroids as needed group and in year 2 compared to year 1 (all $P < .05$).

a more robust improvement in VA, which stabilized during the 2 years of observation. This result can be explained by the lower number of iCNV reactivations observed in this group. Frequent recurrences of exudation, regardless of the causative mechanism underlying the formation of CNV, have been strongly linked to worse anatomical and functional outcomes.^{2,7,13,27,28} Although better visual outcomes are usually achieved with proactive anti-VEGF injection regimens in neovascular age-related macular degeneration, our study suggests that the same can be obtained with IMT in the context of MFC complicated by iCNV.

Unlike CNV caused by neovascular age-related macular degeneration, iCNV has usually demonstrated good responses to reactive, as-needed treatment regimens. In the current study, there were similar outcomes with less need for injections by avoiding the loading phase of 3 monthly injections in these patients.^{1,2,21,27,29} Consistent with the as-needed treatment pattern, the very similar RRs for iCNV reactivation and anti-VEGF injection in our study reflect the reactive nature of this regimen, in which treatment is administered only when symptomatic or overt exudative ac-

tivity is detected.^{1,21} Subjects in the IMT cohort achieved longer disease-free periods, with a lower incidence rate of iCNV reactivation, and significantly fewer anti-VEGF injections needed to control the neovascular lesion. These results translated into a lower exposure of the IMT patients to the risk for serious albeit rare complications of anti-VEGF intravitreal injections such as infective endophthalmitis, retinal detachment, or cataract formation.³⁰ Although health economic assessments are unavailable for MFC complicated by iCNV because of the rarity of the condition, it is reasonable to assume that treatment strategies using IMT to decrease the long-term rate of reactivations and the need for anti-VEGF injections are a cost-effective solution that additionally decreases the treatment burden for the typically young, working-age MFC patient.

Oral prednisone at a maintenance dose of <7.5 mg/d is safe for the intermediate term: the Multicenter Uveitis Steroid Treatment (MUST) Trial and Follow-up Study demonstrated that oral steroids and immunomodulatory drugs can be given safely for up to 7 years with no evident increased risk of systemic side effects.³¹ However, large cumulative doses of oral steroids expose patients to increased risks

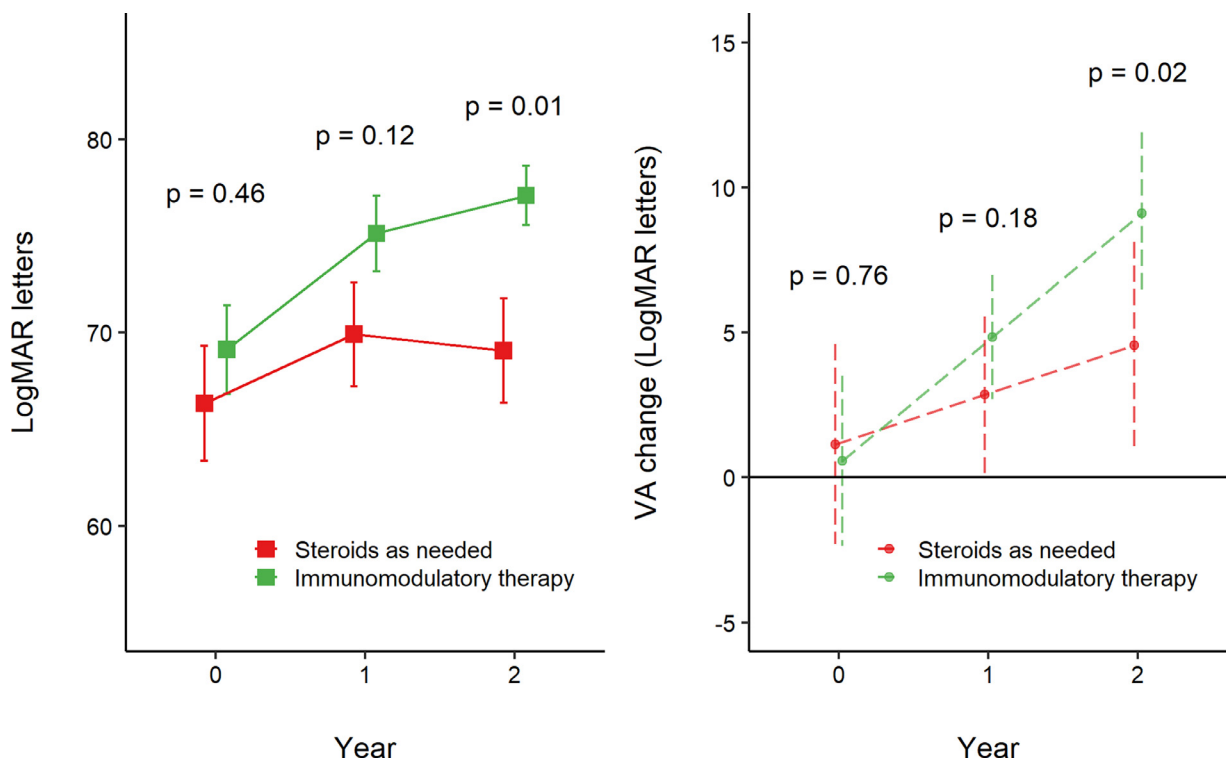


FIGURE 3. Visual acuity (VA) trends over 2 years of follow-up. (Left panel) VA trends between the immunomodulatory therapy (IMT) group and the steroids as needed group over the 2-year follow-up. Solid squares represent the mean VA at each year; error bars extend for 1 standard error of the mean. P values for t tests comparing the average VA between the 2 groups at each interval are reported. (Right panel) The shaded, dashed lines represent the estimated change in VA (95% CI) over time, adjusted for confounding variables. P values derived from contrasts of estimated marginal means from a linear mixed model are reported at each interval. Baseline VA, baseline age, and the interaction between time and treatment arm were significantly associated with overall VA. The difference in slope between the 2 dashed lines represents the estimated difference in VA gain between the IMT group and the steroids as needed group, corresponding to +2.5 logMAR letters per year (95% CI, 0.1-5) in favor of the IMT group. See Supplementary Table 2 for detailed β -coefficients and 95% CIs.

of cardiovascular disease, osteoporosis, and hyperglycemia requiring medical therapy.^{25,32} Furthermore, in a single-centre retrospective cohort study by Thorne et al,³³ prednisone >10 mg/d was found to reduce the risk of structural complications of MFC associated with visual loss, but doses of <10 mg/d were not, indicating that a safe dose of oral corticosteroids alone was ineffective and that immunosuppression should be considered as part of the initial regimen.^{12,13,25,26} In our study, the most commonly used IMT drug was mycophenolate, an anti-metabolite with an excellent safety profile. Among conventional immunosuppressive drugs, mycophenolate had the highest 12-month, single-agent success in uveitis control in the Systemic Immunosuppressive Therapy for Eye Diseases (SITE) Cohort Study,^{25,34} whereas in the First-line Antimetabolites as Steroid-sparing Treatment (FAST) Trial mycophenolate did not result in superior control of inflammation compared with methotrexate.³⁵ Mycophenolate is usually highly effective in inducing MFC remission, with reported

rates of successful inflammation control and oral prednisone <10 mg/d in 88% to 95% of patients at 2 years of follow-up.^{12,36} Nevertheless, the necessity for dose escalation or for the addition of a second immunosuppressive drug is not uncommon in MFC, and less than 10% to 50% of patients are able to discontinue oral steroids completely.^{12,36} In our practice, MFC patients achieving good control of inflammation with standard doses of mycophenolate frequently continue to take very low doses of oral steroids, typically 2.5 to 5 mg/d, a combination that we have found to ensure optimal rates of long-term disease-free remission.

Because of the heterogeneity of treatment in the IMT group in our study, it was not possible to draw conclusions on the effect of different IMT regimens on iCNV activity. In clinical practice, IMT treatment is frequently modulated according to the severity of the underlying inflammation, with patients affected by more active disease requiring multiple drugs or high-dosage regimens.²⁵ In the present cohort study, we found that a relatively small excess number of re-

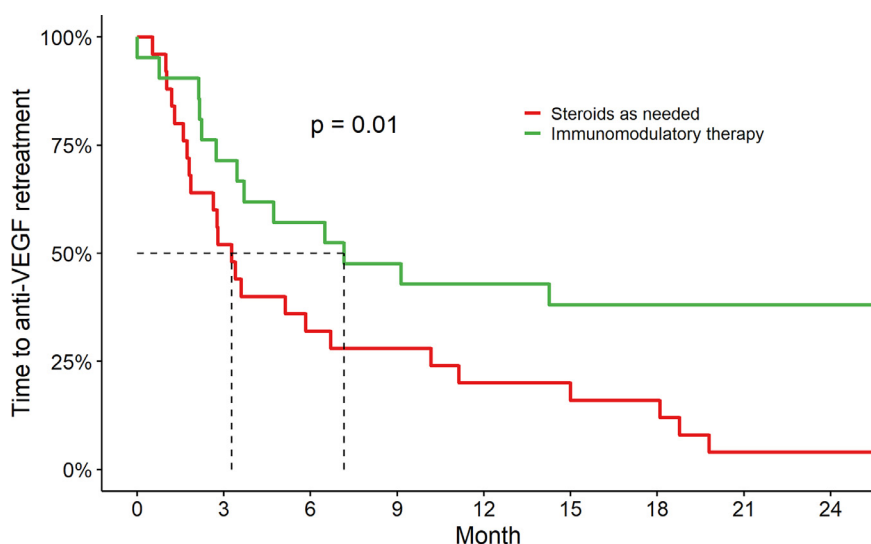


FIGURE 4. Survival curves for anti-vascular endothelial growth factor (anti-VEGF) reinjection. Kaplan–Meier estimates of the time to the first anti-VEGF reinjection after the start of the observation window of the study. The dashed lines indicate the median time to reinjection in the 2 cohorts. A log-rank test showed that a significant difference in the survival trend could be identified between the IMT group and the steroids as needed group.

activations in the steroids as needed cohort over a follow-up of 2 years was sufficient to determine inferior visual outcomes compared to those in the IMT cohort. Regardless of the type of IMT regimen, our findings suggest that IMT is still to be preferred over a steroid as needed strategy to prevent recurrences of the underlying inflammation and, consequently, iCNV reactivations. In fact, given that MFC is a chronic disease that mainly affects young to middle-aged individuals,^{2,7,12} the difference in iCNV reactivations will invariably increase over time without adequate immunosuppressive treatment aimed at controlling the inflammation, lowering the risk of iCNV reactivations, and preventing further vision loss. Moreover, the importance of tight control of inflammation does not exclusively pertain to patients with MFC complicated by iCNV, but also patients who present only with atrophic scars of previous MFC foci. In a recent paper, our group demonstrated how relapses of inflammation within or at the margin of MFC foci led to significantly greater expansion rates of chorioretinal atrophy compared to foci that did not show signs of reactivations.¹⁰ In fact, we found that for each additional reactivation observed through a 4-year follow-up, the expansion rate of individual atrophic foci increased by over 20%. Complementing our previous findings, in this cohort study we have presented compelling evidence for the need of adequate immunomodulatory treatment to limit both the exudative and the atrophic complications of MFC.

Limitations of this study are mainly attributable to its design. Given its observational retrospective nature, no control or standardization of the treatment administered to the subjects was possible, with likely inter-patient and inter-location variability. Consequently, patients in the IMT group could be on more than one IMT drug, or they could

be concomitantly taking low-dose oral corticosteroids; patients in the steroids as needed group could be on variable dosages of oral corticosteroids.

It could be argued that, in the absence of randomization, patients treated with IMT could be those with a more aggressive clinical picture. This is not the case, as treatment depended only on the referring physician, with some practitioners preferring high-dose systemic steroids and others being more confident with the use of IMT. Furthermore, if IMT had indeed been reserved for more severe cases, then the better outcomes achieved by this group would only strengthen the validity of our findings.

Even though the majority of the patients in the IMT cohort were treated with mycophenolate, we could not control for confounding variables such as treatment switches or multi-drug therapies, and the study was not powered enough to draw conclusions regarding different IMT drugs. We therefore refrained from making any comparisons between different IMT regimens, limiting our analysis to treatment outcomes of the IMT and steroids as needed cohorts.

Anti-VEGF injections could also differ among subjects, even though multiple studies suggest that the reactivations of iCNV are not significantly affected by the anti-VEGF use or by the switch between drugs.^{7,37-40}

Strengths of this study include the relatively large number of patients, considering the low prevalence of the disease, as well as the matched, historical cohort design, which permitted us to estimate the incidence rate of iCNV recurrence and its relative risk between patients exposed and not exposed to IMT therapy.¹⁸ The matched design also helped to reduce as much as possible the variability between groups associated with diminishing iCNV activity.¹

The historical cohort approach allowed us to present reasonable evidence of the efficacy of IMT therapy for a condition the low prevalence of which prevents researchers from planning more robust studies such as randomized controlled trials.^{8,19}

In conclusion, we found that, over 2 years of follow-up, IMT significantly reduced the number of iCNV reactivations and need for anti-VEGF injections in eyes with MFC, allowing for better VA gains over time. These findings suggest that IMT should be recommended in MFC patients not only to decrease inflammatory reactivations but also to limit the structural and functional damage induced by iCNV, when present. Although IMT surely implies the need for systemic side effects monitoring, the better functional outcomes and the reduced need for anti-VEGF injections strongly favor this approach over repeated courses of high-dose systemic steroids, especially in patients with bilateral involvement.

CREDIT AUTHORSHIP CONTRIBUTION STATEMENT

Matteo Airdi: Writing – review & editing, Writing – original draft, Visualization, Validation, Software, Project

administration, Methodology, Investigation, Formal analysis, Data curation, Conceptualization. **Davide Monteduro:** Writing – review & editing, Writing – original draft, Methodology, Investigation, Formal analysis, Data curation, Conceptualization. **Giovanni Tondini:** Resources, Methodology, Investigation, Data curation. **Francesco Pichi:** Writing – review & editing, Resources, Methodology, Data curation, Conceptualization. **Luca De Simone:** Writing – review & editing, Methodology, Investigation, Data curation, Conceptualization. **Elisa Cornish:** Writing – review & editing, Methodology, Investigation, Data curation, Conceptualization. **Giuseppe Casalino:** Writing – review & editing, Methodology, Investigation, Data curation, Conceptualization. **Federico Zicarelli:** Writing – review & editing, Methodology, Investigation, Data curation, Conceptualization. **Marta Oldani:** Writing – review & editing, Methodology, Investigation, Data curation, Conceptualization. **Giovanni Staurengi:** Writing – review & editing, Methodology, Investigation, Data curation, Conceptualization. **Peter McCluskey:** Writing – review & editing, Methodology, Investigation, Formal analysis, Data curation, Conceptualization. **Luca Cimino:** Writing – review & editing, Methodology, Investigation, Data curation, Conceptualization. **Alessandro Invernizzi:** Writing & editing, Writing – original draft, Validation, Supervision, Methodology, Investigation, Formal analysis, Data curation, Conceptualization.

Funding/Support: This study received no funding. All authors report no financial disclosures. All authors attest that they meet the current ICMJE criteria for authorship.

REFERENCES

1. Invernizzi A, Pichi F, Symes R, et al. Twenty-four-month outcomes of inflammatory choroidal neovascularisation treated with intravitreal anti-vascular endothelial growth factors: a comparison between two treatment regimens. *Br J Ophthalmol*. 2020;104(8):1052–1056.
2. Erba S, Cozzi M, Xhepa A, et al. Distribution and progression of inflammatory chorioretinal lesions related to multifocal choroiditis and their correlations with clinical outcomes at 24 months. *Ocul Immunol Inflamm*. 2022;30(2):409–416.
3. Zicarelli F, Azzolini C, Cornish E, et al. Optical coherence tomography features of choroidal neovascularization and their correlation with age, gender, and underlying disease. *Retina*. 2021;41(5):1076–1083.
4. Niederer RL, Gilbert R, Lightman SL, Tomkins-Netzer O. Risk factors for developing choroidal neovascular membrane and visual loss in punctate inner choroidopathy. *Ophthalmology*. 2018;125(2):288–294.
5. Amer R, Priel E, Kramer M. Spectral-domain optical coherence tomographic features of choroidal neovascular membranes in multifocal choroiditis and punctate inner choroidopathy. *Graefes Arch Clin Exp Ophthalmol*. 2015;253(6):949–957.
6. Grossniklaus HE, Hutchinson AK, Capone A, Woolfson J, Lambert HM. Clinicopathologic features of surgically excised choroidal neovascular membranes. *Ophthalmology*. 1994;101(6):1099–1111.
7. Agarwal A, Invernizzi A, Singh RB, et al. An update on inflammatory choroidal neovascularization: epidemiology, multimodal imaging, and management. *J Ophthalmic Inflamm Infect*. 2018;8(1):13.
8. Kramer M, Axer-Siegel R, Jaouni T, et al. Bevacizumab for choroidal neovascularization related to inflammatory diseases. *Retina*. 2010;30(6):938–944.
9. Chen SN, Chen YL, Yang BCL. Long-term outcome of punctate inner choroidopathy or multifocal choroiditis with active choroidal neovascularization managed with intravitreal bevacizumab. *Ocul Immunol Inflamm*. 2020;28(1):33–38.
10. Airdi M, Zicarelli F, Forlani V, et al. Correlation between inflammatory foci reactivation and atrophy growth in eyes with idiopathic multifocal choroiditis. *Retina*. 2023;43(3):472–480.
11. Ganesh S, Ahmed A, Biswas J. Analysis of the clinical profile and management of inflammatory choroidal neovascular membranes in uveitic eyes: a study from a tertiary referral center. *Ocul Immunol Inflamm*. 2019;27(3):424–434.

12. de Groot EL, ten Dam-van Loon NH, de Boer JH, Ossewaarde-van Norel J. The efficacy of corticosteroid-sparing immunomodulatory therapy in treating patients with central multifocal choroiditis. *Acta Ophthalmol.* 2020;98(8):816–821.
13. Neri P, Pichi F, Pirani V, Arapi I. Systemic immunosuppression is highly effective in the long-term control of inflammatory non-infectious uveitic choroidal neovascularization: a comparative study. *Ocul Immunol Inflamm.* 2021;29(6):1132–1136.
14. Chen YC, Chen YL, Chen SN. Chorioretinal atrophy in punctate inner choroidopathy/multifocal choroiditis: a five-year follow-up study. *Ocul Immunol Inflamm.* 2022;30(2):270–275.
15. Papisavvas I, Neri P, Mantovani A, Herbolt CP. Idiopathic multifocal choroiditis (MFC): aggressive and prolonged therapy with multiple immunosuppressive agents is needed to halt the progression of active disease. An offbeat review and a case series. *J Ophthalmic Inflamm Infect.* 2022;12(1):2.
16. de Groot EL, Ossewaarde-van Norel J, Ho L, ten Dam-van Loon NH, de Boer JH. The efficacy of adalimumab in treating patients with central multifocal choroiditis. *Am J Ophthalmol Case Rep.* 2020;20:100921.
17. Shmueli O, Amer R. Outcomes of adalimumab therapy in refractory punctate inner choroidopathy and multifocal choroiditis. *Graefes Arch Clin Exp Ophthalmol.* 2022;260(6):2013–2021.
18. Klebanoff MA, Snowden JM. Historical (retrospective) cohort studies and other epidemiologic study designs in perinatal research. *Am J Obstet Gynecol.* 2018;219(5):447–450.
19. Kempen JH, Daniel E, Gangaputra S, et al. Methods for identifying long-term adverse effects of treatment in patients with eye diseases: the Systemic Immunosuppressive Therapy for Eye Diseases (SITE) Cohort Study. *Ophthalmic Epidemiol.* 2008;15(1):47–55.
20. von Elm E, Altman DG, Egger M, et al. The Strengthening the Reporting of Observational Studies in Epidemiology (STROBE) statement: guidelines for reporting observational studies. *Lancet.* 2007;370(9596):1453–1457.
21. Lai TYY, Staurenghi G, Lanzetta P, et al. Efficacy and safety of ranibizumab for the treatment of choroidal neovascularization due to uncommon cause: twelve-month results of the MIN-ERVA Study. *Retina.* 2018;38(8):1464–1477.
22. Glynn RJ, Buring JE. Ways of measuring rates of recurrent events. *BMJ.* 1996;312(7027):364–367.
23. Atan D, Fraser-Bell S, Plskova J, et al. Punctate inner choroidopathy and multifocal choroiditis with panuveitis share haplotypic associations with IL10 and TNF loci. *Invest Ophthalmol Vis Sci.* 2011;52(6):3573–3581.
24. de Groot EL, Ossewaarde-van Norel J, de Boer JH, et al. Association of risk variants in the CFH gene with elevated levels of coagulation and complement factors in idiopathic multifocal choroiditis. *JAMA Ophthalmol.* 2023;141(8):737–745.
25. Jabs DA. Immunosuppression for the uveitides. *Ophthalmology.* 2018;125(2):193–202.
26. Vienne-Jumeau A, Brézin AP, Seminel M, Ribeau-Saindelle F, Bousquet E. Corticosteroids decrease the incidence and activity of choroidal neovascularization in patients with punctate inner choroidopathy or multifocal choroiditis. *Ocul Immunol Inflamm.* 2023;1–7 Epub ahead of print. doi:10.1080/09273948.2023.2181189.
27. Cozzi M, Monteduro D, Esposito RA, et al. Lesion area progression in eyes with neovascular age-related macular degeneration treated using a proactive or a reactive regimen. *Eye.* 2024;38(1):161–167.
28. Romano F, Cozzi E, Airaldi M, et al. Ten-year incidence of fibrosis and risk factors for its development in neovascular age-related macular degeneration. *Am J Ophthalmol.* 2023;252:170–181.
29. Mansour AM, Arevalo JF, Ziemssen F, et al. Long-term visual outcomes of intravitreal bevacizumab in inflammatory ocular neovascularization. *Am J Ophthalmol.* 2009;148(2):310–316.
30. Falavarjani KG, Nguyen QD. Adverse events and complications associated with intravitreal injection of anti-VEGF agents: a review of literature. *Eye (Lond).* 2013;27(7):787–794.
31. Writing Committee for the Multicenter Uveitis Steroid Treatment (MUST) Trial and Follow-up Study Research Group. Association between long-lasting intravitreal fluocinolone acetonide implant vs systemic anti-inflammatory therapy and visual acuity at 7 years among patients with intermediate, posterior, or panuveitis. *JAMA.* 2017;317(19):1993–2005.
32. Udoetuk JD, Dai Y, Ying GS, et al. Risk of corticosteroid-induced hyperglycemia requiring medical therapy among patients with inflammatory eye diseases. *Ophthalmology.* 2012;119(8):1569–1574.
33. Thorne JE, Wittenberg S, Jabs DA, et al. Multifocal choroiditis with panuveitis: incidence of ocular complications and of loss of visual acuity. *Ophthalmology.* 2006;113(12):2310–2316.
34. Daniel E, Thorne JE, Newcomb CW, et al. Mycophenolate mofetil for ocular inflammation. *Am J Ophthalmol.* 2010;149(3):423–432.
35. Rathinam SR, Gonzales JA, Thundikandy R, et al. Effect of corticosteroid-sparing treatment with mycophenolate mofetil vs methotrexate on inflammation in patients with uveitis: a randomized clinical trial. *JAMA.* 2019;322(10):936–945.
36. Goldberg NR, Lyu T, Moshier E, Godbold J, Jabs DA. Success with single-agent immunosuppression for multifocal choroidopathies. *Am J Ophthalmol.* 2014;158(6):1310–1317.
37. Kim M, Lee J, Park YG, Park YH. Long-term analysis of clinical features and treatment outcomes of inflammatory choroidal neovascularization. *Am J Ophthalmol.* 2022;233:18–29.
38. Cornish KS, Williams GJ, Gavin MP, Imrie FR. Visual and optical coherence tomography outcomes of intravitreal bevacizumab and ranibizumab in inflammatory choroidal neovascularization secondary to punctate inner choroidopathy. *Eur J Ophthalmol.* 2011;21(4):440–445.
39. Fine HF, Zhitomirsky I, Freund KB, et al. Bevacizumab (Avastin) and ranibizumab (Lucentis) for choroidal neovascularization in multifocal choroiditis. *Retina.* 2009;29(1):8–12.
40. Zina S, Khochtali S, Invernizzi A, et al. Results of intravitreal anti-vascular endothelial growth factor therapy in inflammatory choroidal neovascularization. *J Curr Ophthalmol.* 2021;33(1):68–74.