

# Reconstruction and Implant Rehabilitation of the Completely Edentulous Maxilla and Mandible Utilizing Iliac Crest Autogenous Block Grafts: A Clinical Case-Report

Poli Pier Paolo<sup>1</sup>, Nguyen Katina<sup>2</sup>, Herford Alan Scott<sup>2</sup>

<sup>1</sup>Department of Dental Implants, U.O.C. Maxillofacial Surgery and Odontostomatology, Fondazione IRCCS Cà Granda Ospedale Maggiore Policlinico, University of Milan, Milan, Italy. <sup>2</sup>Department of Oral and Maxillofacial Surgery, Loma Linda University, Loma Linda, California, USA.

## Abstract

The number of completely edentulous patients has been increasing over the years due to an extended life expectancy. This debilitating condition is frequently associated with severe bone resorption which complicates predictable implant rehabilitation. This report shows the clinical outcome of an edentulous geriatric patient treated with iliac crest appositional autogenous bone block grafts and subsequent implant-supported bar-retained overdentures in a staged-approach. An adequate quality and quantity of newly formed bone allowed for ideal implant placement. After the surgical procedures the healing proceeded uneventfully and no adverse events were encountered. The final prosthesis improved the oral-health quality of life of the patient resulting in a high satisfaction level as well as low morbidity. After a one-year follow-up period, no clinical and radiographic signs of inflammation and infection were reported in either jaw, stressing the reliability of this procedure even in geriatric patients.

*Key Words: Pre-prosthetic surgery, Iliac crest, Autologous grafts, Dental implants, Overdentures*

## Introduction

During the 1990s, edentulism was included by the World Health Organization among physical and mental impairments, defining it as an oral handicap due to its debilitating effect on the patient [1]. Total edentulism is frequently associated with severe bone resorption that initially affects the alveolar process and gradually involves the underlying basal bone. This unfavorable anatomical situation leads to functional problems such as: insufficient retention of the conventional prosthesis, pain, difficulties with eating and speech, loss of soft tissue support and an altered aging aspect of the face, in addition to psychological and social discomforts [2,3]. An implant-supported overdenture retained with a milled bar is associated with a high survival rate and excellent peri-implant condition showing clinical stability and retention comparable with those of a fixed prosthesis as well as prosthodontic advantages of a removable prosthesis [4,5]. This treatment option should be considered a predictable treatment option in case of total edentulism associated with severely resorbed jaws. With regard to number, two to six implants have been recommended for both an implant and an implant and tissue supported restoration [6-8], depending on multiple factors including the amount and quality of bone [9,10]. In anatomical conditions where the implant recipient site is characterized by minimal basal bone, pre-prosthetic surgery becomes mandatory to achieve an adequate quantity of hard tissue allowing for an ideal prosthetic-driven implant placement. Reconstruction of extremely resorbed jaws with cortico-cancellous autologous bone grafts prior to implant placement is considered a viable technique and has been recently advocated in cases of bar-retained overdenture rehabilitations [3,8,11,12], exhibiting its superiority when compared to other graft materials [13]. In addition to the functional improvement, implant-retained overdentures positively influence the oral-health related quality of life in the edentulous elderly population, and patient

satisfaction [14].

The aim of this present case-report is to share the management and clinical outcome of an edentulous geriatric patient, rehabilitated with iliac crest autogenous block grafts and implant-supported bar-retained overdentures in a staged approach.

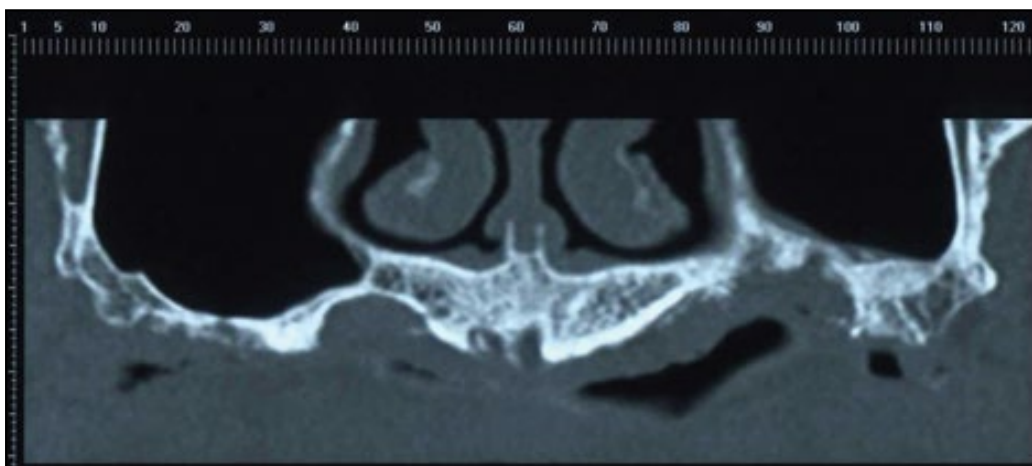
## Case presentation

A 72 year-old female with complete edentulism on both the upper and the lower jaws presented with the complaint of being unable to wear her upper and lower dentures. She expressed a desire to replace her old conventional prostheses with implant-supported overdentures due to functional and aesthetic problems. Previously the patient had undergone implant surgery elsewhere, however the implants failed likely as a consequence of untreated peri-implant infections. The implants were consequently removed which resulted in total edentulism with significant bone loss. This treatment led to severe atrophy of the alveolar process with a resorption pattern that extended to the basal bone.

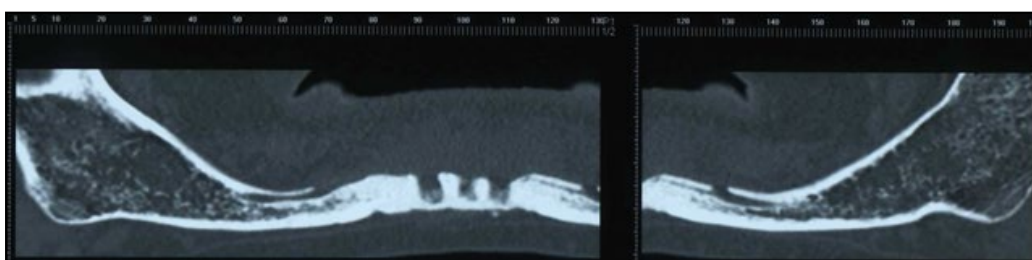
From a clinical point of view, the anatomical situation represented a class VI, according to the Cawood and Howell atrophy classification [15]. A reversed inter-arch horizontal relation was observed, caused by the physiological centripetal and centrifugal resorption pattern of the maxilla and the mandible respectively. The panoramic views on the CT scan (*Figures 1-2*) and the three-dimensional stereolithographic models (*Figures 3-4*) demonstrate the extreme atrophy of the jaws. Residual peri-implant defects could be observed in the upper and lower anterior areas. An informed consent including a discussion of all the possible treatment options was completed. The patient elected to undergo bone reconstruction by means of autologous iliac crest block grafts for implant placement purposes.

## Surgical procedure

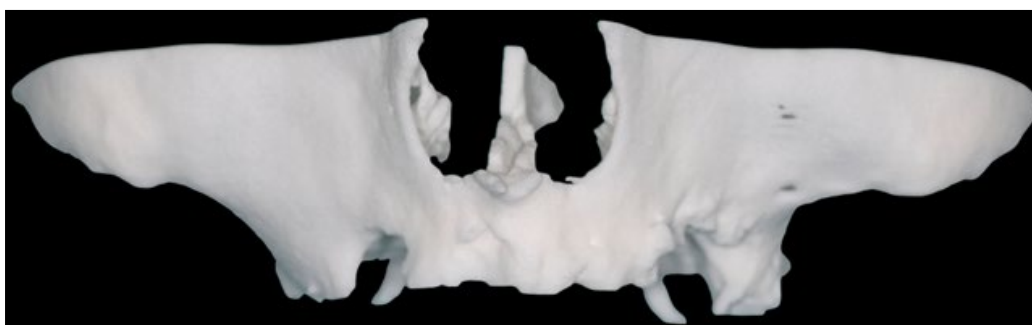
The reconstructive surgery was performed under general



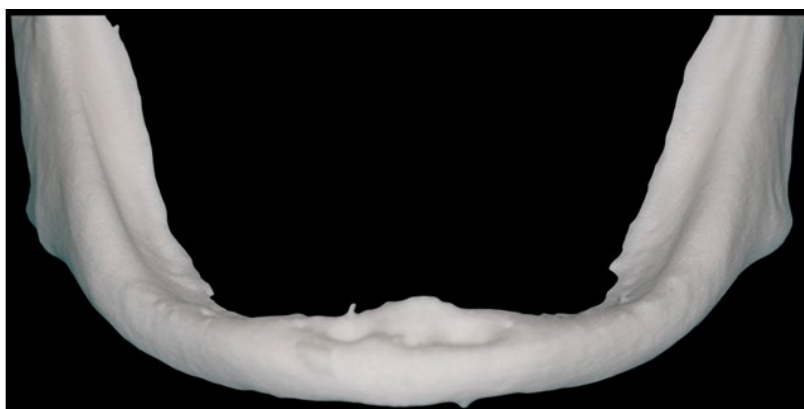*Figure 1. Pre-operative panorex examination of the upper jaw.*



*Figure 2. Pre-operative panorex examination of the lower jaw.*



*Figure 3. Pre-operative 1:1 scale stereolithographic model of the maxilla.*



*Figure 4. Pre-operative 1:1 scale stereolithographic model of the mandible.*

anesthesia and the same protocol was used for both jaws. The antero-superior edge of the left iliac crest was used to harvest two autogenous bone blocks. Local anesthesia was induced via infiltration using 4% articaine with 1:100.000 epinephrines and 4 mg of dexamethasone phosphate intramuscularly was injected at the surgical area to reduce the post-operative swelling.

For the maxilla, a mid-crestal incision was performed. The incision line was slightly lingualized on the distal aspect of

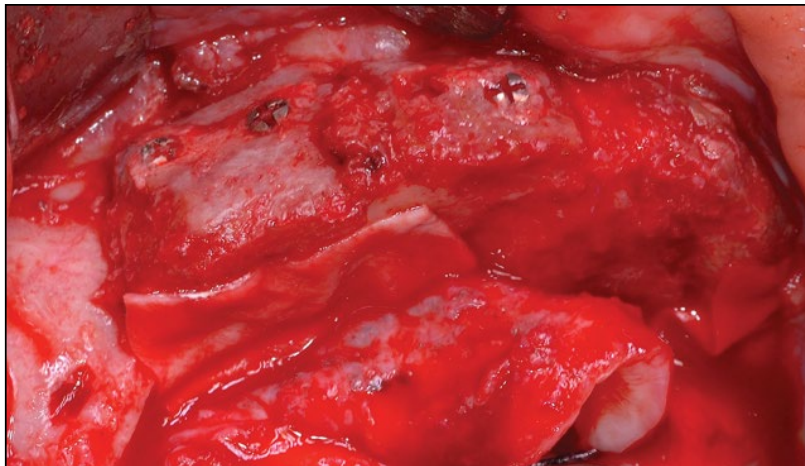
the mandibular basal bone to prevent possible injuries to the mental nerve. A full-thickness flap was carefully elevated to expose the anatomical defect and identify the neurovascular bundles. Cortical perforations of the recipient bed were made with a 1.5 mm diameter carbide bur to stimulate bleeding in order to provide a pathway for the marrow progenitor cells and blood vessels to reach the bone graft site. Autogenous block grafts were then pre-contoured on the stereolithographic model and secured with titanium screws (KLS Martin,

Tuttlingen, Germany) at the recipient bed to replace the missing bone. The bone blocks were then covered with the same morcellized autograft, which was maintained in situ with resorbable collagen membranes (Biogide®, GeistlichPharma AG, Wolhusen, Switzerland) (*Figures 5 and 6*). The surgical wound was sealed with horizontal mattress sutures and simple interrupted sutures (Vicryl®, Ethicon Inc., Somerville, NJ, USA), after having adequately released the adjacent flaps to obtain closure without tension. A post-operative panoramic radiograph was obtained to verify the proper position of the bone blocks (*Figure 7*). Control of post-operative pain was obtained via oral administration of 500 mg of paracetamol and 30 mg of codeine phosphate. The patient was instructed to rinse with 0.2% chlorhexidine three times a day starting one week before the surgery up until suture removal. The sutures

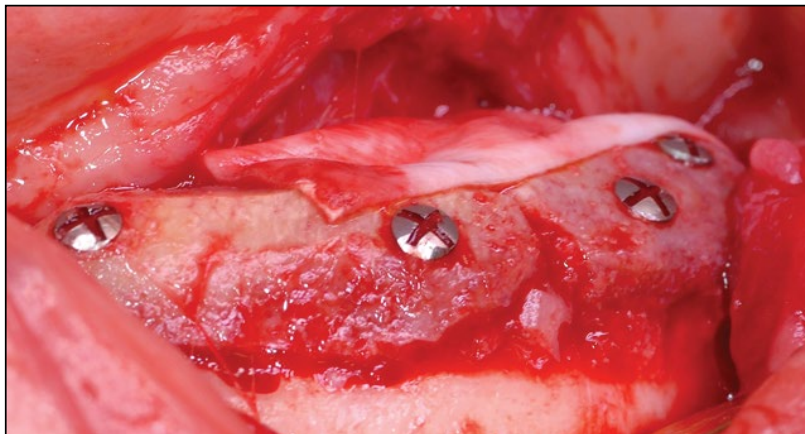
were removed after 14 days and the patient was instructed to not wear their old dentures for a period of 4 weeks. At a subsequent time, the upper and the lower prostheses were relined and the supporting areas above the grafts have been unloaded to prevent any possible ischemic reactions and micro-movements of the bone blocks as well as opening of the incisions over the grafted areas.

#### **Implant placement**

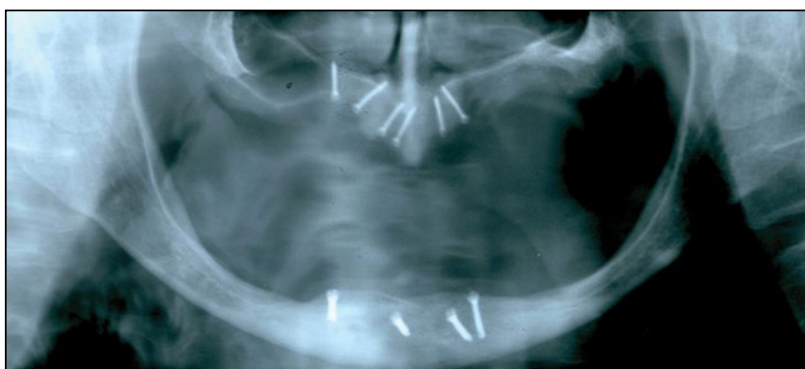After six months of healing, with no apparent complications, three-dimensional virtual reconstruction of the upper and the lower jaws were obtained that overlapped the pre and post-operative CT-scans in order to evaluate the amount of newly formed bone (*Figures 8 and 9*). This was clearly visible even in the stereolithographic models (*Figures 10 and 11*). The treatment plan developed includes a plan to proceed



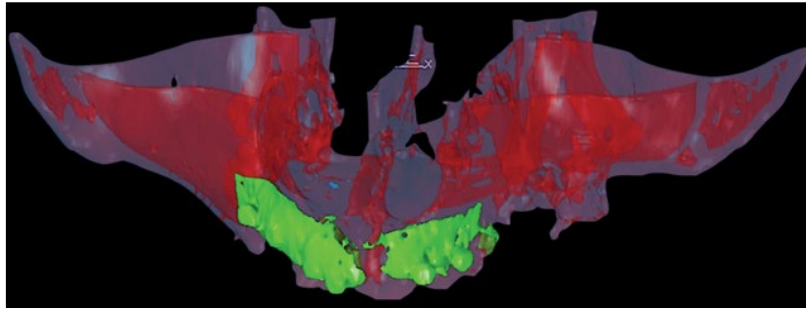
**Figure 5.** Autologous bone blocks grafted on the maxilla. Particulated autogenous graft maintained in situ with resorbable collagen membranes was used to fill the gaps.



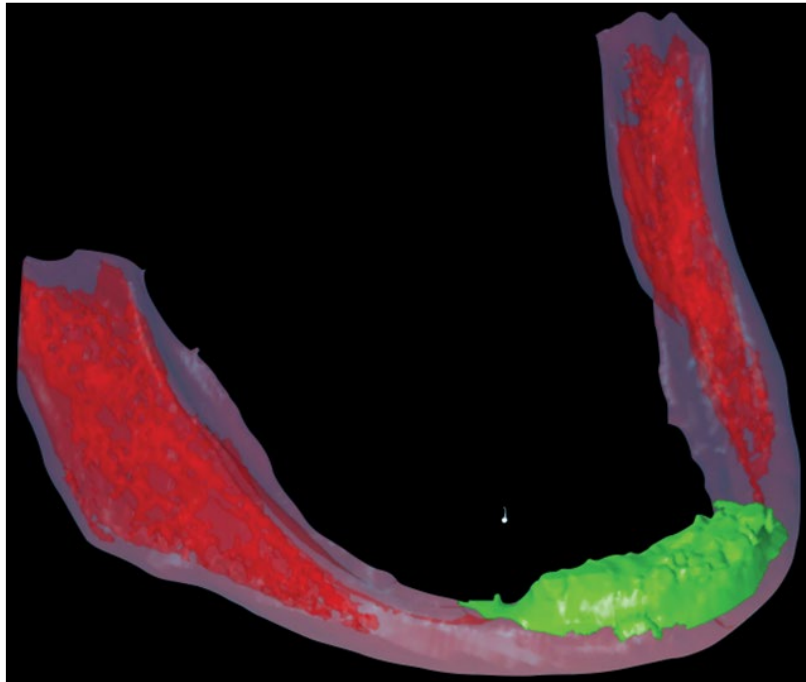
**Figure 6.** Autogenous bone blocks fixed in the interforaminal region. The same morcellized graft maintained in situ with bioabsorbable collagen membranes was used to cover the blocks.



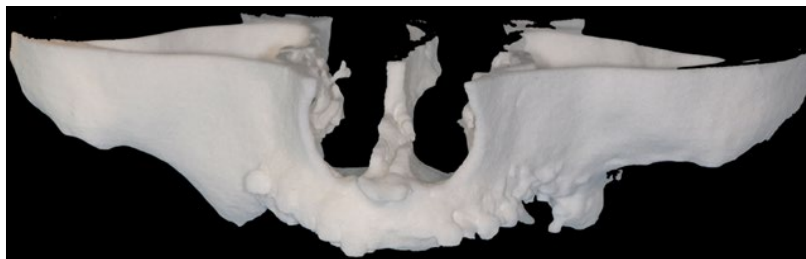
**Figure 7.** Post-operative orthopantomograph.



**Figure 8.** Three-dimensional reconstruction of the upper jaw, obtained overlapping the pre- and post-operative CT scans. The augmented bone is visible in green colour.



**Figure 9.** Superimposition of the pre- and post-operative CT scans on the lower jaw. The newly formed bone is clearly visible in green colour.



**Figure 10.** Post-operative stereolithographic model of the maxilla.



**Figure 11.** Post-operative stereolithographic model of the mandible.

with placement of four rough-surface implants in the pre-maxilla and in the mandibular interforaminal region. After the elevation of a full-thickness mucoperiosteal flap, the titanium screws were carefully removed and implants (blueSKY,

Bredent GmbH & Co.KG, Senden, Germany) were placed according to the manufacturer instructions in a prosthetically driven position. In the upper jaw, four total implants were placed; two 4.0 mm diameter by 10 mm length implants were

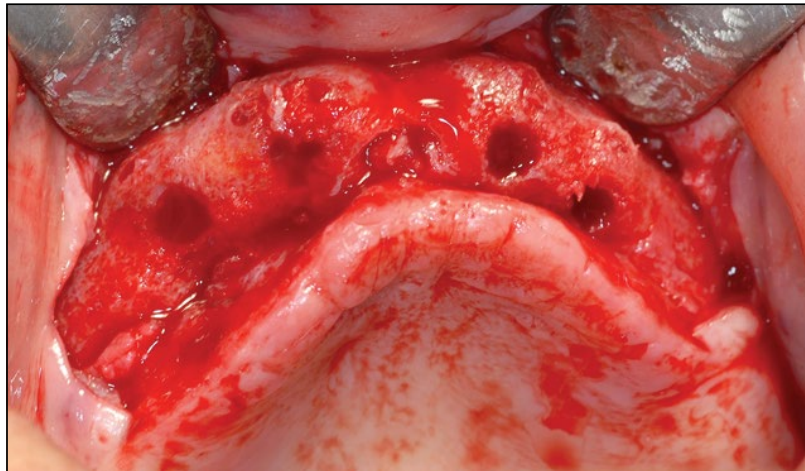

placed anteriorly, while two 4.0 mm diameter by 8 mm length implants were inserted posterior to these implants. In relation to the lower jaw, four 4.0 mm diameter and 10 mm length implants were placed (*Figures 12-15*). Wound closure was obtained primarily with vicryl horizontal mattress and simple interrupted sutures and the same previously reported post-operative care was adopted.

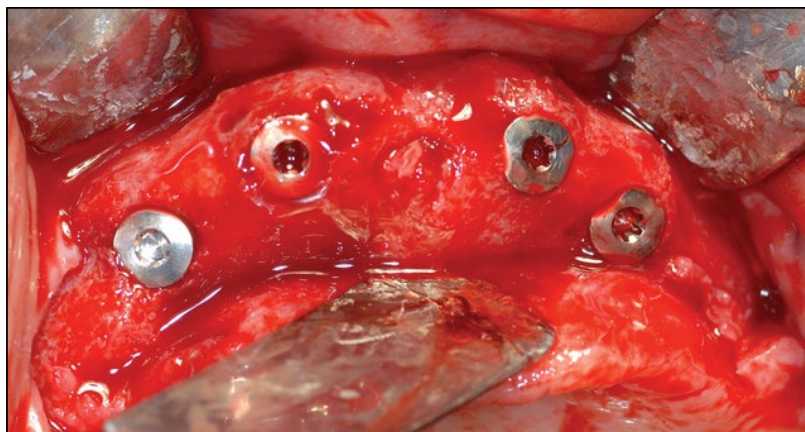
**Prosthetic rehabilitation**

The healing process was uneventful and the implants were left unloaded for 3 months. A panoramic radiograph was obtained to verify the osteointegration of the implants (*Figure 16*). Under local anesthesia, a limited incision was made to expose the implants and place healing abutments. Four weeks

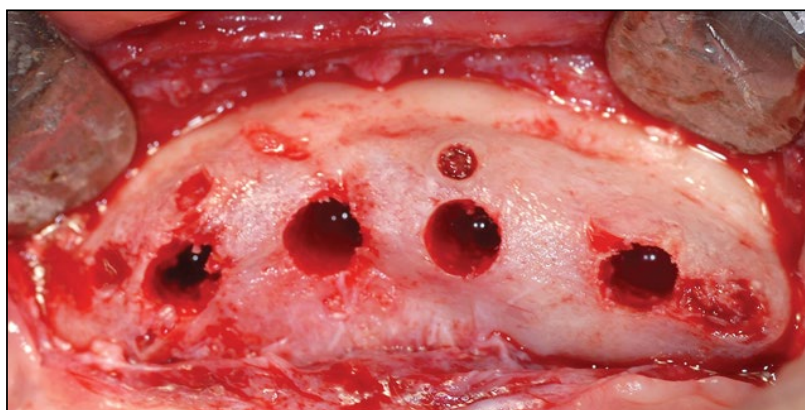
after placement of healing abutments, two milled bar-retained overdentures were delivered to the patient for the maxilla and the mandible, and subsequently the functional loading was started (*Figure 17*). The patient was on a strict oral hygiene recall protocol and underwent clinical evaluation every 6 months. A panoramic radiograph was taken at the follow-up evaluation one year later, showing physiological levels of the marginal bone without signs of peri-implant radiolucency (*Figure 18*). All of the implants appeared clinically stable and no signs of inflammation or infection were observed. A survival and success rate of 100% was reported at this time point (*Figure 19-24*).



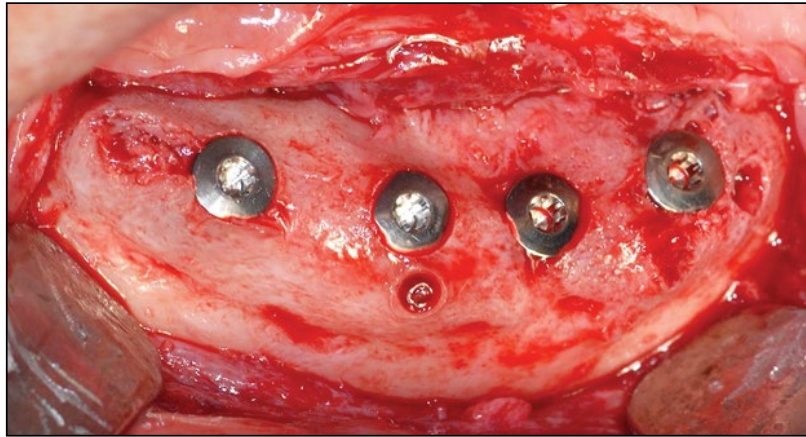
*Figure 12. Second-stage surgery on the upper jaw. Bleeding bone is visible through the implant preparations, highlighting the incorporation of the graft into the recipient bone.*



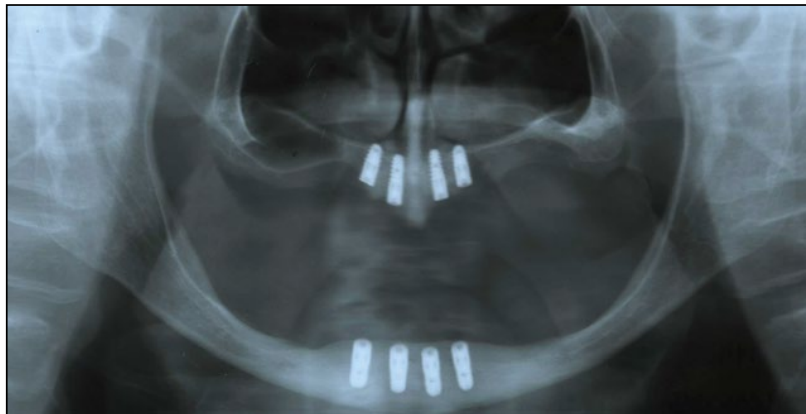
*Figure 13. Implant placement in the maxilla.*



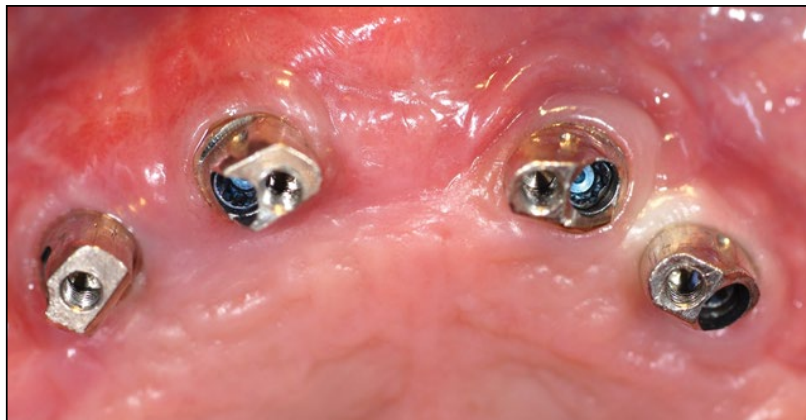
*Figure 14. Implant site preparation on the lower jaw. The newly formed bone has gone through a physiological remodelling and appears well integrated with the surrounding tissue.*



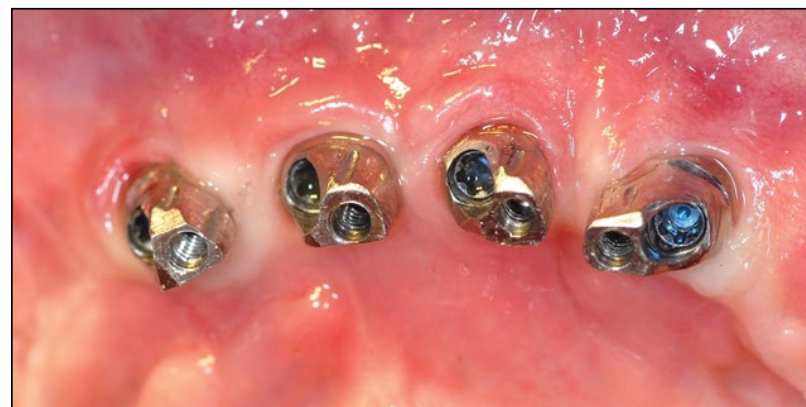*Figure 15. Four implants have been placed in the interforaminal region.*



*Figure 16. Post-operative orthopantomograph*



*Figure 17. Definitive implant abutments screwed in the upper jaw.*



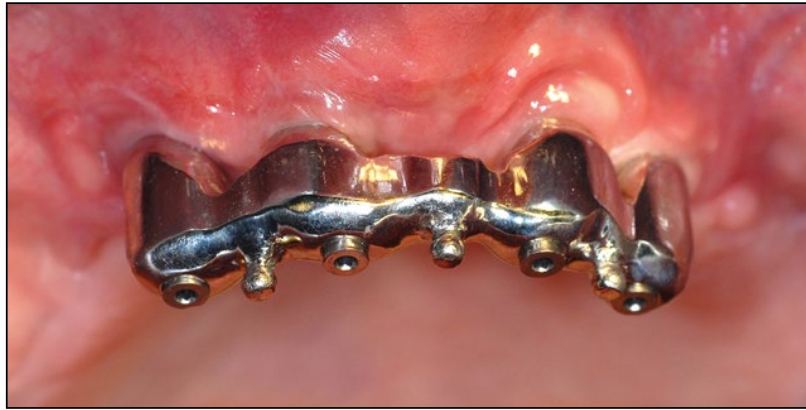*Figure 18. Definitive implant abutments fixed in the lower jaw.*

### **Discussion**

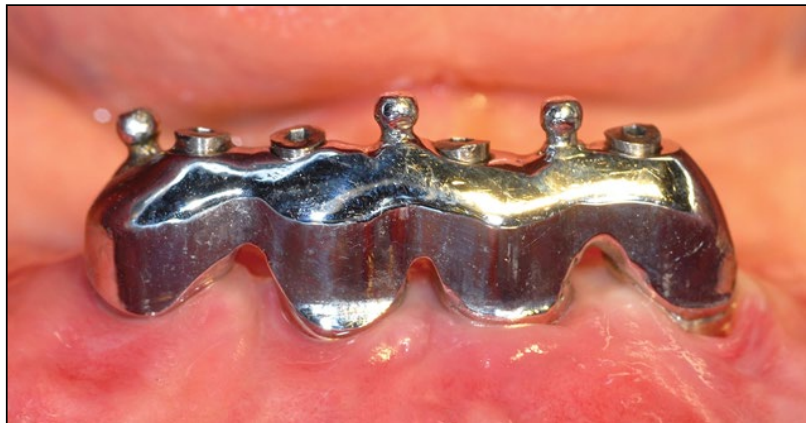In the present case-report, the concomitant use of autologous

bone block grafts and dental implants allowed for a successful rehabilitation of severe total edentulism with bar-retained

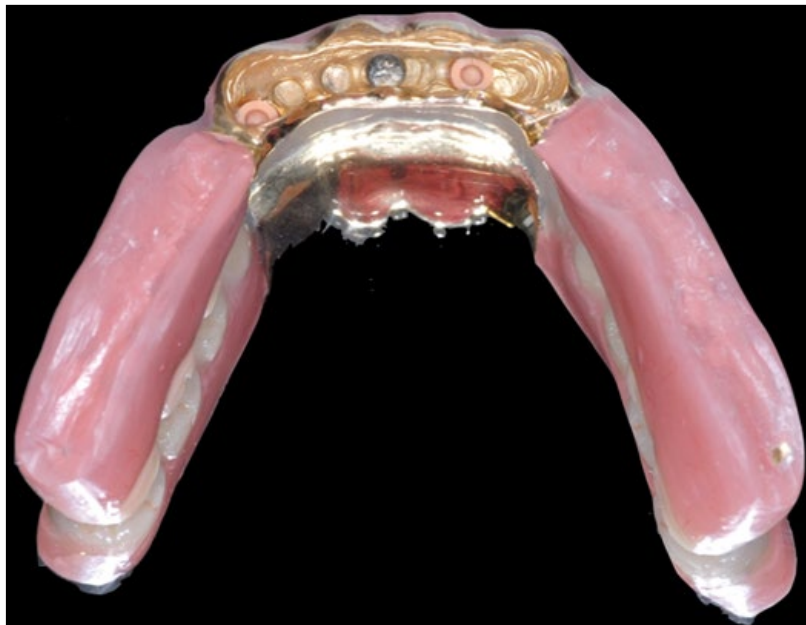



*Figure 19. Milled-bar fitted in the maxilla.*



*Figure 20. Superstructure fixed in the mandible.*

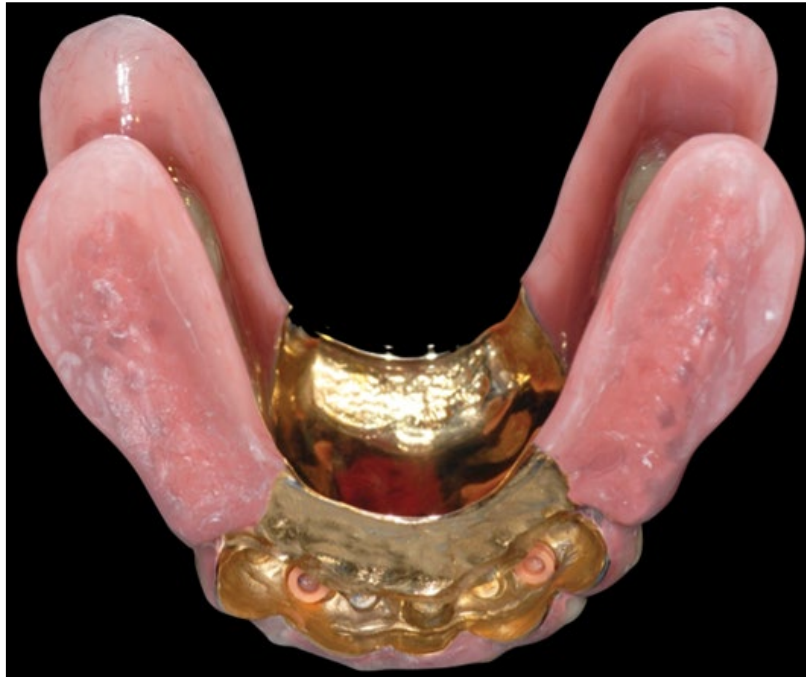

*Figure 21. Upper overdenture base with a metal-reinforced framework.*

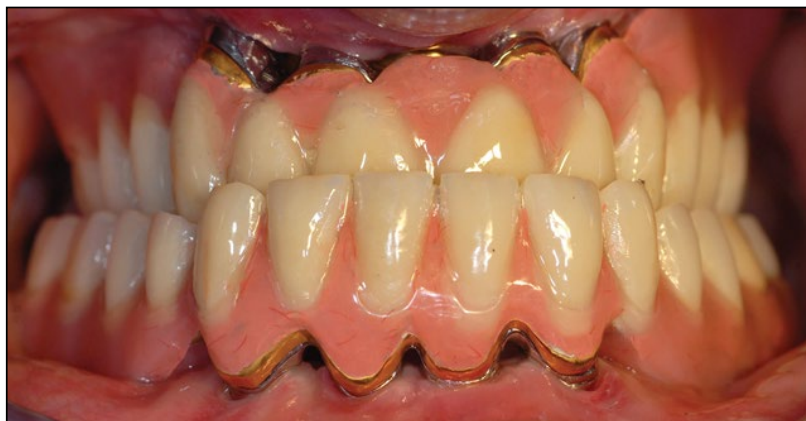overdentures, improving the oral-health related quality of life for the patient. The positive outcome was obtained by combining appositional autogenous grafts and maximal length implants to provide retention and stability to the overdentures and was comparable with those reported in recent studies [3,8,11].

Currently there is a trend toward minimally invasive surgical and prosthetic procedures especially when such protocols are able to improve patient satisfaction, which is one of the most important goals in oral rehabilitation [16].

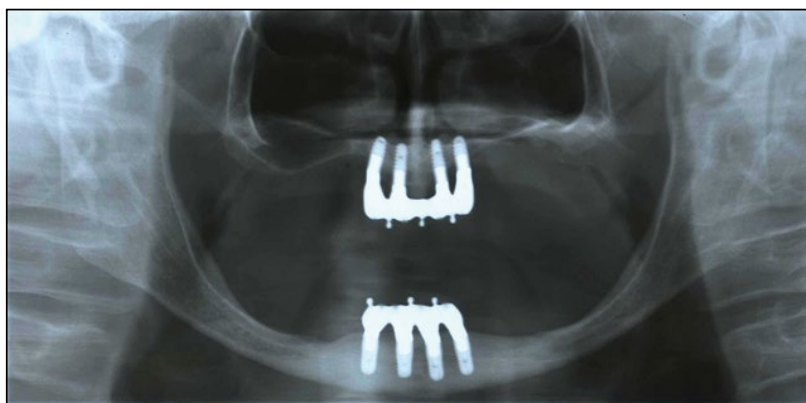
As a matter of fact, it has been recently deduced that patient satisfaction with graft-less solutions for implant rehabilitation of complete edentulism is generally high. However, a direct comparison with bone augmentation surgery could not be performed due to lack of data in the current literature and clinical heterogeneity within the studies [17]. For these reasons, the reversed inter-arch horizontal relation observed in this case report was maintained without incurring more invasive orthognathic surgeries, compensated with functional prosthetic rehabilitation. Nevertheless, clinical anatomical



*Figure 22. Definitive mandibular prosthesis reinforced with a metal framework.*



*Figure 23. Final implant-supported bar-retained overdenture rehabilitation.*



*Figure 24. One-year follow-up panoramic radiograph.*

situations presenting with extremely resorbed class VI jaws, according to Cawood and Howell atrophy classification [15], inevitably will require bone augmentation procedures for implant placement purposes. Particularly, in the case of bone height  $< 6$  mm, short implants could not be used and reconstructive procedures become mandatory before implant placement [18]. Although different allogeneic, xenogeneic and alloplastic grafts have been proposed to obtain an adequate three-dimensional bone volume for proper positioning of

endosseous implants, autologous bone is still considered the golden standard due to its intrinsic osteogenic, osteoinductive and osteoconductive properties [19]. Autografts can be collected from intraoral sites, however, in cases with defects  $> 2$  cm, an extraoral source should be considered due to greater availability of bone [20]. Despite the fact that intramembranous bone autografted in the cranio-facial region results in better volume maintenance [21] and higher degree of vital bone volume [22], enhancing not only the quantity



of bone tissue at the defect site, but also its quality when compared to endochondral sources [23]; in this case report the patient preferred an iliac crest harvesting procedure. The anterior iliac crest was therefore chosen for this patient as it provides the highest concentration of osteocompetent cells with adequate quantities of cortico-cancellous bone, in addition to the easy accessibility of the donor site and a relatively low morbidity [24,25]. When hip autografts are used in pre-prosthetic surgery for bone augmentation procedures, the implant survival rate may vary between 97.1% and 100% [26] whereas the success rate of implants placed in ridges reconstructed with appositional grafts could range from 72.8% to 97% after follow-up periods of 6 months to 10 years [27]. After a one-year follow-up, the survival and success rate was reported as 100% in this case study, which is in agreement with the above-mentioned literature reviews. This is likely attributed to several factors, including the management of the recipient site, the periosteum preservation, and the timing of implant placement.

The recipient site influences the revascularization process, which enables the integration and the maintenance of the bone blocks' vitality, hence reducing chances of graft infection and necrosis [28]. Block grafts could be fixed in three different recipient bed preparations: non-perforated, perforated and decorticated, and when compared interesting results have emerged. From a histological analysis, autogenous bone blocks were integrated with the receptor bed mainly in the perforated and decorticated groups probably due to a rapid revascularization process, which maintains the vitality of the grafts. Moreover, connective tissue was found between the graft and the non-perforated recipient bed, which jeopardizes the integration of the bone blocks [29]. In our opinion, decortication tends to extend the operation time and compromise the visibility in the operative field due to excess bleeding. The additional surgical trauma from decortication can cause loss of blood and bone substances, and has the potential to generate overheating via the drilling bur. For this reason we decided to perforate the recipient bed rather than decorticate it. In a recent study series, the influence of perforating the autogenous bone block and the recipient bed was investigated. Four groups were evaluated: a solid graft fixed in a non-perforated bed, a perforated graft in a perforated bed, a solid graft in a perforated bed and a perforated graft in a non-perforated bed. From a radiographic analysis using micro-CT scan reconstruction, the perforated graft fixed in the perforated bed exhibited the highest volume maintenance, with higher values of residual bone volume and cross sectional area. On the other hand, the solid block graft that was fixed onto the non-perforated recipient bed was not integrated after 8 weeks of healing, most likely due to an inadequate vascular supply [30]. The essential role of revascularization was subsequently supported histologically, confirming that cortical bone perforation helps the osteoclastic cutting cones to imitate the bone penetrating procedure in the bone-remodeling phase. This stage enhances capillary ingrowth, which in turn advances bone formation [31]. Clinically during the implant surgery, we noticed well-integrated newly formed bone, characterized by bleeding vessels incorporated within the remodeled grafts (*Figures 12,14*). This emphasizes

the importance of revascularization during the creeping substitution process, allowing for proper regeneration of an adequate quality and quantity of bone.

Another important issue is periosteal preservation, which appears to be an important factor in maintaining long-term bone volume stability in bone grafts. The periosteum has two important characteristics: osteogenic and vascular potential. Adeyemo et al. inspected the osteogenic potential in an experimental animal study. When a layer of intact host periosteum covered block grafts, islands of new bone within the periosteal tissue and above the cortex of the grafts could be detected after four weeks of healing. This particular event is normally absent in periosteum-excised specimens [32]. De Marco et al. demonstrated the vascular potential by treating block bone specimens with methylsalicylate in order to demarcate the vessels with a carbon black suspension. When e-PTFE membrane did not cover the blocks, blood vessels had penetrated the graft and extended across the entire graft, originating both from the recipient bed and from the suprapariosteal plexus. When e-PTFE membrane covered the blocks, newly formed vessels penetrated the periphery of the graft, with the exception of the surface covered by the membrane. For these reasons, the revascularization process took place earlier and was more intense and extensive when the autogenous bone block graft was covered only with periosteum, emphasizing the importance of this tissue on the grafts [33]. In this present case, a slow resorbable bilayer collagen membrane was used to take advantage of its double function: the porous inner surface facing the bone consists of collagen fibers in a loose arrangement, allowing osteoblasts to enter and promote bone formation; the outer surface facing soft tissue is dense and functions as a barrier to prevent epithelial cell ingrowth.

Timing could influence the success of treatment. Three months is considered a sufficient timespan to allow for incorporation of the avascular iliac bone graft before implant placement [34]. However, from a recent review of the literature, most studies preferred to wait 4 to 6 months before re-entry surgery [26]. Faria et al. compared simultaneous and delayed implant placement in an experimental study. Histologically, the bone to implant contact at the recipient bed and graft was higher in the delayed implant placement group. This led to higher stability of implants in the delayed approach when resonance frequency analysis was conducted, as demonstrated by the implant stability quotient values. There was lack of stability in the simultaneous implant group, which reported alteration to the graft's revascularization process, which may lead to bone resorption and fibrous union between the graft and resident bone. The authors concluded that the delayed implant protocol resulted in improved implant osseointegration and stabilization with larger amount of bone surrounding the implant when compared with findings using the simultaneous approach [35]. In this case report, the implant placement was performed after 6 months of healing, allowing for proper incorporation of the grafts.

## Conclusions

The outcome of this clinical and radiographic case report shows that the treatment of extremely resorbed jaws with autologous

appositional block grafts and implant placement in a staged approach that is rehabilitated with implant-supported bar-retained overdentures could be considered a valid therapeutic solution. After a one-year follow-up, physiological peri-implant bone resorption, clinical and radiological signs of inflammation and peri-implantitis were not observed. This case had 100% implant survival and success rate, stressing the reliability of this technique even in geriatric patients. After

treatment, the patient's reported oral-health related quality of life was greatly improved and a high level of satisfaction was obtained, which was considered the most important goal before starting rehabilitation.

### Acknowledgement

None declared.

### References

1. Kent G. Effects of osseointegrated implants on psychological and social well-being: A literature review. *Journal of Prosthetic Dentistry*. 1992; **68**: 515-518.
2. Stellingsma C, Vissink A, Meijer HJ, Kuiper C and Raghoebar GM. Implantology and the severely resorbed edentulous mandible. *Critical Reviews in Oral Biology & Medicine*. 2004; **15**: 240-248.
3. Kuoppala R, Kainulainen VT, Korpi JT, Sandor GK, Oikarinen KS. Outcome of treatment of implant-retained overdenture in patients with extreme mandibular bone resorption treated with bone grafts using a modified tent pole technique. *Journal of Oral Maxillofacial Surgery*. 2013; **71**: 1843-1851.
4. Krennmair G, Krainhofner M and Piehslinger E. Implant-supported mandibular overdentures retained with a milled bar: A retrospective study. *International Journal of Oral Maxillofacial Implants*. 2007; **22**: 987-994.
5. Bueno-Samper A, Hernandez-Aliaga M and Calvo-Guirado JL. The implant-supported milled bar overdenture: A literature review. *Medicina Oral, Patología Oral y Cirugía Bucal*. 2010; **15**: 375-378.
6. Rangert B, Jemt T and Jorneus L. Forces and moments on Branemark implants. *International Journal of Oral Maxillofacial Implants*. 1989; **4**: 241-247.
7. Hutton JE, Heath MR, Chai JY, Harnett J, Jemt T. Factors related to success and failure rates at 3-year follow-up in a multicenter study of overdentures supported by Branemark implants. *International Journal of Oral Maxillofacial Implants*. 1995; **10**: 33-42.
8. Boven GC, Meijer HJ, Vissink A and Raghoebar GM. Reconstruction of the extremely atrophied mandible with iliac crest onlay grafts followed by two endosteal implants: A retrospective study with long-term follow-up. *International Journal of Oral Maxillofacial Surgery*. 2014; **43**: 626-632.
9. Jivraj S, Chee W and Corrado P. Treatment planning of the edentulous maxilla. *British Dental Journal*. 2006; **201**: 261-279.
10. Chee W and Jivraj S. Treatment planning of the edentulous mandible. *British Dental Journal*. 2006; **201**: 337-347.
11. Bell RB, Blakey GH, White RP, Hillebrand DG and Molina A. Staged reconstruction of the severely atrophic mandible with autogenous bone graft and endosteal implants. *Journal of Oral Maxillofacial Surgery*. 2002; **60**: 1135-1141.
12. van der Meij EH, Blankestijn J, Berns RM, Bun RJ, Jovanovic A. The combined use of two endosteal implants and iliac crest onlay grafts in the severely atrophic mandible by a modified surgical approach. *International Journal of Oral Maxillofacial Surgery*. 2005; **34**: 152-157.
13. Pistilli R, Felice P, Piatelli M, Nisii A, Barausse C. Blocks of autogenous bone versus xenografts for the rehabilitation of atrophic jaws with dental implants: preliminary data from a pilot randomised controlled trial. *European Journal of Oral Implantology*. 2014; **7**: 153-171.
14. Preciado A, Del Rio J, Suarez-Garcia MJ, Montero J, Lynch CD. Differences in impact of patient and prosthetic characteristics on oral health-related quality of life among implant-retained overdenture wearers. *Journal of Dentistry*. 2012; **40**: 857-865.
15. Cawood JI and Howell RA. A classification of the edentulous jaws. *International Journal of Oral Maxillofacial Surgery*. 1988; **17**: 232-236.
16. Al-Omiri M, Hantash RA and Al-Wahadni A. Satisfaction with dental implants: A literature review. *Implant Dentistry*. 2005; **14**: 399-406.
17. Pommer B, Mailath-Pokorny G, Haas R, Busenlechner D, Furhauser R. Patients' preferences towards minimally invasive treatment alternatives for implant rehabilitation of edentulous jaws. *European Journal of Oral Implantology*. 2014; **7**: 91-109.
18. Raghoebar GM, Meijer HJ, Stellingsma K and Vissink A. Addressing the atrophied mandible: A proposal for a treatment approach involving endosseous implants. *International Journal of Oral Maxillofacial Implants*. 2011; **26**: 607-617.
19. McAllister BS and Haghghat K. Bone augmentation techniques. *Journal of Periodontology*. 2007; **78**: 377-396.
20. Tolman DE. Reconstructive procedures with endosseous implants in grafted bone: A review of the literature. *International Journal of Oral Maxillofacial Implants*. 1995; **10**: 275-294.
21. Zins JE and Whitaker LA. Membranous versus endochondral bone: Implications for craniofacial reconstruction. *Plastic and Reconstructive Surgery*. 1983; **72**: 778-785.
22. Crespi R, Vinci R, Cappare P, Gherlone E and Romanos GE. Calvarial versus iliac crest for autologous bone graft material for a sinus lift procedure: a histomorphometric study. *International Journal of Oral Maxillofacial Implants*. 2007; **22**: 527-532.
23. Tete S, Zara S, Zizzari VL, De Carlo A, Vinci R. Immunohistochemical analysis of matrix metalloproteinase-9, vascular endothelial growth factor, bone sialoprotein and i-nitric oxide synthase in calvaria vs. iliac crest bone grafts. *Clinical Oral Implants Research*. 2012; **23**: 1254-1260.
24. Kalk WW, Raghoebar GM, Jansma J, Boering G. Morbidity from iliac crest bone harvesting. *Journal of Oral Maxillofacial Surgery*. 1996; **54**: 1424-1429.
25. Baqain ZH, Anabtawi M, Karaky AA and Malkawi Z. Morbidity from anterior iliac crest bone harvesting for secondary alveolar bone grafting: An outcome assessment study. *Journal of Oral Maxillofacial Surgery*. 2009; **67**: 570-575.
26. Maestre-Ferrin L, Boronat-Lopez A, Penarrocha-Diago M and Penarrocha-Diago M. Augmentation procedures for deficient edentulous ridges, using onlay autologous grafts: An update. *Medicina Oral, Patología Oral y Cirugía Bucal*. 2009; **14**: 402-407.
27. Clementini M, Morlupi A, Canullo L, Agrestini C and Barlattani A. Success rate of dental implants inserted in horizontal and vertical guided bone regenerated areas: A systematic review. *International Journal of Oral Maxillofacial Surgery*. 2012; **41**: 847-852.
28. Burchardt H. The biology of bone graft repair. *Clinical Orthopaedics and Related Research*. 1983: 28-42.
29. de Carvalho PS, Vasconcellos LW and Pi J. Influence of bed preparation on the incorporation of autogenous bone grafts: A study in dogs. *International Journal of Oral Maxillofacial Implants*. 2000; **15**: 565-570.
30. Oh KC, Cha JK, Kim CS, Choi SH, Chai JK. The influence of perforating the autogenous block bone and the recipient bed in dogs. Part I: a radiographic analysis. *Clinical Oral Implants Research*. 2011; **22**: 1298-1302.
31. Cha JK, Kim CS, Choi SH, Cho KS, Chai JK. The influence of perforating the autogenous block bone and the recipient bed in

dogs. Part II: histologic analysis. *Clinical Oral Implants Research*. 2012; **23**: 987-992.

32. Adeyemo WL, Reuther T, Bloch W, Korkmaz Y, Fischer JH. Influence of host periosteum and recipient bed perforation on the healing of onlay mandibular bone graft: An experimental pilot study in the sheep. *Journal of Oral Maxillofacial Surgery*. 2008; **12**: 19-28.

33. De Marco AC, Jardini MA and Lima LP. Revascularization of autogenous block grafts with or without an e-PTFE membrane. *International Journal of Oral Maxillofacial Implants*. 2005; **20**: 867-874.

34. Nelson K, Ozyuvaci H, Bilgic B, Klein M and Hildebrand D. Histomorphometric evaluation and clinical assessment of endosseous implants in iliac bone grafts with shortened healing periods. *International Journal of Oral Maxillofacial Implants*. 2006; **21**: 392-398.

35. Faria PE, Carvalho AL, de Torres EM, Rasmusson L and Salata LA. Effects of early functional loading on maintenance of free autogenous bone graft and implant osseointegration: An experimental study in dogs. *Journal of Oral Maxillofacial Surgery*. 2010; **68**: 825-832.