

# Natural History and Management of Hepatitis C in Children

## 25 Years Experience of a Reference Center in Northern Italy

Francesca Musto<sup>1</sup>, MD,\* Marta Stracuzzi<sup>1</sup>, MD,\* Elisa Crivellaro, MD,\* Valeria Rubinacci, MD,\*  
Alessandro Cibarelli, MD,\* Cecilia Porro, MD,\* Elena Ghidoni<sup>1</sup>, MD,\*  
Gian Vincenzo Zuccotti, MD, PhD,†‡ and Vania Giacomet<sup>1</sup>, MD, PhD\*

**Abstract:** Hepatitis C virus (HCV) infection natural history and management in the pediatric population are still debated. We retrospectively evaluated the outcome of a HCV pediatric population managed at the Pediatric Infectious Disease Unit of Luigi Sacco Hospital (Milan, Italy) from January 1997 to January 2022 (median follow-up 10 years) and we focused on the role of new drugs and transient elastography. Fifty-seven patients were enrolled: 8 (14%) had a spontaneous clearance, 33 were treated (58%), 7 (12%) were not treated because they were under 12 years old and 9 were lost at follow-up. HCV RNA was undetectable in all treated patients at the end of therapy, after 12 weeks (SVR12) and for the rest of their follow-up. All patients treated underwent elastography before and 1 year after therapy. Median stiffness pretherapy was 5.6 kPa, and 9 patients (16%) had abnormal transient elastography (>7 kPa, median 8.7 kPa). Median stiffness after treatment in the abnormal group was 6.8 kPa. Direct-acting antiviral agents are a safe and effective therapy for HCV chronic infection in the pediatric population. Liver elastography is normal in many vertically infected children before 12 years, but, when abnormal, it shows a significant improvement after direct-acting antiviral agent treatment. Further studies are needed to evaluate the role of elastography at diagnosis and follow-up in children.

**Key Words:** hepatitis C, direct antiviral agents, elastography, children

(*Pediatr Infect Dis J* 2024;XX:00–00)

Hepatitis C virus (HCV) infection is a significant global health problem, being a major cause of chronic liver disease and associated morbidity and mortality worldwide. It is estimated that there are almost 3.26 million children 0–18 years of age with HCV infection worldwide (corresponding to 0.13% of the pediatric population).<sup>1</sup> However, the true prevalence of HCV in adolescents and children might be underestimated since only a small percentage of HCV-infected children are identified.<sup>2–4</sup> Most epidemiological data regarding the pediatric population in Italy are sparse and based on outdated studies. Available data showed a decreasing trend in the last 13 years with a general decline in newly diagnosed cases while there is a rise in the proportion of immigrant children with HCV infection.<sup>5</sup>

Accepted for publication March 26, 2024

\*From the Paediatric Infectious Disease Unit, Department of Paediatrics, Luigi Sacco Hospital Milan, University of Milan; †Pediatric Department, Buzzi Children's Hospital and ‡Department of Biosciences, Pediatric Clinical Research Center Romeo ed Enrica Invernizzi, University of Milan, Milan, Italy.

The authors have no funding or conflicts of interest to disclose.

Address for correspondence: Vania Giacomet, MD, PhD, Paediatric Infectious Disease Unit, Department of Paediatrics, Luigi Sacco Hospital Milan, University of Milan, Via Giovanni Battista Grassi, Milan, Italy. E-mail: vania.giacomet@unimi.it.

Copyright © 2024 Wolters Kluwer Health, Inc. All rights reserved.

ISSN: 0891-3668/24/XXX-0000

DOI: 10.1097/INF.0000000000004374

Genotype 1a is the most frequent genotype observed in Italy, while it has been reported a decrease in the prevalence of genotype 1b and an increase of genotype 3 and 4.<sup>6,7</sup>

Vertical transmission represents the most common source of HCV infection in children; at major risk are babies born to mothers with high HCV viral load, and even greater in the case of mothers with HIV–HCV coinfection.<sup>8</sup> Between 25% and 40% of infected children spontaneously clear the infection in the first 4 years of life.<sup>9</sup> Chronic HCV infection is usually asymptomatic during childhood and has a more indolent course than adulthood: the occurrence of cirrhosis and end-stage liver disease due to HCV infection is rare (1%–2%).<sup>10,11</sup> However, chronic HCV infection can lead to severe complications in early adulthood such as cirrhosis, hepatic cancer, liver failure<sup>11</sup> with a median of 33 years after infection and disease outcomes were better in patients treated before the development of advanced liver disease.<sup>12</sup>

In fact, even in the absence of a severe clinical manifestation, also in the pediatric population a chronic hepatic rearrangement might occur and early treatment could arrest this process and avoid future complications. The treatment of chronic HCV infection has changed since the development of direct-acting antiviral agents (DAAs) and combination drug regimens, which are effective, well tolerated, all oral and interferon-free. They have been approved for pediatric use in children older than 12 years of age since 2017 and recently DAA regimens received FDA and EMA approval for their implementation for children between 3 and 11 years of age, without delay in all viremic children 3 years old and up.<sup>13</sup>

Accurate staging of liver involvement, in particular fibrosis, is important to define the prognosis and to guide the management of patients with chronic C hepatitis.<sup>14</sup> Transient elastography (TE) is a noninvasive method for staging and monitoring liver fibrosis regression after treatment<sup>15</sup>; nevertheless, there is still lack of evidence of its implementation in the pediatric population, with only a few studies available, mostly case reports/series. Moreover, there are no univocal cutoff values, with stiffness values for moderate-severe fibrosis ranging from 6.9 to 8.6 kPa.<sup>14,16,17</sup>

The aim of our study was to describe the outcome of a pediatric HCV-infected population managed in a tertiary Pediatric Infectious Disease Department followed over a 25 years period. We also evaluated the role of new drugs and elastography in the management of chronic HCV infection in children.

## METHODS

We performed a single-center retrospective study in a cohort of children afferent to the Pediatric Infectious Disease Unit of Luigi Sacco Hospital (Milan, Italy) from January 1997 to January 2022 with diagnosis of HCV before 18 years old. Medical records were reviewed and data about clinical history, HCV diagnosis, comorbidities, diagnostic procedures, antiviral therapy, adverse effects and follow-up were extracted. Chronic HCV infection was defined in vertically transmitted patients by the presence of HCV RNA viral load >15 IU/mL in the serum twice between 2–6 months and by 2° and 3°

generation enzyme-linked immunosorbent assay anti-HCV antibodies at 18 months<sup>10</sup> of age, confirmed at 24 months. In suspected horizontally transmitted patients, determination of the presence of anti-HCV antibodies using second- or third-generation enzyme-linked immunosorbent assay tests was confirmed by HCV RNA >15 IU/mL, in the absence of clinical features of acute hepatitis. Genotype testing was recorded when available. Spontaneous clearance of HCV infection was defined by the presence of anti-HCV antibodies and by negative HCV RNA testing in 2 consecutive serum samples taken at least 6 months apart and timing of spontaneous resolution was calculated by the age at first negative HIV-RNA test. The follow-up for each patient included clinical and laboratory evaluation every 6 months after diagnosis. Alanine transaminase (ALT) was considered normal if <35 IU/mL for males and <25 IU/mL for females.<sup>10</sup> In addition, an abdomen ultrasound was performed at diagnosis and once a year. Therapy was prescribed according to the age-specific indications and based on the available treatment regimens during the follow-up, in particular in accordance with EASL Recommendations of Treatment of Hepatitis C of 2016<sup>18</sup> and treatment was started in children of 12 years of age or older. Patients who received treatment underwent clinical and laboratory follow-up at baseline, 2–4–8–12 weeks of treatment, at the end of the therapy and at 12 weeks post-treatment to assess sustained virologic response (SVR12). Afterward, the follow-up continued annually. All patients treated underwent elastography 1 month before therapy and 1 year after therapy according to our clinical management protocol. Elastography could not be performed in children age <10 years with usually an intercostal space smaller than fibrosan-probe. The stiffness cutoff used to define altered values indicative of possible fibrosis was 7 kPa. Patients with HIV–HCV coinfection followed the same follow-up protocol in addition to the hospital protocol implemented for HIV-infected pediatric patients.

## Outcomes

The primary outcomes of our study were to describe the natural history (rates of spontaneous clearance, chronic infection and complicated disease) and the efficacy and safety of treatment (SVR at 12 weeks and at the end of the follow-up after treatment, adverse events). The secondary outcome was to evaluate the grade of stiffness at TE before and after treatment.

## Ethics

All parents/guardians of enrolled children gave their written consent to treatment and inclusion in observational studies with anonymized data. The data was entered into the study database in accordance with international standards for information protection and respect for privacy. The study was conducted according to the guidelines of the Declaration of Helsinki.

## Statistical Analysis

Continuous variables were expressed using median and interquartile range or mean and standard deviations. Categorical variables were described as frequency and percentages. Groups were compared using Student *t* tests, if variables with normal distribution, or Wilcoxon test if a variable with no-normal distribution. A *P* < 0.05 was chosen as cutoff for significance. Unadjusted and adjusted odds ratios and 95% confidence intervals are presented. Data were analyzed with GraphPad Prism 9.

## RESULTS

Our cohort consists of 57 patients (M/F = 23/34). Population characteristics are listed in Table 1. Median age at diagnosis was 8 (IQ 2–14). Median follow-up duration was 10 years (range 1–25 years). In 90% (n° 51) the transmission was vertically. Horizontal transmission

**TABLE 1.** Characteristics of Hepatitis C Virus Infected Pediatric Population at Diagnosis

Characteristics of HCV-Infected Pediatric Population (n = 57)		
	N°	%
M	23	40
Median age (years, months)	8 (IQ 2–14)	
Genotype (°n 53/57)		
Genotype 1	31	58
1a	15	
1b	16	
Genotype 2	8	15
2a	1	
2a/2c	2	
2b	1	
Genotype 3	10	19
3	10	
Genotype 4	4	8
4a	1	
4a/4d	1	
Transmission		
Vertical	51	90
Horizontal	6	10
Comorbidities		
Coinfection HCV–HIV	5	9

was incidental and secondary to blood transfusion; 3/6 were immigrants. Fifty-two patients (N° 52 = 91%) had an exclusive HCV infection and 5 (9%) were HCV–HIV coinfecting. Genotype was investigated for 53/57 patients: the most frequent one was 1B (Table 1).

In our cohort 8 (14%) patients had spontaneous clearance at the median age of 2 years and 6 months (range 1–4 years), 33 were treated (58%), 7 (12%) were not treated because they were under 12 years old and 9 were lost at follow-up (Fig. 1).

Among the group vertically infected, 31 (60%) patients were diagnosed before 18 months. In this group, 6 patients (20%) underwent spontaneous clearance, the median age of clearance was 2 years and 7 months.

All patients were asymptomatic at the time of diagnosis except for 1 HCV/HIV coinfecting with vertical transmission who had cirrhosis and portal hypertension.

## Children With Chronic Hepatitis C Not Treated

The group of children who did not receive therapy (n° = 23) includes children <12 years old not treated for age (N° = 7), spontaneous clearance (N° 7) and patients lost at follow-up (N° 9). In the subgroup with <12 years of age (n = 7) median follow-up was 8.5 years (IQ 5.75–9.75). At the end of follow-up 7/7 showed persistent mild hypertransaminasemia (AST median 54 IU/mL, range 44–166 IU/mL, ALT median 72 IU/mL, range 59–104 U/I) and median viral load was 794.207 IU/mL (range 4020–33,836,060 IU/mL). Fibrosan was performed in 4/7 patients at a median age of 9.5 years and the median stiffness value was 4.8 kPa (range 3.3–5.3 kPa).

Ultrasound was pathological in 2 patients: 1 patient was 6 years had hyperechogenicity; the other showed hepatomegaly, was 12 years and was lost at follow-up.

## Children With Chronic Hepatitis C Treated

Twenty-nine HCV patients received the treatment. The median age of treated patients at baseline was 16 years (IQ 12–24 years). Therapeutic regimens are reported in Table 2. Mild side effects were reported in 8 patients (27%): headache, nausea, abdominal pain, diarrhea and asthenia.

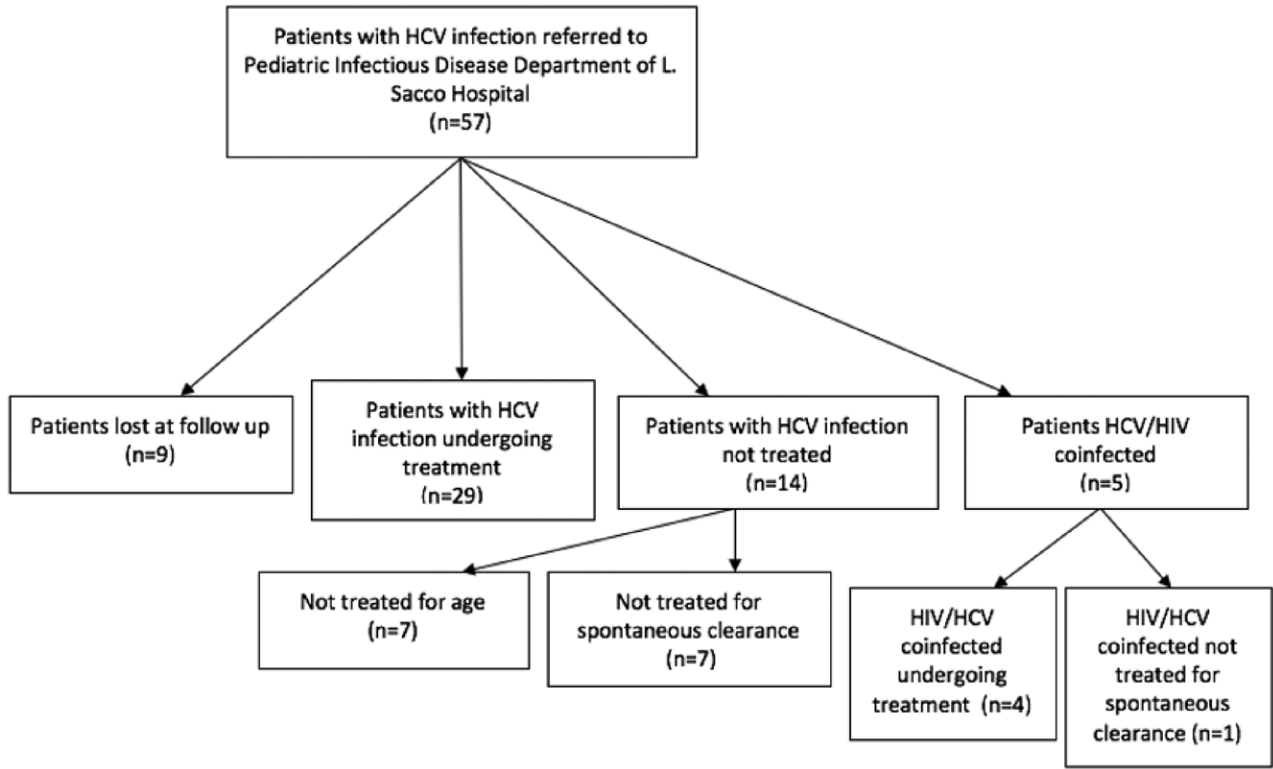


FIGURE 1. HCV pediatric population study cohort.

TABLE 2. Hepatitis C Virus Pediatric Antiviral Treatment

Patients Undergoing Treatment (n = 29)—Therapy			
	n°	%	Weeks
DAAs therapy			
Sofosbuvir/Ledipasvir	13	45	12 (n = 13)
Ombitasvir/paritaprevir/ritonavir + dasabuvir	4	14	12 (n = 4)
Glecaprevir/pibrentasvir	8	28	8 (n = 7), 12 (n = 1)
Sofosbuvir + Ribavirin	2	7	12 (n = 1), 24 (n = 1)
Sofosbuvir/Velpatasvir/Voxilaprevir	1	3	8 (n = 1)
No DAA			
Interferon + Ribavirin	1	3	24 (n = 1)

Description of antiviral treatment received by HCV pediatric patients: DAA, direct-acting antiviral agents; Weeks of treatment: in the brackets is specified the number of patients who completed the weeks of treatment.

Laboratory and radiologic data of the 29 patients treated are reported in "Table 3A and B. Before starting therapy, the median viral load was 390,228 IU/mL (range 37,118–9,481,391 IU/mL); 100% of patients showed decreasing viral load during treatment and undetectable viral load at the end of it. SVR12 was documented in 27 of 29 patients (the remaining 2 patients were lost at follow-up). The viral load persisted undetectable in all of them for the rest of their follow-up. In HCV patients treated in the US and elastography has been performed at baseline before treatment and the median age was 16 years.

Ultrasound before treatment was abnormal in 7 patients (24%): 5 had mild-moderate hepatomegaly (17%), 1 (3%) of which presenting also nonhomogeneous echo pattern while 2 presented

TABLE 3. Laboratory and Radiological Exams Before and After Treatment

A. Laboratory Exams of Hepatitis C Virus Treated Group						
Laboratory Exams of HCV Treated Group (n° = 29)						
	Before Therapy			After Therapy		
	Median	Range		Median	Range	
ALT (U/L)	42	19–184		20	11–32	
AST (U/L)	35	24–92		24	12–44	
HCV RNA (IU/mL)	3,900,228	37,118–9,481,391		0	0	

B. Radiological Exams of Hepatitis C Virus Treated Group						
Abnormal Radiological Exams of HCV Treated Group (n° = 29)						
	Before Therapy			After Therapy		
	N°	%	Median (kPa) Range	N°	%	Median (kPa) Range
Abnormal abdominal ultrasound	7	24		3 (out of 20)	15	
Abnormal elastography	6	23	9 7–15	1 (out of 17)	6 8	3–9

Table A: Median values before and after antiviral treatment of ALT (alanine transaminase), AST (aspartate transaminase) and HCV RNA viral load; Table B: Numbers of patients with pathologic radiological exams (abdominal US and elastography) before and after treatment in patients at the end of the follow-up when available.

with mild steatosis (7%). Patients with hepatomegaly were 70% genotype 1 and 30% genotype 3. One patient with steatosis was also obese and was genotype 2.

Median age of patients with pathologic US was 14 years; among those vertically infected was 14 and among those with horizontal infection (n° 3) milder lower 13.

After treatment, ultrasound was normal in 4/7 patients with alterations and when alterations persisted no further progression was observed (2 cases of mild hepatomegaly and 1 of steatosis).

TE before treatment was performed in 26/29 patients: median stiffness was 5.4 kPa (range 2.7–14.6 kPa). Abnormal stiffness (N.V. <7 kPa) was found in 9 (23%) (median 9.1 kPa, 7.1–14.6 kPa). Median age of patients with pathologic fibroscan was 17±5.6 years for both vertically and horizontally infected subgroups.

Four of them had hepatomegaly and/or nonhomogeneous echo patterns. TE after treatment was performed in 17/29 patients and showed a median stiffness of 5.1 kPa (range 3.3–9.4 kPa). Among the 6 patients with altered stiffness, median stiffness post-therapy was 7.9 kPa (Table 3B).

In exclusive HCV treated patients (n = 29) we also found a statistically significant difference in the values of AST and ALT pre- and post-therapy [respectively:  $t(55) = 4.592, P < 0.0001$  and  $t(56) = 4.800, P < 0.0001$ ] (Fig. 2A,B) and of HCV RNA viral loads [ $t(56) = 3.240, P < 0.002$ ] (Fig. 2C). Wilcoxon signed-rank test shows a significant drop in fibroscan values pre- and post-therapy ( $P < 0.05$ ) (Fig. 2D). A positive correlation between TE pretherapy

and AST pretherapy [ $P = 0.003$ , Pearson correlation coefficient ( $r$ ) = 0.566], (Fig. 2E) was found.

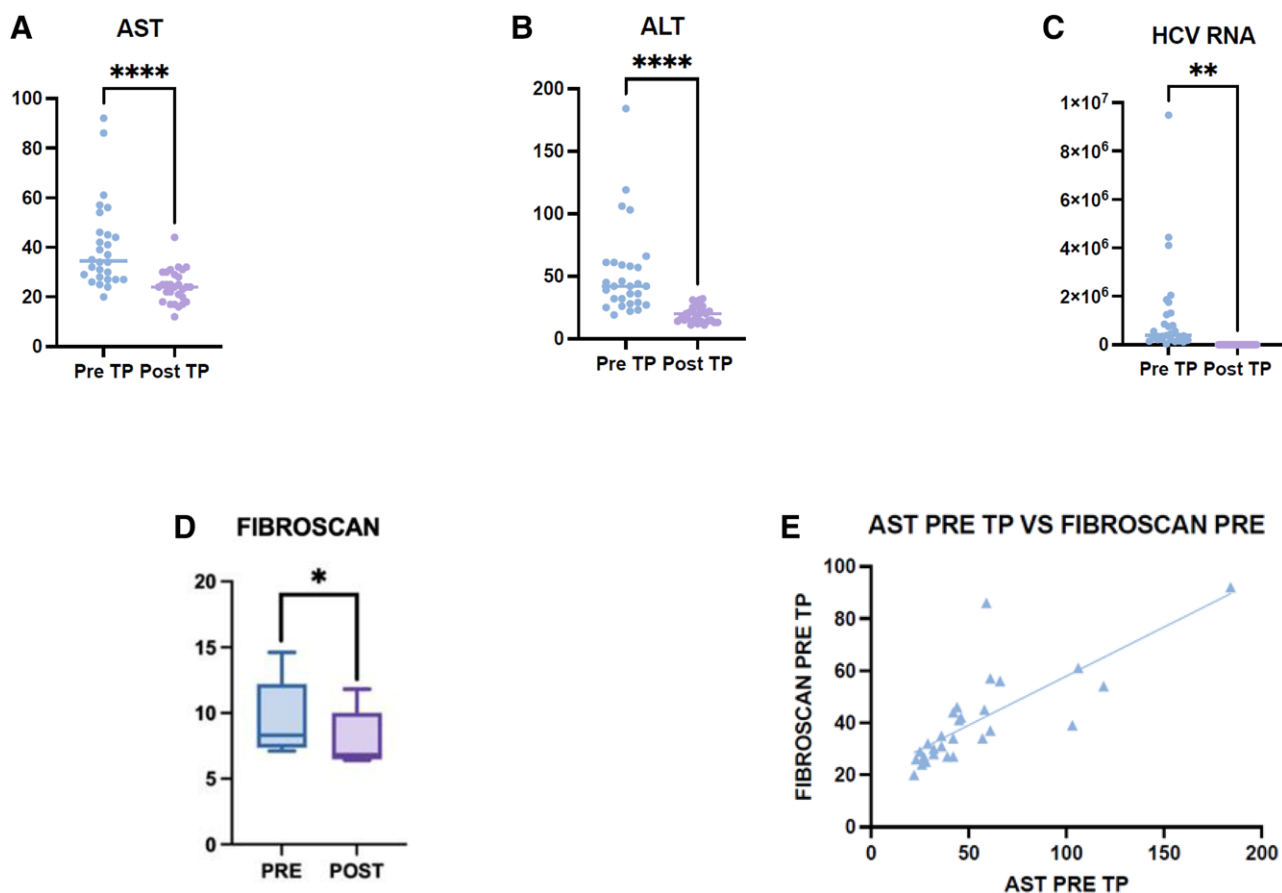
### Children With Coinfection HCV–HIV

We described separately the 5 HIV–HCV vertically coinfecting patients of our cohort. Median age 29.5 years, range 22–34 years. Four vertically infected.

At the time of treatment, all patients were taking antiretroviral therapy: 2 patients raltegravir + atazanavir + ritonavir, 1 patient raltegravir + darunavir + ritonavir and 1 patient abacavir + dolutegravir + lamivudine. HIV viral load was undetectable throughout the period of treatment and remained undetectable even after treatment for the entire period of follow-up (median of 4.5 years, range 2–7 years).

Four of 5 underwent treatment for HCV eradication, 2 with Ombitasvir/paritaprevir/ritonavir + dasabuvir (for 12 and 24 weeks, respectively), 1 with Sofosbuvir/Ledipasvir for 12 weeks and 1 with Glecaprevir/pibrentasvir for 8 weeks, without reporting side effects. One patient was not treated because of spontaneous clearance.

Only one of them was symptomatic, with cirrhosis, portal hypertension and esophageal varices. Laboratory monitoring before HCV therapy showed mild hypertransaminasemia (AST median 40 U/L, ALT median 54 U/L) in 3 of 4 patients. After treatment, there was a resolution of hypertransaminasemia in all of them.



**FIGURE 2.** Significant modifications after antiviral therapy exams: AST (A), ALT (B) and HCV RNA viral load (C). D: Nonparametric Wilcoxon signed-rank test compare fibroscan value pre- and post-therapy. \*\*\*\*extremely significant  $P < 0.0001$ ; \*\* very significant  $P < 0.01–0.001$ ; \* significant  $0.05–0.01$ . E: Linear regression between stiffness pre-TP and AST pre-TP ( $P = 0.003$ , Pearson correlation coefficient  $r = 0.5662$ ).



Median HCV RNA before treatment was 1,575,035 IU/mL (range 116,261–2,311,378 IU/mL); at the end of treatment all patients achieved HCV eradication, with viral load persistently undetectable for the entire follow-up. Abdomen ultrasound was altered only in 1 patient, showing cirrhosis, and remained altered after treatment. Elastography was performed before treatment in all 4 treated patients showing an altered stiffness in 3/4 (median 7.6 kPa, range 7.1–14.6 kPa). After 1 year of treatment an improvement in stiffness was observed in all 3 cases (median 6.8, range 6.5–11.8 kPa). The only patients with complicated cirrhosis was 22 years old when he received his first fibroscan detection and was 17.9 kPa; after treatment his clinical condition remained stable and after 10 years his stiffness drop to 12 kPa.

## DISCUSSION

Our study described the epidemiological and clinical characteristics of a cohort of chronically infected children evaluated over a period of 25 years. Thus far there are only very few studies with such a long-term follow-up. In our study, the majority of patients acquired the infection vertically, in accordance with recent literature. Genotype 1B was the most frequent followed by 3, 2 and 4, according to Italian prevalence data.<sup>19,20</sup>

Regarding the natural course of infection, the children cohort was asymptomatic at the time of diagnosis and the infection persisted clinically silent throughout its course. Fifteen percent had spontaneous clearance and patients with chronic infection exhibit mild disease activity with hyper-transaminases and a low degree of fibrosis, in comparison with adults.<sup>21</sup>

Probably our cohort is enriched in children who would have persistent infection, but the percentage of clearance in vertically infected is in line with the literature. In our cohort, characterized by a long median follow-up, none of our patients have developed complications, so far. This could be most likely related to the fact that 70% of the patients (excluding patients lost at follow-up) have been treated with good responses to treatment. Only one patient, which was HIV/HCV coinfecting, had cirrhosis at 22 years and nevertheless, his hypertransaminasemia resolved after treatment, radiological progression was observed and also his hepatic stiffness improved with good clinical control of chirotoxic complications. Treatment was limited to children older than 12 years of age according to drug policy at the time. The efficacy of treatment reported in our cohort confirms previous excellent data, with undetectable viral load at 12 weeks (SVR12) and till the end of the follow-up in 100% of patients. Moreover, we described an improvement in liver damage, based on both laboratory and radiological exams. None of the patients underwent to progression of disease or complications. In our cohort, we did not perform liver biopsy in any of our patients because of the absence of severe cases. To evaluate liver involvement during follow-up in our cohort it was implemented elastography. In the absence of pediatric cutoff, we use 7 kPa as a threshold for diagnosis of fibrosis and in the subgroup of treated patients we observed a significant drop in fibroscan values pre- and post-therapy. Patients not treated with <12 years, with a median age of 9.5 years had a median stiffness of 4.8 kPa, while older patients with a median age of 16 years had a median stiffness of 5.4 kPa and 23% of them had a pathologic fibroscan. Older patients belonging to HIV/HCV cohort had a median stiffness of 7.6 kPa at a median age of 23 years. It was interesting that in all of them, only 13% had a pathologic ultrasound, suggesting standard radiologic exams could underestimate liver progression. In our cohort, we also observed a statistically significant correlation between fibroscan values with laboratory tests such as AST as described in many studies in adult population.<sup>22,23,24</sup> All these data support the hypothesis that even in the absence of a severe clinical and radiological manifestation, also

in the pediatric population a chronic hepatic rearrangement might occur and early treatment could arrest this process and avoid future complications. Further study would be necessary to define specific elastography parameters for the pediatric population and predictive factors.

Concerning the HIV/HCV coinfecting population, in the pre-DAA era, it was considered one of the most difficult to treat, as HCV treatment success rates in real-world settings were low, around 30% in adults and 50% in children and young people.<sup>10,25-28</sup> Few reports concerning the use of DAAs in HIV/HCV coinfecting adolescents and youths are available. In our cohort, 5 patients were HIV/HCV coinfecting. Our cohort was at a median age of 23.5 years with HIV well-suppressed viremia. Four were treated with DAAs with a complete response to therapy, no side effects and no progression of hepatic disease according to Malik et al<sup>29</sup> data.

Some limitations of our analysis should be reported. First, the sample size was limited: it included patients referred to a single center and some of them had been lost during the follow-up.

## CONCLUSION

The present study is one of the longest actually available describing a cohort of HCV-infected children. It confirms the indolent clinical course in the pediatric population even if mild progressive chronic hepatic alteration might be observed with elastography also in the pediatric and young adult population. Moreover, our real-life study confirms and supports previous findings about the prompt and sustained efficacy of DAA therapy in HCV eradication in the pediatric population with an excellent tolerance and an effective improvement on liver involvement thus leading to prevention of long-term complications. Our study also shows how HIV/HCV coinfecting population in the DAA era can be successfully treated.

Furthermore, according to our data, fibroscan might be a non-invasive highly informative indicator of the patient's status and liver function that should be implemented in the pediatric population.

## REFERENCES

- Schmelzer J, Dugan E, Blach S, et al. Global prevalence of hepatitis C virus in children in 2018: a modelling study. *Lancet Gastroenterol Hepatol.* 2020;5:374–392.
- Delgado-Borrego A, Smith L, Jonas MM, et al. Expected and actual case ascertainment and treatment rates for children infected with hepatitis C in Florida and the United States: epidemiologic evidence from statewide and nationwide surveys. *J Pediatr.* 2012;161:915–921.
- Kuncio DE, Newbern EC, Johnson CC, et al. Failure to test and identify perinatally infected children born to hepatitis C virus-infected women. *Clin Infect Dis.* 2016;62:980–985.
- Honegger JR, Gowda C. Defer no more: advances in the treatment and prevention of chronic hepatitis C virus infection in children. *Curr Opin Infect Dis.* 2022;35:468–476.
- Indolfi G, Resti M. Perinatal transmission of hepatitis C virus infection. *J Med Virol.* 2009;81:836–843.
- Ades AE, Gordon F, Scott K, et al. Spontaneous clearance of vertically acquired hepatitis C infection: implications for testing and treatment. *Clin Infect Dis.* 2023;76:913–991.
- Tost ME, et al. Sieva Report Epidemiology of Acute Viral Hepatitis In Italy Bollettino Number 10 Update 2021. Istituto Superiore di Sanità; 2022
- Alberti A, Lacoini L, Morais E, et al. Literature review of the distribution of hepatitis C virus genotypes across Europe. *J Med Virol.* 2016;88:2157–2169.
- Ciccozzi M, Equestre M, Costantino A, et al. Hepatitis C virus genotype 4d in Southern Italy: reconstruction of its origin and spread by a phylogenetic analysis. *J Med Virol.* 2012;84:1613–1619.
- Serranti D, Nebbia G, Cananzi M, et al. Efficacy of Sofosbuvir/Ledipasvir in adolescents with chronic hepatitis C genotypes 1, 3, and 4: a real-world study. *J Pediatr Gastroenterol Nutr.* 2021;72:95–100.

11. Indolfi G, Easterbrook P, Dusheiko G, et al. Hepatitis C virus infection in children and adolescents [published correction appears in *Lancet Gastroenterol Hepatol*. 2020 May;5(5):e4]. *Lancet Gastroenterol Hepatol*. 2019;4:477–487.
12. Kamsakul W, Schwarz KB. Management of hepatitis C Infection in children in the era of direct-acting antiviral agents. *J Viral Hepat*. 2019;26:1034–1039.
13. Pokorska-Śpiewak M, Dobrzeńska A, Lipińska M, et al. Liver fibrosis evaluated with transient elastography in 35 children with chronic hepatitis C virus infection. *Pediatr Infect Dis J*. 2021;40:103–108.
14. Kronfli N, Young J, Wang S, et al; Canadian Coinfection Cohort Study Investigators. Liver fibrosis in human immunodeficiency virus (HIV)-hepatitis C virus (HCV) coinfection before and after sustained virologic response: what is the best noninvasive marker for monitoring regression? *Clin Infect Dis*. 2021;73:468–477.
15. Lee CK, Perez-Atayde AR, Mitchell PD, et al. Serum biomarkers and transient elastography as predictors of advanced liver fibrosis in a United States cohort: the Boston Children's Hospital experience. *J Pediatr*. 2013;163:1058–1064.
16. Fitzpatrick E, Quaglia A, Vimalasvaran S, et al. Transient elastography is a useful noninvasive tool for the evaluation of fibrosis in paediatric chronic liver disease. *J Pediatr Gastroenterol Nutr*. 2013;56:72–76.
17. European Association for the Study of the Liver. Electronic address: easloffice@easloffice.eu. EASL Recommendations on Treatment of Hepatitis C 2016. *J Hepatol*. 2017;66:153–194.
18. Indolfi G, Kelly D, Nebbia G, et al. Sofosbuvir-velpatasvir-voxilaprevir in adolescents 12 to 17 years old with HCV infection. *Hepatology*. 2022;76:445–455.
19. Stinco M, Bartolini E, Veronese P, et al. Epidemiology and natural history of childhood-acquired chronic hepatitis C: a single-center long-term prospective study. *J Pediatr Gastroenterol Nutr*. 2022;75:e2–e7.
20. Bortolotti F, Verucchi G, Cammà C, et al; Italian Observatory for HCV Infection and Hepatitis C in Children. Long-term course of chronic hepatitis C in children: from viral clearance to end-stage liver disease. *Gastroenterology*. 2008;134:1900–1907.
21. Iorio R, Giannattasio A, Sepe A, et al. Chronic hepatitis C in childhood: an 18-year experience. *Clin Infect Dis*. 2005;41:1431–1437.
22. Foucher J, Chanteloup E, Vergniol J, et al. Diagnosis of cirrhosis by transient elastography (FibroScan): a prospective study. *Gut*. 2006;55:403–408.
23. ElShahawy A, El-Raziky MS, Sharaf SA, et al. Accuracy of noninvasive methods for the diagnosis of liver fibrosis in children with chronic viral hepatitis. *BMC Gastroenterol*. 2022;22:508.
24. Chaidez A, Pan Z, Sundaram SS, et al. The discriminatory ability of FibroScan liver stiffness measurement, controlled attenuation parameter, and FibroScan-aspartate aminotransferase to predict severity of liver disease in children. *Hepatol Commun*. 2022;6:3015–3023.
25. Turkova A, Giacomet V, Goetghebuer T, et al. HCV treatment in children and young adults with HIV/HCV co-infection in Europe. *J Virus Erad*. 2015;1:179–184.
26. European Paediatric HIV/HCV Co-infection Study Group in the European Pregnancy and Paediatric HIV Cohort Collaboration (EPPICC) in EuroCoord. Coinfection with HIV and hepatitis C virus in 229 children and young adults living in Europe. *AIDS*. 2017;31:127–135.
27. Indolfi G, Bartolini E, Serranti D, et al. Hepatitis C in children co-infected with human immunodeficiency virus. *J Pediatr Gastroenterol Nutr*. 2015;61:393–399.
28. Carrasco I, Sainz T, Frick MA, et al; the Pediatric National AIDS Research Network of Spain (CoRISpe) integrated in the Translational Research Network in Pediatric Infectious Diseases (RITIP). Response to direct-acting antivirals for hepatitis C treatment in vertically HIV/HCV co-infected patients. *J Viral Hepat*. 2020;27:955–958.
29. Malik F, Malyuta R, Volokha A, et al; for the Ukraine Paediatric HIV Cohort. Hepatitis C virus treatment response to direct-acting antivirals among adolescents with HIV/HCV coinfection: real-world data from Ukraine. *Pediatr Infect Dis*. 2022;41:417–419.