

Vascular access and closure management for electrophysiological interventions in 2025: a Clinical Consensus Statement of the European Heart Rhythm Association and the European Association of Percutaneous Cardiovascular Interventions of the ESC, and the ESC Working Group on Cardiovascular Surgery

Tom J. R. De Potter ^{1*}, Chiara Valeriano ², Finn Akerstrom ^{3,4},
Salvatore Cassese ⁵, Malcolm Finlay ⁶, Dhiraj Gupta ^{7,8}, Josef Kautzner ⁹,
Antonio Miceli ¹⁰, Sotirios Nedios ¹¹, Katarzyna Malaczynska-Rajpold ^{12,13},
Hemanth Ramanna ^{14,15}, Flavio Ribichini ¹⁶, Philipp Sommer ¹⁷,
Roland Tilz ^{18,19}, Jorge Toquero Ramos ²⁰, and Stylianos Tzeis ²¹

**Reviewers: Alireza Sepehri Shamloo²² (Review Coordinator), Claudio Tondo²³, Borislav Dinov²⁴,
Ignacio Fernández-Lozano²⁵, Piotr Kulakowski²⁶, Luigi Di Biase²⁷, Francesco Burzotta²⁸,
and Roman Gottardi^{29,30}**

¹Heart Center AZORG, Campus Aalst, Moorselbaan 164, 9300, Aalst, Belgium; ²Cardiovascular Department, IRCCS Humanitas Research Hospital, Milan, Italy; ³Department of Cardiology, Karolinska University Hospital, Stockholm, Sweden; ⁴Heart and Lung Diseases Unit, Department of Medicine, Huddinge, Karolinska Institute, Stockholm, Sweden; ⁵Department of Cardiovascular Diseases, German Heart Centre Munich, School of Medicine and Health, TUM University Hospital, Technical University of Munich, Munich, Germany; ⁶St Bartholomew's Hospital, London & Queen Mary University of London, London, UK; ⁷Department of Cardiology, Liverpool Heart and Chest Hospital, Liverpool, UK; ⁸Liverpool Center for Cardiovascular Science, University of Liverpool, Liverpool, UK; ⁹Department of Cardiology, Institute for Clinical and Experimental Medicine, Prague, Czech Republic; ¹⁰Minimally Invasive Cardiac Surgery Department Milan, IRCCS Galeazzi-Sant'Ambrogio, Milan, Italy; ¹¹Department of Electrophysiology, Heart Center Leipzig at University of Leipzig, Leipzig, Germany; ¹²Heart, Lung and Critical Care, Royal Brompton Hospital, Guy's and St Thomas' NHS Foundation Trust, London, UK; ¹³Cardiology Department, Lister Hospital, East and North Hertfordshire NHS Trust, Stevenage, UK; ¹⁴Department of Cardiology, Haga Teaching Hospital, The Hague, The Netherlands; ¹⁵University of Applied Sciences of The Hague, The Netherlands; ¹⁶Cardiovascular Section of the Department of Medicine, University of Verona, Verona, Italy; ¹⁷Department of Electrophysiology, Heart- and Diabetescenter NRW Bad Oeynhausen, Ruhr University Bochum, Bochum, Germany; ¹⁸Department of Rhythmology, University Heart Center Lübeck, University Hospital Schleswig-Holstein, Lübeck, Germany; ¹⁹German Center for Cardiovascular Research (DZHK), Partner Site Hamburg/Kiel/Lübeck, Lübeck, Germany; ²⁰Cardiology Department, Puerta de Hierro Majadahonda University Hospital, Madrid, Spain; ²¹Department of Cardiology, Mitera Hospital, Athens, Greece; ²²Department of Cardiology, Deutsches Herzzentrum der Charité—Medical Heart Center of Charité, German Heart Institute Berlin, Berlin, Germany; ²³Department of Clinical Electrophysiology & Cardiac Pacing, Department of Surgical, Biomedical and Dental Sciences, Centro Cardiologico Monzino, IRCCS, University of Milan, Milan, Italy; ²⁴Department of Cardiology and Angiology, University Hospital of Giessen, Giessen, Germany; ²⁵Arrhythmia Unit, Cardiology Service, Puerta de Hierro University Hospital, Madrid, Spain; ²⁶Department of Cardiology, Medical School for Postgraduate Education, Grochowski Hospital, Warsaw, Poland; ²⁷Albert Einstein College of Medicine at Montefiore Health System, New York, USA; ²⁸Fondazione Policlinico Universitario Agostino Gemelli, IRCCS, Università Cattolica del Sacro Cuore, Rome, Italy; ²⁹Department of Cardiovascular Surgery, University Heart Center Freiburg-Bad Krozingen, Hugstetter Strasse 55, Freiburg D-79106, Germany; and ³⁰Faculty of Medicine, Albert Ludwigs University Freiburg, Freiburg, Germany

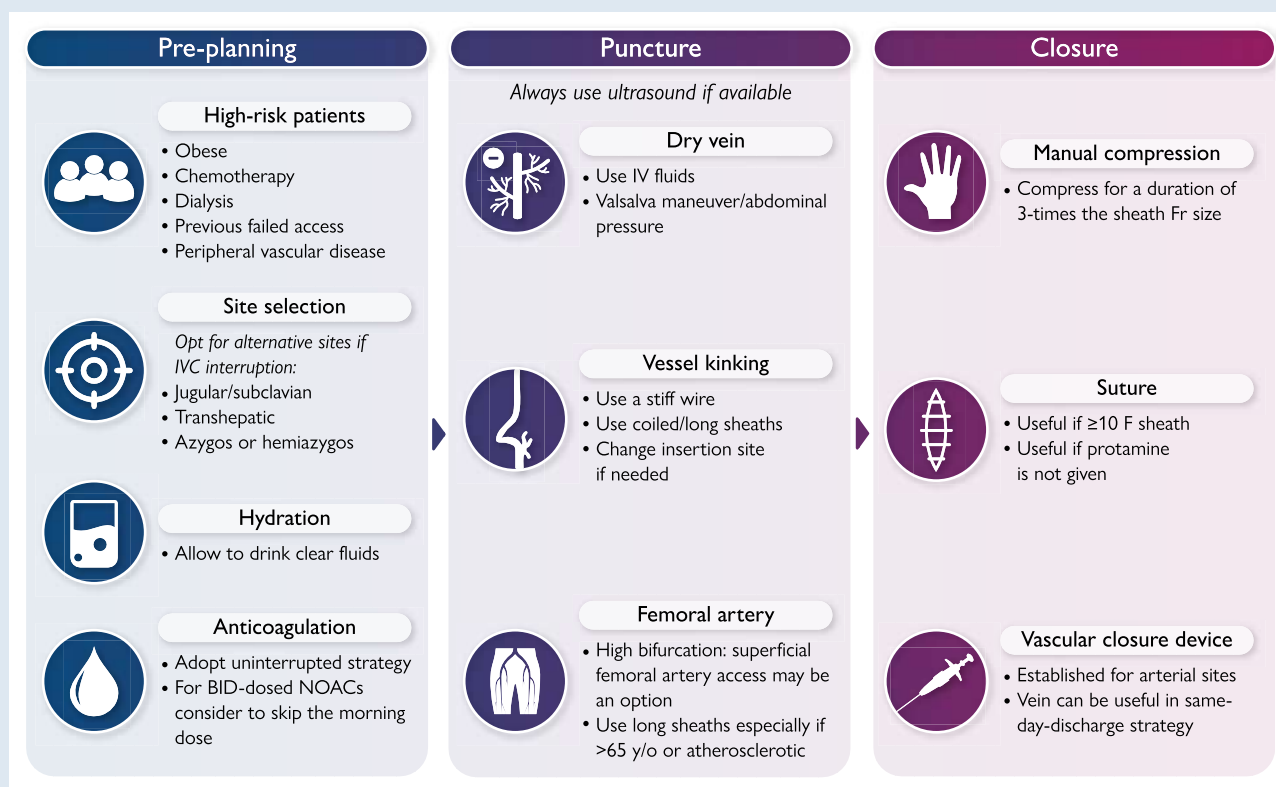
Received 4 April 2025; accepted after revision 16 May 2025; online publish-ahead-of-print 14 October 2025

* Corresponding author. Tel: +3253724439, E-mail address: tom.de.potter@azorg.be

© the European Society of Cardiology 2025.

This is an Open Access article distributed under the terms of the Creative Commons Attribution-NonCommercial-NoDerivs licence (<https://creativecommons.org/licenses/by-nc-nd/4.0/>), which permits non-commercial reproduction and distribution of the work, in any medium, provided the original work is not altered or transformed in any way, and that the work is properly cited. For commercial re-use, please contact journals.permissions@oup.com

Graphical Abstract



A standardized step-by-step approach to vascular access during electrophysiological procedures: Begin by identifying patients at higher risk for vascular complications and consider alternative access routes in cases of inferior vena cava interruption. Allow the patient to drink clear fluids and adopt an uninterrupted anticoagulation strategy when feasible. Choose the access site based on procedural needs and patient anatomy, giving preference to ultrasound-guided puncture to improve accuracy and reduce complications. At the end of the procedure, select the most appropriate closure technique – manual compression, figure-of-eight suture, or a vascular closure device – based on access site, sheath size, and patient-specific factors.

Keywords

• Vascular access • Electrophysiology procedures • Ultrasound-guided access • Vascular closure

Table of contents

1. Introduction.....	2	4.3.2.2. Sealants.....	8
2. Vascular anatomy.....	3	4.4. Clinical evidence and outcomes of vascular closure devices in electrophysiology procedures.....	8
2.1. Femoral access.....	3	4.5. Early ambulation and early discharge considerations.....	9
2.2. Internal jugular and subclavian access.....	3	5. Complication avoidance and management.....	9
2.3. Transhepatic access.....	3	6. Specific scenarios—tips and tricks.....	11
3. Vascular access procedure.....	4	7. Training requirements.....	12
3.1. Pre-procedural considerations.....	4	8. Economical aspects.....	12
3.2. Periprocedural anticoagulation.....	4	9. Gaps in evidence and future perspectives.....	14
3.3. General techniques.....	5	10. Key messages.....	14
3.4. Specific site considerations and site selection.....	6	11. Table of clinical advice.....	14
3.5. Surgical access.....	7	Supplementary material.....	14
4. Vascular closure techniques.....	7	Acknowledgements.....	14
4.1. Manual compression.....	7		
4.1.1. Compression devices.....	7		
4.2. Suture techniques.....	7		
4.3. Vascular closure devices.....	7		
4.3.1. Active vascular closure devices.....	7		
4.3.1.1. Suture-based.....	7		
4.3.1.2. Clip-based.....	8		
4.3.2. Passive vascular closure devices.....	8		
4.3.2.1. Collagen plugs.....	8		

1. Introduction

Vascular access is a fundamental aspect of all electrophysiology (EP) procedures, enabling the placement of diagnostic and therapeutic catheters, essential for arrhythmia management. Over recent years, advancements in imaging and vascular closure techniques have significantly improved the safety and efficiency of EP procedures.¹ As it remains such a central element of daily workflows—and

unfortunately an important driver of complications in all procedure types—a collaborative team of electrophysiologists and vascular specialists has developed this document, integrating current evidence, and providing practical guidance on vascular access management. Key sections include comprehensive review of ultrasound use for vascular access, strategies for managing challenging vascular anatomies, and techniques for minimizing complications. The document also addresses the use of various vascular closure devices and methods, providing clinical advice based on available evidence and expert opinion. Additionally, special considerations for paediatric patients and those with anatomical variations are covered, ensuring comprehensive care for all patient populations. The aim of this document is to support clinicians in their everyday practice by providing practical and actionable advice that consolidates all aspects of vascular access into a single, comprehensive resource. By offering evidence-based clinical advice and expert insights, it seeks to enhance procedural safety and streamline the adoption of best practices for vascular access in EP procedures.

The clinical advice provided at the end of this document was categorized in accordance with guidance from the EHRA scientific documents committee. The strength of published evidence was quantified in three strata based on the underlying reference material (a group for >1 high-quality RCT or a meta-analysis of high-quality RCTs, a group for high-quality observational data only and a group for evidence falling between those two definitions). Consensus opinion was obtained by private voting within the entire writing group and was labelled as 'consensus' if >70% of the writing group supported the advice and as 'strong consensus' if >90% of the writing group supported the advice.

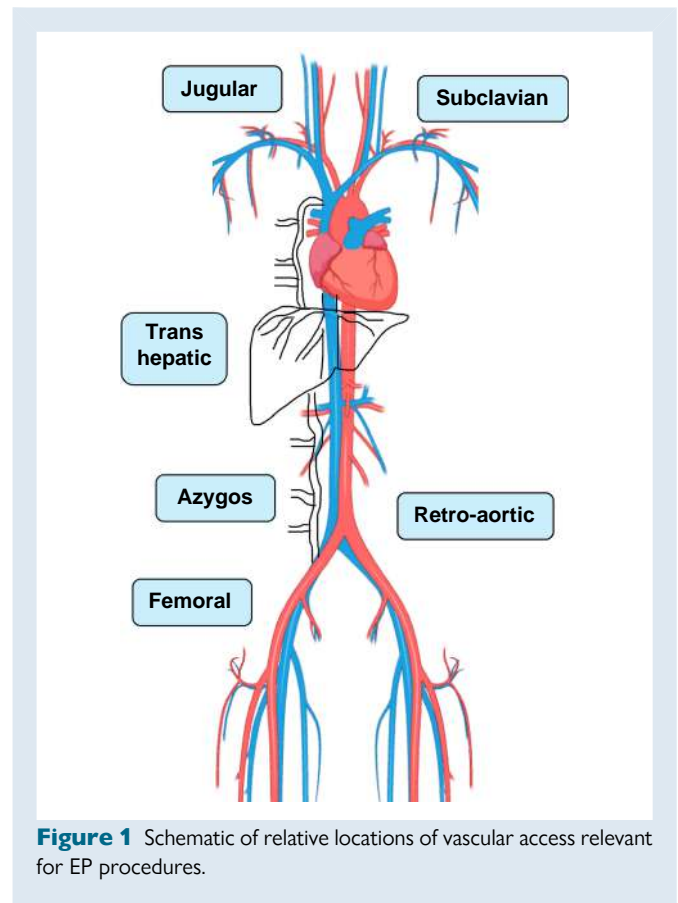
2. Vascular anatomy

2.1. Femoral access

Venous drainage from the lower limb flows from the popliteal vein to the superficial femoral vein. This vein then connects proximally with the deep femoral vein to form the common femoral vein. The great saphenous vein joins the common femoral vein at this level. Above the inguinal ligament, the common femoral vein continues as the external iliac vein and unites with the internal iliac vein to form the common iliac vein.

The femoral triangle, crucial for femoral access, is a subfascial space bordered superiorly by the inguinal ligament, medially by the adductor longus and laterally by the sartorius muscle. Within this triangle the femoral vein lies alongside the femoral artery, nerve, and lymphatics. At the upper inguinal level, the vein typically runs medially to the artery either in parallel or with lumen overlap $\leq 50\%$.² However, at a lower inguinal level, anatomical relationships of the femoral vessels vary substantially with the vein coursing posterior to the artery with major lumen overlap (>50%) in 24% of cases, while in 6% of cases the vein travels completely lateral to the artery.² These relationships have profound clinical implications for the safety of femoral vascular access based on anatomic landmarks only and explain the higher risk of arteriovenous fistula at more inferior puncture sites, in particular for venous access guided by palpation alone.

Several variants of the inferior vena cava (IVC) may be encountered impeding access to the right atrium via the typical femoral—iliac—IVC route.³ The most common variant is the absence of the hepatic segment of the IVC with azygos continuation (estimated prevalence $\sim 0.6\%$).⁴ In this variation, venous blood caudally or at the renal vein level is shunted via the azygos/hemiazygos vein, bypassing the absent hepatic IVC segment, reaching the right side of the heart via the superior vena cava (SVC). In several cases, hepatic vein drainage to the right atrium remains intact, allowing for a percutaneous transhepatic access route if needed (see below). *Figure 1* provides a schematic overview of vascular access sites relevant to EP procedures and their relative location.



2.2. Internal jugular and subclavian access

The internal jugular vein (IJV) collects blood from the head and neck. It originates in the posterior part of the jugular foramen and descends within the carotid sheath, lying anterolateral to the carotid artery and the vagus nerve.⁵ The key anatomical landmarks for accessing the IJV are the two heads of the sternocleidomastoid muscle, which form a triangle with the clavicle as its base.

The subclavian vein (SV) starts beneath the middle third of the clavicle, lying anterosuperior to the subclavian artery over the first rib. It joins the ipsilateral IJV posterior to the end of the clavicle and becomes the brachiocephalic or innominate vein. At the junction with the IJV, the left SV receives the thoracic duct, while the right SV receives the right lymphatic duct. As with femoral access, the use of anatomical landmarks alone for IJV or SV access carries a risk of complications by inadvertent puncture of the artery or other nearby structures.

The superior approach for ablation is the most frequently used strategy in case of obstruction of the IVC.⁶ Left atrial access and ablations have been effectively performed via the SVC.⁷ Additionally, ablation of right ventricular tachycardia in patients with repaired congenital heart disease and without femoral access has also been successfully carried out.⁸

2.3. Transhepatic access

The hepatic veins are large intraparenchymal veins which drain into the IVC at the level of the diaphragm, approximately 2 cm caudal to the right atrium. They are usually three in number and named as right hepatic vein (RHV), middle hepatic vein (MHV), and left hepatic vein (LHV). The RHV enters the IVC separately, but the MHV and the LHV may share a common trunk in 65–85% of patients.⁹ When the IVC route is not patent due to congenital abnormalities or surgical ligation, transhepatic access can

offer an alternative route to the right atrium, providing a 'familiar approach' for transseptal access when it is needed. With meticulous planning, the procedures can be carried out successfully, with a low risk of complications.^{6,10,11} As there are specific considerations to this approach in terms of anatomy and post-procedural management that are unique to the transhepatic access (e.g. coil-based closure), consultation with operators experienced in the procedure, potentially from other fields such as interventional radiology, is of great added value.

3. Vascular access procedure

3.1. Pre-procedural considerations

Pre-procedural preparation is essential for EP procedures but frequently overlooked. Identifying patients with potential vascular access challenges, such as known peripheral vascular disease, dialysis, pre-existing vascular access (e.g. portal catheter), anatomical obstacles such as large inguinal herniations or limb deformations, previous abdominal surgery or previous failed access, is crucial for procedural optimization. A review of previous imaging studies (mostly computed tomography (CT) and magnetic resonance imaging (MRI), commonly performed for different indications, is essential to help the operator performing the procedure with planning.

The use of ultrasound-guided (USG) techniques and awareness of prior vascular access difficulties can significantly improve success rates, even in difficult or previously unsuccessful cases. Early identification of high-risk patients allows the team to prepare appropriate equipment and adjust procedural schedules to better accommodate complex cases.

Poor patient hydration, a common and modifiable risk factor, can complicate vascular access. Patients are often kept 'nil by mouth' for several hours before a procedure, leading to fluid depletion. While guidelines recommend restricting oral fluid intake within 2 h of surgery to minimize the risk of gastric reflux, evidence supporting this is limited. Allowing patients to drink clear fluids until the time of the procedure has been shown to improve patient satisfaction without compromising safety.^{12,13}

Obese patients may present additional challenges for safe vascular access due to poor ultrasound penetration and tissue compression of deep structures. Pre-procedural identification of these challenges allows for appropriate planning, including considering general anaesthesia, where Valsalva manoeuvres may be easier to employ. In some cases, tissue

strapping or even postponement of the procedure for weight loss may be necessary. See *Table 1* for a summary.

3.2. Periprocedural anticoagulation

Management of periprocedural anticoagulation is critical for ensuring the safety of EP procedures, particularly regarding vascular access. To balance the haemorrhagic and thromboembolic (TE) risk, careful consideration of procedural and patient characteristics is needed.

The optimal management strategy for periprocedural anticoagulation in the setting of catheter ablation of AF has been covered in the recent consensus statement on catheter and surgical ablation of AF. In brief, uninterrupted anticoagulation should be used with either direct oral anticoagulants (DOACs) or warfarin during AF ablation procedures. Furthermore, implementation of a minimally interrupted DOAC anticoagulation strategy (skipping a single dose on the day of the procedure) is also reasonable prior to AF catheter ablation.

For patients on vitamin K antagonists (VKA), an uninterrupted strategy is guideline recommended because heparin bridging has been shown to be associated with higher TE and bleeding risk during AF ablation.^{14,15} For those with DOACs, an uninterrupted strategy has been proven to be non-inferior to uninterrupted VKAs in several randomized controlled trials.^{15–21} Overall, meta-analysis of these trials showed fewer major bleedings with DOACs than with VKAs while bleeding was lower in fully interrupted DOACs (4%) than in uninterrupted (6%) or minimally interrupted DOACs (7%).^{22,23} However, use of uninterrupted DOACs was associated with similar TE rates and significantly less (56%) silent cerebral lesions.^{23,24} Although elderly patients (>75 years old) with comorbidities have a higher bleeding and TE risk, these event rates are lowered by an uninterrupted DOAC strategy, especially with apixaban.²⁵ Thus, uninterrupted DOAC therapy should be the preferred strategy for EP procedures.^{26,27}

Although not mandatory, many operators administer low-dose heparin even for right-sided procedures. For left-sided interventions, anticoagulation with unfractionated heparin should be administered after femoral access and ideally before transseptal puncture, aiming for an activated clotting time of 300–400 s.¹⁴ This strategy reduces the rate of cerebral lesions that have been reported after left-sided ablations.²⁸ For ablation in the pericardial space, no heparin administration is needed. Epicardial access though should be obtained before heparin infusion or after reversal with protamine.^{29,30} Before epicardial access, a minimally interrupted strategy may be useful, involving the discontinuation of NOACs 48 h prior to the procedure and withholding VKA until

Table 1 Summary of pre-procedural considerations

Strategy	Description
Patient assessment	Comprehensive evaluation of patients to identify those with specific vascular access issues enables targeted procedural optimization
Risk identification	Early recognition of high-risk patients allows teams to prepare appropriate equipment and adjust procedural schedules to accommodate complex cases, potentially rescheduling if needed (e.g. supratherapeutic INR)
Peripheral cannulation	Difficult in patients with diabetes, prior chemotherapy, obesity. Use imaging or place a central venous catheter if needed
Ultrasound-guided techniques	Utilizing USG access techniques improves success rates, particularly in patients with difficult vascular anatomy or a history of failed access attempts
Hydration management	Ensuring adequate patient hydration before the procedure can reduce complexity during vascular access, as fluid depletion can make cannulation more challenging
Special considerations for obese patients	For patients with obesity, pre-procedural planning may include the use of general anaesthesia to improve access success.

INR, international normalized ratio; USG, ultrasound-guided techniques.

the international normalized ratio is <1.5 .³¹ Finally, administration of protamine at the end of the procedure was associated with faster haemostasis and ambulation, and similar complications to no reversal.^{32–34} It was also associated with adverse reactions and significant hypotension (1%).³⁵ Thus, more recent studies with modern access and closure techniques, have questioned this strategy.^{36–39} These data support the use of protamine, especially in cases of access problems,⁴⁰ but also show that modern techniques may obviate the need for protamine and highlight the need for further studies. Post-procedural anticoagulation is based on the TE risk and should be resumed 4–6 h after the procedure if no contraindication arises.³¹ In that case, withholding OAC or using heparin can be tailored to the patient specific TE/bleeding risks.

3.3. General techniques

Until recently, venous puncture for EP procedures was predominantly performed using traditional anatomic landmark-guided methods (e.g. femoral artery pulsation, inguinal ligament). As vascular access complications are the most common complications following catheter ablation, techniques aimed at increasing safety were evaluated. Real-time USG venipuncture, first used for the placement of central venous catheters, has been associated with reduced procedure time and vascular complications compared to the standard anatomic landmark-guided approach.⁴¹ Similarly for femoral venous access in catheter ablation, which often involves multiple sheaths and higher anticoagulation levels, there is substantial evidence that USG venipuncture significantly reduces complications, mainly due to fewer inadvertent arterial punctures and puncture attempts.⁴² Given the lack of adverse effects or additional cost, the use of USG vascular access is a key component of the clinical advice throughout this document.

Ideal ultrasound probes for USG venipuncture are high-frequency linear transducers with a range of 10–15 MHz, which provide high-resolution images with limited depth penetration, making them ideal for superficial targets such as vascular access. It is useful to ensure that the probe marker aligns with the ultrasound screen to correlate needle movements with the image and ensure anatomical relationships between vascular structures are correctly represented. The initial administration of local anaesthetic agents may decrease the quality of the ultrasound image; thus, it may be preferable to administer them at the end of the ablation procedure in case general anaesthesia is used. Alternatively, a short waiting period to allow diffusion of the anaesthetic may be useful.

Before venipuncture a good understanding of the regional anatomy is obtained by a pre-procedural scan (Figure 2 and [Supplementary material online, Video S1](#)). Arteries and veins have a similar appearance on a greyscale ultrasound image, but they are usually readily distinguished using visual inspection alone. Typically, an artery has identifiable layers in its vessel wall, commonly with calcifications, and exhibits a pulsatile aspect which is synchronized with the heart rate. Veins in contrast usually appear with a monolayer wall, rarely show calcifications and are either non-pulsatile or show a fluctuation in diameter which does not track the heart rate. Finally, veins should readily and fully collapse under probe pressure, while arteries remain circular due to their resistance to compression. A Valsalva manoeuvre can be very helpful to further confirm the dynamic nature of venous diameter. Colour Doppler may also be used to distinguish between artery and vein if needed but is not routinely performed.

Care should be taken to perform femoral vascular puncture with a safe distance (≥ 1 cm) below the inguinal ligament to avoid accidental bleeding into the retroperitoneal space. The safest site for femoral venous puncture is at the common femoral vein, proximal to the saphenous intake and with a safe margin to the inguinal ligament. Practically, this can be achieved by puncturing distal to the femoral artery bifurcation, which is easily visualized along the femoral vein in the

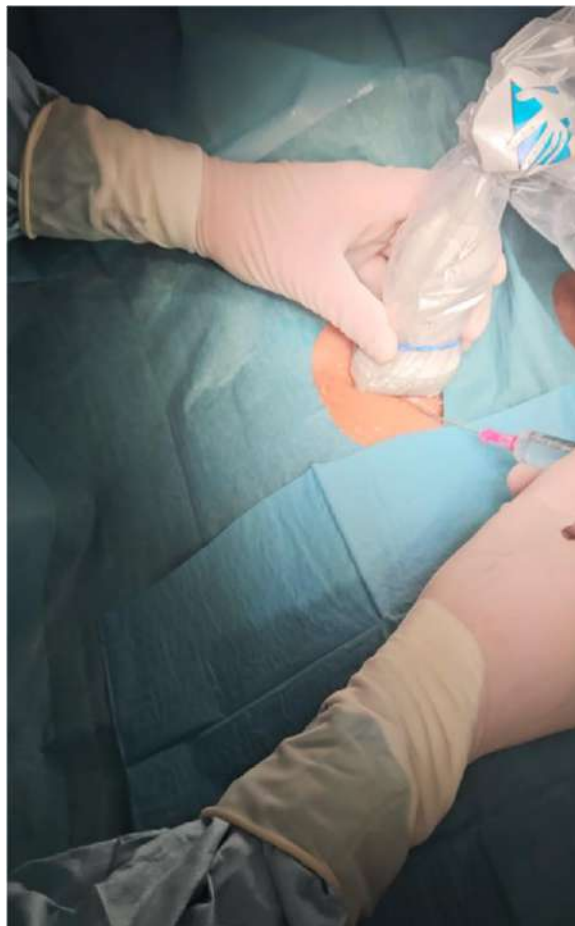

Figure 2 The ultrasound probe has been inserted in a sterile cover together with contact gel and is held by the non-dominant hand vertically to the femoral vessels to obtain a short-axis view. The operator needs to move the transducer along with the needle advancement to follow its tip towards to the puncture site (creeping technique).

short-axis view. To ensure a safe needle trajectory, the puncture site should ideally be at a point where the vein and the artery lie side-by-side. The needle insertion point (distance from the probe) is estimated from the measured vessel depth, the angle of needle insertion and the desired vessel puncture site. Femoral venous cannulation is commonly performed by using a short-axis view, where the image plane is perpendicular to both the course of the vessel and the needle (Figure 3, [Supplementary material online, Video S2](#)). This approach allows for easy visualization of adjacent vessels and structures. However, novice users may find it challenging to keep the needle tip in view as they advance it—it will not be possible to image the entire length of the needle and the ultrasound image of the tip and mid-portion of the needle look similar on the ultrasound screen, potentially leading to excessive advancement. To achieve safe and successful cannulation, the operator needs to follow the needle tip with the probe using a creeping technique until it punctures the vein and/or use continuous negative pressure on the syringe to identify vessel entry. It helps to keep the needle in the central portion of the probe to enable its tracking and use gentle back-and-forth movement. Alternatively, a long-axis view can be used where the image plane is parallel to the course of the vessel, allowing visualization of the longitudinal course of the vessel

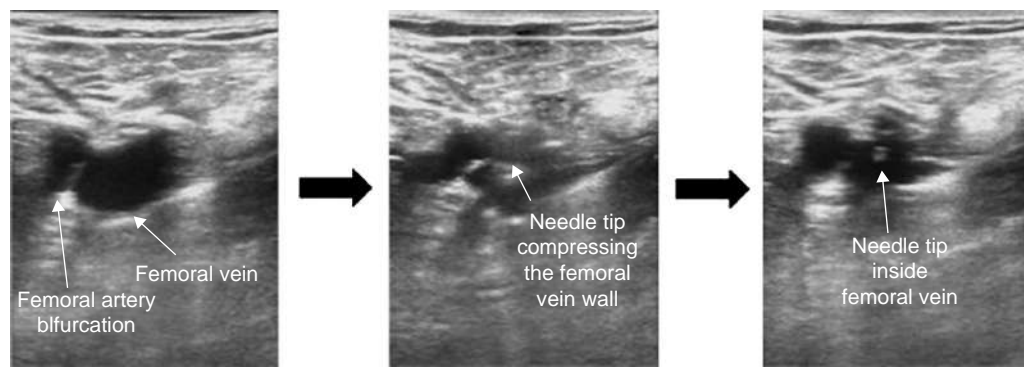


Figure 3 Short-axis view at the level of femoral artery bifurcation where the needle tip can be followed during venous puncture.

and the full length of the needle in its trajectory to the vessel (see [Supplementary material online, Video S3](#)). Advantages of this approach are better depth control and intuitive needle movement in the field of view. However, the longitudinal view does not allow appreciation of lateral relationships to surrounding structures, leading to a potentially higher risk of puncturing the adjacent artery.⁴³ Dedicated training for either approach is therefore necessary.

The maximal number of sheaths that can be safely introduced in a single femoral vein varies depending on patient and procedural factors. In practice, inserting more than three sheaths in a femoral vein is generally avoided, especially when larger sheaths are required for large-diameter catheters. Observational studies have shown that insertion of more than three sheaths ipsilaterally is associated with increased risk of deep vein thrombosis following catheter ablation procedures.⁴⁴ The use of bilateral groin puncture reduces the number of sheaths introduced on each side and may limit the associated risk of deep vein thrombosis. However, the latter should be weighed against the need to immobilize both legs resulting in significantly increased patient discomfort.⁴⁵

For femoral artery puncture, the ideal site is located just proximal to the bifurcation. Care must be taken to avoid puncturing calcified segments to ensure optimal haemostasis after sheath removal, especially if closure devices are intended to be used. The long-axis view is especially valuable for femoral artery puncture as it precisely displays the relationship between the bifurcation and the needle trajectory.⁴⁶

3.4. Specific site considerations and site selection

The introduction of USG vascular access represents a fundamental evolution in the field of interventional procedures, offering a safer and faster access method with fewer complications. This technique should be universally adopted as the standard of care.^{42,47} However, adoption has been inconsistent; a recent Italian survey revealed that while 46 out of 103 respondents had experience with USG access, only a fraction used it routinely.⁴⁸

The jugular or subclavian approaches are less frequently employed⁴⁹ but remain valuable alternatives, especially when IVC access is compromised.⁶ Superior access routes also enable transseptal punctures, albeit with increased fluoroscopy times and a higher risk of operator radiation exposure.^{7,50} Specific complications, such as pneumothorax or haemothorax, also present challenges with these approaches.

Recent reviews on alternative approaches for patients with obstructed or absent IVC indicate a preference for azygos or hemiazygos vein access (24%), followed by transhepatic (14%), and retrograde

aortic (10%) approaches.⁶ Azygos or hemiazygos veins are cannulated using a puncture of the femoral veins. In the transhepatic approach, the needle can be introduced into the hepatic vein under ultrasound or fluoroscopic guidance.^{11,51}

In paediatric patients, the limitations imposed by smaller vessel sizes necessitate reduced use of diagnostic catheters and/or alternative access strategies. The internal jugular and subclavian veins become crucial access sites for catheter placement, addressing the challenges of coronary sinus cannulation from femoral routes. The use of appropriately sized catheters and specialized techniques becomes even more critical in this demographic, emphasizing the necessity for tailored approaches in paediatric EP.^{52–54}

Femoral arterial access is frequently used in everyday practice for retrograde left ventricular access, particularly for ablation of premature ventricular contraction or ventricular tachycardia mainly originating from the base of the heart and less commonly for mapping of ventricular insertions of accessory pathways.⁵⁵ An increased risk of subclinical systemic embolization with retrograde LV access compared to transseptal LV access was shown in a randomized trial,⁵⁶ that reported higher rates of asymptomatic brain injury, assessed by a >30% increase in S100B levels post-procedure. Recently, the TRAVERSE trial, presented during the 2024 ACC, also indicated lower rates of acute cerebral injury on post-procedure MRI associated with a transseptal approach (28% vs. 45%, $P = 0.036$ in the intention-to-treat analysis, data presented but unpublished), highlighting the need for careful consideration of safety aspects when selecting between the antegrade/transseptal vs. the retrograde/transaortic approach. Beyond the highlighted indications, comprehensive management of femoral artery access is strongly influenced by sheath size and its discussion falls beyond the scope of this consensus document.

Pericardial access has gained importance, especially for the ablation of VTs. Innovations since its original description by Sosa et al. have aimed at minimizing risks associated with the dry puncture technique.⁵⁷ Novel strategies, such as the SAFER approach, which integrates right ventricular angiography, puncture during sustained apnoea, and real-time needle visualisation through electroanatomical mapping, have enhanced safety and efficacy. Additionally, the advent of pericardial carbon dioxide insufflation techniques highlights ongoing innovation in access strategies, offering alternatives based on local expertise and available resources.⁵⁸

Moreover, incorporating advanced imaging techniques, including CT and MRI, into procedural planning and execution has opened new frontiers in vascular and epicardial access.⁵⁹ These imaging modalities offer detailed anatomical insights, facilitating a more informed approach to access site selection and catheter navigation, ultimately improving procedural outcomes and patient safety.^{60,61}

3.5. Surgical access

Surgical access of femoral vessels may be appropriate when introducing large bore devices or to prevent potential vascular complications like pseudoaneurysm or dissection, especially in cases of calcified femoral arteries. It may also be a better option for patients with complex anatomy, such as vessel tortuosity or a high take-off of the deep femoral artery, which can raise the risk of retroperitoneal bleeding and complicate percutaneous groin access.^{47,62}

For procedures requiring haemodynamic support with extracorporeal membrane oxygenation (ECMO), like unstable ventricular arrhythmia, support during ablation has shown a reduction in the arrhythmic burden at long term follow-up.⁶³ While surgical femoral access is considered the reference approach for VA-ECMO, a total percutaneous USG approach is possible for elective settings and was associated with fewer local infections and fewer sensory-motor complications at the expense of increased vascular complication risks in large retrospective studies.^{64,65}

Surgical exposure of the femoral vessels is performed by a 2–3 cm suprainguinal skin incision, to avoid wound dehiscence and infection, and runs parallel to the inguinal ligament. The incision is centred over the femoral vessels and should be USG to identify the common femoral artery above the bifurcation and the femoral vein. After gentle dissection of soft tissues, the fascia lata is interrupted taking care not damaging the Cloquet lymph node to avoid lymphocele after the procedure. Once the femoral vessels are exposed and heparin is given, purse-string sutures with polypropylene are performed. Venous cannulation is performed with a 25 Fr multistage venous cannula inserted through the femoral vein into the right atrium, and the correct position achieved with the Seldinger technique under transoesophageal echocardiographic guidance. A 16–20 Fr arterial cannula (depending on patient's size) is inserted in the common femoral artery via Seldinger technique and ECMO is established⁶⁶ (see [Supplementary material online, Video S4](#)).

If femoral arteries are not suitable for cannulation (calcified vessel or peripheral vessel disease), ECMO or other large bore access (e.g. Impella) can be established through the right subclavian artery (see [Supplementary material online, Video S5](#)).

Finally, surgical access is also considered in case of bail out option for failed access or for bleeding complications. For the latter, it is essential to keep a guidewire *in situ* and insert a vascular dilator to control the bleeding, thereby maintaining an access route to the intraluminal space beyond the bleeding site to allow vascular access for repairing the vessel, potentially using endovascular tools.

After surgical cut-down for arterial access, conventional vessel sutures are used for closure, but this method increases the risk of wound infections and iatrogenic nerve damage.⁶⁷ Compared to surgical cut-down and closure, VCDs have been associated with fewer groin complications and shorter procedural time.⁶⁸

4. Vascular closure techniques

The optimal vascular haemostasis technique depends on factors like vessel type (vein or artery), vessel site (e.g. femoral, jugular, subclavian), number of sheaths, and maximal sheath calibre. Generally, vascular access site haemostasis can be achieved by manual compression, suture techniques and vascular closure devices.

4.1. Manual compression

For arterial access sites, a simple rule is to compress the site at supra-systolic pressure for a duration corresponding to three times the French size of the sheath being removed (i.e. 18 min for a 6-French sheath). For femoral venous sites, no such rule exists. However, large calibre venous sheaths typically require a minimum of 10 min of

manual compression especially when associated with periprocedural anticoagulation. Typically, after successful compression a bandage is applied to provide further compression while bed rest is needed for variable duration of at least several hours, depending on procedure type and institutional practice.

4.1.1. Compression devices

Specialized mechanical compression devices have been developed for different access sites, FemoStop (Abbott Vascular, Santa Clara, CA, USA) or ClampEase (Pressure Products, Rancho Palos Verdes, CA, USA) for femoral artery, TR Band (Terumo Corporation, Tokyo, Japan), PrecludeSYNC (Merit, Jordan, UT) or TRAcelet (Medtronic) for radial and ulnar arteries or the Safe-Guard family of devices (Merit, Jordan, UT) that can accommodate different access sites.

4.2. Suture techniques

Suture-based vascular closure techniques use the perivascular skin and subcutaneous tissue to apply external compressive forces over the venotomy. For femoral venous access site closure, subcutaneous suture techniques include the purse-string suture and the figure-of-eight (or Z-stitch) suture. The figure-of-eight stitch involves making two criss-crossing passes of the needle through the tissue on either side of the sheath insertion. When the suture is tightened, it pulls the tissue together in an overlapping pattern, resembling the shape of the number 8. The purse-string suture involves passing a continuous stitch through the skin at 4 or 5 points around the sheath, creating a constricting loop with the ends left free, making it particularly suitable for large-bore access closure. Modifications of classical sutures include the 'three-way stopcock suture technique', a figure-of-eight stitch where a stopcock pulls the skin by rotating the lever ([Figure 4, Supplementary material online, Videos S6 and S7](#)), and the 'Woggle', a purse-string variant using a tension collar and suture lock for adjustable tension without knotting. These techniques allow for adjustable suture tensioning by pulling (or releasing) the end of the sutures until haemostasis is achieved ([Figure 5](#)).

4.3. Vascular closure devices

With the increase in procedure volume and the growing use of larger vascular sheaths, the vascular closure device (VCD) market has rapidly expanded since the early 1990s to assist the physician in achieving haemostasis. Commonly used VCDs are summarized in [Table 2](#). While originally developed for closure of arterial access, several VCDs have been studied for venous closure as well and are discussed as such below.

When discussing VCDs, it is helpful to categorize them systematically based on their mechanisms of action. We can consider two main categories: active closure devices, which physically close the arteriotomy using a suture or nitinol clip, and passive closure devices, which deploy a plug, sealant, or gel at the arteriotomy site without actively closing the arteriotomy ([Figure 6](#)).

4.3.1. Active vascular closure devices

4.3.1.1. Suture-based

Suture-based VCDs were among the first developed, designed to mimic open surgical closure by percutaneously deploying sutures on either side of the arteriotomy, which are then pulled together to achieve haemostasis. The Perclose ProGlide (Abbott Vascular, Santa Clara, CA) is approved for venous closure and compatible with 5–21 F arterial sheaths [up to 26 F outer diameter (OD)] and 5–24 F venous sheaths (up to 29 F OD). The latest version, ProStyle (Abbott Vascular), offers improvements over ProGlide, including stronger needles for better penetration, reduced plunger spring force for smoother deployment, and added lubrication to decrease deployment force. When using suture-based closure devices it is of crucial

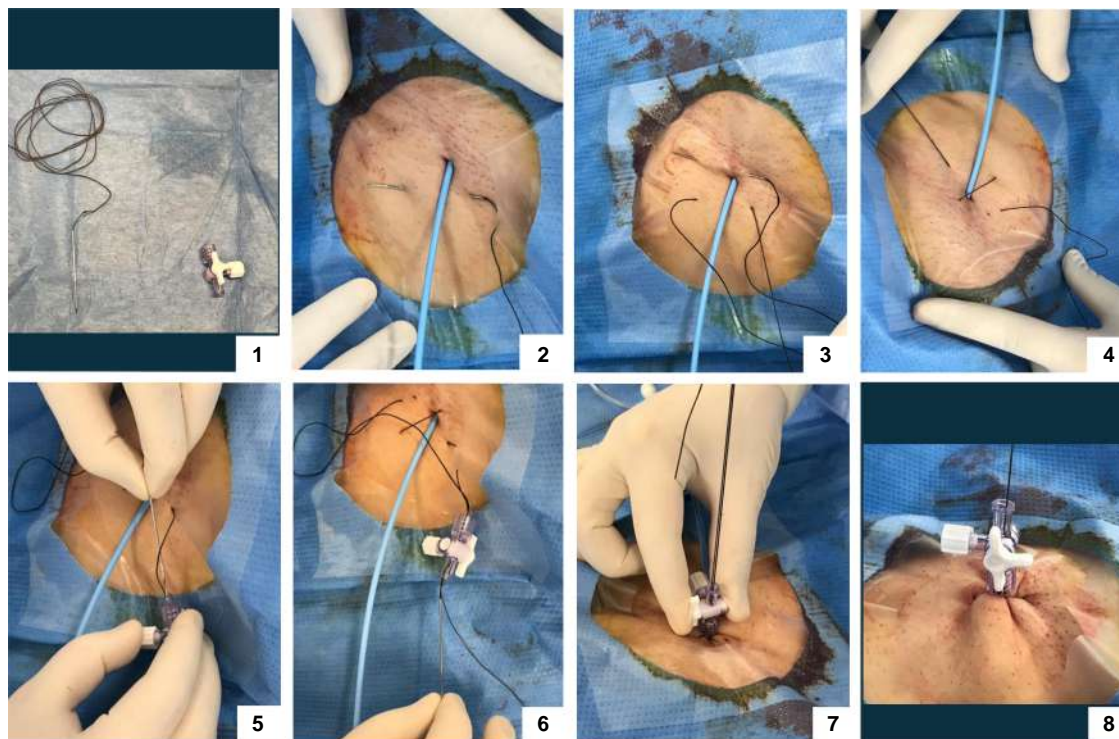


Figure 4 Step-by-step guide: performing a figure-of-eight stitch with a 3-way stopcock. The steps including a 3-way stopcock are optional (see text). For a traditional knot, after Step 4 tie both wire ends over the skin to achieve haemostasis. 1—(optional) Insert the wire: begin by threading the wire into one end of the 3-way stopcock; 2—First pass: guide the wire under the skin and the venous sheath; 3—Cross the sheath: direct the wire across the venous sheath; 4—Second pass: pass the wire under the skin again, this time looping over the venous sheath; 5—(optional) Reinsert the wire: insert the wire back into the same end of the 3-way stopcock; 6—(optional) Tighten the stitch: pull both ends of the wire upward while gradually removing the venous sheath; 7—(optional) Achieve haemostasis: slowly turn the 3-way stopcock lever to apply tension, ensuring proper haemostasis.

importance to deploy the device before sheath insertion when using a sheath size of 9 F or greater. Advantages of suture-based VCDs include complete physical closure of the arteriotomy, allowing unrestricted re-access and reducing concerns about anticoagulation. Disadvantages are a steep learning curve and the risk of luminal distortion due to the suture closure.

4.3.1.2. Clip-based

The StarClose SE (Abbott Vascular) deploys a 4-mm nitinol clip over the arteriotomy and requires a sheath exchange but leaves nothing intravascularly. The metallic clip remains in place indefinitely.

4.3.2. Passive vascular closure devices

This class of VCD deploys a plug, sealant, or gel over the arteriotomy site without physically closing it. Haemostasis is achieved because the material expands when deployed in the subcutaneous tissues, and collagen-based plugs also accelerate the clotting cascade.

4.3.2.1. Collagen plugs

The Angio-Seal (Terumo Corporation, Tokyo, Japan) is the most widely used VCD, employing an intravascular anchor to secure an extravascular collagen plug over the arteriotomy. All components are fully absorbed within 60–90 days. The device's intravascular anchor secures the plug, promoting haemostasis without compression but carries a risk of distal embolization, especially if re-entry is required within 90 days.

The Vascade system (Haemonetics, Boston, MA, USA) is a fully extravascular, bioabsorbable femoral closure device that combines a

collapsible disc with a thrombogenic resorbable collagen patch, providing both mechanical and physiological haemostasis. The Vascade MVP is specifically designed for mid-bore 6–12 F ID (Max 15 F OD), multi-access venous closure following catheter ablation.

The use of two VCDs, whether suture-based, plug-based, or a combination of both, is an established technique for percutaneous closure of large-bore access,⁶⁹ as in the case of electrophysiological procedures requiring mechanical circulatory support.

4.3.2.2. Sealants

The Mynx (Cordis; Milpitas, CA, USA) family of devices delivers a polyethylene glycol sealant to the extravascular space over the arteriotomy site. The sealant expands by up to 300% when deployed, sealing the vessel without enhancing coagulation. This closure method requires no sutures, clamping, or metal implants and dissolves within 30 days. It does not require sheath exchange and is also approved for closing femoral veins.

4.4. Clinical evidence and outcomes of vascular closure devices in electrophysiology procedures

Vascular closure devices have no absolute contraindications. Relative contraindications include dense arterial calcifications in the access vessel, entry above the inguinal ligament, small access artery site and the presence of an ipsilateral stent. In the case of suture or plug-mediated VCDs, the intravascular wire or anchor may become entangled in the stent strut, making it difficult to achieve haemostasis. To reduce

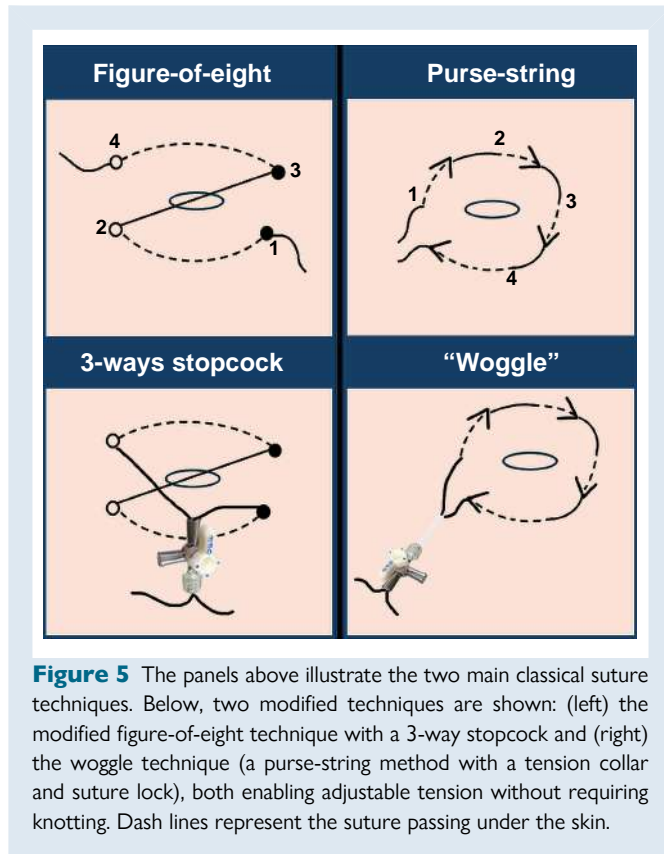


Figure 5 The panels above illustrate the two main classical suture techniques. Below, two modified techniques are shown: (left) the modified figure-of-eight technique with a 3-way stopcock and (right) the woggle technique (a purse-string method with a tension collar and suture lock), both enabling adjustable tension without requiring knotting. Dash lines represent the suture passing under the skin.

the risk of VCD failure in a vessel with a stent near the access site, the use of an extravascular VCD may be preferred.

The use of VCDs for venous puncture has increased in recent years, particularly with large-bore sheaths and the rise of same-day discharge strategies. In the AMBULATE trial, the Vascade MVP, significantly reduced time to ambulation and time to haemostasis without increasing complications.⁷⁰ The ProGlide system reduced time to discharge, improved patient satisfaction, and lowered costs compared to overnight stays.^{71,72} Recent randomized data confirm this trend, also showing fewer minor vascular access complications [7 (11.1%) vs. 15 (24.2%); $P = 0.063$].⁷³ VCDs have also been successfully used in pulse field ablation workflows with 16.8 F OD sheaths.⁷⁴ A strategy involving device deployment immediately after vascular access, without tightening the sutures, demonstrated lower re-bleeding rates and faster haemostasis compared to a strategy where the device is deployed after the procedure.⁷⁵

4.5. Early ambulation and early discharge considerations

The use of closure techniques beyond manual compression has led to a vast expansion of procedure types now deemed appropriate for early ambulation and same-day discharge. Suture techniques allow early ambulation at virtually no additional disposable cost, although some form of spontaneous haemostasis (and therefore bedrest for a few hours) is still needed, which can be further accelerated using VCDs if so desired (e.g. patient preference, scheduling/operational reasons). These shortened workflows have led to indirect changes that further stand to improve periprocedural safety. For example, foley catheter insertion for AF procedures has become unnecessary in most settings due to shortened total supine time. In addition, routine protamine administration is no longer considered useful after suture closure despite heparin administration. Finally, while anatomical features/body habitus and body mass

index (BMI) can make manual compression challenging, these features do not typically impact the efficacy of suture closure or VCDs, enabling standardized discharge workflows for the majority of patient profiles.

5. Complication avoidance and management

Several previous observational studies reported on the utility of ultrasound guidance in catheter ablation of different substrates, including AF.^{76–79} A recent meta-analysis evaluated the safety of USG femoral vein access compared to the traditional anatomic landmark guidance in all EP procedures.⁴² Nine studies (1 randomized controlled trial and 8 observational), with 7858 participants (3743 in the USG group, 4115 in the control group), were included. Overall vascular complication rates in all EP procedures were significantly decreased in the USG group compared to the control group (1.2% vs. 3.2%, RR: 0.38, 95% confidence interval: 0.27–0.53). Of interest, one randomized study included in this analysis documented additional benefits of USG, such as shorter puncture time, higher first-pass success and less extra puncture attempts or inadvertent arterial punctures.⁷⁷ The magnitude of this effect was consistent among trainees and experienced operators. Similar results were described when a mixed population of venous and arterial access patients was studied.⁸⁰ Interestingly, patients with BMI > 30 kg/m² showed larger benefit from a USG vascular access. Other studies found age⁷⁸ or female gender⁸¹ as significant predictors of vascular complications.

Observational data suggest that simple suture closure technique (Z or figure-of-eight stitch) may obviate the need for protamine administration by achieving haemostasis after venous sheath removal.^{36,38} Two small randomized controlled trials have demonstrated the clinical efficiency of the suture technique, showing reduced time in the EP lab, earlier ambulation, and a lower rate of access site complications when using large (≥ 10 F) sheaths.^{82,83}

The mode of failure and complications of VCDs vary by type and include bleeding, pseudoaneurysm formation, arterial obstruction, and infection. Collagen plugs most commonly cause bleeding and pseudoaneurysm formation when the plug fails to reach the adventitial surface of the arteriotomy, often due to inadequate tissue dilation or femoral scarring. Additional risks include intravascular deployment and vessel dissection, particularly in small vessels. All VCDs can potentially cause femoral artery occlusion, either through the anchor plate or the suture engaging the intima on the posterior wall.

Vascular closure devices approved for venous closure have shown significant decrease in time to ambulation, total post-procedure time, time to discharge eligibility, time to haemostasis and opioid use, with increased patient satisfaction and no increase in complications.^{70,73} Observational data shows a potential for complication reduction and cost containment using closure devices although these observations have not yet been confirmed in randomized trials.^{70,71,73,84}

Sheath size significantly impacts bleeding and complication risks during femoral access.⁸⁵

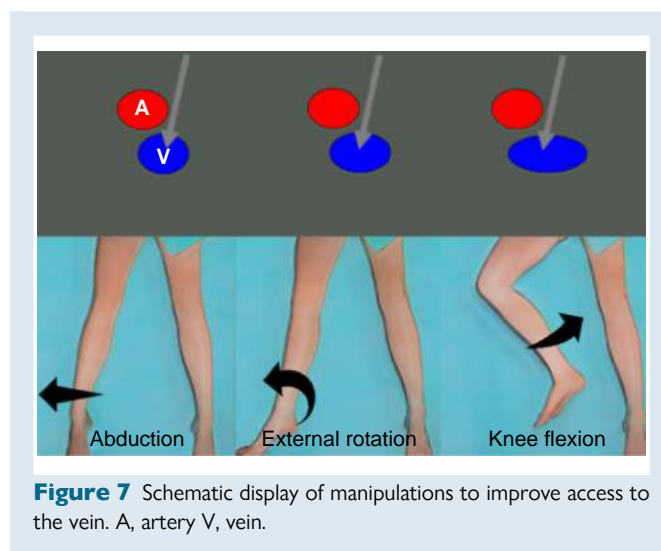
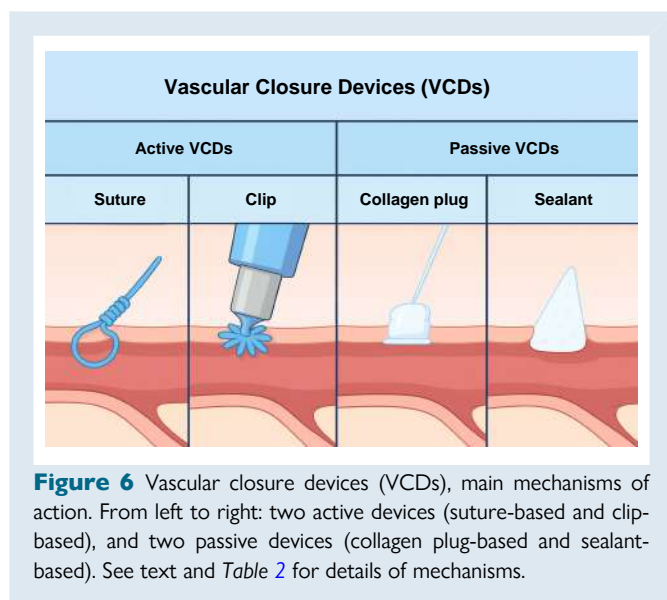
For arterial haemostasis, VCDs have improved patient comfort and reduced time to haemostasis and ambulation after percutaneous procedures. Meta-analysis of earlier studies demonstrated comparable complication rates in comparison with manual compression, with low occurrence of major complications. Although the risk of infections (0.6% with VCDs vs. 0.2% with MC) and thrombotic complications (0.3% with VCDs vs. none with MC) is slightly higher when compared to MC.⁸⁶ However, studies after 2005 reported reduced complications, especially haematomas with AngioSeal or FemoSeal devices.⁸⁷

For early recognition of vascular complications, some centres adopted a strict protocol for their pre-discharge assessment, aiming to detect complications at the potential preclinical stage using ultrasound.^{79,87,88}

Table 2 Main vascular closure devices (VCDs) available on the market

Product	Manufacturer	Mechanism of action	FDA approved use	Puncture size (F)	Comments
Perclose ProStyle/ ProGlide	Abbott	Suture	Femoral artery and vein	5–21 (artery) 5–24 (vein)	Provides secure repair with pre-tied polypropylene monofilament suture, ability to maintain wire access, minimal intravascular footprint with no re-access restrictions; broadest indication for both femoral arterial and venous access
Prostar XL	Abbott	Suture	Femoral artery	8.5–10	Provides secure repair with two braided sutures, ability to maintain wire access with minimal intravascular footprint
StarClose SE	Abbott	Extravascular nitinol clip	Femoral artery	5–6	Utilizes an extravascular nitinol clip to provide immediate repair; haemostasis can be challenged and confirmed on the table
Exoseal	Cordis	Extravascular sealant	Femoral artery	5–7	Deployed through existing procedural sheath (up to 12 cm) without impeding arterial blood flow, with two visual indicators; polyglycolic acid plug material, fully absorbable within 60–90 days
Mynx Control/ MynxGrip	Cordis	Extravascular sealant	Femoral artery and vein	5–7	Next-gen deployment system with two-button operation, compatible with the procedural sheath (up to 12 cm), tension indicator providing visual confirmation of device position; polyethylene glycol, dissolves in 30 days
Vascade MVP	Haemonetics	Extravascular bioabsorbable collagen plug	Femoral vein	6–12 inner diameter (max OD 15)	Designed for mid-bore, multiaccess femoral venous closure. Extravascular, bioabsorbable femoral venous closure system with proprietary collapsible disc technology and a thrombogenic resorbable collagen patch in a single design.
Vascade	Haemonetics	Extravascular bioabsorbable collagen plug	Femoral artery and vein	5–7	Designed for small-bore femoral arterial and venous closure, this extravascular, bioabsorbable system combines collapsible disc technology with a thrombogenic collagen patch in a single integrated design
Angio-Seal VIP	Terumo	Extravascular bioabsorbable collagen plug	Femoral artery	≤6; ≤8	Haemostasis is achieved by sealing the arteriotomy with an anchor and collagen plug, held together by a suture. All implantable components resorb within 90 days.
FemoSeal	Terumo	Mechanical seal (intra and extravascular) with 3 bioabsorbable components (inner and outer disk held together by sutures)	Femoral artery	≤7	Suture and polymer discs sandwich the arteriotomy. All components reabsorb within 90 days
Manta	Teleflex	Extravascular bioabsorbable collagen plug (reabsorbable collagen and anchor)	Femoral artery	10–20 inner diameter (12–25 OD)	Specifically designed for large-bore femoral artery access sites; no pre-closure needed. Deployment with auditory and visual cues for reliable closure. The 14 F device is for 10–14 F access sites (max OD 18 F), and the 18 F device is for 15–18 F access sites (max OD 25 F)

OD, outer diameter.



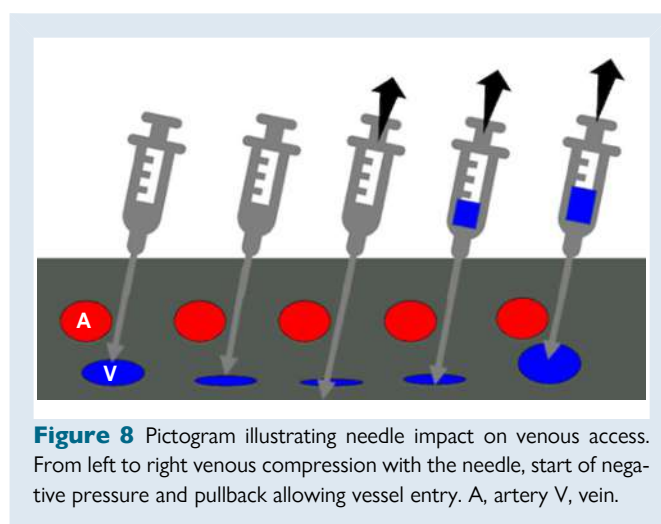
Recently, smart phone applications are being tested for telemonitoring of the patients and for tracking complications during the follow-up.^{89,90}

Percutaneous interventions can lead to various vascular complications, such as arteriovenous fistula, arterial pseudoaneurysm, retroperitoneal bleeding, haematoma, and infection. Early detection of these complications is essential for effective management and better patient outcomes.

The occurrence of a femoral pseudoaneurysm can be clinically suspected by the presence of a pulsatile mass, a palpable thrill, or an audible murmur. Ultrasound imaging confirms the diagnosis. Small pseudoaneurysms (less than 2 cm) may thrombose spontaneously.⁹¹ Ultrasound-guided compression is a common first-line treatment but carries a substantial risk of recurrence, especially in patients receiving anticoagulants.⁹² Alternate treatment options include surgical repair and percutaneous therapy with echo-guided thrombin or collagen injection, coil embolization or stent placement. Therapy selection depends on pseudoaneurysm and patient characteristics. Ultrasound-guided thrombin injection is a minimally invasive procedure performed under local anaesthesia and has a success rate of 91–100%. It is typically the preferred treatment for pseudoaneurysms measuring 1.5 to 6.5 cm in diameter and with a neck width less than 1 cm. Thrombin injection is disfavoured in pseudoaneurysms with a wider neck due to a higher risk of embolization and in multi-lobed pseudoaneurysms because of associated technical challenges. Surgical repair is considered as second treatment option due to inherent risk of complications and its use is limited in pseudoaneurysms with large neck, rapid expansion, skin necrosis, infection, or compression of neighbouring structures. Endovascular treatment is best suited for patients with comorbidities and high surgical risk.

The management of arteriovenous fistula varies depending on its size, associated symptoms and haemodynamic and local sequelae. Echo-guided compression should be implemented as a first-line therapy due to its non-invasive nature. One-third of femoral arteriovenous fistulae close spontaneously within one year. In case of persistent arteriovenous fistulae, associated limb damage or substantial left to right shunt, endovascular or surgical treatment is required with the latter being considered the gold standard.⁹³

Retroperitoneal bleeding is a rare but serious complication that significantly increases the risk of adverse cardiovascular outcomes and mortality.⁴⁴ It is more likely to occur with high femoral arterial puncture, above the inguinal ligament, preventing adequate vessel compression.



Clinical symptoms may be subtle including abdominal, flank and back pain, and physical findings may be unremarkable. Therefore, a high degree of clinical suspicion and vigilance is necessary. Contrast-enhanced computed tomography serves as the primary imaging modality for diagnosing retroperitoneal haematoma. Treatment approach vary from supportive care to vessel embolization or surgery and should be individualised.

6. Specific scenarios—tips and tricks

As indicated before, maintaining good hydration is paramount for success. If not necessary, patients should not fast before procedures. In cases of inadequate hydration, intravenous fluid supplementation with 0.9% saline or Ringer's lactate (0.5–1 L) can be administered to expand and visualise the veins. Valsalva manoeuvres or abdominal pressure along with abduction, external rotation of the leg and knee flexion can also help to expose and access the veins (Figure 7).^{94–96}

In case of collapsed veins due to fasting or bleeding, utilizing ultrasound becomes crucial. Colour Doppler and compression tests help to identify the vein and differentiating it from the artery, reducing the risk of accidental arterial puncture. Needle visualization can be enhanced by observing tissue movement (gentle back-and-forth

Table 3 Tips and tricks for vascular access in challenging situations

Category	Tips and tricks
Hydration	<ul style="list-style-type: none"> Maintain good hydration Avoid fasting if possible Use IV fluids (0.9% saline or Ringer's lactate)
Vein exposure	<ul style="list-style-type: none"> Valsalva manoeuvre/abdominal pressure Leg abduction, external rotation, knee flexion
Ultrasound guidance	Vein identification: <ul style="list-style-type: none"> Colour Doppler and Compression tests Needle visualization: <ul style="list-style-type: none"> Tremor technique (gentle back-and-forth movements) Echogenic needles
Dry vein access	<ul style="list-style-type: none"> Get access by retracting the needle with negative pressure
Vessel kinking	<ul style="list-style-type: none"> Use a stiff wire or the catheter for straightening the vein Consider coiled/long sheaths Change insertion site if needed
Inferior access obstruction	<ul style="list-style-type: none"> Consider alternative access sites (jugular, subclavian, or transhepatic)
Arterial femoral access	<ul style="list-style-type: none"> Use ultrasound for common femoral artery cannulation Consider superficial femoral artery access if bifurcation is high Use long sheaths in elderly or patients with atherosclerosis

movements, 'tremor' technique) or using echogenic needles.^{97,98} Advancing the needle in a dry vein may cause the walls to collapse and lead to an inadvertent puncture through both walls. Retracting the needle with negative pressure, can separate the walls, allowing blood withdrawal and confirming intravascular access (Figure 8).

After successful vascular access, vessel kinking can hinder further advancement. One approach is to use a stiff wire or catheter for straightening the vein out ('stenting') and maintain patency. If kinking persists, changing the insertion side or employing coiled (coil-wire design) or long sheaths can provide more support. In case of persistent obstruction of inferior access, presence of IVC filters or vessels atresia, consider alternative access via the jugular or SV, but also transhepatic access as described in Section 3.

For arterial femoral access, ultrasound is useful for visualizing the femoral bifurcation and identifying femoral calcification or the relationship to the femoral head.⁹⁹ In cases of high bifurcation, superficial femoral artery access may be an option, though it carries a higher risk of pseudoaneurysm.¹⁰⁰ Long sheaths can help reduce the risk of arterial dissection in all patients and especially those who are >65 years or have known atherosclerotic disease or tortuous vasculature. Table 3 lists a summary of practical tips to consider for optimizing vascular access success rate.

7. Training requirements

Proficiency in vascular access and closure is a critical skill set in cardiac EP, directly affecting patient safety and procedural outcomes. A

structured training is essential to ensure practitioners can perform tasks with confidence and precision.¹⁰¹

A solid knowledge of vascular anatomy forms the foundation for successful vascular access. Trainees need to be proficient in recognizing and navigating key access sites, such as the femoral, subclavian, and jugular veins, as well as the femoral artery.

Incorporating USG vascular access into the EP training curriculum is crucial due to its discussed clinical advantages. While specific training requirements for US-guided access in EP are yet to be established, drawing from intensive care practices suggests incorporating 50 supervised plus 50 independent US-guided femoral venous access cases as a potential target for training.¹⁰² Specific research suggests the actual learning curve may be much shorter and a plateau is already observed after a mean of 6 cases.¹⁰³ Additionally, training should include exposure to US-guided access to other vascular sites, such as the femoral artery, subclavian, and jugular veins, to ensure a comprehensive skill set for various clinical scenarios.

Trainees should master haemostasis techniques, including manual compression and suture methods. They should become familiar with VCDs, gaining broader exposure through external rotations in other catheterization labs.

Simulation-based training is a valuable component of EP education, offering a risk-free environment where trainees can develop and refine their skills.^{104,105} The use of 3D anatomical models, and virtual or augmented reality platforms allows for a realistic practice of procedures, from initial access to complication management.^{106,107} This approach not only builds technical proficiency but also enhances decision-making skills under simulated clinical pressures, bridging the gap between theoretical knowledge and practical application.

8. Economical aspects

Vascular complications occur in 2–4% of EP procedures and contribute significantly to healthcare costs.¹⁰⁸ Although many complications can be managed conservatively, they trigger further evaluation (ultrasound, CT scan) and therapeutic interventions (USG compression, thrombin injection, transfusion, surgical repair, covered stents, etc.), leading to increased direct costs and indirect costs such as increased length of stay and reduced availability for treating other patients.¹⁰⁹

After AF ablation, invasive treatment of complications occurs in 0.6–0.9% of patients, mostly for pseudoaneurysms after failed compression attempts (30% of cases).¹¹⁰ Direct costs can reach 500€, but indirect costs due to prolonged hospitalization and repetitive interventions can reach up to 15 544€. As a result, the average cost, irrespective to complications, is estimated to be 150€ per patient treated without ultrasound.¹⁰⁹ In contrast, ultrasound use has been associated with a 66% reduction in complications¹¹¹ and higher first-pass access-rates both for trainees and experts.⁷⁷ This was also partially achieved by omitting the femoral arterial line. Taken together, these strategies could save enough money (approximately 50 000€) to off-set the costs of ultrasound machines and staff-training with 1000 treated AF-patients.¹⁰⁹ Additionally, early thrombin therapy (rather than serial duplex scans) in patients with pseudoaneurysms after cardiac catheterization could achieve similar savings by expediting patient discharge.¹¹² Similar savings are expected by earlier thrombin injection for vascular complications after an EP procedure. Thus, vascular access should be performed under ultrasound guidance with systematic monitoring for potential complications and appropriate equipment, checklist and team support to ensure rapid response.^{79,113}

Since most of the costs for EP procedures are due to hospitalization,¹¹⁴ rapid haemostasis with VCDs can lead to faster ambulation, shorter length of stay, less medication, fewer additional interventions (urinary catheters) and even same-day discharge.^{71,72,115,116} The use of closure devices or figure-of-eight/Z-stitch can facilitate this better than manual compression.^{82,117–120} Together, these techniques can

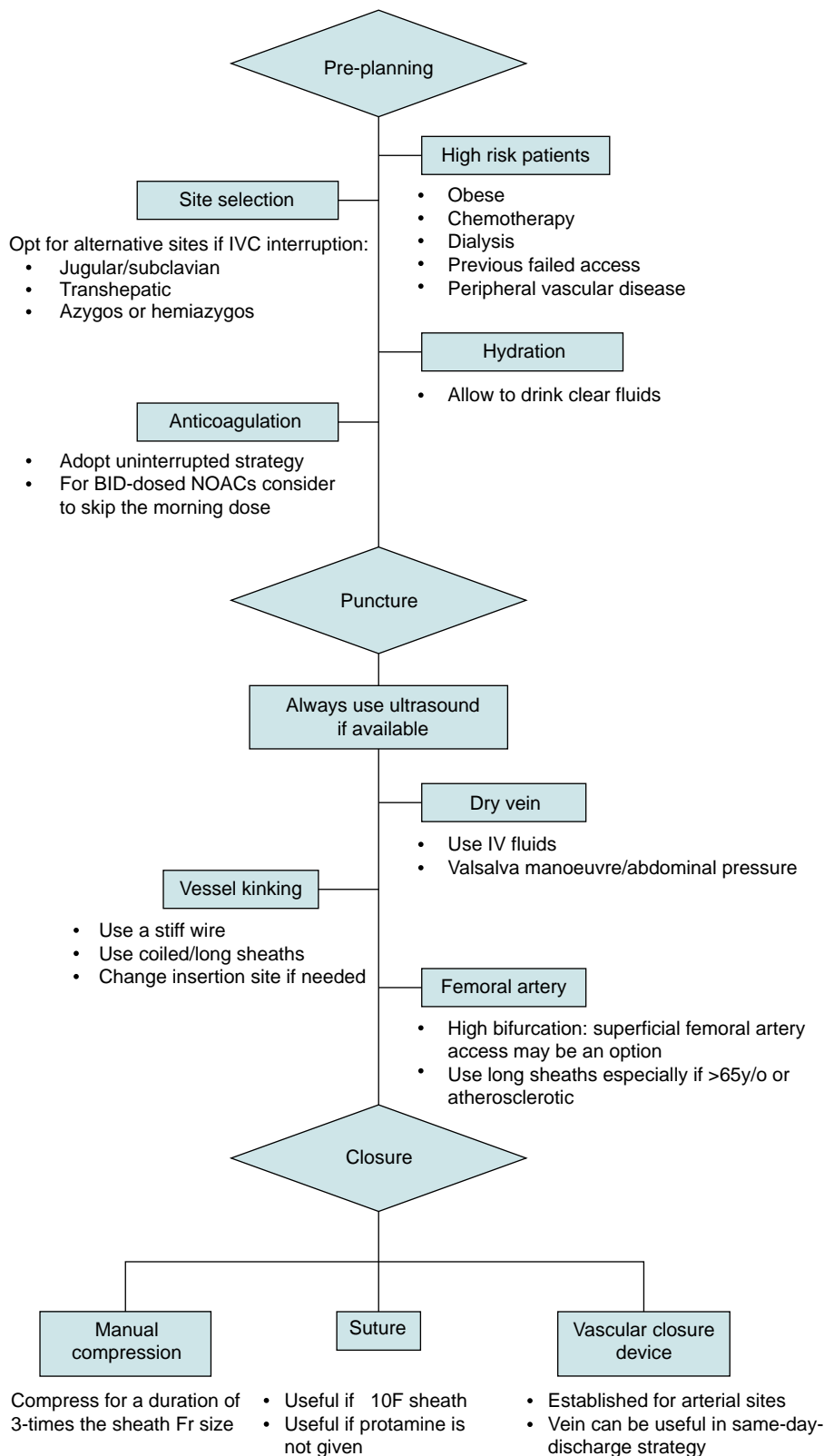


Figure 9 Vascular access flowchart. A step-by-step guide for vascular access site preparation, selection, puncture, and closure.

reduce health-care costs while reducing patient discomfort.¹²¹ In summary, incorporating USG access and effective closure techniques in EP interventions is cost-effective. Minimizing complications and systematically monitoring performance measures is crucial to improve cost-effectiveness and patient outcomes.

9. Gaps in evidence and future perspectives

While ultrasound guidance has demonstrably reduced complications in EP, significant knowledge gaps remain, hindering the optimisation of vascular access practices.

Current research largely focuses on comparing vascular closure devices against longer observation periods, often within single centres. This approach, while informative, suffers from limited generalizability due to the inherent biases and idiosyncrasies of local protocols. Additionally, comparing one closure technique to another against an aggressive mobilization protocol may artificially inflate the impact of devices on patient flow, neglecting the influence of sedation and other factors. Furthermore, the rarity of serious complications with ultrasound guidance necessitates large-scale studies to evaluate the impact of further innovations.

A crucial gap exists in understanding how vascular access devices truly impact patient flow and recovery. We lack knowledge on the optimal timing for early mobilization beyond the limitations imposed by vascular access itself. Similarly, the influence of pre-procedural hydration and other patient factors (e.g. obesity, anticoagulation) on first-attempt access and complications remains unexplored. Head-to-head comparisons of different devices and sheath combinations are also scarce, hindering informed decision-making in diverse clinical scenarios.

Current research often overlooks patient-reported outcomes like bruising, despite their significant impact on experience and satisfaction. Integrating these subjective measures would provide a more holistic understanding of patient well-being. Valuable insights can also be gleaned from vascular management practices in other specialities like interventional cardiology or radiology, fostering cross-disciplinary collaboration and knowledge exchange. Standardized data collection and sharing across teams and centres would further accelerate knowledge generation and benefit patients across the board.

The increasing adoption of the Z-suture closure method means that new technologies require rigorous evaluation beyond apparent ease-of-use and perceived effectiveness. Potential downsides like bleeding and pain, often hidden by the excellent post-procedural haemostasis of the z-suture, can negatively impact patient flow and experience. Robust evidence is essential before adopting new technologies, especially when established methods provide a high baseline standard.

Future research should focus on tailoring vascular access strategies to individual patient characteristics and risk profiles. This personalized approach holds the promise of optimising patient care and minimizing complications. By actively addressing these knowledge gaps and fostering collaborative research efforts, we can pave the way for robust, patient-centred, and evidence-based guidelines for vascular access in EP, ultimately leading to safer, more efficient, and less invasive procedures with improved patient outcomes.

10. Key messages

Techniques for vascular and pericardial access in EP laboratories continue to evolve, driven by technological advancements and a better understanding of anatomical complexities. The integration of

ultrasound guidance, innovative access and closure techniques, and personalized approaches for paediatric patients represents the forefront of this evolution. As the field progresses, continuous learning and adaptation to emerging technologies and techniques will remain essential for clinical electrophysiologists, ensuring optimal patient care and procedural success. There is room for a standardized workflow which can reduce vascular access complications by implementation of training protocols, use of imaging and appropriate selection of tools and techniques. Based on available evidence such a workflow should be able to reduce complications by several orders of magnitude compared to existing practice and be able to demonstrate its cost-effectiveness by focusing on the cost of the total patient journey (Figure 9).

11. Table of clinical advice

	Category of evidence	Strength of evidence
Advised TO DO		
Use ultrasound for all percutaneous vascular access to avoid complications	Published data	META and RCT ^{42, 76–79}
Use suture-based closure technique for earlier ambulation and reduction of access site complications when using large (≥ 10 F) sheaths	Published data	Small RCT ^{82, 83}
Use VCDs if minimum time to ambulation is desired	Published data	Observational and RCT ^{70–74}
May be appropriate TO DO		
Use heparin for right-sided procedures	Opinion	Consensus (>70% agreement)
Allow oral hydration before the procedure	Opinion	Consensus (>70% agreement)
Advised NOT TO DO		
Do not interrupt (>8 h) anticoagulation for AFib ablation with the purpose of bleeding risk reduction	Published data	META and RCT ^{15–24}
In case of suture closure, consider not to give protamine for heparin reversal	Opinion Published data	Strong consensus (>90% agreement) Observational ^{36,38}

Supplementary material

Supplementary material is available at *Europace* online.

Acknowledgements

The authors wish to thank the EHRA Scientific Document Committee for their contribution to this document: Prof Katja Zeppenfeld, Prof Jens

Cosedis Nielsen, Dr Luigi di Biase, Prof Isabel Deisenhofer, Prof Kristina Hermann Haugaa, Dr Daniel Keene, Prof Christian Meyer, Prof Petr Peichl, Prof Silvia Priori, Dr Alireza Sepehri Shamloo, Prof Markus Stühlinger, Prof Jacob Tfelt Hansen, Prof Arthur Wilde.

Conflict of interest: TJRDP declares being Chairperson for the EHRA selection Committee. MF declares speaker's fees from Medtronic, Abbott, Boston Scientific, Biosense Webster (J&J); and being present on advisory boards from Boston Scientific. MF is the founder & CMO of Echopoint Medical; director & CSO from Rhythm AI Ltd; founder & Shareholder of Epicardio Ltd; and received consultancy fees from Arta Health Ltd, Cathvision Inc. MF holds a patent US11647957B2 Ultrasound Probe. HR reports consultancy and speaker fees from Medtronic. RT is a consultant for Abbott, Boston Scientific, Biotronik and Biosense Webster and received speaker honoraria payment support for meetings or travel from Biosense Webster, Medtronic, Boston Scientific and Abbot Medical and research support from Abbott medical. None of the remaining authors declare any conflicts of interest.

References

- Boersma L, Andrade JG, Betts T, Duytschaever M, Pürerfellner H, Santoro F et al. Progress in atrial fibrillation ablation during 25 years of Europace journal. *Europace* 2023;**25**:eoad244.
- Guan W, Li X, Chen K, Yao Y, Liu J. Anatomical variation of femoral vessels and ultrasound-guided femoral vein puncture for catheter ablation of arrhythmias. *Pacing Clin Electrophysiol* 2024;**47**:330–5.
- Bass JE, Redwine MD, Kramer LA, Huynh PT, Harris JH. Spectrum of congenital anomalies of the inferior vena cava: cross-sectional imaging findings. *Radiographics* 2000;**20**: 639–52.
- Ginaldi S, Chuang VP, Wallace S. Absence of hepatic segment of the inferior vena cava with azygous continuation. *J Comput Assist Tomogr* 1980;**4**:112–4.
- Susan S. Section 4: Head and Neck (ed.), *Gray's Anatomy*. 42nd Ed. 2020.
- Al-Sinan A, Chan KH, Young GD, Martin A, Sepahpour A, Sy RW. Systematic review of electrophysiology procedures in patients with obstruction of the inferior vena cava. *J Cardiovasc Electrophysiol* 2022;**33**:1300–11.
- Liang JJ, Lin A, Mohanty S, Muser D, Briceno DF, Burkhardt JD et al. Radiofrequency-assisted transseptal access for atrial fibrillation ablation via a superior approach. *JACC Clin Electrophysiol* 2020;**6**:272–81.
- Martins RP, Behar N, Galand V, Basquin A, Daubert JC, Mabo P et al. Radiofrequency ablation of right ventricular tachycardia in patients with no femoral access: safety and efficacy of a superior approach. *Europace* 2019;**21**:803–9.
- Sureka B, Sharma N, Khera PS, Garg PK, Yadav T. Hepatic vein variations in 500 patients: surgical and radiological significance. *Br J Radiol* 2019;**92**:20190487.
- Singh SM, Neuzil P, Skoka J, Kriz R, Popelova J, Love BA et al. Percutaneous transhepatic venous access for catheter ablation procedures in patients with interruption of the inferior vena cava. *Circ Arrhythm Electrophysiol* 2011;**4**: 235–41.
- Nguyen DT, Gupta R, Kay J, Fagan T, Lowery C, Collins KK et al. Percutaneous transhepatic access for catheter ablation of cardiac arrhythmias. *Europace* 2013;**15**: 494–500.
- Ruggeberg A, Nickel EA. Unrestricted drinking before surgery: an iterative quality improvement study. *Anaesthesia* 2022;**77**:1386–94.
- Marsman M, Kappen TH, Vernooij LM, van der Hout EC, van Waes JA, van Klei WA. Association of a liberal fasting policy of clear fluids before surgery with fasting duration and patient well-being and safety. *JAMA Surg* 2023;**158**:254–63.
- Van Gelder IC, Rienstra M, Bunting KV, Casado-Arroyo R, Caso V, Crijns HJGM et al. 2024 ESC Guidelines for the management of atrial fibrillation developed in collaboration with the European Association for Cardio-Thoracic Surgery (EACTS). *Eur Heart J* 2024;**45**:3314–414.
- Di Biase L, Burkhardt JD, Santangeli P, Mohanty P, Sanchez JE, Horton R et al. Periprocedural stroke and bleeding complications in patients undergoing catheter ablation of atrial fibrillation with different anticoagulation management: results from the Role of Coumadin in Preventing Thromboembolism in Atrial Fibrillation (AF) Patients Undergoing Catheter Ablation (COMPARE) randomized trial. *Circulation* 2014;**129**: 2638–44.
- Kirchhof P, Haeusler KG, Blank B, De Bono J, Callans D, Elvan A et al. Apixaban in patients at risk of stroke undergoing atrial fibrillation ablation. *Eur Heart J* 2018;**39**: 2942–55.
- Cappato R, Marchlinski FE, Hohnloser SH, Naccarelli GV, Xiang J, Wilber DJ et al. Uninterrupted rivaroxaban vs. uninterrupted vitamin K antagonists for catheter ablation in non-valvular atrial fibrillation. *Eur Heart J* 2015;**36**:1805–11.
- Kimura T, Kashimura S, Nishiyama T, Katsumata Y, Inagawa K, Ikegami Y et al. Asymptomatic cerebral infarction during catheter ablation for atrial fibrillation: comparing uninterrupted rivaroxaban and warfarin (ASCERTAIN). *JACC Clin Electrophysiol* 2018;**4**:1598–609.
- Calkins H, Willems S, Gerstenfeld EP, Verma A, Schilling R, Hohnloser SH et al. Uninterrupted dabigatran versus warfarin for ablation in atrial fibrillation. *N Engl J Med* 2017;**376**:1627–36.
- Kuwahara T, Abe M, Yamaki M, Fujieda H, Abe Y, Hashimoto K et al. Apixaban versus warfarin for the prevention of periprocedural cerebral thromboembolism in atrial fibrillation ablation: multicenter prospective randomized study. *J Cardiovasc Electrophysiol* 2016;**27**:549–54.
- Hohnloser SH, Camm J, Cappato R, Diener HC, Heidbuchel H, Mont L et al. Uninterrupted edoxaban vs. vitamin K antagonists for ablation of atrial fibrillation: the ELIMINATE-AF trial. *Eur Heart J* 2019;**40**:3013–21.
- Romero J, Cerrud-Rodriguez RC, Alviz I, Diaz JC, Rodriguez D, Arshad S et al. Significant benefit of uninterrupted DOACs versus VKA during catheter ablation of atrial fibrillation. *JACC Clin Electrophysiol* 2019;**5**:1396–405.
- Gorla R, Dentali F, Crippa M, Marazzato J, Di Minno MND, Grandi AM et al. Perioperative safety and efficacy of different anticoagulation strategies with direct oral anticoagulants in pulmonary vein isolation: a meta-analysis. *JACC Clin Electrophysiol* 2018;**4**:794–806.
- Mao YJ, Wang H, Huang PF. Meta-analysis of the safety and efficacy of using minimally interrupted novel oral anticoagulants in patients undergoing catheter ablation for atrial fibrillation. *J Interv Card Electrophysiol* 2021;**60**:407–17.
- Kim DH, Pawar A, Gagne JJ, Bessette LG, Lee H, Glynn RJ et al. Frailty and clinical outcomes of direct oral anticoagulants versus warfarin in older adults with atrial fibrillation: a cohort study. *Ann Intern Med* 2021;**174**:1214–23.
- Tzeis S, Gerstenfeld EP, Kalman J, Saad EB, Sepehri Shamloo A, Andrade JG et al. 2024 European Heart Rhythm Association/Heart Rhythm Society/Asia Pacific Heart Rhythm Society/Latin American Heart Rhythm Society expert consensus statement on catheter and surgical ablation of atrial fibrillation. *Europace* 2024;**26**:euae043.
- Steffel J, Collins R, Antz M, Cornu P, Desteghe L, Haeusler KG et al. 2021 European Heart Rhythm Association Practical Guide on the use of non-vitamin K antagonist oral anticoagulants in patients with atrial fibrillation. *Europace* 2021;**23**:1612–76.
- Di Biase L, Gaita F, Toso E, Santangeli P, Mohanty P, Rutledge N et al. Does periprocedural anticoagulation management of atrial fibrillation affect the prevalence of silent thromboembolic lesion detected by diffusion cerebral magnetic resonance imaging in patients undergoing radiofrequency atrial fibrillation ablation with open irrigated catheters? Results from a prospective multicenter study. *Heart Rhythm* 2014;**11**:791–8.
- Zeppenfeld K, Tfelt-Hansen J, de Riva M, Winkel BG, Behr ER, Blom NA et al. 2022 ESC Guidelines for the management of patients with ventricular arrhythmias and the prevention of sudden cardiac death. *Eur Heart J* 2022;**43**:3997–4126.
- Cronin EM, Bogun FM, Maury P, Peichl P, Chen M, Namboodiri N et al. 2019 HRS/EHRA/APHRS/LAHS expert consensus statement on catheter ablation of ventricular arrhythmias. *Heart Rhythm* 2020;**17**:e2–154.
- Sticherling C, Marin F, Birnie D, Boriani G, Calkins H, Dan GA et al. Antithrombotic management in patients undergoing electrophysiological procedures: a European Heart Rhythm Association (EHRA) position document endorsed by the ESC Working Group Thrombosis, Heart Rhythm Society (HRS), and Asia Pacific Heart Rhythm Society (APHRS). *Europace* 2015;**17**:1197–214.
- Ghannam M, Chugh A, Dillon P, Alyesh D, Kossidas K, Sharma S et al. Protamine to expedite vascular hemostasis after catheter ablation of atrial fibrillation: a randomized controlled trial. *Heart Rhythm* 2018;**15**:1642–7.
- Kewcharoen J, Shah K, Bhardwaj R, Contractor T, Turagam MK, Mandapati R et al. Periprocedural outcomes of protamine administration after catheter ablation of atrial fibrillation. *Rev Cardiovasc Med* 2022;**23**:34.
- Conte G, de Asmundis C, Baltogiannis G, Di Giovanni G, Ciconte G, Seira J et al. Periprocedural outcomes of prophylactic protamine administration for reversal of heparin after cryoballoon ablation of atrial fibrillation. *J Interv Card Electrophysiol* 2014;**41**:129–34.
- Chilukuri K, Henrikson CA, Dalal D, Scherr D, MacPherson EC, Cheng A et al. Incidence and outcomes of protamine reactions in patients undergoing catheter ablation of atrial fibrillation. *J Interv Card Electrophysiol* 2009;**25**:175–81.
- Yasar SJ, Bickel T, Zhang S, Akkaya M, Aznaurov SG, Krishnan K et al. Heparin reversal with protamine sulfate is not required in atrial fibrillation ablation with suture hemostasis. *J Cardiovasc Electrophysiol* 2019;**30**:2811–7.
- Al-Ahmad A, Mittal S, DeLurgio D, Joseph Gallinghouse G, Horton RP, Preminger MW et al. Results from the prospective, multicenter AMBULATE-CAP trial: reduced use of urinary catheters and protamine with hemostasis via the Mid-Bore Venous Vascular Closure System (VASCADE(R) MVP) following multi-access cardiac ablation procedures. *J Cardiovasc Electrophysiol* 2021;**32**:191–9.
- Velagic V, Mugnai G, Pasara V, Prepolec I, Puljevic M, Pezo-Nikolic B et al. Use of figure of eight suture for groin closure with no heparin reversal in patients undergoing cryoballoon ablation for atrial fibrillation. *J Interv Card Electrophysiol* 2021;**60**:433–8.
- Kottmaier M, Bourrier F, Reents T, Reiter A, Kornmayer M, Semmler V et al. Safety and feasibility of subcutaneous purse-string suture of the femoral vein after electrophysiological procedures on uninterrupted oral anticoagulation. *Am J Cardiol* 2017;**119**:1781–4.

40. Calkins H, Hindricks G, Cappato R, Kim YH, Saad EB, Aguinaga L et al. 2017 HRS/EHRA/ECAS/APHS/SOLAECE expert consensus statement on catheter and surgical ablation of atrial fibrillation. *Europace* 2018;**20**:e1–160.
41. Weiner MM, Geldard P, Mittnacht AJ. Ultrasound-guided vascular access: a comprehensive review. *J Cardiothorac Vasc Anesth* 2013;**27**:345–60.
42. Triantafyllou K, Karkos CD, Fragakis N, Antoniadis AP, Meletidou M, Vassilikos V. Ultrasound-guided versus anatomic landmark-guided vascular access in cardiac electrophysiology procedures: a systematic review and meta-analysis. *Indian Pacing Electrophysiol J* 2022;**22**:145–53.
43. Millington SJ, Colvin MO, Shiloh AL, Koenig S. How I do it: ultrasound-guided internal jugular and femoral central venous catheter insertion. *Chest* 2020;**158**:2425–30.
44. Kwok CS, Kontopantelis E, Kinnaird T, Potts J, Rashid M, Shoaib A et al. Retroperitoneal hemorrhage after percutaneous coronary intervention: incidence, determinants, and outcomes as recorded by the British Cardiovascular Intervention Society. *Circ Cardiovasc Interv* 2018;**11**:e005866.
45. Park SY, Jeong W, Choi YD, Chung BH, Hong SJ, Rha KH. Yonsei experience in robotic urologic surgery-application in various urological procedures. *Yonsei Med J* 2008;**49**: 897–900.
46. Bangalore S, Bhatt DL. Femoral arterial access and closure. *Circulation* 2011;**124**: e147–56.
47. Ding WY, Khanra D, Kozhuharov N, Shaw M, Luther V, Ashrafi R et al. Incidence of vascular complications for electrophysiology procedures in the ultrasound era: a single-centre experience over 10,000 procedures in the long term. *J Interv Card Electrophysiol* 2023;**66**:693–700.
48. Ziacchi M, Placci A, Angeletti A, Quartieri F, Balla C, Virzi S et al. Vascular accesses in cardiac stimulation and electrophysiology: an Italian Survey Promoted by ALAC (Italian Association of Arrhythmias and Cardiac Pacing). *Biology (Basel)* 2022;**11**:265.
49. Bohora S, Tharakan J. Internal jugular/subclavian venous access in electrophysiology study and ablation. *Indian Pacing Electrophysiol J* 2009;**9**:190–4.
50. Santangeli P, Kodali S, Liang JJ. How to perform left atrial transeptal access and catheter ablation of atrial fibrillation from a superior approach. *J Cardiovasc Electrophysiol* 2020;**31**:293–9.
51. Ebeid MR. Transhepatic vascular access for diagnostic and interventional procedures: techniques, outcome, and complications. *Catheter Cardiovasc Interv* 2007;**69**:594–606.
52. Lee PC, Hwang B, Chen SA, Tai CG, Chen YJ, Chiang CE et al. The results of radiofrequency catheter ablation of supraventricular tachycardia in children. *Pacing Clin Electrophysiol* 2007;**30**:655–61.
53. Kugler JD, Danford DA, Houston K, Felix G. Radiofrequency catheter ablation for paroxysmal supraventricular tachycardia in children and adolescents without structural heart disease. Pediatric EP Society, Radiofrequency Catheter Ablation Registry. *Am J Cardiol* 1997;**80**:1438–43.
54. Paul T, Krause U, Sanatani S, Etheridge SP. Advancing the science of management of arrhythmic disease in children and adult congenital heart disease patients within the last 25 years. *Europace* 2023;**25**:euaad155.
55. Adlan AM, Campbell T, Fairbairn T, Aggarwal S, Nawaytou O, Penha D et al. Retrograde aortic access during ventricular tachycardia ablation: indications, techniques, and challenges. *J Cardiovasc Electrophysiol* 2019;**30**:2629–39.
56. Borisinova E, Peichl P, Wichterle D, Sramko M, Aldhoon B, Franekova J et al. Impact of access route to the left ventricle on asymptomatic periprocedural brain injury: the results of a randomized trial in patients undergoing catheter ablation of ventricular tachycardia. *Europace* 2021;**23**:610–5.
57. Sosa E, Scanavacca M, d'Avila A, Pilleggi F. A new technique to perform epicardial mapping in the electrophysiology laboratory. *J Cardiovasc Electrophysiol* 1996;**7**:531–6.
58. Tonko JB, Lambiase PD. Current and novel percutaneous epicardial access techniques for electrophysiological interventions: a comparison of procedural success and safety. *J Cardiovasc Electrophysiol* 2023;**34**:2330–41.
59. Natale A, Zeppenfeld K, Della Bella P, Liu X, Sabbag A, Santangeli P et al. Twenty-five years of catheter ablation of ventricular tachycardia: a look back and a look forward. *Europace* 2023;**25**:euaad225.
60. Subramanian M, Ravilla VV, Yalagudri S, Saggi DK, Rangaswamy VV, d'Avila A et al. CT-guided percutaneous epicardial access for ventricular tachycardia ablation: a proof-of-concept study. *J Cardiovasc Electrophysiol* 2021;**32**:2665–72.
61. Shim DJ, Maher TR, Laham RJ, Santangeli P, Zimetbaum PJ, d'Avila A. Novel use of pre-procedure imaging for planning and guidance of right atrium-to-left ventricle access for catheter ablation of ventricular tachycardia. *HeartRhythm Case Rep* 2021;**7**:726–30.
62. Wang TKM, Wang MTM, Martin A. Meta-analysis of ultrasound-guided vs conventional vascular access for cardiac electrophysiology procedures. *J Arrhythm* 2019;**35**:858–62.
63. Grimaldi M, Marino MM, Vitulano N, Quadri F, Troisi F, Caporusso N et al. Cardiopulmonary support during catheter ablation of ventricular arrhythmias with hemodynamic instability: the role of inducibility. *Front Cardiovasc Med* 2021;**8**:747858.
64. Danial P, Hajage D, Nguyen LS, Mastroianni C, Demondion P, Schmidt M et al. Percutaneous versus surgical femoro-femoral veno-arterial ECMO: a propensity score matched study. *Intensive Care Med* 2018;**44**:2153–61.
65. Wang L, Yang F, Zhang S, Li C, Du Z, Rycus P et al. Percutaneous versus surgical cannulation for femoro-femoral VA-ECMO in patients with cardiogenic shock: results from the extracorporeal life support organization registry. *J Heart Lung Transplant* 2022;**41**:470–81.
66. Miceli A, Murzi M, Gilmanov D, Fugà R, Ferrarini M, Solinas M et al. Minimally invasive aortic valve replacement using right minithoracotomy is associated with better outcomes than ministernotomy. *J Thorac Cardiovasc Surg* 2014;**148**:133–7.
67. Goldsweig AM, Secemsky EA. Vascular access and closure for peripheral arterial intervention. *Interv Cardiol Clin* 2020;**9**:117–24.
68. van Wiechen MP, Ligthart JM, Van Mieghem NM. Large-bore vascular closure: new devices and techniques. *Interv Cardiol* 2019;**14**:17–21.
69. Sandoval Y, Basir MB, Lemor A, Lichaa H, Alasnag M, Dupont A et al. Optimal large-bore femoral access, indwelling device management, and vascular closure for percutaneous mechanical circulatory support. *Am J Cardiol* 2023;**206**:262–76.
70. Natale A, Mohanty S, Liu PY, Mittal S, Al-Ahmad A, De Lurgio DB et al. Venous vascular closure system versus manual compression following multiple access electrophysiology procedures: the AMBULATE trial. *JACC Clin Electrophysiol* 2020;**6**:111–24.
71. Fabbriatore D, Buytaert D, Valeriano C, Mileva N, Paolisso P, Nagumo S et al. Ambulatory pulmonary vein isolation workflow using the Perclose ProGlide™ suture-mediated vascular closure device: the PRO-PVI study. *Europace* 2023;**25**: 1361–8.
72. Castro-Urda V, Segura-Dominguez M, Jiménez-Sánchez D, Aguilera-Agudo C, García-Izquierdo E, De la Rosa Rojas Y et al. Efficacy and safety of ProGlide use and early discharge after atrial fibrillation ablation compared to standard approach. PROFA trial. *Pacing Clin Electrophysiol* 2023;**46**:598–606.
73. Tilz RR, Feher M, Vogler J, Bode K, Duta AI, Ortolan A et al. Venous vascular closure system vs. figure-of-eight suture following atrial fibrillation ablation: the STYLE-AF study. *Europace* 2024;**26**:euae105.
74. Tilz RR, Vogler J, Kirstein B, Eitel C, Phan HL, Popescu S et al. Pulsed field ablation-based pulmonary vein isolation using a simplified single-access single-catheter approach- the fast and furious PFA study. *Circ J* 2023;**87**:1722–6.
75. Chikata A, Kato T, Usuda K, Fujita S, Maruyama M, Otowa KI et al. Preclose versus postclose using suture-mediated vascular closure system for catheter ablation with femoral vein access. *JACC Clin Electrophysiol* 2024;**10**:1828–36.
76. Wynn GJ, Haq I, Hung J, Bonnett LJ, Lewis G, Webber M et al. Improving safety in catheter ablation for atrial fibrillation: a prospective study of the use of ultrasound to guide vascular access. *J Cardiovasc Electrophysiol* 2014;**25**:680–5.
77. Yamagata K, Wichterle D, Roubicek T, Jarkovsky P, Sato Y, Kogure T et al. Ultrasound-guided versus conventional femoral venipuncture for catheter ablation of atrial fibrillation: a multicentre randomized efficacy and safety trial (ULTRA-FAST trial). *Europace* 2018;**20**:1107–14.
78. Sharma PS, Padala SK, Gunda S, Koneru JN, Ellenbogen KA. Vascular complications during catheter ablation of cardiac arrhythmias: a comparison between vascular ultrasound guided access and conventional vascular access. *J Cardiovasc Electrophysiol* 2016;**27**:1160–6.
79. Ströker E, de Asmundis C, Kupics K, Takarada K, Mugnai G, De Cocker J et al. Value of ultrasound for access guidance and detection of subclinical vascular complications in the setting of atrial fibrillation cryoballoon ablation. *Europace* 2019;**21**:434–9.
80. Foerschner L, Erhard N, Dorfmeister S, Telishevska M, Kottmaier M, Bourrier F et al. Ultrasound-guided access reduces vascular complications in patients undergoing catheter ablation for cardiac arrhythmias. *J Clin Med* 2022;**11**:6766.
81. Plasek J, Wichterle D, Peichl P, Cihak R, Jarkovsky P, Roubicek T et al. Gender differences in major vascular complications of catheter ablation for atrial fibrillation. *J Cardiovasc Electrophysiol* 2021;**32**:647–56.
82. Pracon R, Bangalore S, Henzel J, Cendrowska-Demkow I, Pregowska-Chwala B, Tarnowska A et al. A randomized comparison of modified subcutaneous “Z”-stitch versus manual compression to achieve hemostasis after large caliber femoral venous sheath removal. *Catheter Cardiovasc Interv* 2018;**91**:105–12.
83. Kumar V, Wish M, Venkataraman G, Bliden K, Jindal M, Strickberger A. A randomized comparison of manual pressure versus figure-of-eight suture for hemostasis after cryoballoon ablation for atrial fibrillation. *J Cardiovasc Electrophysiol* 2019;**30**: 2806–10.
84. Mills MT, Calvert P, Lip GYH, Luther V, Gupta D. Outcomes of vascular closure devices for femoral venous hemostasis following catheter ablation of atrial fibrillation. *J Cardiovasc Electrophysiol* 2024;**35**:1656–62.
85. Paraggio L, Bianchini F, Aurigemma C, Romagnoli E, Bianchini E, Zito A et al. Femoral large bore sheath management: how to prevent vascular complications from vessel puncture to sheath removal. *Circ Cardiovasc Interv* 2024;**17**:e014156.
86. Noori VJ, Eldrup-Jørgensen J. A systematic review of vascular closure devices for femoral artery puncture sites. *J Vasc Surg* 2018;**68**:887–99.
87. Jiang J, Zou J, Ma H, Jiao Y, Yang H, Zhang X et al. Network meta-analysis of randomized trials on the safety of vascular closure devices for femoral arterial puncture site haemostasis. *Sci Rep* 2015;**5**:13761.
88. Meis A, Osada N, Schlegel PM, Fischbach R, Heindel W, Kloska SP. Sonographic follow-up of the access site after arterial angiography: impact on the detected complication rate. *J Ultrasound Med* 2009;**28**:1151–7.

89. Bottoni E, Mangiameli G, Testori A, Piccioni F, Giudici VM, Voulaz E et al. Early hospital discharge on day two post robotic lobectomy with telehealth home monitoring: a pilot study. *Cancers (Basel)* 2023;**15**:1146.
90. Svennberg E, Caiani EG, Bruining N, Desteghe L, Han JK, Narayan SM et al. The digital journey: 25 years of digital development in electrophysiology from an Europace perspective. *Europace* 2023;**25**:euaad176.
91. Madaia C. Management trends for postcatheterization femoral artery pseudoaneurysms. *JAAPA* 2019;**32**:15–8.
92. Yoo T, Starr JE, Go MR, Vaccaro PS, Satiani B, Haurani MJ. Ultrasound-guided thrombin injection is a safe and effective treatment for femoral artery pseudoaneurysm in the morbidly obese. *Vasc Endovascular Surg* 2017;**51**:368–72.
93. Kelm M, Perings SM, Jax T, Lauer T, Schoebel FC, Heintzen MP et al. Incidence and clinical outcome of iatrogenic femoral arteriovenous fistulas: implications for risk stratification and treatment. *J Am Coll Cardiol* 2002;**40**:291–7.
94. Werner SL, Jones RA, Emerman CL. Effect of hip abduction and external rotation on femoral vein exposure for possible cannulation. *J Emerg Med* 2008;**35**:73–5.
95. Czyzewska D, Ustymowicz A, Kowalewski R, Zurada A, Krejza J. Cross-sectional area of the femoral vein varies with leg position and distance from the inguinal ligament. *PLoS One* 2017;**12**:e0182623.
96. Futyma P, Ciapala K, Sander J, Gluszczyk R, Futyma M, Kulakowski P. Ultrasound-guided venous access facilitated by the Valsalva maneuver during invasive electrophysiological procedures. *Kardiol Pol* 2020;**78**:235–9.
97. Scholten HJ, Pourtaherian A, Mihajlovic N, Korsten HHM, A Bouwman R. Improving needle tip identification during ultrasound-guided procedures in anaesthetic practice. *Anaesthesia* 2017;**72**:889–904.
98. Franco-Sadud R, Schnobrich D, Mathews BK, Candotti C, Abdel-Ghani S, Perez MG et al. Recommendations on the use of ultrasound guidance for central and peripheral vascular access in adults: a position statement of the society of hospital medicine. *J Hosp Med* 2019;**14**:E1–E22.
99. Seto AH, Abu-Fadel MS, Sparling JM, Zacharias SJ, Daly TS, Harrison AT et al. Real-time ultrasound guidance facilitates femoral arterial access and reduces vascular complications: FAUST (Femoral Arterial Access With Ultrasound Trial). *JACC Cardiovasc Interv* 2010;**3**:751–8.
100. Sandoval Y, Burke MN, Lobo AS, Lips DL, Seto AH, Chavez I et al. Contemporary arterial access in the cardiac catheterization laboratory. *JACC Cardiovasc Interv* 2017;**10**:2233–41.
101. Trines SA, Moore P, Burri H, Gonçalves Nunes S, Massoulié G, Merino JL et al. 2024 updated European Heart Rhythm Association core curriculum for physicians and allied professionals: a statement of the European Heart Rhythm Association of the European Society of Cardiology. *Europace* 2024;**26**:euae243.
102. Lamperti M, Bodenham AR, Pittiruti M, Blaivas M, Augoustides JG, Elbarbary M et al. International evidence-based recommendations on ultrasound-guided vascular access. *Intensive Care Med* 2012;**38**:1105–17.
103. Errahmouni A, Bun SS, Latcu DG, Saoudi N. Ultrasound-guided venous puncture in electrophysiological procedures: a safe method, rapidly learned. *Pacing Clin Electrophysiol* 2014;**37**:1023–8.
104. Davidson IJ, Yoo MC, Biasucci DG, Browne P, Dees C, Dolmatch B et al. Simulation training for vascular access interventions. *J Vasc Access* 2010;**11**:181–90.
105. Tjong FVY, Perrotta L, Goette A, Duncker D, Vernooy K, Boveda S et al. Utilization of and perceived need for simulators in clinical electrophysiology: results from an EHRA physician survey. *Europace* 2024;**26**:euae037.
106. Sheu AY, Laidlaw GL, Fell JC, Triana BP, Goettl CS, Shah RP. Custom 3-dimensional printed ultrasound-compatible vascular access models: training medical students for vascular access. *J Vasc Interv Radiol* 2019;**30**:922–7.
107. García-Carpintero E, Naredo E, Vélez-Vélez E, Fuensalida G, Ortiz-Miluy G, Gómez-Moreno C. Phantoms for ultrasound-guided vascular access cannulation training: a narrative review. *Med Ultrason* 2023;**25**:201–7.
108. Hindricks G, Potpara T, Dagres N, Arbelo E, Bax JJ, Blomstrom-Lundqvist C et al. 2020 ESC Guidelines for the diagnosis and management of atrial fibrillation developed in collaboration with the European Association for Cardio-Thoracic Surgery (EACTS): The Task Force for the diagnosis and management of atrial fibrillation of the European Society of Cardiology (ESC) developed with the special contribution of the European Heart Rhythm Association (EHRA) of the ESC. *Eur Heart J* 2021;**42**:373–498.
109. Bode K, Ueberham L, Gawlik S, Hindricks G, Bollmann A. Inguinal vascular complications after ablation of atrial fibrillation: an economic impact assessment. *Europace* 2019;**21**:91–8.
110. Kugelmass AD, Cohen DJ, Brown PP, Simon AW, Becker ER, Culler SD. Hospital resources consumed in treating complications associated with percutaneous coronary interventions. *Am J Cardiol* 2006;**97**:322–7.
111. Sobolev M, Shiloh AL, Di Biase L, Slovut DP. Ultrasound-guided cannulation of the femoral vein in electrophysiological procedures: a systematic review and meta-analysis. *Europace* 2017;**19**:850–5.
112. Stone PA, Aburahma AF, Flaherty SK. Reducing duplex examinations in patients with iatrogenic pseudoaneurysms. *J Vasc Surg* 2006;**43**:1211–5.
113. Kirchhof P, Breithardt G, Bax J, Benninger G, Blomstrom-Lundqvist C, Boriani G et al. A roadmap to improve the quality of atrial fibrillation management: proceedings from the fifth Atrial Fibrillation Network/European Heart Rhythm Association consensus conference. *Europace* 2016;**18**:37–50.
114. Patel NJ, Atti V, Mitrani RD, Viles-Gonzalez JF, Goldberger JJ. Global rising trends of atrial fibrillation: a major public health concern. *Heart* 2018;**104**:1989–90.
115. Mahadevan VS, Jimeno S, Benson LN, McLaughlin PR, Horlick EM. Pre-closure of femoral venous access sites used for large-sized sheath insertion with the Perclose device in adults undergoing cardiac intervention. *Heart* 2008;**94**:571–2.
116. Al-Ahmad A, Mittal S, DeLurgio D, Joseph Gallinghouse G, Horton RP, Preminger MW et al. Results from the prospective, multicenter AMBULATE-CAP trial: reduced use of urinary catheters and protamine with hemostasis via the Mid-Bore Venous Vascular Closure System (VASCARE® MVP) following multi-access cardiac ablation procedures. *J Cardiovasc Electrophysiol* 2021;**32**:191–9.
117. Mohammed M, Ramirez R, Steinhaus DA, Yousuf OK, Giocondo MJ, Ramza BM et al. Comparative outcomes of vascular access closure methods following atrial fibrillation/flutter catheter ablation: insights from VAScular Closure for Cardiac Ablation Registry. *J Interv Card Electrophysiol* 2022;**64**:301–10.
118. Aytemir K, Canpolat U, Yorgun H, Evranos B, Kaya EB, Şahiner ML et al. Usefulness of 'figure-of-eight' suture to achieve haemostasis after removal of 15-French calibre femoral venous sheath in patients undergoing cryoablation. *Europace* 2016;**18**:1545–50.
119. Kumar P, Aggarwal P, Sinha SK, Pandey U, Razi M, Sharma AK et al. Efficacy and safety of subcutaneous fellow's stitch using "Fisher's Knot" technique to achieve large caliber (>10 French) venous hemostasis. *Cardiol Res* 2019;**10**:303–8.
120. Fabella A, Markovic LE, Coleman AE. Comparison of manual compression, Z-stitch, and suture-mediated vascular closure device techniques in dogs undergoing percutaneous transvenous intervention. *J Vet Cardiol* 2024;**51**:124–37.
121. Steinberg BA, Woolley S, Li H, Crawford C, Groh CA, Navaravong L et al. Patient-reported outcomes and costs associated with vascular closure and same-day discharge following atrial fibrillation ablation. *J Cardiovasc Electrophysiol* 2022;**33**:1737–44.