

Cricopharyngeal myotomy with thulium laser through flexible endoscopy: proof-of-concept study



Authors

Stefano Siboni, Alberto Aiolfi, Chiara Ceriani, Gian Eugenio Tontini, Luigi Bonavina

Institution

University of Milan, Department of Biomedical Sciences for Health, Division of General Surgery, IRCCS Policlinico San Donato, Milan, Italy

submitted 17.8.2017

accepted after revision 27.12.2017

Bibliography

DOI <https://doi.org/10.1055/a-0581-8789> |

Endoscopy International Open 2018; 06: E470–E473

© Georg Thieme Verlag KG Stuttgart · New York

ISSN 2364-3722

Corresponding author

Prof. Luigi Bonavina, Divisione Universitaria di Chirurgia Generale, IRCCS Policlinico San Donato, Piazza Malan 2, San Donato Milanese (Milano) 20097, Milan, Italy
Fax: +02-52774840
luigi.bonavina@unimi.it

ABSTRACT

Background and study aims Endoscopic treatment of Zenker's diverticulum has proven feasible, but electrocautery and CO₂ laser technology carry the risk of collateral thermal injury. Thulium laser septum incision may over-

come this limitation. We describe for the first time the use of thulium laser through flexible endoscopy in a small cohort of patients with Zenker diverticulum.

Patients and methods Thulium laser septum division was performed via flexible endoscopy under general anesthesia in consecutive symptomatic patients with primary or recurrent Zenker diverticulum. Primary study outcomes were feasibility and safety of the procedure. A 1.9- μ m laser fiber was used with an emission power of 10–16W.

Results Five patients were treated between May and June 2017. Two patients presented with recurrent symptomatic diverticulum after previous transoral septum stapling. Complete division of the septum was achieved in all patients. There was no bleeding nor need of adjunctive electrocautery devices to complete the procedure. The postoperative course was uneventful in all patients; the chest film and gastrographin swallow study on postoperative Day 1 were negative for pneumomediastinum, leaks or residual pouch. All patients were discharged within 48 hours on a soft diet. At the 1- and 3-month follow-up visits, all patients were satisfied with the procedure and reported improved swallowing and absence of regurgitation and cough.

Conclusions Division of Zenker's septum with thulium laser is feasible and safe through flexible endoscopy. Longer-term follow-up is required to establish efficacy and effectiveness of this novel procedure.

Introduction

The aim of transoral treatment of Zenker diverticulum is to divide the cricopharyngeal muscle contained in the septum, i.e. the posterior common wall separating the pouch from the esophagus. The transoral approach through rigid endoscopy (with stapler, CO₂-laser, harmonic scalpel, or Ligasure) or through flexible endoscopy (mainly with electrocautery) has proven safe and effective in expert centers [1–3].

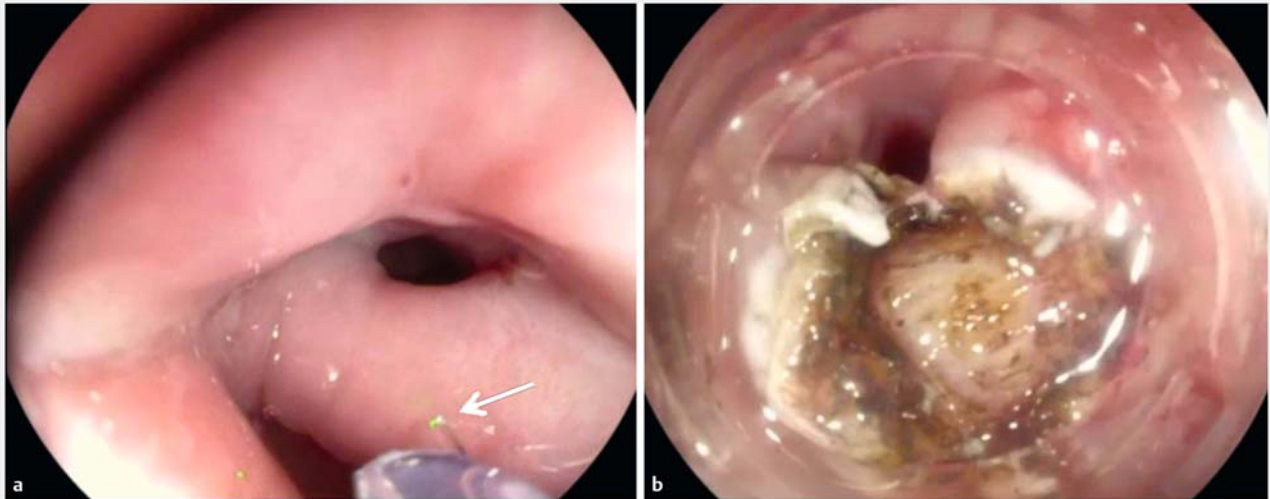
Today, Thulium laser is extensively used in urology because it allows optimal tissue vaporization, precise tissue ablation with limited lateral thermal spread (0.1–0.3 mm), and controlled tissue penetration [4]. To date, only experimental animal stud-

ies and few human endoscopic applications in the upper gastrointestinal tract have been reported [5,6].

We hypothesized that the technical characteristics of the Thulium laser could allow safe and effective division of the septum in Zenker diverticulum through flexible endoscopy. We report the first human application of Thulium laser in a small cohort of patients with Zenker diverticulum.

Patients and methods

Thulium laser septum division was performed via flexible endoscopy in consecutive symptomatic patients referred to our institution for primary or recurrent Zenker diverticulum. The Internal Review Board deemed the study exempt from ethi-



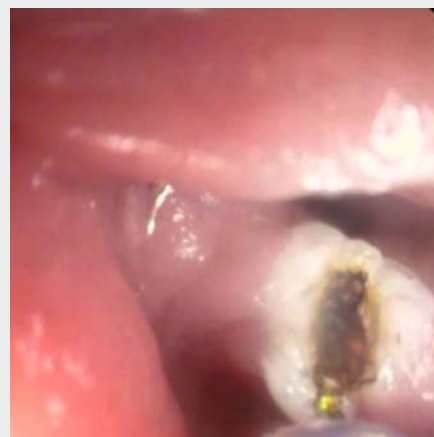► **Fig. 1** Endoscopic cricopharyngeal myotomy with Thulium laser. **a** The 272 fiber is out of the operating channel of the endoscope and the laser beam is directed to the septum. **b** The cricopharyngeal muscle has been exposed after mucosal incision.

cal approval. Primary study outcomes were feasibility and safety of the procedure. Patient demographics and relevant clinical data were collected prospectively. Dysphagia and regurgitation were scored on a scale from 1 to 4, and presence of respiratory symptoms was recorded [7]. The endoscopic procedure was performed in the operating room under general anesthesia with endotracheal intubation. Intravenous antibiotic prophylaxis was given 30 minutes before the procedure. To improve exposure and stabilize the septum during the procedure, either a transparent cap (Olympus), a flexible overtube (Cook), or the Weerda diverticuloscope were used. The laser system used was the Opera (Quanta System SPA, Varese, Italy), emitting a 1.9- μm Thulium wavelength radiation. A continuous laser configuration and an emission power of 5 to 16W were chosen. Using 272 and 365 μm optical fibers in a non-contact mode, laser incision was performed in the midline of the septum until cricopharyngeal muscle fibers were encountered and a V-shaped myotomy was completed under visual control (► **Fig. 1**). A chest film and a gastrographin swallow study were performed on postoperative Day 1 before oral feeding. Patients were scheduled for a follow-up visit at 1 and 3 months after surgery.

Results

Between May and June 2017, 5 consecutive patients with a median age of 81 years (range 43–84) were treated. All patients complained of dysphagia and regurgitation; chronic cough was reported by two patients. Two patients presented with a recurrent symptomatic diverticulum after previous transoral septum stapling. The median diverticulum size was 3 cm. All procedures were performed under general anesthesia. In all patients, complete division and separation of the septum was achieved. No bleeding/oozing occurred, and there was no need for adjunctive electrocautery devices to complete the procedure (► **Video 1**). Median operative time was 110 minutes (range 60–

125 min). The initial emission power was set 10W for the mucosal layer and then increased to 16W for the myotomy. The total amount of energy delivered and the laser time are summarized in ► **Table 1**. The two patients with recurrent diverticulum required an energy delivery > 10,000 Joules. The procedure was assisted by a transparent cap in three patients, a flexible overtube in one, and the Weerda diverticuloscope in one. The postoperative course was uneventful in all patients and no cervical emphysema or fever were recorded. The chest film and the gastrographin swallow study on postoperative Day 1 did not show evidence of pneumomediastinum, leaks or residual pouch (► **Fig. 2**). Patients were discharged home within 48 hours on a soft diet. At 1- and 3-month follow-up visits all patients were satisfied with the procedure and reported improved swallowing and absence of regurgitation and cough.

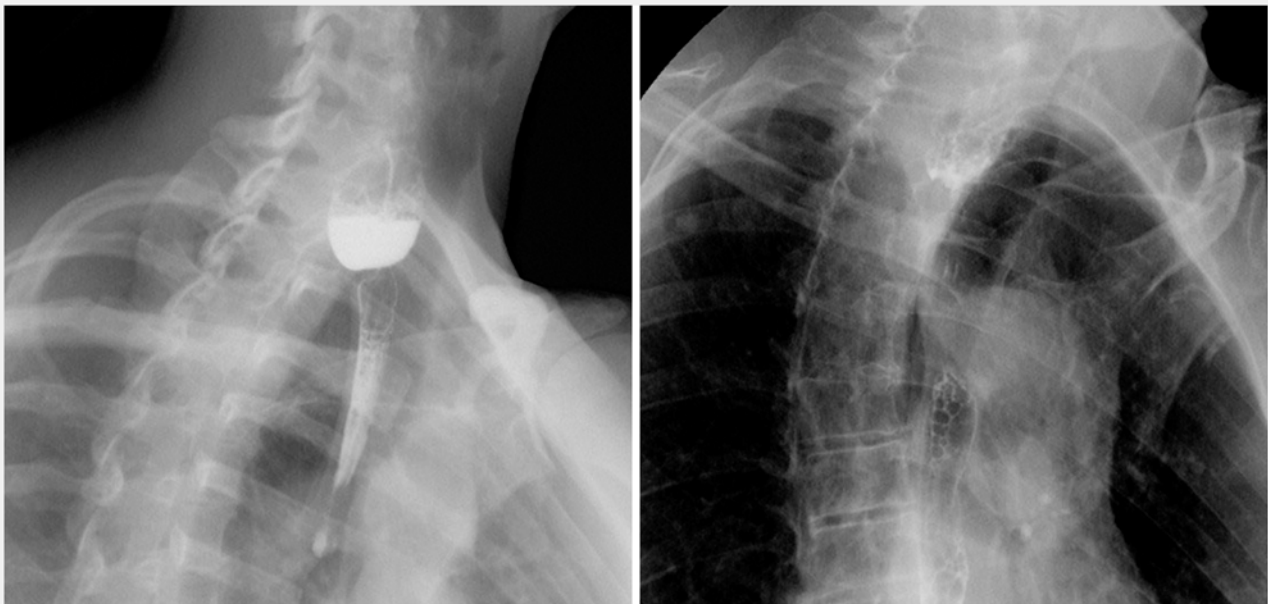


► **Video 1** Thulium-laser assisted cricopharyngeal myotomy.

► **Table 1** Demographic and operative data

Patient	Age	Sex	Septum length (cm)	Operative time (min)	Energy (J)	Laser time (min)	Fibers (μm)
1	43	F	3 ¹	110	10 578	21:02	272, 365
2	82	M	2	125	8012	14:05	272, 365
3	81	F	3 ¹	105	11 815	19:43	272
4	72	M	2	60	5408	07:51	272
5	84	F	3	110	8765	10:10	365

¹ Recurrent diverticulum

► **Fig. 2** Gastrographin swallow study before and after flexible endoscopic cricopharyngeal myotomy.

Discussion

In this pilot study, the Thulium laser beam allowed precise, bloodless incision of both the mucosal and muscular layers of the septum. Depth of incision was predictable, with minimal necrosis and lateral thermal spread. The procedure was smokeless and the fibers of the cricopharyngeal muscle were clearly seen to retract laterally in all cases, suggesting that microscopic magnification is unnecessary when using Thulium laser. Neither fever nor cervical emphysema occurred in any of the patients, indicating that the buccopharyngeal fascia was preserved. Incision time was variable and probably reflected the learning curve of the procedure. Interestingly, recurrent diverticula after transoral stapling required more energy delivery, reflecting a greater amount of tissue fibrosis in the residual septum. Because physical limitations of the stapling device can explain incomplete division of the cricopharyngeus muscle and clinical recurrences, especially in diverticula smaller than 3 cm [1], we speculate that the Thulium laser technique may be the preferred initial option in these patients.

Thulium laser works with a 1.9- to 2.0- μm wavelength with limited lateral thermal spread (0.1–0.3 mm with small fibers), tissue penetration (0.2–0.4 mm beyond ablated/cut tissue layer) and fine coagulation [6]. There have been concerns in the past about creating a perforation at the bottom of the diverticulum when using the laser technique which is why the results of this procedure are still considered operator-dependent. According to a cadaveric study by Chang et al. [8], risk of creating a free mediastinal perforation is significantly reduced by paying attention to maintaining the integrity of the buccopharyngo-esophageal fascia during the common wall division. It is likely that the buccopharyngeal fascia is displaced posteriorly by the diverticulum, creating a safer plane to divide the septum without entering the prevertebral space. However, because the cricopharyngeal muscle represents only the proximal portion of the common wall, the operator should keep in mind that the goal of the procedure is, in fact, to perform a cricopharyngeal myotomy and not to reach the bottom of the pouch. Special care must be taken in patients with recurrent diverticulum after

incomplete transoral stapling due to the possible tissue fibrosis and asymmetry of the septum.

In the past, CO₂ laser treatment for Zenker's diverticulum has been confined to the domain of otorhinolaryngologists because of the need of a rigid scope and a special microendoscopic equipment [9]. A recent systematic review and meta-analysis has found that, despite substantial heterogeneity across studies, flexible endoscopic treatment for Zenker's diverticulum with needle knife or IT knife is feasible, safe, and effective [10]. Because the optimal incision technique still remains elusive, it is possible that in the future, the Thulium laser will be added to the current armamentarium of both gastroenterologists and surgeons for flexible endoscopic treatment of Zenker diverticulum.

Conclusions

Division of Zenker's diverticulum septum with Thulium laser appeared feasible and safe through flexible endoscopy in this pilot study. Experience with a larger patient cohort with longer follow-up is needed to assess efficacy and effectiveness.

Acknowledgements

We thank Mr. Gregorio Cattignoli for his expert assistance in the operating room with the Thulium laser equipment.

Competing interests

None

References

- [1] Bonavina L, Rottoli M, Bona D et al. Transoral stapling for Zenker diverticulum: effect of the traction suture-assisted technique on long-term outcomes. *Surg Endosc* 2012; 26: 2856–2861
- [2] Dzeletovic I, Ekbohm DC, Baron TH. Flexible endoscopic and surgical management of Zenker's diverticulum. *Expert Rev Gastroenterol Hepatol* 2012; 6: 449–466
- [3] Yuan Y, Zhao YF, Hu Y et al. Surgical treatment of Zenker's diverticulum. *Dig Surg* 2013; 30: 207–218
- [4] Zhu Y, Zhuo J, Xu D et al. Thulium laser versus standard transurethral resection of the prostate for benign prostatic obstruction: a systematic review and meta-analysis. *World J Urol* 2015; 33: 509–515
- [5] Cho JH, Cho JY, Kim MY et al. Endoscopic submucosal dissection using a thulium laser: preliminary results of a new method for treatment of gastric epithelial neoplasia. *Endoscopy* 2013; 45: 725–728
- [6] Tontini GE, Neumann H, Pastorelli L et al. Thulium laser in interventional endoscopy: animal and human studies. *Endoscopy* 2017; 49: 365–337
- [7] Siboni S, Asti E, Sozzi M et al. Respiratory symptoms and complications of Zenker diverticulum: effect of trans-oral septum stapling. *J Gastrointest Surg* 2017; 21: 1391–1395
- [8] Chang CW, Liou SS, Nettekville JL. Anatomic study of laser-assisted endoscopic cricopharyngeus myotomy. *Ann Otol Rhinol Laryngol* 2005; 114: 897–901
- [9] Van Overbeek JJM. Meditation on the pathogenesis of hypopharyngeal diverticulum and a report of endoscopic treatment in 545 patients. *Ann Otol Rhinol Laryngol* 1994; 103: 178–185
- [10] Ishaq S, Hassan C, Antonello A et al. Flexible endoscopic treatment for Zenker's diverticulum: a systematic review and meta-analysis. *Gastrointest Endosc* 2016; 83: 1076–1089