


# Immediate placement and loading of implants with laser-microgrooved collar in combination with an anorganic porcine bone mineral matrix in the esthetic zone. Twelve-month results of a prospective multicenter cohort study

Gabriele Rosano DDS, PhD, MSc, FICD<sup>1,2</sup> | Tiziano Testori MD, DDS, MSc, FICD<sup>3,4,5,6</sup> | Paolo Torrisi DDS<sup>7,8</sup> | Matteo Invernizzi DDS<sup>1,2</sup> | Nicolò Vercellini DDS<sup>2</sup> | Massimo Del Fabbro MSc, PhD<sup>4,9</sup> 

<sup>1</sup>Academy of Craniofacial Anatomy (ACA), Como, Italy

<sup>2</sup>Lake Como Institute, Academy of Osseointegration (AO) Approved Training Center, Como, Italy

<sup>3</sup>Department of Implantology and Oral Rehabilitation, Dental Clinic, IRCCS Istituto Ortopedico Galeazzi, Milan, Italy

<sup>4</sup>Department of Biomedical, Surgical and Dental Sciences, Università degli Studi di Milano, Milan, Italy

<sup>5</sup>Department of Periodontics and Oral Medicine, University of Michigan, School of Dentistry, Ann Arbor, Michigan, USA

<sup>6</sup>Department of Oral Medicine, Infection and Immunity, Harvard University, School of Dental Medicine, Cambridge, Massachusetts, USA

<sup>7</sup>Department of General Surgery and Surgical Medical Specialties, School of Dentistry, University of Catania, Catania, Italy

<sup>8</sup>Private Practice, Catania, Italy

<sup>9</sup>Fondazione IRCCS Ca' Granda Ospedale Maggiore Policlinico, Milan, Italy

## Correspondence

Massimo Del Fabbro, Department of Biomedical, Surgical and Dental Sciences, Via della Commenda 10, Milan, Italy.  
Email: [massimo.delfabbro@unimi.it](mailto:massimo.delfabbro@unimi.it)

## Abstract

**Background:** Many techniques have been proposed to address post-extraction ridge resorption, which often represents a concern, especially in the esthetic region.

**Purpose:** The purpose of the present, prospective, multicenter, single cohort study was to investigate, up to 1 year of function, the effectiveness of a protocol for alveolar ridge preservation involving implants with laser-microgrooved surface immediately placed in fresh extraction sockets.

**Materials and Methods:** Twenty eight patients candidate to tooth extraction in the esthetic zone (site 15–25 and 35–45) were treated by immediate placement of a single laser-microgrooved implants with the adjunct of a highly porous anorganic porcine bone mineral matrix and a collagen wound dressing. Peri-implant marginal bone level (MBL) was evaluated at time of loading, 3 and 12 months after loading. Gingival index, plaque index, probing depth, and bleeding on probing were measured at 3, 6, and 12 months after loading. Dimensional changes at implant sites were digitally evaluated using the best-fit superimposition of pre- and post-socket preservation models. Implant aesthetic score (IAS) as well as patients' post-operative quality of life were also evaluated at 12 months. Comparisons between data relative to thick and thin gingival phenotypes were made using Student's *t*-test or Mann–Whitney test, as appropriate. The significance level was set at  $p = 0.05$ .

**Results:** No patient dropped out, and 28 implants were evaluated at 12 months post-loading. The overall MBL was found to be  $0.92 \pm 1.11$  mm. Volumetric analysis of superimposed models showed an alveolar bone tissue displacement at the buccal aspect of  $-0.57 \pm 0.52$  mm in thin phenotypes and  $-0.46 \pm 0.31$  mm in thick phenotypes ( $p = 0.58$ , unpaired Student's *t*-test). No signs of soft tissue recession or esthetically unpleasant buccal gingiva were reported.

This is an open access article under the terms of the [Creative Commons Attribution](https://creativecommons.org/licenses/by/4.0/) License, which permits use, distribution and reproduction in any medium, provided the original work is properly cited.

© 2023 The Authors. *Clinical Implant Dentistry and Related Research* published by Wiley Periodicals LLC.

**Conclusions:** The clinical protocol herein employed showed benefits in maintaining marginal bone levels and soft tissue contour around post-extraction implants in the esthetic zone.

**KEYWORDS**

3D evaluation, anorganic bone matrix, bone substitutes, esthetic outcome, immediate implant placement, Laser-Lok, post-extraction sockets

**Summary box**

**What is known**

After immediate single-tooth replacement with osseointegrated implants, the socket as well as the surrounding soft tissues undergo remodeling and resorption, which may represent a concern in the esthetic region. Several protocols have been proposed to address such issue.

**What this study adds**

The present protocol, combining the use of a xenograft with immediate placement of laser-microgrooved implants, showed minimal hard and soft tissue changes, and could be a viable therapeutic option for the rehabilitation of post-extraction sockets in the esthetic zone.

## 1 | INTRODUCTION

Immediate post-extraction implant placement is a well-accepted protocol due to the preservation of esthetics, maintenance of socket walls, reduced surgical time, shorter total treatment time, and better actual fixture placement as compared to delayed implant insertion.<sup>1-3</sup>

Nevertheless, clinical studies have documented that, after immediate single-tooth replacement with osseointegrated implants, the socket as well as the surrounding soft tissues undergo remodeling and resorption.<sup>3</sup>

Following tooth extraction, remodeling of the hard and soft tissues is observed leading to a horizontal volume reduction in the alveolar crest, mainly involving the vestibular area with respect to palatal-lingual side. As a matter of fact, post-extraction morphological alteration has been analyzed in numerous studies and the fundamental role played by the vestibular bone wall in the remodeling process has been widely demonstrated.<sup>4-6</sup>

The success of implant therapy in the esthetic zone is not only determined by high survival rates but, especially, by the appearance of the peri-implant soft tissue, which should be in harmony with the mucosa of the adjacent teeth.<sup>7</sup>

To avoid the regression of the bony architecture and the interproximal papillae, various hard and soft tissue augmentation procedures have been proposed, though these sometimes may produce unpredictable outcomes and require considerable technical skillfulness.<sup>8</sup>

In post-extraction dental implant placement, achieving a satisfying esthetic outcome in the anterior sites is a challenging procedure for clinicians. In fact, an increased risk for soft tissue recession at the facial aspect has been frequently reported and supplementary connective tissue grafts may be required to accomplish the final esthetic result.

Bone grafting at the time of flapless post-extraction socket implant placement into the gap in combination with an absorbable gelatin sponge and a contoured healing abutment<sup>9</sup> or an immediate provisional restoration may limit the amount of ridge contour changes and preserve the facial soft tissue thickness.<sup>2,10</sup> Such procedure allows for guided bone regeneration (GBR) without the need for vertical releasing incisions and primary healing, thus showing a pleasant gingival contour at the facial aspect after a single stage surgery. This technique may guarantee a safe post-operative control of GBR techniques after implant insertion.

As also stated by the recent literature, a laser-microgrooved implant surface at its coronal portion has the potential to attract a physical connective tissue attachment that would inhibit epithelial downgrowth, establish a predetermined site for the connective tissue, and thus preserve the coronal level of bone.<sup>11</sup>

Considering the esthetic importance of an implant supported restoration in the anterior area, clinicians should not merely consider the implant survival as the only success parameter, but also address the different aspects of the esthetic result and long-term stability of the soft tissues.<sup>8</sup>

The purpose of the present, prospective, multicenter clinical study was to investigate, up to 1 year of function, bone and soft tissue contour changes around immediate implants with *Laser-Lok* surface in fresh extraction sockets, using an anorganic porcine bone mineral matrix and a collagen wound dressing to fill the gap between the implant surface and the buccal cortical bone plate. A further aim was to evaluate the esthetic outcome utilizing the implant aesthetic score (IAS).<sup>10</sup>

## 2 | MATERIALS AND METHODS

The present research was performed within the guidelines of the World Medical Association Helsinki Declaration of 1975, as revised in

2000, for ethical treatment of human subjects involved in biomedical research. The study protocol was independently reviewed and approved by the IRCCS Orthopedic Institute Galeazzi Scientific Board, Milan, Italy (IRB approval Prot. N. 75/2019, L2058). The IRB waived the need for ethical approval since the study followed standard clinical protocols for diagnosis, treatment, and follow-up, was not comparative, and no experimental material was used. This is an open, prospective, non-randomized, multi-center single cohort study with a 1-year follow-up period. The study population was recruited from January 2018 to December 2020 in four private centers located in Italy. The patients were enrolled after they had been informed about the study protocol and they had signed an informed consent to the treatment, and for the use of the collected data for scientific purpose.

Patients candidate to tooth extraction were treated by immediate post-extraction implant insertion procedure with the adjunct of a highly porous anorganic porcine bone mineral matrix.

Three months after implant placement and temporary loading the subjects received their permanent restoration. The last follow-up control visits in the study took place 12 months after final functional loading.

Sample size was calculated for paired samples assuming a mean discrepancy (mean of the differences in marginal bone level) of 0.6 mm between pairs, and a standard deviation of the differences of 1.0 mm. To achieve a power of 80% and a level of significance of 5% (two sided), the study would require a sample size of 25 (<https://statulator.com/SampleSize/ss2PM.html>). Considering a possible drop-out of 10%–12%, it was planned to recruit 28 patients.

## 2.1 | Patients selection criteria

### 2.1.1 | Inclusion criteria

Good systemic health of the patient; >18-year-old patients; anterior teeth (i.e., teeth location: 15–25 and 35–45); no periodontal disease and gingival recession; extraction sockets type I with intact socket walls; chronic endodontic lesions even in presence of a potential facial fenestration limited to the apical third of the socket.

### 2.1.2 | Exclusion criteria

Uncontrolled diabetes or any systemic disease that could compromise post-operative healing and/or osseointegration; pregnancy; presence of adjacent implants; extraction sockets type II and III; compromised soft tissue conditions; poor patient compliance; smokers with a cigarette consumption more than 10 cigarettes per day.

## 2.2 | Surgical procedure

A week before surgery the patients underwent a professional oral hygiene session whereby they were instructed on how to correctly

perform a mouth rinse containing 0.12% Chlorhexidine for 1 min twice a day.

All patients received prophylactic antibiotic therapy of 2 g of amoxicillin and clavulanic acid (or clindamycin 600 mg if allergic to penicillin) 1 h before the extraction and implant placement procedures. The patients rinsed for 1 min with chlorhexidine mouthwash 0.2% prior to surgery.

Before tooth extraction two pictures of the site (with occlusal and lateral/frontal view) were taken (Figures 1A,B and 2A,B) and a peri-apical radiograph using the paralleling technique and a customized film holder was taken (Figure 3).

Class IV extra-hard plaster (GC Fuji ROCK EP, GC Corporation, Tokyo, Japan) master casts of the sites were also taken before tooth extraction and after 1 year of loading after making impressions using a silicone material (Flexitime Heavy & Light—Heraeus Kulzer), in order to be optically scanned and to get a baseline volume reference.

Local anesthesia was induced using articaine 4% with adrenaline 1:100,000.

The soft tissue phenotype was preoperatively evaluated using the “Colorvue Phenotype Probe System” featuring white color (indicating that the phenotype is thin, Figure 4) and green color (indicating that the phenotype is medium or thick, Figure 5).<sup>12–14</sup>

The surgical procedure started with tooth extraction which was performed with sharp dissection of the supracrestal gingival fibers using a 15c scalpel blade and without vertical releasing incisions.

This allowed for atraumatic tooth removal without flap elevation, thus maintaining the periosteal blood supply to the labial bone plate (Figure 6A,B).

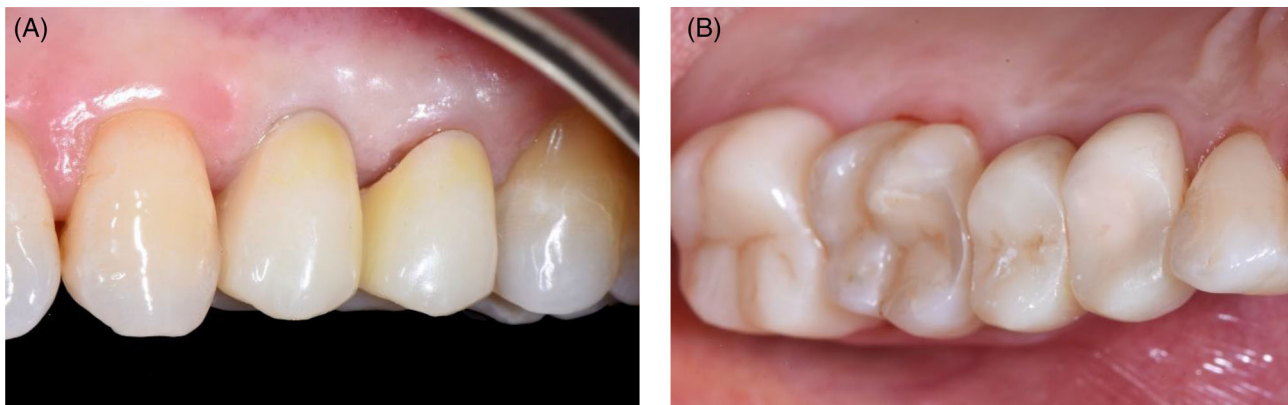
After tooth extraction the alveolar socket was debrided and a BioHorizons Tapered Plus implant (BioHorizons, Inc., Birmingham, Alabama, USA) placed 3 mm below the free gingival margin (FGM) in the correct prosthetically driven position (Figures 7A,B, 8, 9, 10).

The tapered implant used in this study has the 1.8 mm of the platform switched collar surface characterized by the presence of laser-produced microgrooves with resorbable blast texturing (RBT) on implant body.

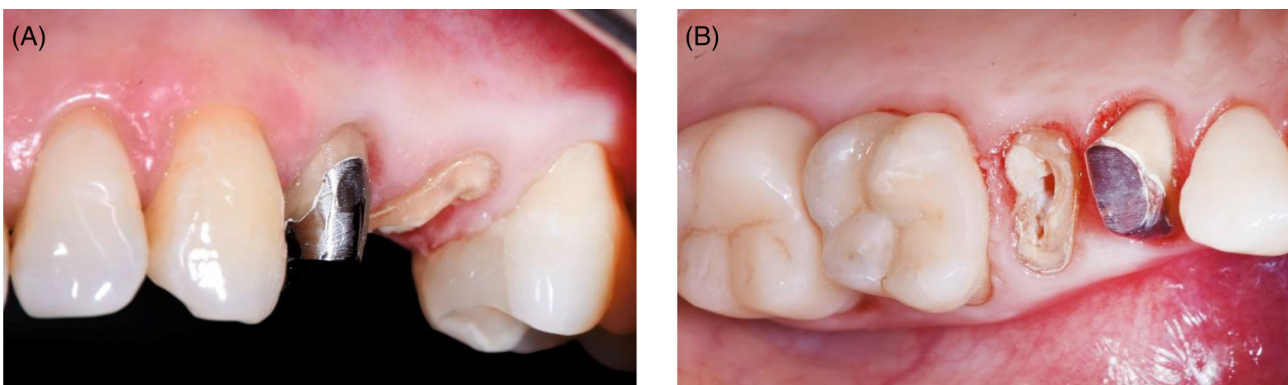
The final insertion torque was measured utilizing a calibrated wrench and taken as an indicator of implant stability right after implant position.

The mismatch between the implant surface and the buccal alveolar cortex was filled using a highly porous anorganic porcine bone mineral matrix in cancellous form (MinerOss XP Cancellous Particulate, BioHorizons, Inc.). An absorbable collagen wound dressing (BioStrip, BioHorizons, Inc.) is then placed and stretched above the fixture head (1) to retain the graft and isolate the grafted socket and (2) as a closure in order to avoid raising a displaced flap (Figure 11).

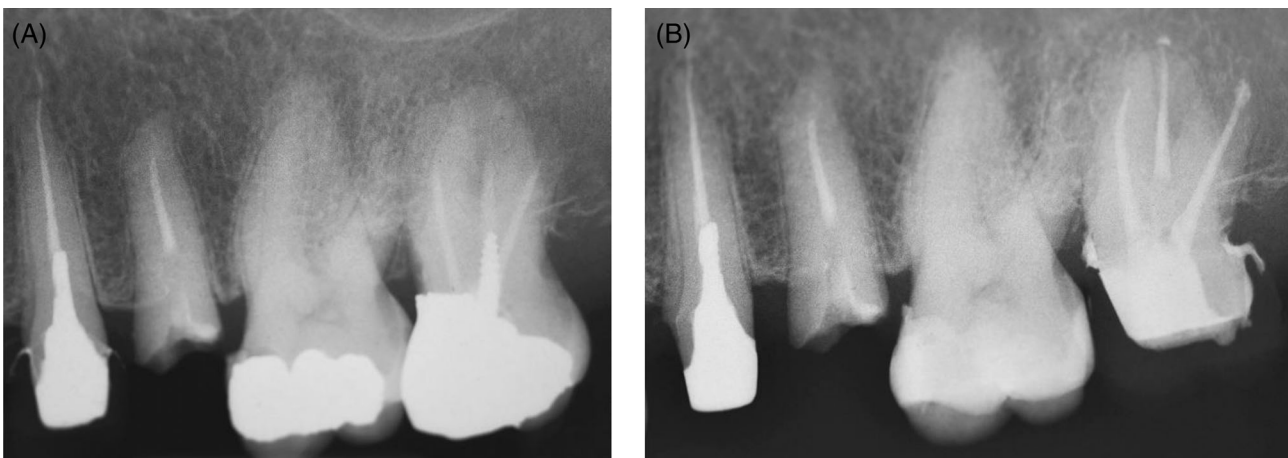
Once the implant primary stability was obtained, with a minimum insertion torque of 35 Ncm, a provisional restoration, fabricated prior to tooth extraction, was seated and connected



**FIGURE 1** Before tooth extraction: (A) lateral view. (B) occlusal view.



**FIGURE 2** Before tooth extraction, after crown removal: (A) lateral view. (B) occlusal view.



**FIGURE 3** Peri-apical radiograph before tooth extraction, taken with the paralleling technique (A) at patient assessment, and (B) after treatment of teeth distal to the one candidate to extraction.

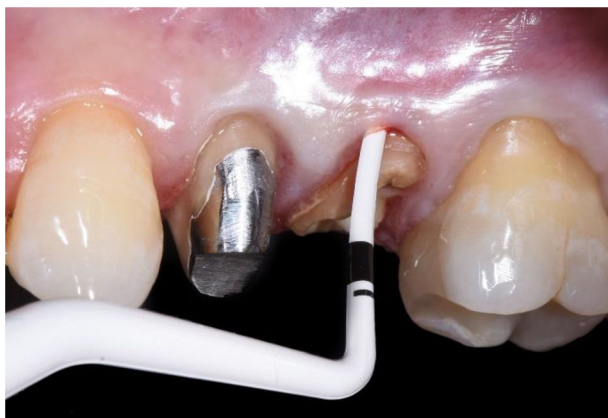to a Laser-Lok screw-retained temporary abutment using auto-polymerizing acrylic resin, and isolating the surgical field with a rubber dam.

On the contrary, when an implant primary stability was not achieved (torque <35 Ncm), a 3 mm Laser-Lok straight healing abutment was placed and a pontic portion provisional prostheses was

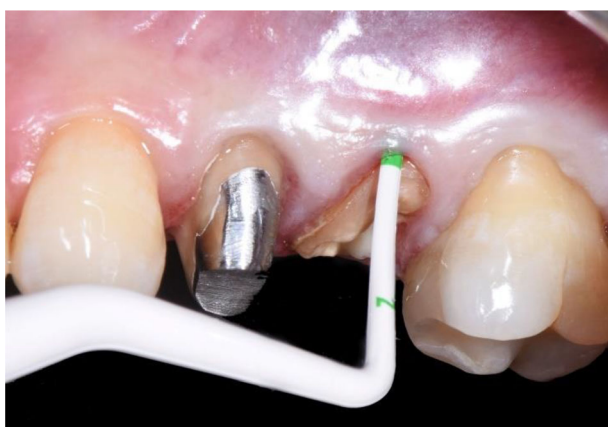adhesively bonded to the adjacent natural teeth and adjusted in occlusion with no contact with the healing abutment (Figures 12 and 13).

In the latter cases, the fibrin sponge was stretched over the straight healing abutment and secured under the surrounding gingiva which will be sutured with an absorbable 6/0 suture (Ethicon Inc. Johnson & Johnson, Piscataway, NJ, USA; Figure 13).





**FIGURE 4** Soft tissue thin phenotype evaluation.



**FIGURE 5** Soft tissue thick phenotype evaluation.

The exclusion criteria for carrying out immediate loading technique were the following: no implant primary stability and bruxism.

In this case, the final screw-retained prosthesis was delivered 3 months after implant placement. Figures 14 and 15 show the control at 12 months after loading.

### 2.3 | Outcome variables

Periapical radiographs using the paralleling technique and marginal bone level radiographic evaluation were done at time of loading (baseline), 3 and 12 months after prosthetic loading. Marginal bone level (MBL) was determined from radiographs, as the difference in mm from a reference point on the implant to the most coronal bone-to-implant contact (BIC) on the mesial and distal aspect of the implant. The evaluation of MBL was carried out using image analysis software (ImageJ, U. S. National Institutes of Health, Bethesda, Maryland, USA). Each image was calibrated using the known length along the major axis of the implant. The precision obtained by the measuring system is accurate to within 0.01 mm. To facilitate the measurements, the images could be slightly rotated by a software function, to fix the major axis in the vertical direction. To improve the visual contrast between the

bone and implant, an image processing procedure (sharpening) could be performed when necessary. MBL alterations were determined as the difference between MBL at the time of implant loading, and MBL at 3 and 12 months after loading.

The condition of peri-implant mucosa was measured by assessment of a gingival and plaque index, of probing pocket depth (PPD) and bleeding on probing (BOP). The PPD was determined by measuring and recording the distance from the gingival margin to the bottom of the gingival pocket using a graduated probe.

The BOP was determined by inserting a PCP-UNC 15 periodontal probe (Hu-Friedy Manufacturing Co., Chicago, IL, USA) to the bottom of the gingival pocket. If bleeding was evident by this instrumentation, the site examined was considered inflamed. All such parameters were measured at 3, 6, and 12 months after loading.

The esthetic outcome was evaluated 12 months after loading utilizing the IAS by Testori et al.,<sup>10</sup> whose index analyses the following items: (1) presence and stability of the mesio-distal papilla (score between 0 and 2); (2) ridge stability bucco-palatally (0 to 1); (3) texture of the peri-implant soft tissue (0 to 2); (4) color of the peri-implant soft tissue (0 to 2); (5) gingival contour (0 to 2). According to this score, a “perfect” outcome is achieved when the score is 9, between 4 and 8 the outcome is considered “acceptable” and between 0 and 3 it is “compromised.” IAS was assessed by an independent evaluator at each center.

Finally, all patients were also asked to fill a quality-of-life evaluation form 12 months after loading. The questionnaire, based on a 1–10 VAS scale, evaluated the satisfaction of the patient with mastication function, phonation, esthetics, cleanliness of the prosthesis, final result as compared to expectations.

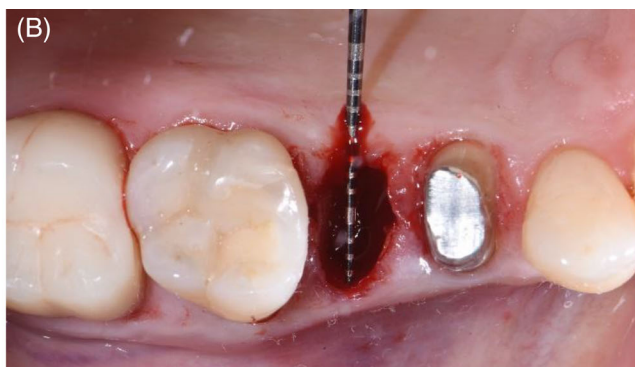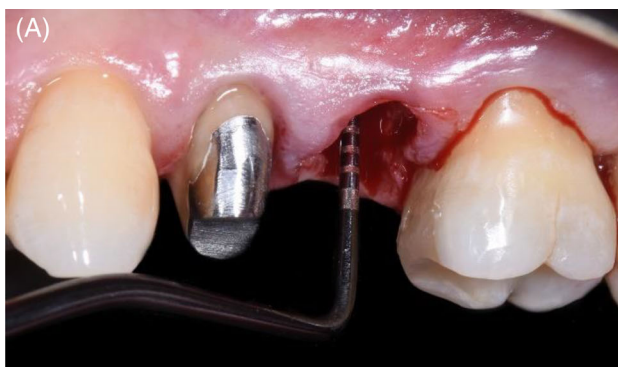### 2.4 | Analysis of models

To evaluate tissue contour changes, pre-op (before implant placement) and post-op (after 1-year loading) master casts of the surgery site were made and optically scanned. A computerized analysis of the contour changes was performed by superimposing the scanned models.

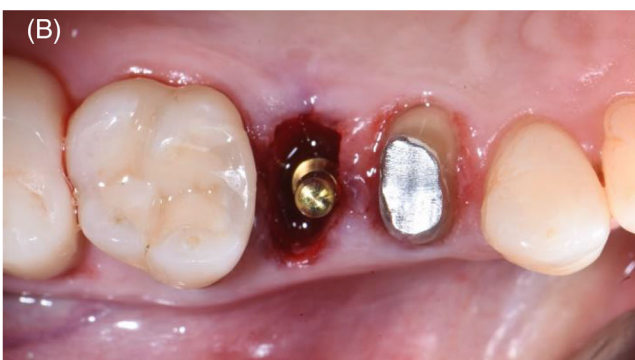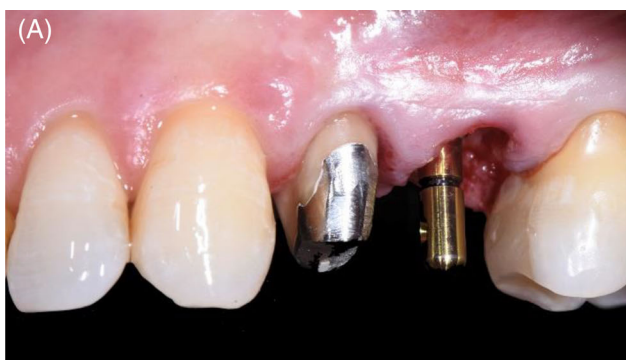For the evaluation of the dimensional changes at the extraction/implant sites obtained from the Scanner on STL files, Medit Link software (MEDIT Corp. Seoul, Korea) was used. After importing them into the Medit Design app, the casts were superimposed by means of a “best-fit” algorithm that progressively reduces the relative distance between the meshes, adapting to the common regions taken in the reference areas, namely the natural teeth not involved in the surgical procedure (Figure 16).

The superimposition result was checked as shown in Figure 17 and the target areas, corresponding to the vestibular and palatal/lingual gingival areas of the extraction/implant sites, were also cut and duplicated (Figures 18 and 19).

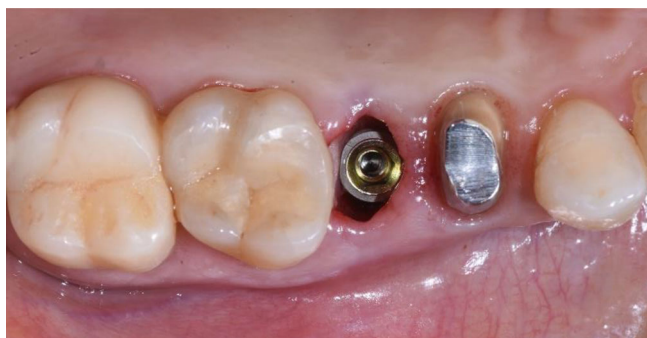This operation was carried out simultaneously on the superimposed casts to obtain two pre-op and two post-op surfaces very similar in size. Finally, we performed a volumetric analysis, comparing pre- and post-op areas; in Figures 20 and 21 it is shown the result visualized with a colorimetric map.



**FIGURE 6** Atraumatic tooth removal: (A) lateral view; (B) occlusal view.



**FIGURE 7** Implant site evaluation (A) lateral view; (B) occlusal view.

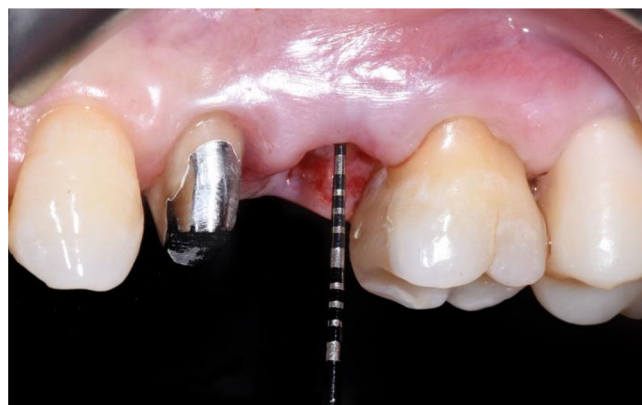

**FIGURE 8** Implant inserted in a prosthetically driven position.

For each model we calculated the mean value of linear resorption and the standard deviation on the buccal side as well as on the palatal/lingual one.

### 2.5 | Statistical analysis

Descriptive statistics was performed. The normality of distributions for quantitative variables was checked using the D'Agostino and Pearson omnibus normality test. Gaussian variables were presented as mean values and standard deviations. The data were split according to the soft tissue phenotype and comparisons between data relative to



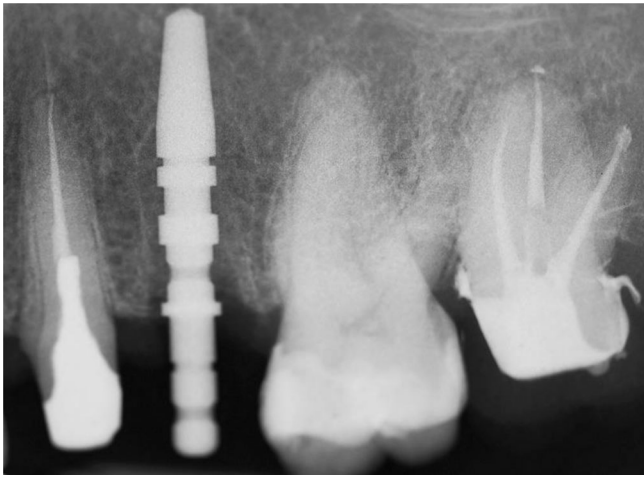
**FIGURE 9** Free gingival margin evaluation.

thick and thin phenotypes were undertaken, using parametric or non-parametric tests (Student's t-test or Mann-Whitney test, respectively) as appropriate. The significance level was set at  $p = 0.05$ .

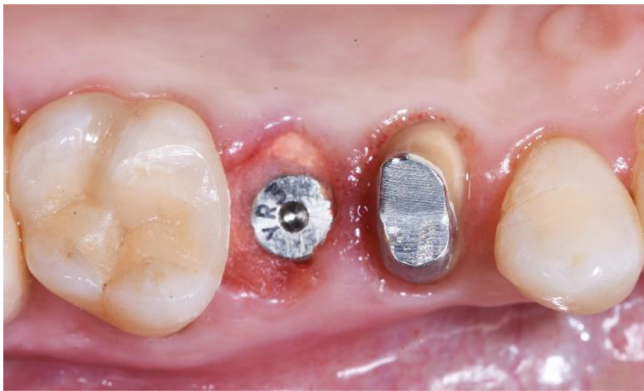### 3 | RESULTS

Twenty eight patients (12 men, 16 women) were enrolled at four centers in Italy. The mean age was  $51.9 \pm 10.5$  years (range 30 to

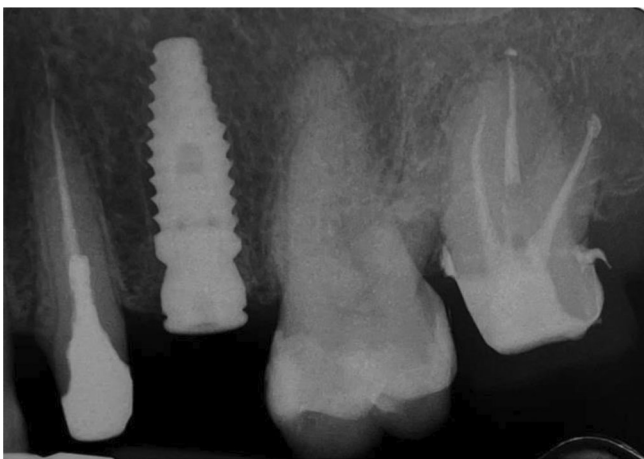




**FIGURE 10** Final radiograph showing parallelism of the implant.

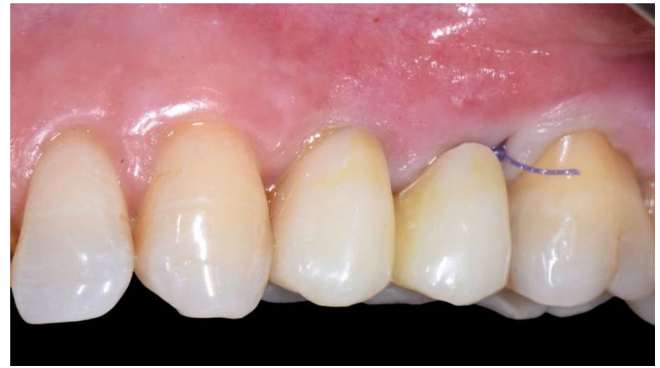

**FIGURE 11** The gap was filled with porcine bone and absorbable collagen.

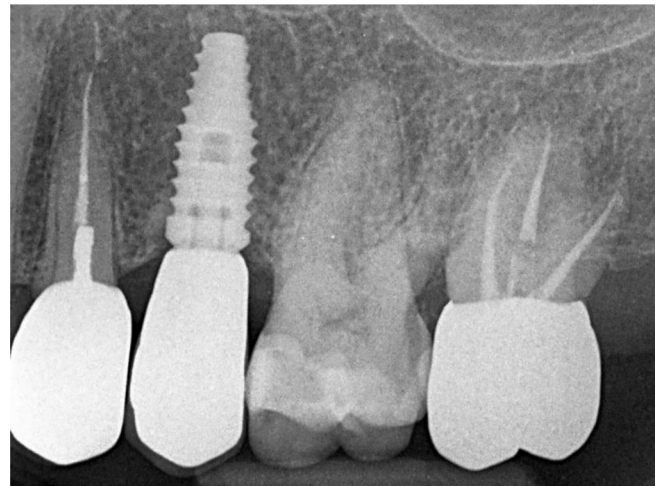


**FIGURE 12** Healing abutment.

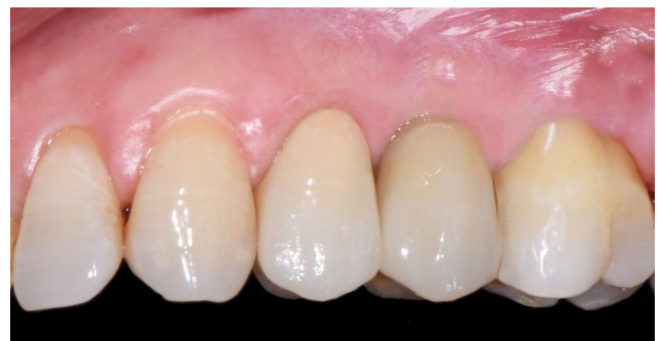68 years). Twenty maxillary teeth (7 incisors, 3 cuspids, and 10 premolars), and 8 mandibular teeth (1 cuspid and 7 premolars) were extracted. The reason for extraction was root caries in



**FIGURE 13** Picture taken soon after suturing.



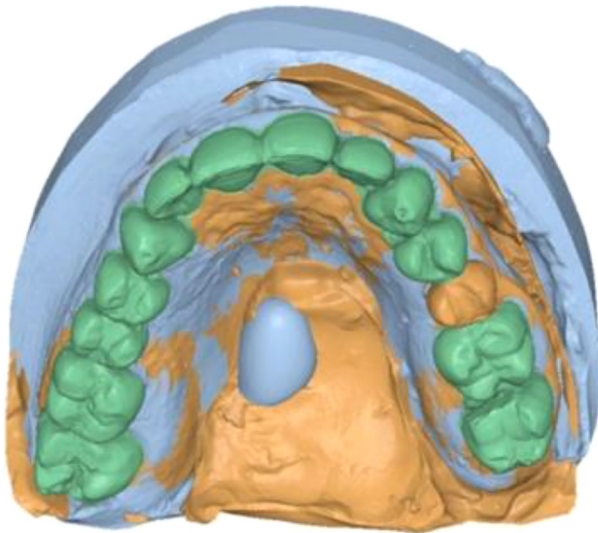
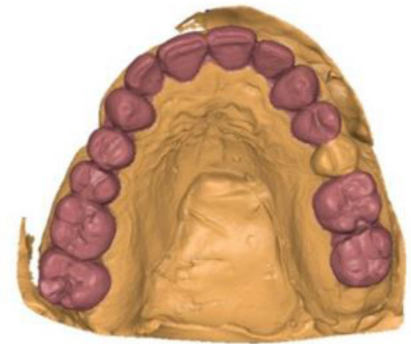
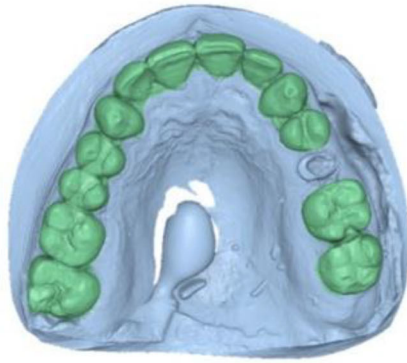
**FIGURE 14** Radiograph taken 1 year after surgery.



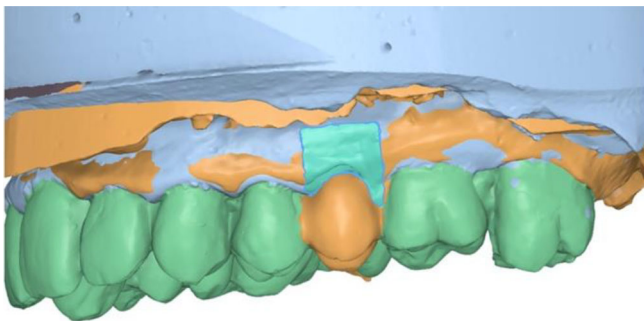
**FIGURE 15** Picture taken 1 year after surgery.

22 cases, periodontitis in three cases, and root fracture in three cases. The cases were treated by four clinicians (GR, TT, PT, MI). No intrasurgical nor post-surgical complications were encountered. In 23 patients it was possible to get adequate implant primary stability and apply the immediate loading protocol, while in five patients the prosthetic loading was carried out 3 months after surgery.

**FIGURE 16** Pre-op (left) and post-op (right) master casts with teeth not involved in surgical procedure and selected as reference area for the superimposition.



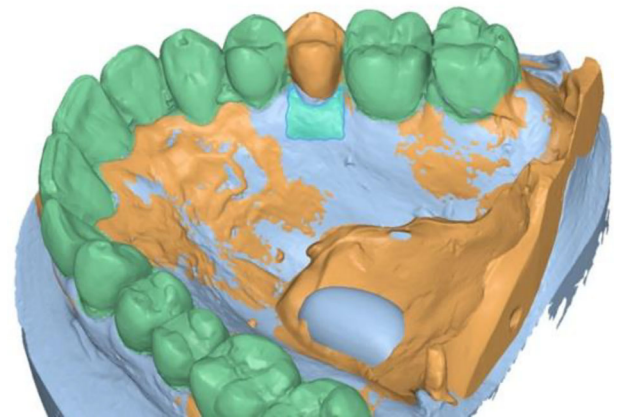
**FIGURE 17** Overlapping check based on the best fit of tooth surface.



**FIGURE 18** Buccal target area for volumetric analyses.

Eighteen cases (17 in the maxilla, 1 in the mandible) showed a thick gingival phenotype while in 10 cases (3 in the maxilla, 7 in the mandible) the phenotype was thin.

Peri-implant gaps larger than 1 mm were always present and there were no dehiscence defects.



**FIGURE 19** Palatal target area for volumetric analyses.

Twenty eight implants were evaluated radiographically at the time of loading (baseline), 3 and 12 months after loading showing a progressive slight decrease of peri-implant bone level during the follow-up period. In particular, the overall MBL was found to be  $0.60 \pm 0.85$  mm at 3 months and  $0.92 \pm 1.11$  mm at 12 months of loading with respect to baseline (Table 1, Figure 22).

Gingival index, plaque index, PPD, and BOP were measured at 3, 6, and 12 months after loading and no significant differences have been found (Table 2, Figure 23A–D).

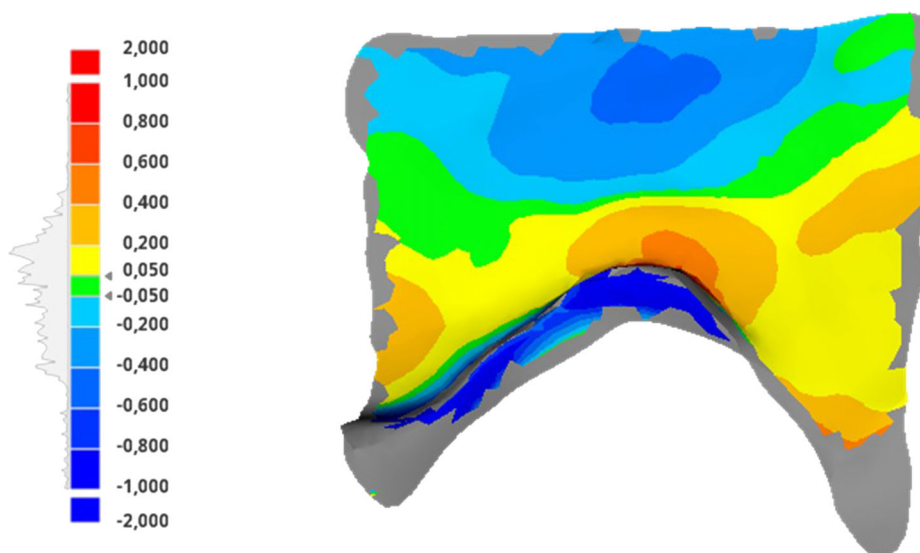
Of course, as expected, a thick gingival phenotype was found to be associated to slightly lower measurements for all such clinical parameters.

The IAS was consistently high mainly due to the adequate preservation of the bucco-palatal/lingual alveolar socket at the implant sites; it was found to be, in a scale from 0 to 9,  $7.56 \pm 0.53$  in thin phenotypes and  $7.94 \pm 0.85$  in thick phenotypes (Table 3).

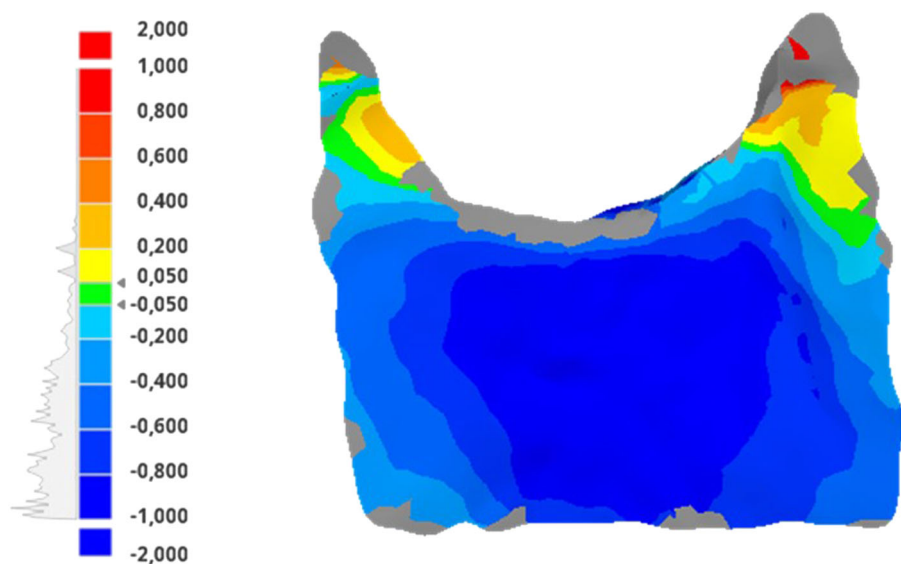
No statistically relevant differences were evidenced between thin and thick phenotypes ( $p = 0.22$ ).

The results of the alveolar bone tissue displacement between the pre-op and post-op optical scans of the 28 cases are summarized in Table 4.





**FIGURE 20** Volumetric analyses of buccal variations.



**FIGURE 21** Volumetric analyses of palatal variations.

**TABLE 1** Radiographic assessment of peri-implant bone level changes.

Time	Phenotype	Marginal bone level, mm	Marginal bone loss, mm	Overall marginal bone loss, mm
Baseline	Thin ( $n = 10$ )	$2.09 \pm 0.52$	-	
	Thick ( $n = 18$ )	$2.32 \pm 0.97$	-	
	Thin versus thick	$p = 0.45$	-	
3 months	Thin ( $n = 10$ )	$1.70 \pm 0.89$	$-0.39 \pm 0.64$	$-0.60 \pm 0.85$
	Thick ( $n = 18$ )	$1.72 \pm 0.89$	$-0.72 \pm 1.05$	
	Thin versus thick	$p = 0.96$	$p = 0.34$	
12 months	Thin ( $n = 10$ )	$1.39 \pm 1.08$	$-0.69 \pm 1.08$	$-0.92 \pm 1.11$
	Thick ( $n = 18$ )	$1.40 \pm 1.13$	$-1.05 \pm 1.13$	
	Thin vs thick	$p = 0.98$	$p = 0.44$	
	3 m versus 12 m			$p = 0.16^a$

<sup>a</sup>Paired student's *t*-test.

Such alveolar bone tissue displacement at the buccal aspect was  $-0.57 \pm 0.52$  in thin phenotypes and  $-0.46 \pm 0.31$  in thick phenotypes ( $p = 0.58$ ).

The results of such displacement have been visualized with a colorimetric map which visually shows the decrease of the volumes in blue color variations (Figures 19 and 20).

All patients returned their quality of life questionnaires after 12 months of prosthetic loading.

All of them reported full satisfaction for mastication function, phonetics, esthetics, and cleaning (see Table 5). Even in this case, any relevant difference between thin and thick phenotypes was evidenced.

No biological nor mechanical complication was recorded to date.

Overall implant and prosthesis success and survival after 1 year of loading was 100%.

During the whole observation period no interproximal papillae loss was observed.

## 4 | DISCUSSION

Once the tooth is extracted, blood flow via periodontal ligament is undermined and, in the case of a thin vestibular wall consisting only of

cortical bone, blood flow coming from the periosteum is not sufficient to fully preserve this structure.

Moreover, as reported in the scientific literature, the more the implant insertion is postponed after extraction, the greater the bone reduction.<sup>9,12</sup>

For these reasons, in modern immediate implantology grafting the alveolar socket is definitely a “must.”

In the present study, the authors propose an immediate post-extraction implant technique without flap elevation by using (1) a highly porous anorganic porcine bone mineral matrix as grafting material to fill the mismatch between the implant surface and the buccal alveolar cortex, and (2) an absorbable collagen wound dressing to be placed and stretched above the fixture head.

Such approach is fundamental to retain the graft, isolate the grafted socket and guarantee an alveolar socket safe closure in order to avoid raising a displaced flap, either in cases of immediate prosthetic loading or in those cases of delayed loading 3 months after surgery.

This procedure allowed for predictable GBR without the need for flap elevation and primary closure, thus preserving the surrounding soft tissue contour and volume, which represent the key aspects when placing immediate implants in the esthetic area.

Based on the analysis of the literature, we might hypothesize that the use in the present study of nano-size laser-microgrooved surfaces on the implant collar and prosthetic abutment had the capacity to allow fibroblasts to create a physical connective tissue attachment, thus preserving the coronal level of bone as well as the soft tissue volume and contour. As a matter of fact, also the influence of the implant collar surface on marginal bone loss around implants has been already discussed<sup>13,14</sup> and some studies reported that the creation of microthreads and microgrooves on the implant neck may limit marginal bone resorption.<sup>15-17</sup>

Ricci and Grew in 2008<sup>18,19</sup> evaluating the level of attachment, spreading, orientation, and growth of fibroblasts with respect to surface microgeometry, showed that cultured fibroblasts grown on microgrooved surfaces become oriented and channeled in line with the grooves, while cells grown on non-grooved surfaces showed random growth. Such results, obtained in rats, provided the hypothesis

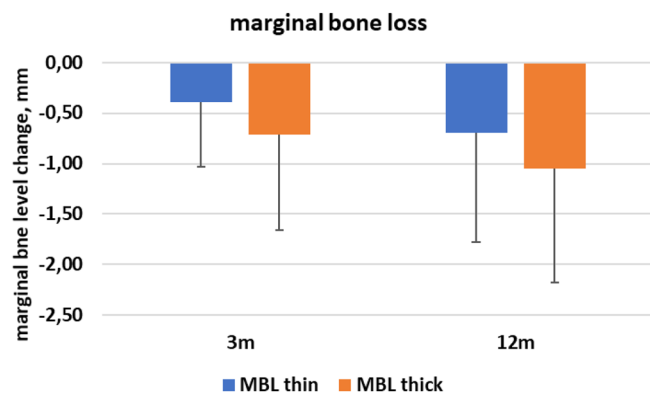


FIGURE 22 Marginal bone loss up to 12 months.

TABLE 2 Clinical parameters.

Time	Phenotype	PD, mm	BOP (0/1)	GI (0-3)	PI (1-4)
3 m	Thin	3.14 ± 0.42	0.22 ± 0.26	0.67 ± 0.50	1.67 ± 0.50
	Thick	3.05 ± 0.41	0.14 ± 0.24	0.63 ± 0.72	1.38 ± 0.50
	Thin versus thick	$p = 0.61$	$p = 0.47$	$p = 0.87$	$p = 0.19$
6 m	Thin	3.19 ± 0.24	0.25 ± 0.13	0.89 ± 0.33	1.89 ± 0.33
	Thick	3.08 ± 0.32	0.19 ± 0.17	0.75 ± 0.58	1.38 ± 0.50
	Thin versus thick	$p = 0.34$	$p = 0.33$	$p = 0.45$	$p = 0.006^a$
12 m	Thin	3.00 ± 0.35	0.06 ± 0.11	0.33 ± 0.50	1.44 ± 0.33
	Thick	2.86 ± 0.37	0.03 ± 0.09	0.13 ± 0.34	1.13 ± 0.34
	Thin versus thick	$p = 0.36$	$p = 0.50$	$p = 0.31$	$p = 0.037^a$

Abbreviations: BOP, bleeding on probing; GI, gingival index; PD, probing depth; PI, plaque index.

<sup>a</sup>Statistically significant.

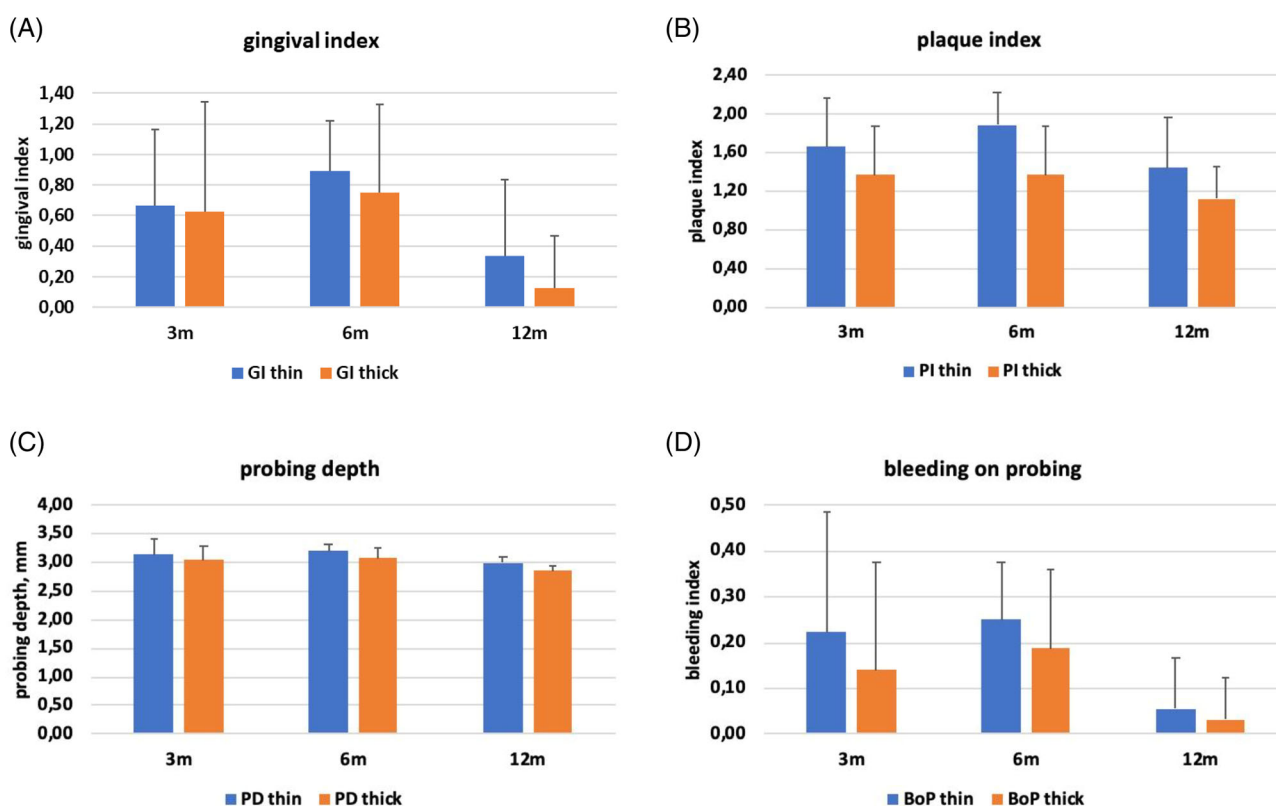
that laser-microtextured surfaces could be used to control soft tissue responses to implant surfaces. Histological researches in animal models<sup>20</sup> and in humans<sup>21</sup> have also confirmed this hypothesis, documenting the presence of a physical connective tissue attachment onto laser-produced microgrooves on implant and abutment surfaces. In all these studies the connective tissue fibers were found to be perpendicularly oriented to the implant surface, acting by sealing out contaminants in the external environment.

Implants with a laser-microgrooved collar, compared with implants without a laser-microgrooved collar, present a statistically significant lower incidence of peri-implant diseases.<sup>22,23</sup> As a connective tissue attachment is supposed to be creating a physical barrier, it is conceivable to speculate that its absence may facilitate an easier apical migration of inflammation. The laser-microgrooved collar

surface, promoting a perpendicular, functional, physical connective tissue attachment, helps to stabilize the peri-implant soft tissue, which could in turn counteract the early peri-implant inflammatory processes.<sup>11,22,23</sup>

Chiapasco and Zaniboni stated that esthetic complications may occur when an exposed implant surface is left uncovered, such as: (1) soft tissue recession at the buccal aspect with consequent exposure of implant threads; (2) "gray areas" on the mucosa covering the dehiscence, especially in patients with a thin periodontal phenotype; and (3) a flattened aspect of the alveolar ridge in the buccal side.<sup>24</sup>

In this study, the overall marginal bone loss was found to be  $0.92 \pm 1.11$  mm at 12 months from loading, the alveolar bone tissue displacement at the buccal aspect was  $-0.57 \pm 0.52$  in thin phenotypes and  $-0.46 \pm 0.31$  in thick phenotypes ( $p = 0.58$ ), and no signs of soft



**FIGURE 23** Clinical parameters: (A) gingival index. (B) plaque index. (C) probing depth. (D) bleeding on probing.

**TABLE 3** Implant esthetic score after 12 months of loading.

	Thin phenotype	Thick phenotype	Thin versus thick
A. Presence and stability of the mesiodistal papilla (0–2)	$1.22 \pm 0.44$	$1.56 \pm 0.51$	$p = 0.08$
B. Ridge stability buccopalatally (0–1)	$0.89 \pm 0.33$	$1.00 \pm 0.00$	$p = 0.32$
C. Texture of the peri-implant soft tissue (0–2)	$1.67 \pm 0.50$	$1.69 \pm 0.48$	$p = 0.90$
D. Color of the peri-implant soft tissue (0–2)	$1.78 \pm 0.44$	$1.81 \pm 0.40$	$p = 0.83$
E. Gingival contour (0–2)	$2.00 \pm 0.00$	$1.88 \pm 0.34$	$p = 0.32$
Overall score (0–9)	$7.56 \pm 0.53$	$7.94 \pm 0.85$	$p = 0.22$



**TABLE 4** Alveolar bone tissue displacement evaluation after 12 months of loading.

	Thin phenotype	Thick phenotype	Thin versus thick
Buccal side	-0.57 ± 0.52	-0.46 ± 0.31	<i>p</i> = 0.58
Lingual side	-0.23 ± 0.34	-0.34 ± 0.35	<i>p</i> = 0.45
Buccal versus lingual	<i>p</i> = 0.02 <sup>a</sup>	<i>p</i> = 0.19	

<sup>a</sup>Statistically significant.**TABLE 5** Quality of life after 12 months of loading.

	Thin biotype	Thick biotype	Thin versus thick
Chewing (0–10)	9.56 ± 0.53	9.63 ± 0.62	<i>p</i> = 0.74
Speaking (0–10)	9.89 ± 0.33	9.81 ± 0.40	<i>p</i> = 0.57
Esthetics (0–10)	9.56 ± 0.53	9.19 ± 0.66	<i>p</i> = 0.13
Cleaning (0–10)	9.22 ± 0.83	8.94 ± 0.85	<i>p</i> = 0.42
Compared to expectations (0–10)	9.11 ± 0.33	9.19 ± 0.66	<i>p</i> = 0.69

tissue recession or esthetically unpleasant buccal gingiva were reported, in line with previous papers.<sup>25–27</sup>

In the present study MBL has been measured from the loading time and not from the implant placement, since measuring MBL changes in the first year after functional loading is the standard outcome in the dental community, and a loss of 2 mm or less has long been considered among the successful outcomes in several consensus statements.<sup>28,29</sup> A recent retrospective study compared immediate vs delayed loading in two groups of patients subject to immediate implantation after tooth extraction.<sup>30</sup> In this research, no significant difference was observed in the first 3–6 months after implantation, but immediate loading group showed 0.92 mm more bone loss compared to conventional loading group at 24 months follow-up. They concluded that loading time could affect marginal bone level after immediate implantation in extraction sites.<sup>30</sup> In our study, delayed loading implants showed a MBL in line with immediate loading ones. However, the low number of cases undergoing delayed loading (only 5 out of 28) prevented any comparison between different loading modalities.

It is authors' opinion that integrating post-extraction techniques and implant surfaces similar to the present one into our daily practice could provide important benefits for patients in terms of maintenance of marginal bone levels and soft tissue contour, as well as a reduced treatment time, with no need for additional soft tissue grafts.

The observed MBL is compatible with data of the literature on peri-implant bone resorption at 1 year after loading,<sup>16</sup> and does not justify the need for additional soft tissue grafts. However, since the majority of our cases (18 out of 28) showed a thick gingival phenotype, it cannot be excluded that the very good results of bone maintenance obtained in our research may be also connected to this favorable anatomical aspect in addition to the present grafting technique.

The main limitation of the present study is the lack of a control group and the relatively short follow-up. Furthermore, the relatively small sample size could limit the power and the generalization of the observed results. Further limitations can be identified. The first could be the lack of a control group using tapered implants with the same body design with reverse buttress thread and without a laser-

microgrooved collar in another anatomic anterior site in the same patient, but such eventuality of replacing another single tooth at the esthetic zone, not adjacent to the implant already placed, is more unlikely and demanding. The effect of loading timing on MBL could not be investigated, due to the small sample of implants undergoing delayed functional loading. This topic could be investigated in properly designed future studies. According to the exclusion criteria of this study, the presence of adjacent implants was not acceptable, to better analyze the inter-dental/inter-implant papilla esthetic outcome. In future studies, the behavior of papilla between two adjacent implants with the laser microgrooved collars could be specifically investigated.

## 5 | CONCLUSIONS

Guided bone regeneration in post-extraction implant placement plays a relevant role in maintaining the alveolar socket buccal-palatal/lingual dimension and, as a consequence, an adequate esthetic result at the buccal aspect.

The outcome of the present prospective multicenter clinical study was in line with previous reports about immediate post-extraction implant placement, suggesting that the use of MinerOss XP Cancellous Particulate® and BioStrip® in combination with immediate placement of laser-microgrooved implants could be a viable therapeutic option for the rehabilitation of post-extraction sockets in the esthetic zone.

Further studies will be necessary to monitor soft tissue changes on a long-term basis and confirm the promising results of the present report.

## AUTHOR CONTRIBUTIONS

The concept and design of this study was performed by Gabriele Rosano and Tiziano Testori. Data were collected by Gabriele Rosano, Paolo Torrisi, Matteo Invernizzi, and Niccolò Vercellini. Data analysis and interpretation of data was performed by Massimo Del Fabbro, Gabriele Rosano, and Tiziano Testori. Statistics was executed by Massimo del Fabbro. Writing and critical revision was performed by all authors. All authors approved the final version of the manuscript.

## ACKNOWLEDGMENTS

No external funding or grants were received for the present research.

## CONFLICT OF INTEREST STATEMENT

The authors declare no conflict of interest.

## DATA AVAILABILITY STATEMENT

The data that support the findings of this study are available from the corresponding author upon reasonable request.

## INSTITUTIONAL REVIEW BOARD STATEMENT

The present study was conducted in accordance with the guidelines of the World Medical Association Helsinki Declaration of 1975 for biomedical research involving human subjects, as revised in 2000. The study protocol was reviewed and approved by the IRCCS Orthopedic Institute Galeazzi Scientific Board, Milan, Italy (Prot. N. L2057, 2019).

## INFORMED CONSENT STATEMENT

All subjects gave their informed consent for inclusion before they participated in the study.

## ORCID

Massimo Del Fabbro  <https://orcid.org/0000-0001-7144-0984>

## REFERENCES

- Becker W, Becker BE. Guided tissue regeneration for implants placed into extraction sockets and for implant dehiscences: surgical techniques and case report. *Int J Periodontics Restorative Dent.* 1990;10:376-391.
- Lazzara RJ. Immediate implant placement into extraction sites: surgical and restorative advantages. *Int J Periodontics Restorative Dent.* 1989;9:332-343.
- Koh RU, Rudek I, Wang H-L. Immediate implant placement: positives and negatives. *Implant Dent.* 2010;19:98-108.
- Cardaropoli G, Araújo M, Lindhe J. Dynamics of bone tissue formation in tooth extraction sites. An experimental study in dogs. *J Clin Periodontol.* 2003;30:809-818.
- Araujo MG, Lindhe J. Dimensional ridge alterations following tooth extraction. An experimental study in the dog. *J Clin Periodontol.* 2005;32:212-218.
- Araújo MG, Wennström JL, Lindhe J. Modeling of the buccal and lingual bone walls of fresh extraction sites following implant installation. *Clin Oral Implant Res.* 2006;17:606-614.
- Den Hartog L, Huddleston Slater JJR, Vissink A, Meijer HJA, Raghoobar GM. Treatment outcome of immediate, early and conventional single-tooth implants in the aesthetic zone: systematic review to survival, bone level, soft tissue, aesthetics and patient satisfaction. *J Clin Periodontol.* 2008;35:1073-1086.
- Kan JYK, Rungcharassaeng K. Interimplant papilla preservation in the aesthetic zone: a report of six consecutive cases. *Int J Periodontics Restorative Dent.* 2003;23:249-259.
- Rosano G, Taschieri S, Del Fabbro M. Immediate postextraction implant placement using plasma rich in growth factors technology in maxillary premolar region: a new strategy for soft tissue management. *J Oral Implantol.* 2013;39:98-102.
- Testori T, Bianchi F, Del Fabbro M, et al. Implant aesthetic score for evaluating the outcome: immediate loading in the aesthetic zone. *Pract Proced Aesthet Dent.* 2005;17:123-130.
- Guarnieri R, Di Nardo D, Gaimari G, Miccoli G, Testarelli L. Implant-gingival unit stability around one-stage implant with laser-microgrooved collar: three-year result of a prospective study. *Int J Periodontics Restorative Dent.* 2019;39:875-882.
- Schropp L, Kostopoulos L, Wenzel A. Bone healing following immediate versus delayed placement of titanium implants into extraction sockets: a prospective clinical study. *Int J Oral Maxillofac Implants.* 2003;18:189-199.
- Bateli M, Att W, Strub JR. Implant neck configurations for preservation of marginal bone level: a systematic review. *Int J Oral Maxillofac Implants.* 2011;26:290-303.
- Ketabi M, Deporter D. The effects of laser microgrooves on hard and soft tissue attachment to implant collar surfaces: a literature review and interpretation. *Int J Periodontics Restorative Dent.* 2013;33:145-152.
- Hansson S. The implant neck: smooth or provided with retention elements. A biomechanical approach. *Clin Oral Implants Res.* 1999;10:394-405.
- Shin YK, Han CH, Heo SJ, Kim S, Chun HJ. Radiographic evaluation of marginal bone level around implants with different neck designs after 1 year. *Int J Oral Maxillofac Implants.* 2006;21:789-794.
- Lee DW, Choi YS, Park KH, Kim CS, Moon IS. Effect of microthread on the maintenance of marginal bone level: a 3-year prospective study. *Clin Oral Implants Res.* 2007;18:465-470.
- Ricci JL, Grew JC, Alexander H. Connective-tissue responses to defined biomaterial surfaces. I. Growth of rat fibroblast and bone marrow cell colonies on microgrooved substrates. *J Biomed Mater Res A.* 2008;85:313-325.
- Grew JC, Ricci JL, Alexander H. Connective-tissue responses to defined biomaterial surfaces. II. Behavior of rat and mouse fibroblasts cultured on microgrooved substrates. *J Biomed Mater Res A.* 2008;85:326-335.
- Nevins M, Kim DM, Jun SH, Guze K, Schupbach P, Nevins ML. Histologic evidence of a connective tissue attachment to laser microgrooved abutments: a canine study. *Int J Periodontics Restorative Dent.* 2010;30:245-255.
- Nevins M, Nevins ML, Camelo M, Boyesen JL, Kim DM. Human histologic evidence of a connective tissue attachment to a dental implant. *Int J Periodontics Restorative Dent.* 2008;28:111-121.
- Guarnieri R, Ceccarelli R, Ricci JL, Testori T. Implants with and without laser-microtextured collar: a 10-year clinical and radiographic comparative evaluation. *Implant Dent.* 2018;27:81-88.
- Guarnieri R, Grande M, Zuffetti F, Testori T. Incidence of peri-implant diseases on implants with and without laser-microgrooved collar: a 5-year retrospective study carried out in private practice patients. *Int J Oral Maxillofac Implants.* 2018;33:457-465.
- Chiapasco M, Zaniboni M. Clinical outcomes of GBR procedures to correct peri-implant dehiscences and fenestrations: a systematic review. *Clin Oral Implants Res.* 2009;20(suppl 4):113-123.
- Rasperini G, Acunzo R, Cannalire P, Farronato G. Influence of periodontal biotype on root surface exposure during orthodontic treatment: a preliminary study. *Int J Periodontics Restorative Dent.* 2015;35:665-675.
- Fischer KR, Büchel J, Testori T, Rasperini G, Attin T, Schmidlin P. Gingival phenotype assessment methods and classifications revisited: a preclinical study. *Clin Oral Investig.* 2021;25:5513-5518.
- Aslan S, Clauser T, Testori T, Del Fabbro M, Rasperini G. A novel technique for the estimation of gingival thickness: a preliminary study. *Int J Periodontics Restorative Dent.* 2021;41:571-577.

28. Albrektsson T, Zarb G, Worthington P, Eriksson AR. The long-term efficacy of currently used dental implants: a review and proposed criteria of success. *Int J Oral Maxillofac Implants*. 1986; 1:11-25.
29. Misch CE, Perel ML, Wang HL, et al. Implant success, survival, and failure: the international congress of Oral Implantologists (ICOI) Pisa Consensus conference. *Implant Dent*. 2008;17:5-15.
30. Lee SJ, Kim EH, Lee DK, Song IS, Jun SH. The effect of loading time on marginal bone change of implants immediately placed after extraction: a retrospective study. *Int J Implant Dent*. 2022;8:44. doi:[10.1186/s40729-022-00442-2](https://doi.org/10.1186/s40729-022-00442-2)

**How to cite this article:** Rosano G, Testori T, Torrisi P, Invernizzi M, Vercellini N, Del Fabbro M. Immediate placement and loading of implants with laser-microgrooved collar in combination with an anorganic porcine bone mineral matrix in the esthetic zone. Twelve-month results of a prospective multicenter cohort study. *Clin Implant Dent Relat Res*. 2023; 25(6):1164-1177. doi:[10.1111/cid.13261](https://doi.org/10.1111/cid.13261)