

Aesthetic and Functional Abdominoplasty: Anatomical and Clinical Classification based on a 12-year Retrospective Study

Marco Klingner, MD*
 Francesco Klingner, MD†
 Silvia Giannasi, MD*
 Valeria Bandi, MD*
 Valeriano Vinci, MD‡§
 Barbara Catania, MD*
 Andrea Lisa, MD*
 Alessandra Veronesi, MD*
 Andrea Battistini, MD*
 Micol Giaccone, MD†
 Fabio Caviggioli, MD†
 Luca Maione, MD*¶

Background: Abdomen reshaping is a common plastic surgery procedure, and numerous surgical techniques have been described in the scientific literature. To standardize surgical approach, we propose our protocol that correlates patients' anatomy with the type of procedure performed.

Methods: Between 2008 and 2020, we retrospectively analyzed 582 consecutive female patients who underwent abdomen reshaping procedures, assessing anatomical features, complication rate, patient satisfaction, and surgical result, comparing them with previous reports in the literature. Aesthetic outcomes were evaluated with VAS scale (0–10).

Results: Among the 582 patients recruited in the study, we performed 74 liposuctions as a single procedure, 62 mini-abdominoplasties, 28 T-inverted abdominoplasties, and 418 full-abdominoplasties. Aesthetic outcome evaluation reported a mean value of 8.2 from patients and 7.8 from surgeons. We experienced four early postoperative bleedings requiring hemostasis revision, 18 wound dehiscences, five seromas, and 24 re-interventions for aesthetic issues. We found no differences in the complication rate while comparing our data with previous reports in the literature.

Conclusions: Our protocol and surgical technique have proved to be effective, safe, and reproducible, with high patient and surgeon satisfaction, low complication rate, and fast recovery time. (*Plast Reconstr Surg Glob Open* 2021;9:e3936; doi: 10.1097/GOX.0000000000003936; Published online 20 December 2021.)

INTRODUCTION

Body contouring surgery, in particular abdominoplasty, has become an increasingly popular procedure among patients seeking both aesthetic and functional results. The patient population requiring this surgical procedure is extremely heterogeneous. Excess of either fat or

skin may be prevalent (involving either the entire trunk or only the anterior aspect of the abdomen) and rectus muscle diastasis may occur; for this reason, all components of the abdominal profile should be separately addressed during surgery. Causes of abdominal deformity include aging, hormonal changes (intrinsic and/or extrinsic), excessive weight gain or loss, rectus muscle diastasis, pregnancies, surgical incisions, hernias, genetic defects, and drugs. Nowadays, abdominoplasty is proposed not only to overweight patients, but also to patients showing massive weight loss sequelae following bariatric surgery (trunk festoons) and to thin and postpregnancy patients. Because all these patients can be very different in their presentation, the surgical approach should be tailored to the specific case.^{1,2}

The history of abdominoplasty records the attempt to improve long-term aesthetic outcomes and achieve high patient satisfaction. After the 1960s, many authors have proposed different surgical techniques resulting in horizontal, vertical, or a combination of both scars, and the recent debate has been focused on minimally-invasive procedures. Today, abdominoplasty is performed after bariatric surgery, combined with liposuction, to improve body

From *Plastic Surgery Unit, Department of Medical Biotechnology and Translational Medicine BIOMETRA, Humanitas Clinical and Research Hospital, Reconstructive and Aesthetic Plastic Surgery School, University of Milan, Rozzano, Milan, Italy; †Plastic Surgery Unit, MultiMedica Holding S.p.A., Reconstructive and Aesthetic Plastic Surgery School, University of Milan, Milan, Italy; ‡Humanitas University Department of Biomedical Sciences, Milan, Italy; §Humanitas Clinical and Research Center – IRCCS, Milan, Italy; and ¶Plastic Surgery Unit, Clinica San Carlo, Paderno Dugnano (Milan), Italy.

Received for publication July 5, 2021; accepted September 24, 2021.

Copyright © 2021 The Authors. Published by Wolters Kluwer Health, Inc. on behalf of The American Society of Plastic Surgeons. This is an open-access article distributed under the terms of the [Creative Commons Attribution-Non Commercial-No Derivatives License 4.0 \(CCBY-NC-ND\)](https://creativecommons.org/licenses/by-nc-nd/4.0/), where it is permissible to download and share the work provided it is properly cited. The work cannot be changed in any way or used commercially without permission from the journal.

DOI: 10.1097/GOX.0000000000003936

Disclosure: The authors have no financial interest in relation to the content of this article.

contour of normal-weight patients and/or repair rectus muscle diastasis or abdominal hernia (postpregnancy or not).^{9–10}

Several authors do not perform a deep dissection at the level of the rectus abdominis aponeurosis to preserve the lymphatic network, assuming a consequent reduction of seroma formation. The incidence of seroma in the literature has been described as follows: 0.4% according to Saldanha,^{11–13} 0.1% according to Pollock,^{14,15} 0.2% according to Pascal and Le Louarn.^{16,17} Furthermore, the aforementioned authors adopt a reduced undermining in the supraumbilical area, limiting the dissection to a tunnel in the paramedian abdominal wall with no lateral extension, assuming a safer vascular supply to the abdominal flap.¹⁸

In the present study, we report our protocol to abdomen reshaping depending on the specific patient’s anatomical features, discussing our surgical approach and comparing our results in terms of complication rate and aesthetic outcome with the previously reported experience in the literature. Moreover, as already demonstrated by Rousseau et al,¹⁹ we think diathermocoagulation flap dissection is associated with a higher incidence of noninfectious fluid collections, increased drain output and time before drain removal, compared with steel cold blade dissection. Indeed, before 2008 our group used to perform abdominal surgery with diathermocoagulation only, and after observing a high incidence of seromas, we started using cold blade dissection, with excellent results. In addition to a reduced local complication rate, we believe that cold blade dissection can also promote a faster recovery, thus achieving the final result more rapidly.

MATERIALS AND METHODS

We retrospectively analyzed 582 consecutive female patients who underwent pure aesthetic abdomen reshaping procedures between 2008 and 2020, according to our protocol (Table 1). We excluded postbariatric patients from the study. The average follow-up was 1.5 years. The surgical procedures were all performed by three experienced surgeons, each of them having more than 10 years’ experience. We considered three different anatomical variables to correctly plan the surgery: adipose tissue, muscle continence, and skin.

Table 1. Protocol Used to Correlate Patient’s Anatomical Presentation and the Type of Surgery Needed

	Type	Clinical Condition	Surgical Procedure
Fat	F0	No excess	No need for surgery
	F1	Excess	Liposuction
Muscle	M0	No defect	No need for surgery
	M1	Diastasis	Rectus sheath plication
	M2	Hernia/laparocoele	–Herniorraphie –Plug-in –Mesh
Skin	S0	No skin excess	No need for surgery
	S1	Mild ptosis/excess	Mini-abdominoplasty
	S2	Moderate ptosis/excess	Partial t-inverted abdominoplasty (2 possible vertical scars)
	S3	Severe ptosis/excess	Full-abdominoplasty complete t-inverted abdominoplasty

Takeaways

Question: What are the different types of abdominoplasty available to treat each clinical presentation?

Findings: Considering the wide spectrum of surgical procedures available to treat the skin and/or fat of the abdominal area, we would like to show our protocol. In the recent years, we have increased our knowledge on abdomen remodeling, and we have decided to publish our experience with our protocol.

Meaning: Our protocol and surgical technique have proved to be effective, safe, and reproducible, with high patient and surgeon satisfaction, low complication rate, and fast recovery time.

We evaluated patients’ and surgeons’ satisfaction 1 year after the surgical procedure (on a VAS scale from 0 to 10). Surgical outcome was evaluated by two independent surgeons with specific expertise on abdominoplasties who did not perform the surgery (both had more than 15 years of experience in plastic surgery and were blind about who performed the surgical procedure). We also compared our complication rate with previous reports in the literature.

SURGICAL TECHNIQUES

We considered different anatomical variables to correctly plan the surgery (Fig. 1). The three main variables addressed before surgery were: fat excess, muscle continence, and skin excess.

Type F1 – Fat Excess: In case of an abdomen with a pure fat excess, with no excess skin and no muscle-aponeurotic laxity, a simple liposuction can be performed (deep and/or superficial, depending on the patient’s skin laxity). In patients with skin excess and/or muscle laxity, we perform liposuction before the abdominoplasty.

Liposuction areas are drawn preoperatively with the patient in standing position. With the patient in the supine position, skin incisions are performed at the level of the umbilicus and lower abdomen at right and left inguinal region, respectively (at the same level, where we plan to perform the incision of the abdominoplasty, if needed). The areas are infiltrated with a solution based on 1 mg of epinephrine in 1000 ml of saline solution; successively, a standard liposuction of both deep and superficial planes is performed using 2/2.5 mm blunt-tip cannulas in the marked areas (which do not include the areas of skin resection).

MUSCLE CONTINENCE:

- **Type M1—Diastasis:** When a rectus sheath diastasis is present, it often impacts on the abdominal profile (especially in thin post-gravidic patients), and its surgical correction is crucial. In these patients, we perform rectus sheath plication with interrupted absorbable stitches (Polyglactin 1) to correct the anterior bulging and reduce the abdominal circumference, thus

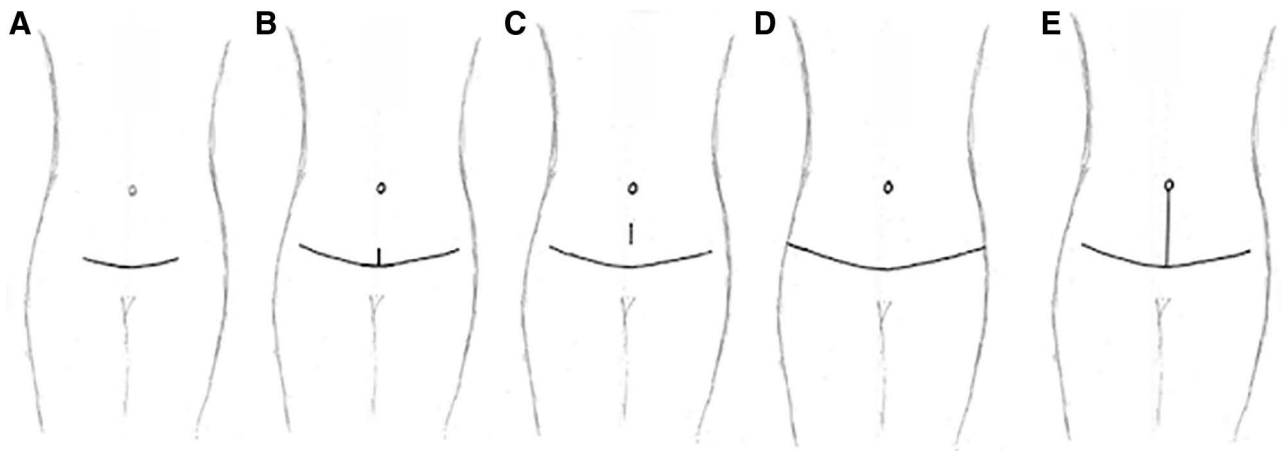


Fig. 1. Skin incisions of the different techniques. From left to right: A, mini-abdominoplasty; B–D, T-inverted abdominoplasty; E, full-abdominoplasty.

creating a slender body contour. Moreover, the knots must be placed deeply to prevent any possible palpability, especially in thin patients.

- Type M2—Hernia/Laparocele: In case of abdominal hernia or laparocele protruding from the abdominal wall, we address the defect depending on its severity. If the defect is less than 1 cm, it can be repaired with a herniorrhaphy. If the defect is between 1 and 2 cm, hernia is corrected by plug-in positioning. For defects more than 2 cm, the correction is made with the help of a general surgeon, and a Polypropylene mesh is employed if we entirely close the peritoneum; on the contrary (not closed peritoneum), a dual mesh (Polypropylene and Polyglactin) is positioned. In addition to the correction of the hernia, rectus sheath diastasis must also be corrected. Indeed, we observed that abdominal hernia is often associated with a rectus sheath laxity, which needs to be addressed as mentioned above.

SKIN EXCESS

- Type S1—Mild Ptosis/Excess: In case of an abdomen with mild suprapubic excess skin, with or without excess fat between the pubis and the umbilicus and muscle-aponeurotic flaccidity, a mini-abdominoplasty can be performed. The amount of skin to be resected depends on the patient presentation, as well as the length of the suprapubic incision. To perform rectus sheath plication in the supraumbilical area, we detach the umbilicus from the abdominal flap and reposition it in the same position. (Fig. 1A)
- Type S2—Moderate Ptosis/Excess: In case of an abdomen with moderate excess skin in the epigastrium and hypogastrium, muscle-aponeurotic flaccidity and/or excess fat, a T-inverted abdominoplasty is performed. Sometimes the skin excess is not enough to remove the flap from umbilicus to pubis; in this case, it is necessary to close the old umbilical scar implantation site with a vertical incision and reposition the umbilicus, avoiding excessive tension on the wound. The length and the position of the vertical scar are not predictable before

the surgery but need to be tailored on patient presentation (Fig. 1B, C).

- Type S3—Severe Ptosis/Excess: In case of an abdomen with severe excess skin in the epigastrium and hypogastrium, with or without muscle-aponeurotic flaccidity or excess fat, a full-abdominoplasty with a long linear suprapubic incision is performed, together with an umbilical transposition (Fig. 1E). In case of severe horizontal and vertical skin excess, a vertical skin resection is performed, resulting in a vertical scar (complete T-inverted abdominoplasty) (Fig. 1D).

SURGICAL KEY POINTS

- Cold blade/finger dissection
- Supraumbilical wide and laterally extended undermining (Fig. 2)
- Pre-aponeurotic deep dissection with lymphatic network division
- Long incision
- Single stitches with deep knots for rectus sheath plication

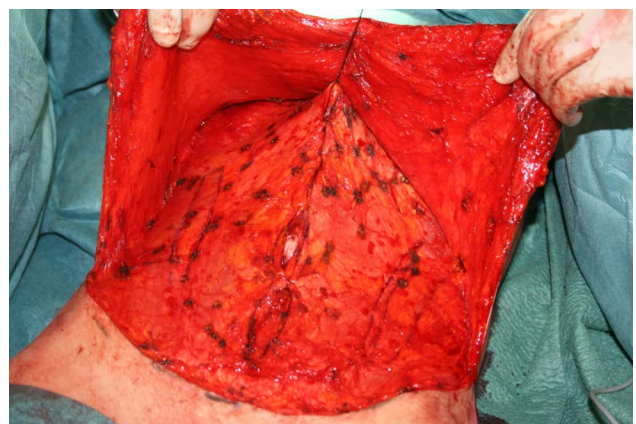


Fig. 2. Intraoperative picture of the wide undermining we perform to obtain a full mobilization of the abdominal flap.

- Umbilical transposition (depending on preoperative position and on the patient)
- Proportioned resection (no changes in the relationship between thorax and abdomen lengths)
- Abdominal flap debulking
- Pubic flap fixation on fascial plane
- Reduced flap medialization

General consideration at the end of surgery: To prevent superior dislocation of the horizontal scar, we perform a pubic flap fixation on fascial plane before flap suture. Two drains are placed in the pubic area. Finally, we keep compressive garments for 6 days and an abdominal girdle for up to one month after surgery to reduce dead space and, consequently, seroma formation, thus favoring flap adhesion to deep layers.

Postoperative care: we remove drains after 24 hours; we maintain compressive dressing for 6 days, then patients must wear an abdominal band for a month.

RESULTS

The average age was 47 years, the mean BMI was 27.54kg/m²; 104 patients (17.8%) underwent previous abdominal surgeries (52 C-sections, three laparotomies, 19 had abdominal scars from previous traumas, 34 patients had a scar for a previous appendectomy procedure). Among the patients recruited, 149 (25.6%) were smokers, 46 (7.9%) were obese (BMI > 30), 29 (4.9%) had diabetes and three (0.5%) were taking corticosteroid therapy.

We performed the following:

- 74 liposuctions as single procedure (Fig. 3).
- 62 mini-abdominoplasties: 36 mini-abdominoplasties as single procedure, 26 mini-abdominoplasties with rectus sheath plication.
- 98 T-inverted abdominoplasties: 79 abdominoplasties from Group B, 16 from group C, three from group D (Fig. 4).
- 348 full-abdominoplasties: 10 full-abdominoplasties as single procedure, 112 full-abdominoplasties with rectus sheath plication (Fig. 5), six full-abdominoplasties with hernia repair (three with herniorrhaphies, two with the plug-in and one with the mesh) (Fig. 6), 42 full-abdominoplasties combined with liposuction, 178 full-abdominoplasties with liposuction and rectus sheath plication (Fig. 7).

Aesthetic outcome evaluation reported a mean value of 8.2 from patients and 7.8 from surgeons on a 0–10 VAS scale.

During follow-up, we experienced four hemorrhages requiring haemostasis revision, 18 wound dehiscences (10 treated with standard medications and eight with negative pressure wound therapy), two seromas (drained in outpatient office), and 24 re-interventions for aesthetic issues. The overall complication rate was 5.3% (Table 2).

RE-INTERVENTION

In three patients, we performed a simple scar revision for aesthetic issues, while 14 patients complained of

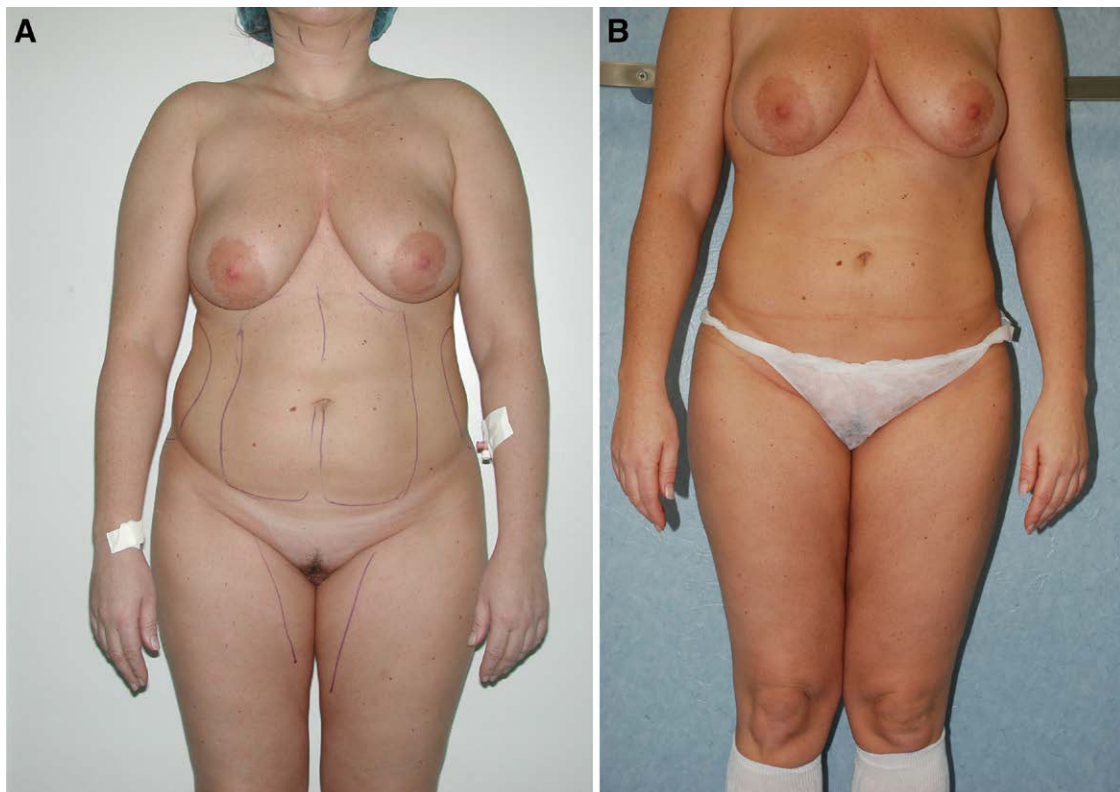


Fig. 3. Preoperative (A) and postoperative (B) views (liposuction).

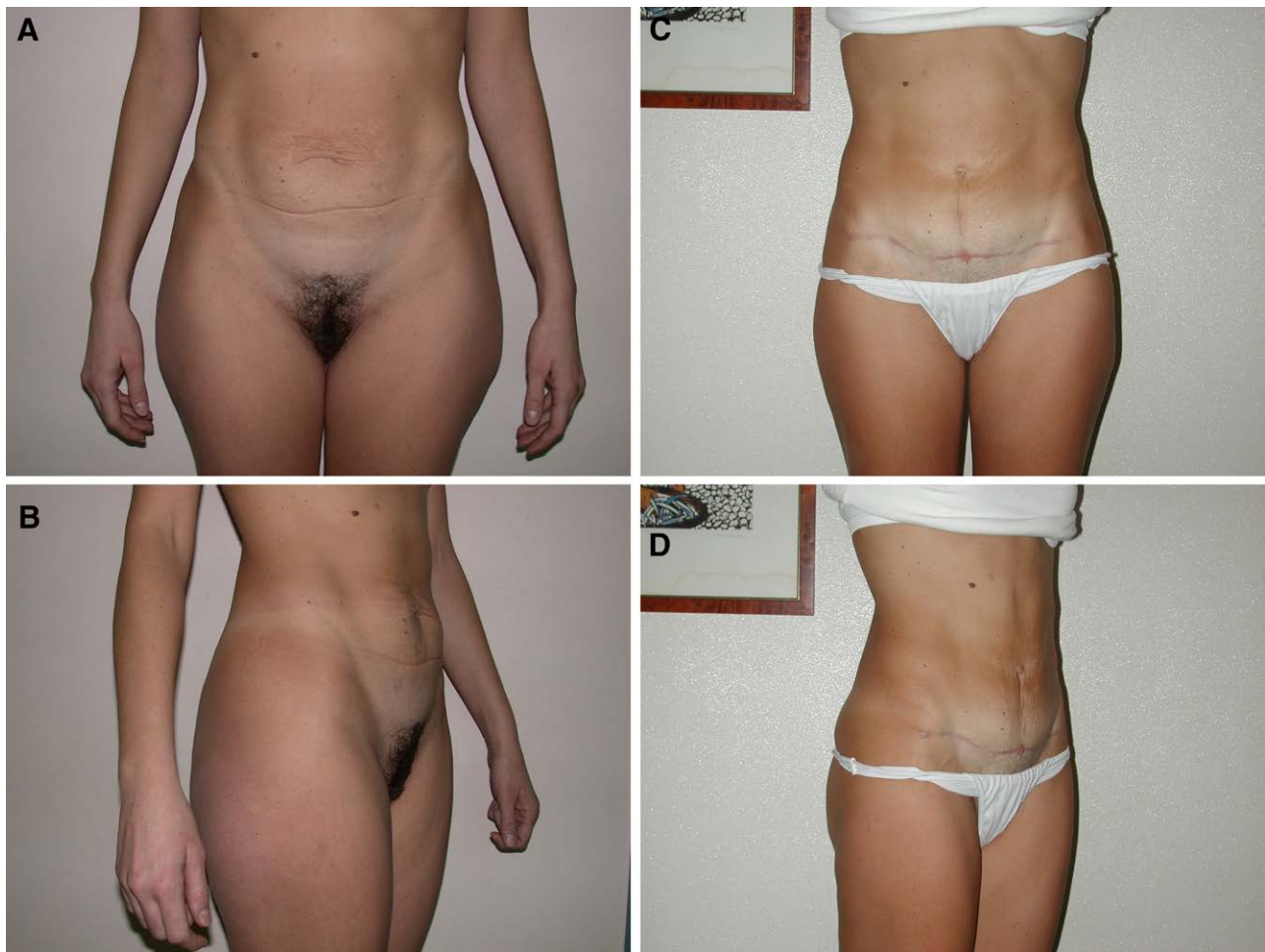

Fig. 4. Preoperative (A-B) and postoperative (C-D) views (T-inverted abdominoplasty with rectus sheath plication and liposuction).

poor scars and superior flap bulging. In those patients we did not perform a secondary abdominoplasty or surgical scar revision, but we harvested fat from the superior bulging and grafted it into the scar after its processing according to the Coleman technique^{20,21} (Fig. 8). Finally, seven patients underwent secondary liposuction for incomplete excess fat removal in the flank region.

DISCUSSION

The correct approach to abdominal deformities should include evaluation of local anatomy, muscular integrity, systemic and local conditions, and psychosocial aspects. We propose performing different techniques depending on all these parameters.

Our group performs classical approaches for liposuction (tumescent technique), muscle defect repair, and abdominoplasty. In this article, we focused on some technical details and related healing processes.

We opt for a long incision at the natural suprapubic fold (the line that connects right to left anterior superior iliac spine—ASIS, no more than 8 cm from anterior labial commissure). We prefer cold blade, finger-assisted dissection

on the suprafascial plane (interrupting lymphatic vessels) to avoid heat damage to the tissues (induced by cautery), thus reducing seroma occurrence or prolonged flap edema. Furthermore, we carry on a wide undermining up to the xiphoid process in most cases as a means to address the entire abdominal profile, thus achieving a complete contour reshaping. In our experience, we observed few complications related to the blood supply to the flap, without any postoperative loss of sensitivity and we believe that a complete and effective abdominal silhouette can be better achieved with a wide undermining. This disaccords with Saldanha,^{11–13} with his “lipoabdominoplasty” technique, which preserves the Scarpa’s fascia and deep fat layer on the inferior flap (under the umbilicus), limiting the undermining just between the medial borders of the rectus abdominis muscle. He advocates that this limited dissection preserves major perforating vessels to the flap, improving lymphatic drainage and decreasing nervous damage.

Once the dissection part is completed, muscle continence is evaluated. When rectus sheath diastasis is present (also minimal), it often has an impact on the abdominal profile (especially in thin postgravidic

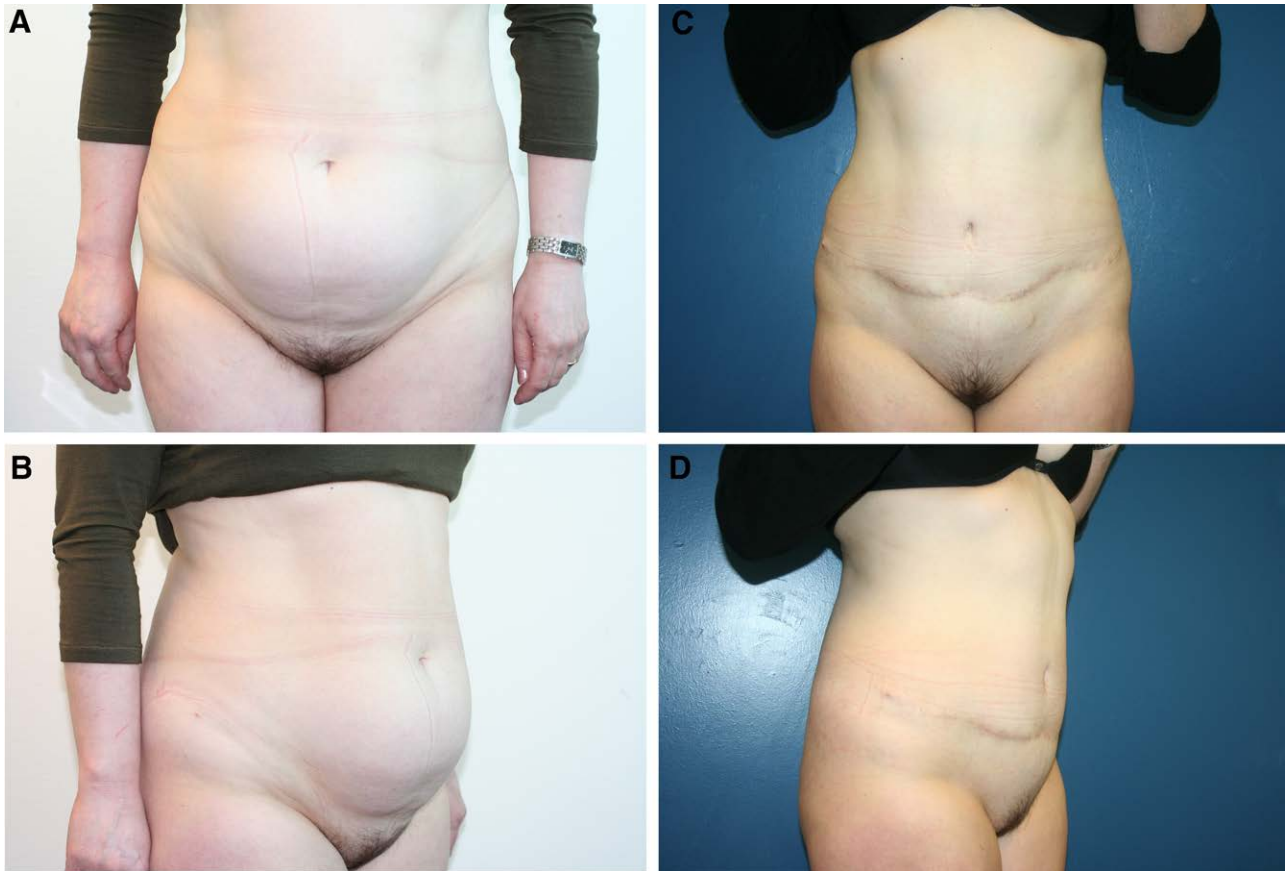


Fig. 5. Preoperative (A-B) and postoperative (C-D) views (full-abdominoplasty with rectus sheath plication).

patients), and its surgical correction is crucial. In these patients, we perform rectus sheath plication, which is fundamental to correct the anterior bulging and reduce the abdominal circumference, thus creating a slender body contour.

Another keystone of our technique is the preservation of the natural dimensional thorax-umbilical-pubic ratios. In particular, when we perform umbilical transposition, we always try to maintain the preexisting umbilical-pubic and umbilical-xiphoid distance ratio to achieve a result that naturally fits patients' silhouette. Therefore, we try to limit skin resection to prevent any upward scar displacement, maintain patient's proportions, and reduce the risk of distal flap necrosis.

In heavy smokers, we perform a smaller cutaneous resection when compared with nonsmokers to avoid tensile vascular stress. In a nonsmoker, the decision of skin resection is made with the patient in a semi-sitting position (45 degrees); in smokers, we keep the patient lying down, so that the skin resection will be less extensive.

Moreover, we often perform a debulking of the abdominal flap on the Scarpa's fascia plane using scissors to match the pubic flap thickness and we usually anchor the latter to the muscular fascia to prevent an upward scar displacement. When performing this

surgical step, we try to be as conservative as possible (no more than 3 cm of debulking) because, if the procedure is too extended, it might create a lack of fascial structure that is an important anchoring point to recreate the superficial fascial system continuity and reduce the scar tension. Besides, this is important to preserve a good vascular supply to the flap and avoid any postoperative complications.

The amount of skin and fat resection is crucial in determining flap tension; nevertheless, the surgeon should consider that muscular wall repair will yield narrowing of the entire abdomen, which decreases lateral tension, allowing the superiorly-based flap to be sutured with moderate tension on deep stitches and medialized. Baroudi's stitches^{8,9} (which reduce dead space) and progressive tension sutures^{14,15} are described to be complementary tips, which may help in preventing early complications, achieving improved recovery and long-term outcomes. Based on our experience, we prefer not to use this technique to avoid possible internal tissue retraction. We believe it is preferable to have a vertical scar to avoid tension and subsequent ischemic fat necrosis on the margin of the flap, when we face the "grey zone" situation in which we do not have a sufficient skin excess to perform a full-abdominoplasty, although the skin excess is neither as little to be addressed with a simple mini-abdominoplasty.

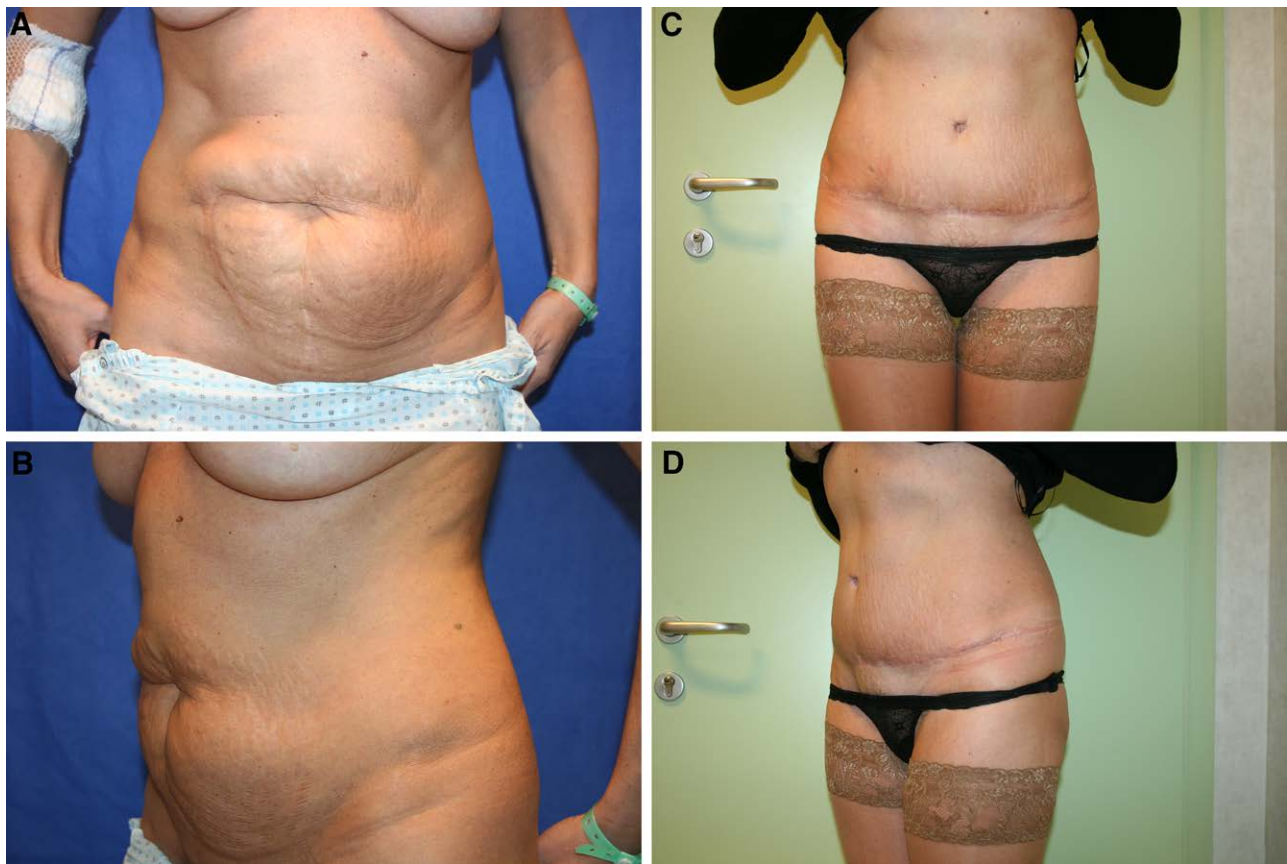


Fig. 6. Preoperative (A-B) and postoperative (C-D) views (full-abdominoplasty with MESH and liposuction).

High lateral tension procedures^{22,23} may be suitable in such patients, but we have found that classic subumbilical dermolipectomy is adequate and allows proper medial and lateral excision and flank lifting. Besides, the use of cold blade dissection is fast, precise, and avoids thermal injury to the flap. In our experience, deep pre-aponeurotic dissection with reduced lymphatic trunks preservation has no impact on seroma formation, and our surgical approach has proved to be safe with a similar complication rate compared with previous reports. More specifically, we found an overall complication rate of 5.3% (seroma 0.3%, partial flap necrosis 0.8%, wound dehiscence 3.1%, infection 0.3%, hemorrhage/hematoma 0.69%). Le Louarn and Pascal^{16,17} reported an overall complication rate of 6.8%: 0.9% of partial necrosis, 4.7% of scar asymmetries requiring revision, 0.4% of venous thromboembolism, 0.2% of local infection, 0.2% of hematoma, and 0.2% of seroma. Pollock^{14,15} reported an overall complication rate of 4.2%: 0.1% of seroma, 0.1% of major flap necrosis, 0.6% of minor flap necrosis, 1.17% of local cellulitis, 0.3% of abscess, 0.3% of hematoma, 0.5% of minor dehiscence, 10.7% of revision surgeries. Saldanha^{11,13} reported a 0.4% of seroma rate, 0.4% of dehiscence, 0.2% of necrosis, 0.2% hematoma, 0.2% deep venous thromboembolism, and 10% of revision rate. Our results are similar to other reports in the scientific literature.²⁴⁻³³ (Table 3).

Our experience with abdominal surgery is longstanding. Before 2008, we used to employ diathermocoagulation in the totality of our patients, but we noticed a high incidence of noninfective fluid collections. For this reason, we switched to cold blade dissection, and realized that this new technique led to a reduced number of seromas. After many years of experience, we believe cold blade results in a faster healing process compared with diathermocoagulation, thus achieving the final result more rapidly than with the techniques involving cautery.

CONCLUSIONS

Our protocol represents a safe and practical approach providing a surgical preoperative planning framework based on patients' anatomy evaluation. Our results with high patients' and surgeons' satisfaction and low complication rate showed our approach to be safe and reproducible.

Moreover, cold blade dissection is an effective method to reduce the flap edema and to obtain faster healing. The downside of our technique could be that the use of cold blade can increase the risk of bleeding (hemorrhages or hematoma). Moreover, our horizontal scars are longer because we medialize the flaps less than the traditional techniques.

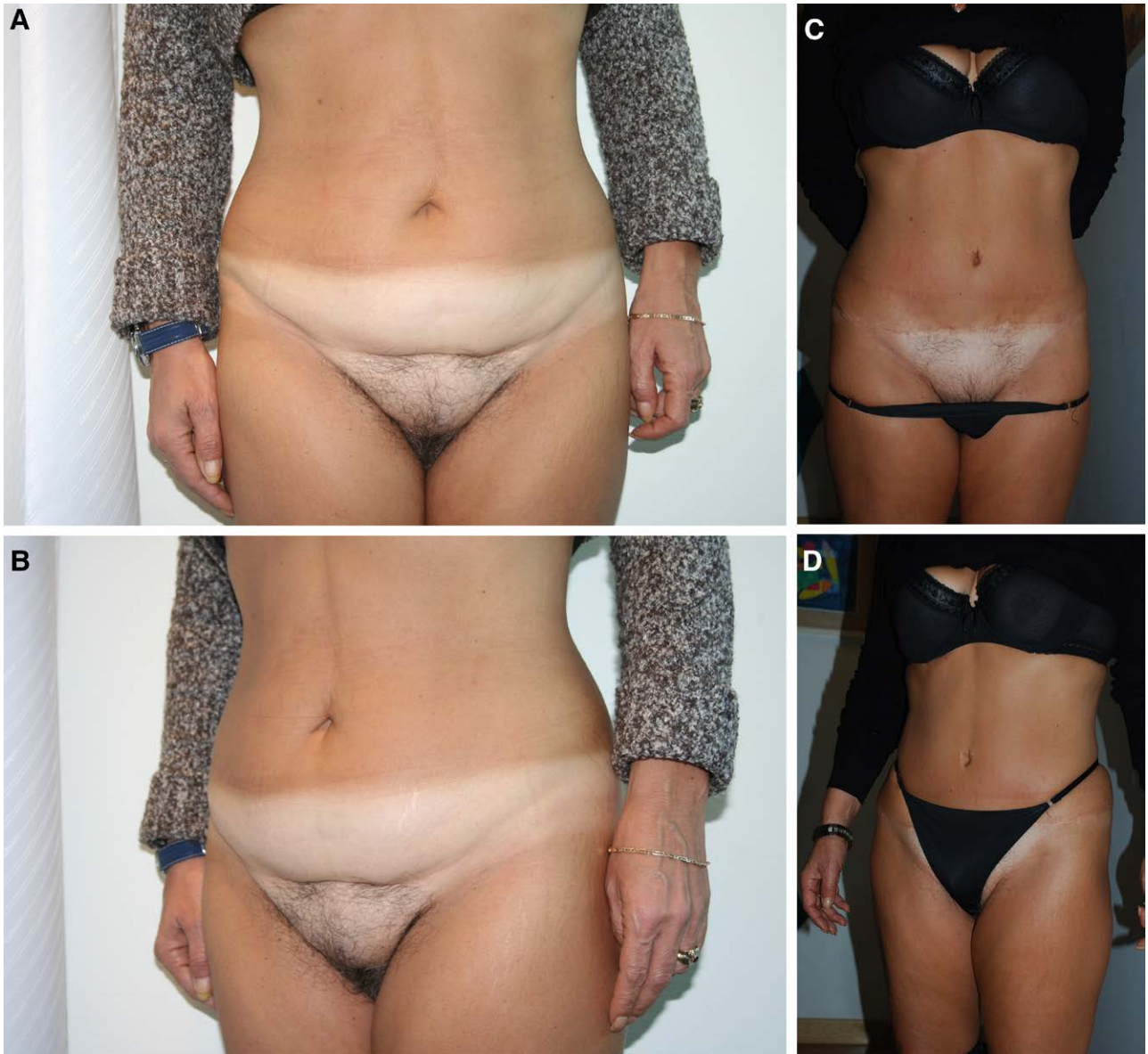

Fig. 7. Preoperative (A-B) and postoperative (C-D) (full-abdominoplasty with liposuction and rectus sheath plication).

Table 2. Number of Patients Treated, the Number of Complications, and the Mean Patients' and Surgeons' Aesthetic Outcome Values for Each Technique

	Mean Patient's Evaluation	Mean Surgeon's Evaluation	Hemorrhage	Dehiscence	Infection	Seroma	Partial Flap Necrosis	Scar Revision	Fat Graft	Secondary Liposuction
Liposuction (n = 74)	8.1 SD 2.3	7.9 SD 2.1	0	0	0	0	0	0	0	1 1.3%
Mini abdominoplasty (n = 62)	7.6 SD 1.8	7.8 SD 2.2	0	0	0	0	0	0	0	0
T-inverted abdominoplasty (n = 98)	7.9 SD 2.1	8.0 SD 2.1	11.1%	55.6%	0	11.1 %	11.1%	22.2%	11.1%	1 1.1%
Full-abdominoplasty (n = 348)	8.3 SD 3.2	8.1 SD 1.8	30.8%	133.6%	20.05%	10.2%	41,1%	10.2%	133.6%	5 1.3%

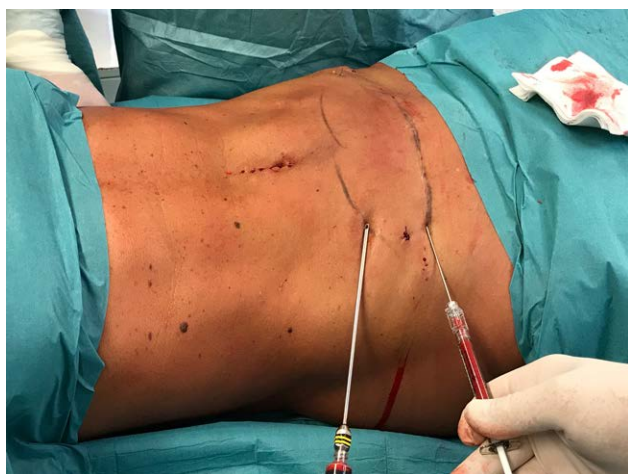

Fig. 8. Intraoperative view of the fat harvesting and consequent injection in the volume deficit area.

Table 3. Complication Rate Comparison

	Le Louarn and Pascal	Pollock et al.	Saldanha et al.	Klinger et al.
Seroma	0.2%	0.1%	0.4%	0.3%
Partial flap necrosis	0.9%	0.6%	0.2%	0.8%
Wound dehiscence	—	0.5%	0.4%	3.1%
Infection	0.2%	1.17%	—	0.3%
Hemorrhage/hematoma	0.2%	0.3%	0.2%	0.69%
Total complication rate	6.8%	4.2%	—	5.3%

Andrea Battistini, MD

Department of Medical Biotechnology and Translational Medicine BIOMETRA
Plastic Surgery Unit, Humanitas Clinical and Research Center
University of Milan, Via Manzoni 56
20089 Rozzano
Milan, Italy
E-mail: andrea.battistini@humanitas.it

ACKNOWLEDGMENTS

Approval was obtained from the ethics committee of Humanitas Clinical and Research Hospital, MultiMedica Holding S.p.A. and Clinica San Carlo (Paderno Dugnano). The procedures used in this study adhere to the tenets of the Declaration of Helsinki. Informed consent was obtained from all individual participants included in the study.

REFERENCES

- Matarasso A, Matarasso DM, Matarasso EJ. Abdominoplasty: classic principles and technique. *Clin Plast Surg.* 2014;41:655–672.
- Toledo LS. The overlap of lipoplasty and abdominoplasty: indication, classification, and treatment. *Clin Plast Surg.* 2004;31:539–53, v.
- Mühlbauer W. Radical abdominoplasty, including body shaping: representative cases. *Aesthetic Plast Surg.* 1989;13:105–110.
- Pitanguy I. Evaluation of body contouring surgery today: a 30-year perspective. *Plast Reconstr Surg.* 2000;105:1499–514; discussion 1515.
- El-Khatib HA, Bener A. Abdominal dermolipectomy in an abdomen with pre-existing scars: a different concept. *Plast Reconstr Surg.* 2004;114:992–997.
- Grazer FM. Abdominoplasty. *Plast Reconstr Surg.* 1973;51:617–623.

- Hughes CE III, Lockwood TE, Baroudi R, et al. Abdominoplasty. *Aesthet Surg J.* 2002;22:465–473.
- Baroudi R, Keppke EM, Netto FT. Abdominoplasty. *Plast Reconstr Surg.* 1974;54:161–168.
- Baroudi R, Ferreira CA. Seroma: how to avoid it and how to treat it. *Aesthet Surg J.* 1998;18:439–441.
- Baroudi R, Ferreira CA. Contouring the hip and the abdomen. *Clin Plast Surg.* 1996;23:551–72; discussion 572.
- Saldanha OR, Azevedo SF, Delboni PS, et al. Lipoabdominoplasty: the Saldanha technique. *Clin Plast Surg.* 2010;37:469–481.
- Saldanha OR, Federico R, Daher PF, et al. Lipoabdominoplasty. *Plast Reconstr Surg.* 2009;124:934–942.
- Saldanha OR, De Souza Pinto EB, Mattos WN Jr, et al. Lipoabdominoplasty with selective and safe undermining. *Aesthetic Plast Surg.* 2003;27:322–327.
- Pollock T, Pollock H. Progressive tension sutures in abdominoplasty. *Clin Plast Surg.* 2004;31:583–589, vi.
- Pollock TA, Pollock H. Progressive tension sutures in abdominoplasty: a review of 597 consecutive cases. *Aesthet Surg J.* 2012;32:729–742.
- Le Louarn C, Pascal JF. The high-superior-tension technique: evolution of lipoabdominoplasty. *Aesthetic Plast Surg.* 2010;34:773–781.
- Le Louarn C, Pascal JF. High superior tension abdominoplasty. *Aesthetic Plast Surg.* 2000;24:375–381.
- Gutowski KA. Evidence-based medicine: abdominoplasty. *Plast Reconstr Surg.* 2018;141:286e–299e.
- Rousseau P, Vincent H, Potier B, et al. Diathermocoagulation in cutting mode and large flap dissection. *Plast Reconstr Surg.* 2011;127:2093–2098.
- Caviggioli F, Forcellini D, Vinci V, et al. Employment of needles: a different technique for fat placement. *Plast Reconstr Surg.* 2012;130:373e–374e.
- Klinger M, Caviggioli F, Klinger FM, et al. Autologous fat graft in scar treatment. *J Craniofac Surg.* 2013;24:1610–1615.
- Lockwood TE. Maximizing aesthetics in lateral-tension abdominoplasty and body lifts. *Clin Plast Surg.* 2004;31:523–37, v.
- Lockwood T. High-lateral-tension abdominoplasty with superficial fascial system suspension. *Plast Reconstr Surg.* 1995;96:603–615.
- Valença-Filipe R, Martins A, Silva Á, et al. Dissection technique for abdominoplasty: a prospective study on scalpel versus diathermocoagulation (Coagulation Mode). *Plast Reconstr Surg Glob Open.* 2015;3:e299.
- Vindigni V, Marchica P, Pagani A, et al. Inguinocrural dermolipectomy: a retrospective study. *Ann Ital Chir.* 2019;90:350–356.
- Brauman D, van der Hulst RRWJ, van der Lei B. Abdominoplasty with circumferential liposuction: a review of 1000 consecutive cases. *Plast Reconstr Surg.* 2019;144:328e–330e.
- Batac J, Hamade M, Hamade H, et al. Abdominoplasty in the obese patient: risk versus reward. *Plast Reconstr Surg.* 2019;143:721e–726e.
- Boudreault DJ, Sieber DA. Getting the best results in abdominoplasty: current advanced concepts. *Plast Reconstr Surg.* 2019;143:628e–636e.
- Rosenfield LK, Davis CR. Evidence-based abdominoplasty review with body contouring algorithm. *Aesthet Surg J.* 2019;39:643–661.
- Papadopoulos NA, Meier AC, Henrich G, et al. Aesthetic abdominoplasty has a positive impact on quality of life prospectively. *J Plast Reconstr Aesthet Surg.* 2019;72:813–820.
- Jin S, Li F. [Research progress of abdominoplasty]. *Zhongguo Xiu Fu Chong Jian Wai Ke Za Zhi.* 2018;32:1611–1614.
- Brauman D, van der Hulst RRWJ, van der Lei B. Liposuction assisted abdominoplasty: an enhanced abdominoplasty technique. *Plast Reconstr Surg Glob Open.* 2018;6:e1940.
- Dutot MC, Serron K, Al Ameri O, et al. Improving safety after abdominoplasty: a retrospective review of 1128 cases. *Plast Reconstr Surg.* 2018;142:355–362.