



Double balloon enteroscopy with laparoscopic assistance and surgical treatment of a subcutaneous varix fistula into the small bowel: case report and literature review

Elisa Cassinotti¹, Luigi Boni¹, Massimilano Della Porta¹, Luca Elli², Ludovica Baldari¹

¹General Surgery, Fondazione IRCCS Cà Granda Ospedale Maggiore Policlinico, Milan, Italy; ²Gastroenterology and Digestive Diseases, Fondazione IRCCS Cà Granda Ospedale Maggiore Policlinico, Milan, Italy

Correspondence to: Elisa Cassinotti. General Surgery, Fondazione IRCCS Cà Granda Ospedale Maggiore Policlinico, Milan, Italy.

Email: cassinotti.elisa@gmail.com.

Abstract: Obscure gastrointestinal bleeding (OGIB) accounts for approximately 5% of gastro-intestinal (GI) bleedings and in most of the cases bleeding sources are reported within the small bowel. After video capsule endoscopy for diagnosis, enteroscopy is recommended to confirm and possibly treat lesions. Combined enteroscopic and laparoscopic approach to treat small bowel lesions has been described in literature. We report the case of a patient with a fistula formed from a subcutaneous varix infiltrating the small bowel with consequent bleeding and severe anemization. After several diagnostic tests, the patient underwent antegrade double-balloon enteroscopy under laparoscopic guidance and definitive surgical treatment.

Keywords: Double balloon enteroscopy; laparoscopy; periumbilical varices; small bowel bleeding

Received: 20 June 2020; Accepted: 28 December 2020; Published: 30 December 2020.

doi: [10.21037/dmr-20-95](https://doi.org/10.21037/dmr-20-95)

View this article at: <http://dx.doi.org/10.21037/dmr-20-95>

Introduction

Obscure gastrointestinal bleeding (OGIB) has been defined as bleeding from unidentified origin that persists after initial negative upper and lower gastrointestinal (GI) evaluation through gastroscopy and colonoscopy (1,2).

OGIB accounts for approximately 5% of GI bleedings and in most of the cases bleeding sources are reported within the small bowel (3); small bowel bleeding can present as overt bleeding (clinically evident melena or hematochezia), occult bleeding leading to transfusion-dependent anemia or more rarely as massive bleeding requiring urgent surgical intervention (4).

OGIB can depend from small bowel tumors or from several types of vascular abnormalities affecting the small intestine such as angiodysplasias/angioectasias, arteriovenous malformations, Dieulafoy ulcers or ileal varices. Varices are more often reported in patients already suffering from portal hypertension while idiopathic ileal varices are a rare condition (5).

Small bowel diseases are a challenging clinical condition

both for diagnosis and treatment. It can be extremely difficult to identify cause and site of bleeding using conventional diagnostic tools; the clinical introduction of capsule endoscopy and enteroscopy [single and double balloon enteroscopy (DBE)] represented a turning point in the localization, diagnosis and treatment of these lesions (6,7).

As reported by guidelines, small bowel video capsule endoscopy is the first-line investigation of OGIB. Therefore double-balloon enteroscopy, which might be combined with abdominal vascular enhanced computed tomography (CT) examination, is a simple and effective method for the diagnosis of intestinal vascular malformation bleeding (8).

While capsule endoscopy only allows preliminary diagnosis and localization of lesions, DBE consents detection and, in most cases, definitive treatment of small bowel conditions but it is also fundamental for biopsies and ink marking of non-endoscopically manageable lesions, such as ileal tumors or bleeding lesion refractory to endoscopic treatment (9).

There are few reports in literature of combined

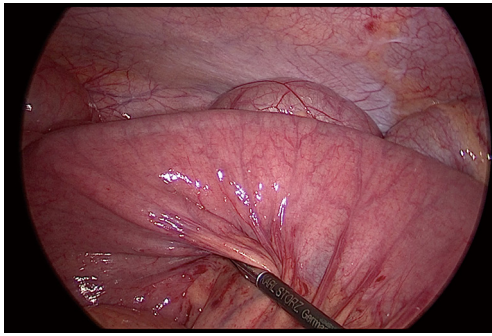


Figure 1 Antegrade double balloon enteroscopy performed with laparoscopic assistance.

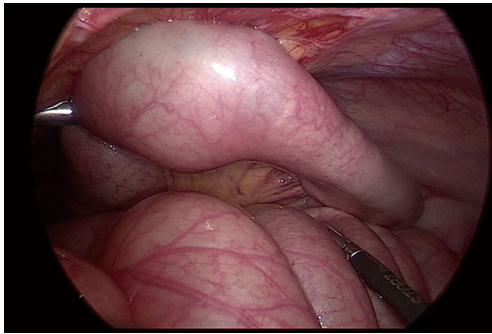


Figure 2 Small bowel loop attached to periumbilical abdominal wall area.

simultaneous DBE and minimally invasive surgery: we hereby present our experience with a case of OGIB from periumbilical varices infiltrating the ileum where laparoscopic surgical approach allowed the completion of small bowel enteroscopic exploration and therapeutic resection of the lesion.

We present the following case in accordance with the CARE reporting checklist (available at <http://dx.doi.org/10.21037/dmr-20-95>).

Case presentation

The patient is a 70-year-old-man with a medical history of type 2 diabetes, chronic kidney disease, chronic coronary artery disease and non-Hodgkin's lymphoma, who underwent endoscopic argon plasma coagulation due to gastric antral vascular ectasia syndrome. One month after this treatment, he was admitted to the Department of Gastroenterology of our Institution for abdominal pain onset associated with melena and anemia (Hb 7.0 g/dL).

After negative esophagogastroduodenoscopy and colonoscopy, a video capsule endoscopy was performed identifying a source of bleeding at the level of ileum (7 hours after ingestion). Moreover, during hospitalization, the patient was diagnosed with metabolic liver disease causing cirrhosis. The patient already developed portal hypertension with ascites and periumbilical varices. Preoperative red blood cells transfusions were administered.

The antegrade double balloon enteroscopy was performed assisted by laparoscopy (*Figure 1*). The diagnostic laparoscopy revealed the presence of a small bowel loop adherent to the periumbilical abdominal wall (*Figure 2*). The enteroscopy showed a non-bleeding varix inside the small bowel, resulting from a fistula of a periumbilical varix. Thus, the patient underwent laparotomy confirming the diagnosis. The varices connected to the small bowel loop were closed with sutures. The small bowel loop was resected and an ileo-ileal stapled anastomosis was performed. The post-operative course was uneventful and the patient was discharged on post-operative day 6. Pathological examination revealed vascular congestion and hemorrhage of muscular and subserosal layers. On follow-up visit the hemoglobin level was 9.5 g/dL and the cirrhosis was compensated without ascites. All procedures performed in studies involving human participants were in accordance with the ethical standards of the institutional and/or national research committee(s) and with the Declaration of Helsinki (as revised in 2013).

Discussion

This is a unique presentation of a small bowel bleeding due to a subcutaneous varix fistula diagnosed with double balloon enteroscopy assisted by laparoscopy and treated by small bowel resection. As reported by European Society of Gastrointestinal Endoscopy guidelines, small bowel video capsule endoscopy is the first-line investigation of OGIB. In case of positive findings at capsule endoscopy, device-assisted enteroscopy is recommended to confirm and possibly treat lesions (10).

In a review of the literature, we found nine papers describing obscure small bowel bleeding or non-bleeding lesion diagnosed and treated with balloon enteroscopy and laparoscopy. As aforementioned, enteroscopy and surgery can be used as running procedures or combined approaches.

Running procedures allow identification and possible tattoo of lesions through enteroscopy and subsequent bowel resection through minimally invasive or open surgery. Grgić

et al. reported two cases of small bowel hemangioma causing bleeding that were detected with single balloon enteroscopy and treated with bowel resection (11). The article of Ota *et al.* presents the case of a small intestinal submucosal tumor-like arterial malformation causing recurrent bleeding. The patient underwent endoscopic hemostasis and then surgical resection to solve the bleeding and confirm the diagnosis with pathology (12).

Iacob *et al.* reported a case of a patient with bleeding GI stromal tumor of the jejunum. Single balloon enteroscopy identified a submucosal tumor of distal jejunum that was marked with SPOT tattoo for a better intraoperative visualization. After endoscopy, the tattooed small bowel segment was easily identified and resected using minimally invasive laparoscopic surgery (13). In a paper of Uehara *et al.*, three patients with small intestinal bleeding underwent antegrade or retrograde DBE identifying the source of bleeding: arteriovenous malformation, malignant lymphoma, Meckel's diverticulum. After enteroscopy tattooing, single incision laparoscopic surgery with small bowel resection was performed in all cases (14). Likewise, Mori *et al.* described a case of a pediatric patient with small bowel angiodysplasia diagnosed and tattooed with DBE. One month later, a trans-umbilical single incision laparoscopic wedge resection was performed to remove the bleeding source (15). In a case series published by Yeh *et al.*, 34 patients underwent DBE due to OGIB or abdominal pain. Enteroscopy allowed diagnosis, biopsy, temporary hemostasis, ink mark. Then, laparoscopic bowel resection was performed as final treatment and open conversion was necessary in six cases. The authors conclude that combination of DBE and laparoscopic small bowel resection represents the ideal treatment for OGIB (16).

Notwithstanding, balloon enteroscopy can be demanding due to small bowel length and adhesions, resulting in incomplete endoscopy. Thus, laparoscopy can be used as a tool to assist the enteroscopy during diagnosis and treatment, allowing surgical bowel resection when endoscopic treatment is not feasible. We used this approach in the case report described. Likewise, Vargas *et al.* described the case of a patient suffering from Peutz-Jeghers syndrome with a non-bleeding hamartomatous polyp of the small bowel. The polyp was removed by a double balloon enteroscopy inserted through a jejunal enterotomy performed during laparoscopic surgery. At the end of the procedure, laparoscopy allowed to check lack of small bowel perforation (17).

The cases mentioned from literature review report diagnosis and treatment of bleeding or non-bleeding small bowel lesion for several causes, but no one was due to varix bleeding. Konishi *et al.* reported a case of idiopathic ileal varix diagnosed by capsule endoscopy and double balloon enteroscopy with tattoo and treated with laparoscopic small bowel resection (18). To date, to our knowledge, the case presented from our experience is the first one of subcutaneous varix fistula into the small bowel treated with combined balloon enteroscopic and laparoscopic approach.

Treatment of bleeding with the combined DBE and laparoscopic approach has been described also in emergency. A case report published by Chung *et al.*, present the history of a patient who underwent laparoscopic resection after emergent single balloon enteroscopic tattoo localization of a jejunal vascular malformation causing hypovolemic shock (19).

Laparoscopy plus DBE has advantages over laparotomy without DBE. First, the surgical incision is smaller in laparoscopic surgery than in laparotomy, reducing postoperative pain. Minimally invasive approach certainly needs to be performed by expert surgeons but first of all it is faster, safer, has better cosmetic outcomes, and is more cost-effective than laparotomy. Second, the use of laparoscopy in a targeted fashion diminished the need for thorough exploration and manipulation of the entire intestine like in those cases where intestinal targets were easily identified at initial laparoscopic examination based on the tattoo of lesions (15). Open surgery approach should still be adopted in those cases where laparoscopy is contraindicated or the patient presents in emergency condition (deep hypovolemia, haemodynamic shock).

Therefore, even if balloon enteroscopy is technically demanding it allows exploration of the entire small bowel with diagnosis and possible treatment. Laparoscopy can be used to facilitate diagnosis and treatment during endoscopic procedures or to treat the lesion during or after it.

Conclusions

This case of small bowel bleeding due to subcutaneous varix fistula confirm that diagnosis and treatment with combined DBE and laparoscopy is feasible and safe. According to literature, the enteroscopy and laparoscopy combined approach seems to be ideal in small bowel bleeding lesions due to accuracy, safety and cost effectiveness.

Acknowledgments

Funding: None.

Footnote

Reporting Checklist: The authors have completed the CARE reporting checklist. Available at <http://dx.doi.org/10.21037/dmr-20-95>

Conflicts of Interest: All authors have completed the ICMJE uniform disclosure form (available at <http://dx.doi.org/10.21037/dmr-20-95>). EC serves as the unpaid editorial board member of *Digestive Medicine Research* from March 2020 to February 2022. The other authors have no conflicts of interest to declare.

Ethical Statement: The authors are accountable for all aspects of the work in ensuring that questions related to the accuracy or integrity of any part of the work are appropriately investigated and resolved. All procedures performed in studies involving human participants were in accordance with the ethical standards of the institutional and/or national research committee(s) and with the Declaration of Helsinki (as revised in 2013). Written informed consent was obtained from the patient for publication of this Case report and any accompanying images.

Open Access Statement: This is an Open Access article distributed in accordance with the Creative Commons Attribution-NonCommercial-NoDerivs 4.0 International License (CC BY-NC-ND 4.0), which permits the non-commercial replication and distribution of the article with the strict proviso that no changes or edits are made and the original work is properly cited (including links to both the formal publication through the relevant DOI and the license). See: <https://creativecommons.org/licenses/by-nc-nd/4.0/>.

References

1. ASGE Standards of Practice Committee, Gurudu SR, Bruining DH, et al. The role of endoscopy in the management of suspected small-bowel bleeding. *Gastrointest Endosc* 2017;85:22-31.
2. Zuckerman GR, Prakash C, Askin MP, et al. AGA technical review on the evaluation and management of occult and obscure gastrointestinal bleeding. *Gastroenterology* 2000;118:201-21.
3. Gerson LB, Fidler JL, Cave DR, et al. ACG Clinical Guideline: Diagnosis and Management of Small Bowel Bleeding. *Am J Gastroenterol* 2015;110:1265-88.
4. Sakai E, Ohata K, Nakajima A, et al. Diagnosis and therapeutic strategies for small bowel vascular lesions. *World J Gastroenterol* 2019;25:2720-33.
5. Traina M, Tarantino I, Barresi L, et al. Variceal bleeding from ileum identified and treated by single balloon enteroscopy. *World J Gastroenterol* 2009;15:1904-5.
6. Yamamoto H, Kita H, Sunada K, et al. Clinical outcomes of double-balloon endoscopy for the diagnosis and treatment of small-intestinal diseases. *Clin Gastroenterol Hepatol* 2004;2:1010-6.
7. Kaffes AJ, Siah C, Koo JH. Clinical outcomes after double-balloon enteroscopy in patients with obscure GI bleeding and a positive capsule endoscopy. *Gastrointest Endosc* 2007;66:304-9.
8. Cui J, Huang LY, Wu CR. Small intestinal vascular malformation bleeding: diagnosis by double-balloon enteroscopy combined with abdominal contrast-enhanced CT examination. *Abdom Imaging* 2012;37:35-40.
9. Mönkemüller K, Weigt J, Treiber G, et al. Diagnostic and therapeutic impact of double-balloon enteroscopy. *Endoscopy* 2006;38:67-72.
10. Pennazio M, Spada C, Eliakim R, et al. Small-bowel capsule endoscopy and device-assisted enteroscopy for diagnosis and treatment of small-bowel disorders: European Society of Gastrointestinal Endoscopy (ESGE) Clinical Guideline. *Endoscopy* 2015;47:352-76.
11. Grgić D, Prijčić R, Romić I, et al. A Single Small Bowel Hemangioma Detected by Video Capsule Endoscopy in a Patient Presenting with Iron-deficiency Anemia - Two Case Reports. *Prague Med Rep* 2019;120:138-43.
12. Ota K, Noda J, Akutagawa H, et al. Massive Bleeding from a Small Intestinal Submucosal Tumor-like Arterial Malformation: An Unclassifiable Vascular Lesion Revealed by a Detailed Pathological Evaluation. *Intern Med* 2019;58:3521-3.
13. Iacob R, Dimitriu A, Stanciulea O, et al. Enteroscopic Tattooing for Better Intraoperative Localization of a Bleeding Jejunal GIST Facilitates Minimally Invasive Laparoscopically-assisted Surgery. *J Gastrointest Liver Dis* 2016;25:105-8.
14. Uehara K, Yoshioka Y, Ebata T, et al. Combination therapy with single incision laparoscopic surgery and double-balloon endoscopy for small intestinal bleeding: report of three cases. *Surg Today* 2013;43:1062-5.

15. Mori K, Koike Y, Inoue M, et al. Success of Minimally Invasive Transumbilical Single-Incision Laparoscopic Surgery (T-SILS) Plus Double-Balloon Endoscopy (DBE) for Pediatric Intestinal Angiodysplasia: A Case Report. *Int Surg* 2015;100:920-3.
16. Yeh TS, Liu KH, Su MY, et al. Laparoscopically assisted bowel surgery in an era of double-balloon enteroscopy: from inside to outside. *Surg Endosc* 2009;23:739-44.
17. Vargas RRD, Costa BVA, Moros G et al. A Case Report of Complete Intraoperative Double-balloon Enteroscopy Assisted by Laparoscopy to treat of Peutz-Jeghers Syndrome. *Rev Col Gastroenterol* 2014; 29(1):65-71.
18. Konishi H, Kikuchi S, Miyashita A, et al. Minimally invasive surgery for obscure idiopathic ileal varices diagnosed by capsule endoscopy and double balloon endoscopy: report of a case. *Surg Today* 2010;40:1088-92.
19. Chung CS, Chen KC, Chou YH, et al. Emergent single-balloon enteroscopy for overt bleeding of small intestinal vascular malformation. *World J Gastroenterol* 2018;24:157-60.

doi: 10.21037/dmr-20-95

Cite this article as: Cassinotti E, Boni L, Della Porta M, Elli L, Baldari L. Double balloon enteroscopy with laparoscopic assistance and surgical treatment of a subcutaneous varix fistula into the small bowel: case report and literature review. *Dig Med Res* 2020;3:68.