

Contents lists available at [ScienceDirect](https://www.sciencedirect.com)

## Resuscitation Plus

journal homepage: [www.elsevier.com/locate/resuscitation-plus](http://www.elsevier.com/locate/resuscitation-plus)

Experimental paper



## Detecting pneumothorax during cardiopulmonary resuscitation: The potential of defibrillator measured transthoracic impedance

Aurora Magliocca<sup>a</sup>, Donatella De Zani<sup>b</sup>, Giulia Merigo<sup>c</sup>, Marianna Cerrato<sup>d</sup>, Daria De Giorgio<sup>d</sup>, Francesca Motta<sup>d</sup>, Francesca Fumagalli<sup>d</sup>, Davide Zani<sup>b</sup>, Giacomo Grasselli<sup>a,e</sup>, Giuseppe Ristagno<sup>a,e,\*</sup>

<sup>a</sup> Department of Pathophysiology and Transplantation University of Milan, Italy

<sup>b</sup> Department of Veterinary Medicine and Animal Sciences, University of Milan, Lodi, Italy

<sup>c</sup> Department of Biomedical Sciences for Health, University of Milan, Italy

<sup>d</sup> Department of Acute Brain and Cardiovascular Injury, Istituto di Ricerche Farmacologiche Mario Negri, IRCCS, Milan, Italy

<sup>e</sup> Department of Anesthesiology Intensive Care and Emergency Fondazione IRCCS Ca' Granda Ospedale Maggiore Policlinico, Milan, Italy

### ABSTRACT

**Introduction:** Pneumothorax is a potentially life-threatening condition that can represent a complication of cardiopulmonary resuscitation (CPR). An increase in the total amount of air within the thorax may act as an insulator increasing transthoracic impedance (TTI). The aim of this study was to evaluate the effects of pneumothorax on TTI and on resuscitation success in a swine model of cardiac arrest (CA) and CPR.

**Methods:** Forty pigs undergoing CA and prolonged CPR, and with a chest CT scan performed after resuscitation were included in the study. Pneumothorax was classified as mild, moderate, or severe whether the space occupied by the gas was <15 %, 15–50 %, or >50 % of the hemithorax. TTI was measured and recorded by the defibrillator before each defibrillation, and the last one was used for the analyses. Rate of return of spontaneous circulation (ROSC) and survival up to 96 h were assessed.

**Results:** Seven (17%) animals had mild-moderate pneumothorax and 10 (25%) severe pneumothorax. Mean TTI was significantly higher in pigs with pneumothorax compared to those without. The rate of ROSC was significantly lower in pigs with pneumothorax compared to those without (53% vs 83%). TTI increased progressively with the size of pneumothorax (mean TTI: 55 Ω no pneumothorax, vs 62 Ω mild-moderate vs 66 Ω severe pneumothorax). Rib fractures were present in all animals with mild-moderate and severe pneumothorax, and in 91% of those without. The total number of rib fractures was significantly higher in animals with severe pneumothorax compared to those without pneumothorax.

**Conclusion:** Pneumothorax causes TTI increases which are proportional to the size of the pneumothorax and ultimately reduce resuscitation success. High prevalence of chest skeletal injuries was observed in this study regardless of the presence of pneumothorax with higher amount of rib fractures in animals with severe pneumothorax. TTI measured by defibrillator can be used to detect the presence of pneumothorax during CPR. Future studies should explore this concept of TTI as a diagnostic tool, in order to improve resuscitation outcome in patients with pneumothorax.

### Introduction

Pneumothorax is a potentially life-threatening condition due to accumulation of air in the pleural cavity causing lung collapse, and in the most severe cases obstruction to venous return and obstructive shock. It can develop spontaneously or be caused by trauma, severe asthma and other respiratory disease; rarely it can be a complication of cardiopulmonary resuscitation (CPR), associated with thoracic skeletal fractures<sup>1–3</sup>. Independently from its etiology, pneumothorax may significantly impede the effectiveness of resuscitative efforts<sup>2–4</sup>. During CPR, application of positive pressure ventilation can convert any pneumothorax

into a tension pneumothorax. Thus, immediate chest decompression when a tension pneumothorax is suspected in the presence of cardiac arrest (CA) takes priority over other interventions<sup>2,3</sup>. However, diagnosis of a pneumothorax during CPR is difficult, grounded only on patient's history before the event and on the presence of clinical and/or echographic signs, while chest X-ray or computer tomography (CT) imaging are usually deferred to the in-hospital post-resuscitation management<sup>2,4,5</sup>.

Transthoracic impedance (TTI) is one of the major factors affecting the success of defibrillation, representing the resistance of the thorax to the flow of electrical current delivered<sup>4,6,7</sup>. TTI is influenced by several

\* Corresponding author at: Department of Pathophysiology and Transplantation, University of Milan, Department of Anesthesiology, Intensive Care and Emergency, Fondazione IRCCS Ca' Granda Ospedale Maggiore Policlinico, Via Francesco Sforza 35, 20122, Milan, Italy.

E-mail address: [gristag@gmail.com](mailto:gristag@gmail.com) (G. Ristagno).

<https://doi.org/10.1016/j.resplu.2024.100801>

Received 31 July 2024; Received in revised form 30 September 2024; Accepted 3 October 2024

Available online 11 October 2024

2666-5204/© 2024 The Author(s). Published by Elsevier B.V. This is an open access article under the CC BY-NC license (<http://creativecommons.org/licenses/by-nc/4.0/>).

factors including electrode-to-skin contact, pad size and position, pathologies affecting lung volume, i.e. pulmonary edema and chronic obstructive pulmonary disease, as well as application of positive end-expiratory pressure (PEEP) <sup>7-11</sup>. Any increase in the total amount of air within the thorax i.e. in the presence of a large pneumothorax, may act as an insulator increasing TTI, and thus decreasing the chance of successful defibrillation <sup>7,10-14</sup>.

TTI changes associated with pneumothorax have not been studied yet, except for a few case reports on defibrillation thresholds with implantable cardioverter defibrillators <sup>12-14</sup>. Thus, the aim of this study was to evaluate the effects of pneumothorax on TTI and on return of spontaneous circulation (ROSC) in a swine model. Furthermore, we assessed whether TTI changes could be proportional to the size of the pneumothorax. The study was a retrospective secondary analysis of data from previous studies, where animals underwent chest CT scans following prolonged CPR <sup>15-17</sup>.

## Methods

All procedures involving animals, and their care conformed with national and international laws and policies. Approval of the studies was obtained from the institutional review board and governmental Institution (Ministry of Health approval no. 979/2017-PR, no. 461/2021-PR, no. n° 962/2023-PR). Animal facilities meet international standards and are regularly checked by a certified veterinarian responsible for health monitoring, animal welfare supervision, experimental protocols and review of procedures. This study followed Animal Research: Reporting of In Vivo Experiments (ARRIVE) guidelines.

### Animal preparation

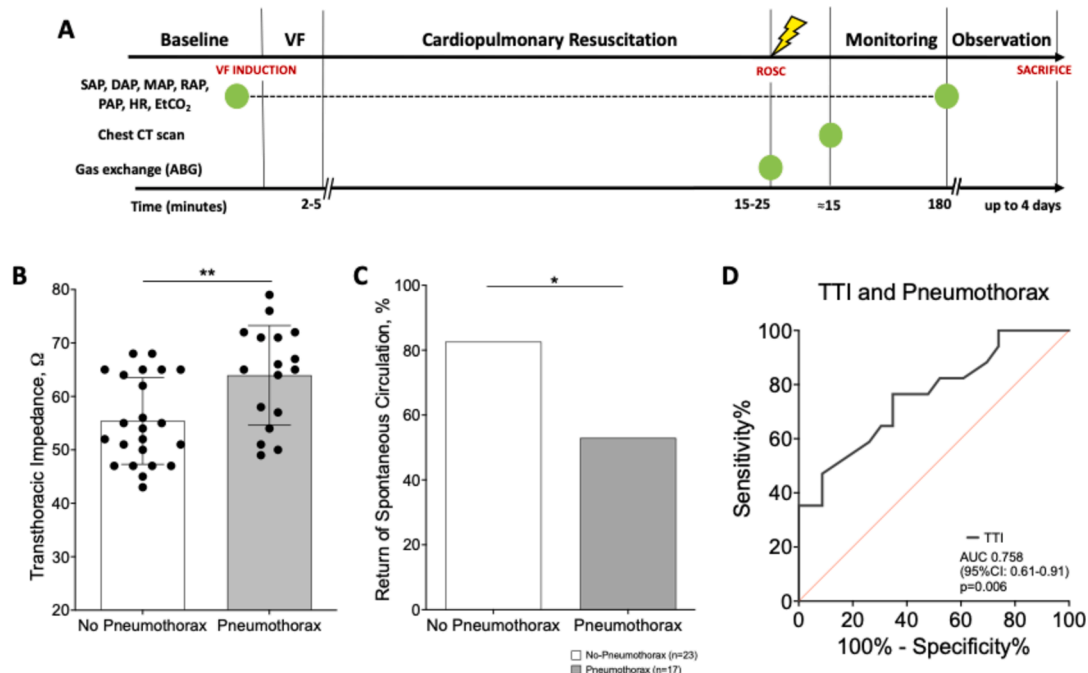
Forty male domestic swine ( $33 \pm 4$  kg) were fasted the night before the experiments, with free access to water. Anesthesia was induced by intramuscular injection of ketamine (20 mg/kg) followed by intravenous administration of propofol (2 mg/kg) and fentanyl (3  $\mu$ g/kg) through an ear vein access. Anesthesia was then maintained with a

continuous intravenous infusion of propofol (4–8 mg/kg/h). A cuffed endotracheal tube was placed, and animals were mechanically ventilated in volume-controlled mode with a tidal volume of 10 mL/kg, a fraction of inspired oxygen (FiO<sub>2</sub>) of 0.21, a positive-end expiratory pressure of 5 cmH<sub>2</sub>O, and a 1:E 1:2 (Bellavista 1000, IMT Medical, Switzerland). Respiratory rate was adjusted to maintain the end-tidal partial pressure of carbon dioxide (EtCO<sub>2</sub>) between 35 and 40 mmHg, using an infrared capnometer (X-Series defibrillator ZOLL Med. Corp. Chelmsford, MA, USA). To measure aortic pressure, a fluid-filled 7F catheter was advanced from the right femoral artery into the thoracic aorta. To measure right atrial and pulmonary artery pressure, core temperature, and cardiac output, a 7F pentalumens thermodilution catheter was advanced from the right femoral vein into the pulmonary artery. For inducing ventricular fibrillation (VF), a 5F pacing catheter was advanced from the right external jugular vein into the right ventricle. The position of all catheters was confirmed by characteristic pressure morphology and/or fluoroscopy. Frontal plane ECG was recorded.

### Experimental procedure

The timeline of the experiments is detailed in Fig. 1A.

VF was induced delivering 1–2 mA alternating current to the endocardium of the right ventricle <sup>15-17</sup>. Mechanical ventilation was discontinued after onset VF. After up to 5 min of untreated VF, continuous mechanical and manual chest compression (CC) was started and performed for up to 25 min, depending on the study design <sup>15-17</sup>. Simultaneously to CC, asynchronous ventilation with a FiO<sub>2</sub> of 1.0 and zero positive end-expiratory pressure (ZEEP) was started. Every 5 min during CPR, epinephrine (1 mg) was administered via the right atrium, while an arterial blood gas was obtained over the last 30 sec of the CPR interval, before the defibrillation attempt. Manual CC was provided in accordance with international CPR guidelines, as previously reported <sup>15-17</sup>. Mechanical CC was delivered by the LUCAS® 3.0 (Stryker/Jolife AB, Lund, Physio-Control, Sweden), which delivers continuous CC (rate:  $102 \pm 2$  per min; depth:  $53 \pm 2$  mm; duty cycle:  $50 \pm 5$  %). Defibrillation



**Fig. 1.** A. Experimental design. B. Transthoracic impedance in the presence or absence of pneumothorax. C. Rate of spontaneous circulation in the presence or absence of pneumothorax. D. Receiver operator characteristic curve for prediction of pneumothorax with the use of transthoracic impedance (TTI). ABG, arterial blood gas; AUC, area under the ROC curve; DAP, diastolic arterial pressure; EtCO<sub>2</sub>, end-tidal carbon dioxide; HR, heart rate; MAP, mean arterial pressure; RAP, right atrial pressure; ROSC, return of spontaneous circulation; SAP, systolic arterial pressure; VF, ventricular fibrillation. \*p < 0.05 \*\*p < 0.01 vs. No Pneumothorax.

was attempted with a single biphasic 150-Joule shock, using a X-Series defibrillator (ZOLL Med. Corp.). ROSC was defined as the presence of sinus rhythm with a mean arterial pressure (MAP) of more than 60 mmHg. If ROSC was not achieved, CPR was resumed and continued for 1 min prior to a subsequent defibrillation attempt. If VF reoccurred after ROSC, an immediate defibrillation was delivered. The same resuscitation protocol was continued until successful resuscitation or for a maximum of 5 additional min. After resuscitation, anesthesia was maintained, and animals were monitored for up to 3 hr prior to be weaned from the ventilator, returned into cage and observed up to 96 hr. No chest drainage was performed, even in the presence of severe pneumothorax. A chest CT was performed approximately 15 min after ROSC to evaluate the presence of pneumothorax, rib fractures and other major CPR-related lung injuries.

### Measurements

Hemodynamics, EtCO<sub>2</sub>, ECG were recorded continuously on a personal computer-based acquisition system (Labchart 8.0, Powerlab ADInstruments). The coronary perfusion pressure was computed from the differences in time-coincident diastolic aortic pressure and right atrial pressure. Blood gas analyses were assessed with i-STAT System (Abbott Laboratories, Princeton, NJ). TTI was measured and recorded by the defibrillator before each shock. TTI at the last defibrillation was used for the analyses. Animals with CPR-associated lung edema (CRALE) and/or other lung injuries than pneumothorax potentially increasing TTI (i.e. hemothorax) were excluded from the study.

### Chest CT scan and pneumothorax definition

Chest CT was performed with a 16-slices helical CT scanner (GE Brightspeed Elite®, GE Healthcare, Italy) using the following parameters: 1.25 slice thickness, tube current 180 mA, tube voltage 120 kV, scan speed 1 s/rotation, 1,375 pitch, 13,75 mm/rot. The images were reconstructed with a window setting for the evaluation of the lung parenchyma (level -500 HU; width: 1700 HU) and bone tissue (level: 600 HU; width: 3000 HU). Scans were performed during breath holding at end-expiration at 5 cmH<sub>2</sub>O, with subjects in dorsal recumbency and no contrast media was used. Identification of CRALE was performed by using previously described criteria, i.e. mean lung density  $\geq$  -500 Hounsfield Units (HU) <sup>15</sup>.

Pneumothorax was classified as mild, moderate, or severe whether the space occupied by the gas was <15 %, 15–50 %, or > 50 % of the hemithorax <sup>18</sup>. Tension pneumothorax was defined as the presence of mediastinal shift <sup>19</sup>.

### Statistical analyses

Continuous and categorical data were expressed as mean  $\pm$  SD, median [interquartile range] or frequency (percentage), as appropriate. Differences among groups were assessed with Chi-square test for categorical data or one-way ANOVA or Kruskal–Wallis, according to data distribution, for non-categorical data. Post-hoc multiple comparisons between groups were performed by controlling the false discovery rate using the two-stage step-up method of Benjamini. The discriminatory ability of TTI to identify the presence of pneumothorax was measured as area under the curve (AUC). A two-tailed p value < 0.05 was considered as statistically significant.

### Results

Forty animals were included in this study. Seven (17 %) animals had mild-moderate pneumothorax and 10 (25 %) severe pneumothorax, 3 of whom developed tension pneumothorax. No differences in body weight, no-flow and low-flow time, number of defibrillations and energy delivered were detected among pigs without pneumothorax and those with

mid-moderate or severe pneumothorax (Table 1). CPP did not differ among groups during CPR. Mean TTI was significantly higher in pigs with pneumothorax compared to those without pneumothorax (Fig. 1B). Accordingly, the rate of ROSC was significantly lower in pigs with pneumothorax compared to those without (53 % vs 83 %, Fig. 1C).

TTI paralleled the severity of pneumothorax, increasing from 55 O in the absence of pneumothorax to 62 and 66 O if a mild-moderate or severe pneumothorax was present, respectively (p = 0.004, Table 1). The AUC of the receiver operating characteristic curve of TTI for association with pneumothorax was 0.76 [0.61–0.91] (p = 0.006, Fig. 1D). ROSC rate followed the opposite trend, being halted from 83 % to 40 % in the presence of a severe pneumothorax (p = 0.014, Table 1). Arterial blood gas analysis showed no significant differences among groups, although there was a trend towards lower arterial oxygenation for larger pneumothoraxes (Table 1).

Data regarding the main chest wall injuries observed at CT scan are summarized in Table 2. Rib fractures were present in all animals with mild-moderate and severe pneumothorax, and in 91 % of those without. The total number of rib fractures was significantly higher in animals with severe pneumothorax compared to those without pneumothorax (p = 0.015, Table 2). No differences in the rib fracture characteristics were detected among the groups (Table 2).

Fig. 2 shows representative CT images in pigs without pneumothorax and with mild-moderate or severe pneumothorax. Fig. 3 reports CT images with corresponding TTI values in the 3 animals with tension pneumothorax.

### Discussion

This retrospective observational study in a porcine model of CPR suggests that pneumothorax is associated with TTI increases which are proportional to the size of the pneumothorax. Indeed, animals with

**Table 1**  
Resuscitation characteristics and arterial blood gases.

	No Pneumothorax n = 23	Mild-moderate Pneumothorax n = 7	Severe Pneumothorax n = 10	p value
<b>Body weight, kg</b>	34 $\pm$ 5	33 $\pm$ 6	32 $\pm$ 4	0.27
<b>No-Flow time, min</b>	2 [2 – 5]	5 [0 – 5]	5 [1 – 5]	0.96
<b>Low-Flow time, min</b>	18 [5 – 20]	20 [18 – 25]	18 [15 – 25]	0.25
<b>ROSC, n (%)</b>	19 (83)	5 (71)	4 (40)	0.01
<b>Survival, n (%)</b>	18 (95)	5 (100)	3 (75)	0.20
<b>Coronary perfusion pressure, mmHg</b>				
CPR 5 min	26 $\pm$ 9	32 $\pm$ 13	28 $\pm$ 13	0.47
CPR before defibrillation	28 $\pm$ 16	32 $\pm$ 16	26 $\pm$ 15	0.67
<b>Defibrillations to ROSC, n</b>	2 [1 – 4]	1 [1 – 3]	4 [1 – 9]	0.16
<b>Energy delivered, Joule</b>	242 [200 – 300]	244 [29 – 251]	241 [194 – 244]	0.66
<b>TTI, ohm</b>	55 $\pm$ 8	62 $\pm$ 12	66 $\pm$ 7*	0.01
<b>Arterial blood gas analysis before defibrillation</b>				
<b>pH</b>	7.324 $\pm$ 0.209	7.209 $\pm$ 0.101	7.212 $\pm$ 0.193	0.22
<b>PaCO<sub>2</sub>, mmHg</b>	40 $\pm$ 22	44 $\pm$ 17	48 $\pm$ 30	0.70
<b>PaO<sub>2</sub>/FiO<sub>2</sub></b>	205 [74 – 352]	105 [72 – 170]	81 [60 – 385]	0.73
<b>SaO<sub>2</sub>, %</b>	100 [88 – 100]	96 [88 – 99]	91 [80 – 100]	0.52
<b>HCO<sub>3</sub>, mmol/L</b>	17 $\pm$ 5	17 $\pm$ 5	17 $\pm$ 6	0.97
<b>BE, mmol/L</b>	-10 $\pm$ 4	-10 $\pm$ 5	-10 $\pm$ 6	0.99
<b>Lactate, mmol/L</b>	8 $\pm$ 2	8 $\pm$ 1	8 $\pm$ 2	0.89

BE, base excess; CPR, cardiopulmonary resuscitation; HCO<sub>3</sub>, bicarbonate; PaCO<sub>2</sub>, carbon dioxide partial pressure; PaO<sub>2</sub>/FiO<sub>2</sub>, oxygen partial pressure/oxygen inspired fraction; ROSC, return of spontaneous circulation; SaO<sub>2</sub>, arterial oxygen saturation; TTI, transthoracic impedance. Data are expressed as mean  $\pm$  SD or median [IQR].

\*p < 0.05 Severe Pneumothorax vs. No Pneumothorax.

**Table 2**  
Chest wall injuries after cardiopulmonary resuscitation.

	No Pneumothorax n = 23	Mild-moderate Pneumothorax n = 7	Severe Pneumothorax n = 10	p value
<b>Animals with rib fractures, n (%)</b>				
Total	21 (91)	7 (100)	10/10 (100)	0.34
Incomplete	20 (87)	7 (100)	10/10 (100)	0.23
Complete	20 (87)	7/7 (100)	10/10 (100)	0.23
compound				
Complete	8/23 (35)	0/7 (0)	4/10 (40)	0.77
dislodged				
Sternocostal	4/23 (17)	1/7 (14)	1/10 (10)	0.59
Dislocation				
<b>Rib fractures, n</b>				
Total	4 [4 – 6]	6 [5 – 6]	6 [6 – 8] *	0.05
Right chest	0 [0 – 0]	1 [0 – 5]	0 [0 – 3]	0.33
Left chest	4 [3 – 5]	3 [1 – 6]	6 [5 – 6]	0.06

\*p < 0.05, Severe Pneumothorax vs. No Pneumothorax.

larger pneumothoraxes had significantly higher TTI values and lower rates of ROSC. This study also documents that TTI measured by a defibrillator might be used to detect the presence of pneumothorax during CPR.

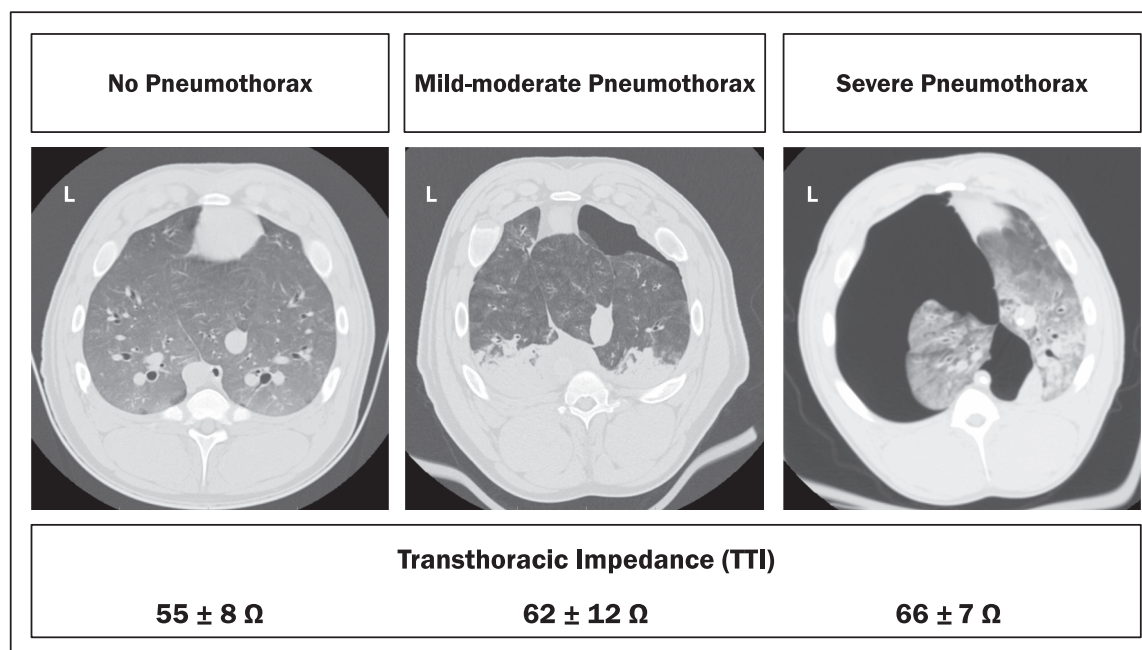
The mechanism by which pneumothorax increases TTI is likely due to the augmented air volume within the thorax which increases the resistance to current flow through the chest during defibrillation, ultimately acting as an insulator<sup>10,11</sup>. The absence of any direct impact of pneumothorax on oxygenation, CO<sub>2</sub> clearance or systemic perfusion, as shown by the arterial blood gas analyses and lactate levels, further supports this hypothesis.

Tension pneumothorax is associated with a progressive reduction in preload and cardiac output, causing severe hemodynamic instability and ultimately pulseless electrical activity (PEA) or asystole<sup>1,4,20</sup>. Although the same mechanism can occur during CPR, in our experiments systemic perfusion was not influenced by pneumothorax, as in no animal the cardiac rhythm deteriorated into PEA or asystole, while lactate levels

remained similar in the three groups. From the chest CT scan analyses, only 3 animals in our study developed tension pneumothorax during CPR, and they all presented high TTI value at the end of CPR. However, the exact moment when the pneumothorax occurred during CPR and how fast it evolved in the most severe cases, is unknown. Ideally, a continuous TTI measurement from the baseline throughout the whole CPR interval would have allowed to identify changes in its value when a pneumothorax occurred and evolved.

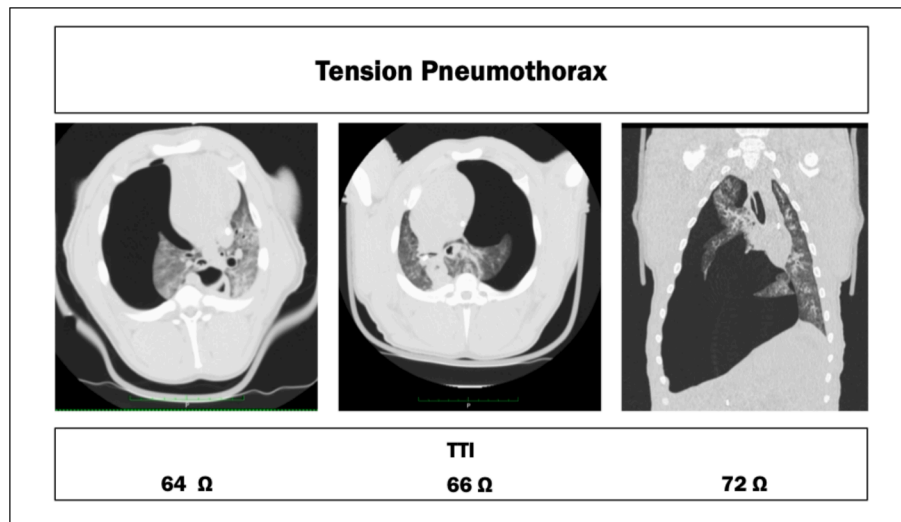
Rib fractures are the most common chest compression-induced complication, but they are rarely associated with life-threatening conditions<sup>3,21</sup>. High prevalence of chest skeletal injuries was observed in this study regardless of the presence of pneumothorax. Indeed, all animals subjected to 20–25 min of continuous chest compressions sustained multiple rib fractures. On average, each animal had 4–6 fractures, with most being complete fractures. The frequency, type, and location of these fractures were consistent with those observed in other porcine CPR studies<sup>21–24</sup>. Animals with severe pneumothorax experienced a higher number of rib fractures, suggesting that these CPR-related chest wall injuries may represent a mechanism of pneumothorax development<sup>3,25</sup>. However, other factor potentially accounting for pneumothorax cannot be excluded, such as excessive airway pressures due to repetitive compression downstrokes occurring during the inspiratory phase of unsynchronized ventilations, or CPR-generated tracheal or bronchial lacerations and traumatic bullae<sup>3,26</sup>. The rate of pneumothorax observed in our animal was also comparable to that reported in other swine studies in which a post-CPR chest CT was performed<sup>22–24</sup>. Thus, two recent studies investigating different ventilation strategies during prolonged mechanical compression in a similar porcine model reported pneumothorax rates of 37–39 %, with a higher incidence of severe pneumothorax after continuous compression<sup>22,24</sup>. Liu et al.<sup>23</sup> previously reported a pneumothorax rate of 17 % after just 6 min of manual CPR in their porcine model.

While pigs are commonly used for CPR research, their thoracic anatomy differs significantly from humans. Human chest is more flattened antero-posteriorly, while porcine chest is more barrel-shaped<sup>22,24,27</sup>. Additionally, porcine chest viscosity is higher during CPR, which, combined with the distinct sternum structure, may predispose pigs to more skeletal injuries during chest compressions<sup>27</sup>. Despite these



**Fig. 2.** Representative computed tomographic images of caudal lung lobes with no, mild-moderate and severe pneumothorax. Transthoracic impedance for each group is detailed below as mean ± SD. L = left lung side.

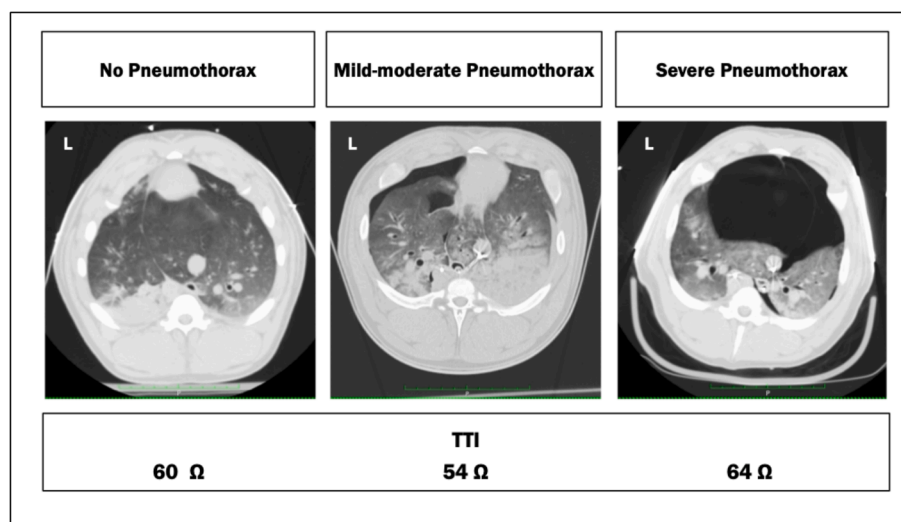




**Fig. 3.** Representative computed tomographic images of lung lobes from the three animals with tension pneumothorax. Transthoracic impedance (TTI) for each animal is reported below.

anatomical differences, human and porcine CPR-related injuries are surprisingly similar <sup>22-24,27-30</sup>. Indeed, rib fractures during CPR are common in humans, with percentages that resemble those reported in pigs, i.e. up to 95 % of patients, with an average of 5 fractures per patient, with majority located antero-laterally <sup>3,28-30</sup>. CPR-specific variables like duration of CPR, depth of compression, and use of mechanical chest compression devices can increase the likelihood of skeletal and lung injuries, in both humans and pigs <sup>3,25,27</sup>. Moreover, pneumothorax rates following CPR are also comparable between the two species, ranging from 2.5 to 26 % in humans and even higher in some cases, especially when CT scan is used for diagnosis <sup>3,28</sup>. Data from the Parisian registry of out-of-hospital CAs, showed that among CPR-related injuries, pneumothorax was present in 46 % of patients <sup>31</sup>. Finally, in our model, pneumothorax development resulted in an air distribution pattern like that seen in humans, with the initial air collection occurring ventrally and expanding to the entire hemithorax in severe cases. Nevertheless, while the porcine model provides valuable insights, it is essential to consider the above anatomical differences, particularly when evaluating data related to TTI in relationship to pad placement on the chest and defibrillation efficacy <sup>32-34</sup>.

Since pneumothorax is potentially reversible, having the possibility to promptly detect it, when suspected during CPR, is crucial to allow for an immediate decompression, enhancing the chances of successful defibrillation <sup>1,2,4</sup>. TTI is potentially available during any resuscitation event, with defibrillators already routinely measuring it before each defibrillation, by sending an alternating current between the pads and sensing the voltage generated when this current flows through the chest <sup>3,4,8</sup>. This study demonstrated that changes in TTI measured by the defibrillator were indicative of the presence and severity of pneumothorax. However, due to the retrospective study design, TTI was assessed only when a defibrillation was delivered at the end of the CPR with no earlier reference values without pneumothorax. Continuous TTI monitoring during CPR would have enabled more timely pneumothorax identification and adjustment of TTI values for a reference basal value in each animal. This would have reduced data variability and prevented overlapping results between group, such as high TTI in animals without pneumothorax or low TTI in animals with pneumothorax, as reported in Fig. 4. Nevertheless, the results were consistent among all the animals with and without pneumothorax as well as with the extent of air accumulation, and the ROC analysis supports the association between TTI



**Fig. 4.** Representative computed tomographic images of caudal lung lobes from animals with no and mild to severe pneumothorax but high and low transthoracic impedance (TTI) values respectively. L = left lung side.

and pneumothorax, with an AUC of 0.76. This new potential use of TTI for diagnostic purposes has the advantage to be an easy, non-invasive, and in real-time measurement performed without additional instrumentation by software implementation in existing defibrillators in order to have TTI measured more frequently or continuously during CPR (not only at the time of defibrillation attempt). Future studies are needed to explore this concept of TTI as a diagnostic tool, in order to improve resuscitation outcomes in patients who develop pneumothorax during CPR.

There are several limitations to be considered in the interpretation of our findings. First, this retrospective study analyzed data from previous experiments, where pneumothorax frequently occurred during prolonged CPR and a chest CT was performed<sup>15–17</sup>. While, we did not induce a controlled pneumothorax, we evaluated its absence or presence and eventually its severity. Second, we did not assess TTI continuously, but we retrieved the value measured by the defibrillator before each defibrillation, limiting our ability to track its evolution over time. To address this issue, we analyzed the last TTI before the final defibrillation attempt, assuming it reflected the condition observed at the subsequent chest CT. In addition, we attempted to minimize biases related to other conditions affecting TTI, i.e. lung edema, by excluding animals with CRALE and hemothorax<sup>15</sup>. However, other factors potentially like atelectasis, auto-PEEP, and circulating blood volume, could have influenced lung volume and TTI<sup>3,7</sup>. Nevertheless, the consistency of our experimental model suggests that these factors were likely evenly distributed among the subject. Third, we employed a model of VF CA, although pneumothorax is more commonly associated with non-shockable CA<sup>1,4</sup>. However, the primary objective was to investigate TTI capability to identify a pneumothorax during CPR, regardless of CA type. Future defibrillators with continuous TTI measurement and display capabilities could extend this approach to non-shockable CAs. It is important to note that this method is applicable only with pads but not paddles, as a consistent electrode/skin contact is essential for accurate TTI measurement<sup>7</sup>. Finally, future prospective studies, with controlled induction of pneumothorax with varying severity, concurrent continuous TTI monitoring, and evaluation in relation to different chest sizes and pad positions<sup>32,33</sup> are needed to validate this method hence anticipated.

#### Fundings

This study was funded in part by the “Re-Starting Grant 2023”, University of Milan to AM and in part by Italian Ministry of Health-Current research IRCCS.

#### CRedit authorship contribution statement

**Aurora Magliocca:** Writing – original draft, Methodology, Investigation, Formal analysis, Data curation, Conceptualization. **Donatella De Zani:** Writing – review & editing, Investigation, Data curation. **Giulia Merigo:** Writing – review & editing, Investigation, Data curation. **Marianna Cerrato:** Investigation, Data curation. **Daria De Giorgio:** Investigation, Data curation. **Francesca Motta:** Investigation, Data curation. **Francesca Fumagalli:** Investigation, Data curation. **Davide Zani:** . **Giacomo Grasselli:** Writing – review & editing, Funding acquisition. **Giuseppe Ristagno:** Writing – review & editing, Writing – original draft, Supervision, Methodology, Investigation, Funding acquisition, Data curation.

#### Declaration of competing interest

The authors declare that they have no known competing financial interests or personal relationships that could have appeared to influence the work reported in this paper.

#### References

- [1]. Lott C, Truhlár A. Cardiac arrest in special circumstances. *Curr Opin Crit Care*. 2021 Dec 1;27(6):642–648.

- [2]. Lott C, Truhlár A, Alfonso A, Barelli A, González-Salvado V, Hinkelbein J, Nolan JP, Paal P, Perkins GD, Thies KC, Yeung J, Zideman DA, Soar J; ERC Special Circumstances Writing Group Collaborators. European Resuscitation Council Guidelines 2021: Cardiac arrest in special circumstances. *Resuscitation*. 2021 Apr; 161:152-219. doi: 10.1016/j.resuscitation.2021.02.011.
- [3]. Marchese G, Bungaro E, Magliocca A, et al. Acute Lung Injury after Cardiopulmonary Resuscitation: A Narrative Review. *J Clin Med*. 2024 Apr 24;13(9):2498.
- [4]. Soar J, Böttiger BW, Carli P, et al. European Resuscitation Council Guidelines 2021: Adult advanced life support. *Resuscitation*. 2021 Apr;161:115–151. <https://doi.org/10.1016/j.resuscitation.2021.02.010>.
- [5]. Zaidi HQ, Li S, Beiser DG, Tataris KL, Sharp WW. The utility of computed tomography to evaluate thoracic complications after cardiopulmonary resuscitation. *Resusc Plus*. 2020 Aug;7(3), 100017.
- [6]. Magliocca A, Castagna V, Fornari C, et al. Transthoracic impedance variability to assess quality of chest compression in out-of-hospital cardiac arrest. *Acta Anaesthesiol Scand*. 2024 Apr;68(4):556–566. <https://doi.org/10.1111/aas.14374>.
- [7]. Deakin CD, McLaren RM, Petley GW, Clewlow F, Dalrymple-Hay MJ. A comparison of transthoracic impedance using standard defibrillation paddles and self-adhesive defibrillation pads. *Resuscitation*. 1998 Oct-Nov;39(1-2):43-6. doi: 10.1016/s0300-9572(98)00117-8.
- [8]. Chen B, Yin C, Ristagno G, et al. Retrospective evaluation of current-based impedance compensation defibrillation in out-of-hospital cardiac arrest. *Resuscitation*. 2013 May;84(5):580–585.
- [9]. Dalzell GW, Cunningham SR, Anderson J, Adgey AA. Electrode pad size, transthoracic impedance and success of external ventricular defibrillation. *Am J Cardiol*. 1989 Oct 1;64(12):741–744. [https://doi.org/10.1016/0002-9149\(89\)90757-1](https://doi.org/10.1016/0002-9149(89)90757-1).
- [10]. Deakin CD, McLaren RM, Petley GW, Clewlow F, Dalrymple-Hay MJ. Effects of positive end-expiratory pressure on transthoracic impedance—implications for defibrillation. *Resuscitation*. 1998 Apr;37(1):9–12. [https://doi.org/10.1016/s0300-9572\(98\)00049-5](https://doi.org/10.1016/s0300-9572(98)00049-5).
- [11]. Heyer Y, Baumgartner D, Baumgartner C. A Systematic Review of the Transthoracic Impedance during Cardiac Defibrillation. *Sensors (base)*. 2022 Apr 6;22(7):2808.
- [12]. Cohen TJ, Lowenkron DD. The effects of pneumothorax on defibrillation thresholds during pectoral implantation of an active can implantable cardioverter defibrillator. *Pacing Clin Electrophysiol*. 1998 Feb;21(2):468–470. <https://doi.org/10.1111/j.1540-8159.1998.tb00075.x>.
- [13]. Ul Haq E, Omar B. Traumatic Tension Pneumothorax as a Cause of ICD Failure: A Case Report and Review of the Literature. *Case Rep Cardiol*. 2014;2014, 261705. <https://doi.org/10.1155/2014/261705>.
- [14]. Hatton KW, Kilinski LC, Ramaiah C, Schell RM. Multiple failed external defibrillation attempts during robot-assisted internal mammary harvest for myocardial revascularization. *Anesth Analg*. 2006 Nov;103(5):1113–1114. <https://doi.org/10.1213/01.ane.0000239242.69740.93>.
- [15]. Magliocca A, Rezoagli E, Zani D, et al. Cardiopulmonary Resuscitation-associated Lung Edema (CRALE). *A Translational Study. Am J Respir Crit Care Med*. 2021 Feb 15;203(4):447–457. <https://doi.org/10.1164/rccm.201912-2454OC>. PMID: 32897758.
- [16]. Magliocca A, Olivari D, De Giorgio D, et al. LUCAS Versus Manual Chest Compression During Ambulance Transport: A Hemodynamic Study in a Porcine Model of Cardiac Arrest. *J Am Heart Assoc*. 2019;8(1):e011189.
- [17]. Magliocca A, Castagna V, Fumagalli F, Olivari D, De Giorgio D, Ristagno G, OR26 Effects of no-flow time on the pathophysiology of Cardiopulmonary resuscitation-associated lung edema (CRALE) in a porcine model of cardiac arrest, *Resuscitation*, Volume 175, Supplement 1, 2022, Pages S24-S25, ISSN 0300-9572, [https://doi.org/10.1016/s0300-9572\(22\)00408-7](https://doi.org/10.1016/s0300-9572(22)00408-7).
- [18]. Baudin Tréhiou C, Gibert S, Sériot P, Dunié-Mérogot A, Blond L. CT is helpful for the detection and presurgical planning of lung perforation in dogs with spontaneous pneumothorax induced by grass awn migration: 22 cases. *Vet Radiol Ultrasound*. 2020 Mar;61(2):157–166. <https://doi.org/10.1111/vru.12831>.
- [19]. Leigh-Smith S, Harris T. Tension pneumothorax—time for a re-think? *Emerg Med J*. 2005 Jan;22(1):8–16. <https://doi.org/10.1136/emj.2003.010421>.
- [20]. Nelson D, Porta C, Satterly S, et al. Physiology and cardiovascular effect of severe tension pneumothorax in a porcine model. *J Surg Res*. 2013 Sep;184(1):450–457. <https://doi.org/10.1016/j.jss.2013.05.057>.
- [21]. Magliocca A, Manfredi M, Olivari D, De Giorgio D, Cucino A, Zani DD, Ristagno G. High quality chest compression: Don't be afraid of breaking ribs to gain a life!. *Heart Lung*. 2019;48(2):173–174. <https://doi.org/10.1016/j.hrtlung.2018.12.004>.
- [22]. Kopra J, Litonius E, Pekkarinen PT, et al. Ventilation during continuous compressions or at 30:2 compression-to-ventilation ratio results in similar arterial oxygen and carbon dioxide levels in an experimental model of prolonged cardiac arrest. *Intensive Care Med Exp*. 2023 Jan 6;11(1):3. <https://doi.org/10.1186/s40635-022-00485-0>.
- [23]. Liu Z, Liu Q, Wu G, et al. Quantitative CT assessment of lung injury after successful cardiopulmonary resuscitation in a porcine cardiac arrest model of different downtimes. *Quant Imaging Med Surg*. 2018 Oct;8(9):946–956. <https://doi.org/10.21037/qims.2018.10.04>.
- [24]. Kopra J, Litonius E, Pekkarinen PT, et al. Oxygenation and ventilation during prolonged experimental cardiopulmonary resuscitation with either continuous or 30:2 compression-to-ventilation ratios together with 10 cm H2O positive end-expiratory pressure. *Intensive Care Med Exp*. 2024 Apr 12;12(1):36. <https://doi.org/10.1186/s40635-024-00620-z>.

- [25]. Kashiwagi Y, Sasakawa T, Tampo A, et al. Computed tomography findings of complications resulting from cardiopulmonary resuscitation. *Resuscitation*. 2015 Mar;88:86–91. <https://doi.org/10.1016/j.resuscitation.2014.12.022>.
- [26]. Olasveengen TM, Skåre C, Skjerven-Martinsen M, et al. Lung tissue injury and hemodynamic effects of ventilations synchronized or unsynchronized to continuous chest compressions in a porcine cardiac arrest model. *Resusc plus*. 2023 Dec;20(17), 100530. <https://doi.org/10.1016/j.resplu.2023.100530>.
- [27]. Neurauter A, Nysaether J, Kramer-Johansen J, et al. Comparison of mechanical characteristics of the human and porcine chest during cardiopulmonary resuscitation. *Resuscitation*. 2009 Apr;80(4):463–469. <https://doi.org/10.1016/j.resuscitation.2008.12.014>.
- [28]. Auinger D, Hötzer D, Zajic P, et al. Post-resuscitation pneumothorax: retrospective analysis of incidence, risk factors and outcome-relevance. *Scand J Trauma Resusc Emerg Med*. 2024 Sep 5;32(1):82. <https://doi.org/10.1186/s13049-024-01260-8>.
- [29]. Karatasakis A, Sarikaya B, Liu L, et al. Prevalence and Patterns of Resuscitation-Associated Injury Detected by Head-to-Pelvis Computed Tomography After Successful Out-of-Hospital Cardiac Arrest Resuscitation. *J Am Heart Assoc*. 2022; 11(3):e023949.
- [30]. Boland LL, Satterlee PA, Hokanson JS, Strauss CE, Yost D. Chest Compression Injuries Detected via Routine Post-arrest Care in Patients Who Survive to Admission after Out-of-hospital Cardiac Arrest. *Prehosp Emerg Care*. 2015;19(1): 23–30. <https://doi.org/10.3109/10903127.2014.936636>.
- [31]. Champigneulle B, Haruel PA, Pirracchio R, et al. Major traumatic complications after out-of-hospital cardiac arrest: Insights from the Parisian registry. *Resuscitation*. 2018 Jul;128:70–75. <https://doi.org/10.1016/j.resuscitation.2018.04.022>.
- [32]. Ristagno G, Yu T, Quan W, Freeman G, Li Y. Comparison of defibrillation efficacy between two pads placements in a pediatric porcine model of cardiac arrest. *Resuscitation*. 2012 Jun;83(6):755–759. <https://doi.org/10.1016/j.resuscitation.2011.12.010>.
- [33]. Cheskes S, Drennan IR, Turner L, Pandit SV, Dorian P. The impact of alternate defibrillation strategies on shock-refractory and recurrent ventricular fibrillation: A secondary analysis of the DOSE VF cluster randomized controlled trial. *Resuscitation*. 2024 May;198, 110186.
- [34]. Dodd TE, Deakin CD, Petley GW, Clewlow F. External defibrillation in the left lateral position—a comparison of manual paddles with self-adhesive pads. *Resuscitation*. 2004 Dec;63(3):283–286. <https://doi.org/10.1016/j.resuscitation.2004.06.002>.