

Spinal disorders and mastication: The potential relationship between adolescent idiopathic scoliosis and alterations of the chewing patterns

Maria Grazia Piacino¹ | Alessandro Tortarolo¹ | Francesco Macdonald² |
Umberto Garagiola³ | Ludovica Nucci⁴ | Marco Brayda-Bruno⁵

¹Division of Orthodontics, Department of Surgical Sciences, Dental School C.I.R., University of Turin, Turin, Italy

²Orthopedic Surgical Institute Maria Adelaide, Turin, Italy

³Department of Biomedical Sciences, University of Milan, Milan, Italy

⁴Department of Surgical Sciences and Dental Specialties, University of Campania Luigi Vanvitelli, Naples, Italy

⁵Spine Surgery III Scoliosis Department, IRCCS Orthopedic Institute Galeazzi, Milan, Italy

Correspondence

Maria Grazia Piacino, Department of Surgical Sciences, Dental School C.I.R., Division of Orthodontics, University of Turin, Turin, Italy.
Email: mariagrazia.piacino@unito.it

Funding information

Ministero dell'Istruzione, dell'Università e della Ricerca

Abstract

Objective: To evaluate mastication in a group of patients with adolescent idiopathic scoliosis (AIS) with a control group, by means of the prevalence of reverse chewing cycles (RCCs).

Material and Methods: This study included a group of patients (N = 32; F = 24; M = 8; mean age \pm SD = 14 \pm 3 years) with a confirmed diagnosis of AIS and a group of control subjects (N = 32; F = 24; M = 8; mean age \pm SD = 13 \pm 6 years) without spinal disorders. Mastication was recorded with both a hard and a soft bolus, following a standardized protocol, and the prevalence of RCCs was compared between the groups.

Results: The prevalence of RCCs was significantly higher in the AIS group, with both a soft and a hard bolus, compared to the control group ($P < .001$).

Conclusion: The results of this study indicate that the presence of AIS influences mastication, one of the main functions of the stomatognathic system. A multidisciplinary approach to these patients may be relevant in providing the best possible treatment outcomes.

KEYWORDS

adolescent idiopathic scoliosis, chewing cycles, malocclusion, mastication, spinal disorders

1 | INTRODUCTION

Mastication is one of the most important functions of the stomatognathic system.¹ It is a highly coordinated neuromuscular movement with continuous modulation and adaptation to bolus volume and consistency.² Masticatory jaw movements are adjusted by the receptors of the stomatognathic system, especially mechanoreceptors and muscle spindles.^{2,3}

The rhythmic chewing pattern in humans is not the simple outcome of reflex, isolated mandibular movements, but rather the

outcome of concomitant mandibular and head-neck movements⁴; jaw opening is paralleled by head-neck extension and jaw closing by head-neck flexion. Well-coordinated and task-specific neck movements seem to optimize the execution of jaw actions, which is further underlined by the finding that head extension can increase the stability of mandibular closing movements.⁵ The size and the texture of bolus can modulate not only the mandibular movement pattern, but also that of the head/neck complex.⁶ In fact, boluses of larger size and harder texture are associated with larger amplitudes of both mandibular and head/neck movement, with a proportional

This is an open access article under the terms of the [Creative Commons Attribution](https://creativecommons.org/licenses/by/4.0/) License, which permits use, distribution and reproduction in any medium, provided the original work is properly cited.

© 2022 The Authors. *Orthodontics & Craniofacial Research* published by John Wiley & Sons Ltd.



recruitment of neck muscles in response to increased chewing load.⁵

There is an increasing interest in the relationship between occlusion and spine pathology, as a greater incidence of pain related to masticatory muscles, neck, trunk, upper and lower limbs, as well as the temporomandibular joints, has been described in adult patients with occlusal dysfunction.^{6,7} At present, malocclusion is largely addressed in the course of development and especially during adolescence, when some pathologies of the spinal column manifest for the first time.^{8,9} Different conditions interfere with normal trunk alignment in the frontal plane, and it is of clinical interest to investigate their influence on dental occlusion.^{10,11} One such condition is idiopathic scoliosis, a deformity without a clear aetiology,¹² classified in 3 types according to the age at presentation: infantile (from birth to 3 years), juvenile (from 3 to 10 years) and adolescent (from 10 years to skeletal maturity).^{13,14} The most common infantile curves present in the first 6 months of life are frequently left thoracic apex, with males more frequently affected, whereas the most common juvenile curves are right thoracic apex with females more frequently affected, as it happens in the adolescent group. In the case of the most common form of scoliosis, that is adolescent idiopathic scoliosis (AIS), there is no clear causal agent and it is generally believed to be multifactorial. AIS represents 80% of all scoliosis patients and has a well-established prevalence of 1.5%.¹⁵ AIS is defined by the Scoliosis Research Society (SRS) as a spinal deformity of unknown aetiology with a coronal Cobb angle $>10^\circ$ occurring in a child over the age of 10 whose skeleton is still developing.¹⁶ AIS occurs frequently in teenage patients that are most often referred for consultation both because of incorrect body posture and malocclusions.

Some studies evaluating the relationship between malocclusion and scoliosis described an increased prevalence of unilateral Angle Class II malocclusion,¹⁷ an increased risk of crossbite¹⁵ and left-right occlusal asymmetries¹⁸; however, there was no agreement between the studies.¹⁹ A recent systematic review concluded that there was no clear evidence of a causal relationship between spinal deformities and malocclusion and underlined the limited quality of the evidence available to support it.²⁰ Nevertheless, even though the results are not directly translatable to humans, three animal studies²¹⁻²³ showed the role of induced malocclusion on the irreversible degeneration of the spine, manifesting as scoliotic curves. Moreover, the demonstration of possible associations of standard orthodontic therapies, such as rapid palatal expansion, on the worsening of scoliotic curves casts a shadow of concern that requires objective scientific clarification.²⁴ This disagreement might be due to the complexity of the system and to the great capacity for compensation in the three planes of space, that result in a variety of different responses and occlusal assessment.

Interestingly, a previous study showed that spinal curvatures affect the anatomical, biomechanical and kinesiological features of the masticatory system, and individuals with AIS may experience more chewing problems than asymptomatic individuals.²⁵ Based on this result and on the synergistic coordination between the masticatory and neck muscles during chewing, this study aims at evaluating the

potential influence of AIS on the masticatory function. The null hypothesis (H0) is that there is no difference in mastication between subjects with AIS and control subjects.

2 | MATERIALS AND METHOD

Before entering the study, informed consent was obtained from all parents or legal guardians. This study was conducted in accord with the Declaration of Helsinki. The study was conducted with the approval of the Institutional Review Board of the University Hospital Company—Turin—Italy, n° 764/2014, 23rd July 2014. Subjects with AIS were selected among patients referred by two orthopaedic surgeons to the Division of Orthodontics, University of Turin, Italy, with the following inclusion criteria: (1) a confirmed diagnosis of AIS, (2) regular follow-up by an orthopaedic surgeon, (3) no history of previous orthodontic treatment and of temporomandibular disease (TMD), (4) absence of crossbite. The exclusion of patients with crossbite (which is the malocclusion correlated to a high percentage of reverse chewing cycles [RCCs]²⁶) guaranteed the exclusion of the dental influence on the inversion of the masticatory pattern. All patients underwent occlusal diagnosis according to the Angle classification, carried out clinically and on study casts by two experienced orthodontists. All patients underwent orthopaedic evaluation of the rachis with Adam forward bend test and Bunnell scoliometer as well as radiological evaluation of orthostatic posture in the coronal and sagittal projections. The diagnosis of AIS, as defined by the SRS,¹⁶ was made by two experienced orthopaedic surgeons on the basis of clinical examination and radiographic data.

The control group was selected to be age- and gender-matched with the AIS group. Control subjects were selected consecutively among those referred to the Division of Orthodontics, University of Turin, Italy, with the following inclusion criteria: (1) absence of genetic or congenital disease, (2) normal growth and development, (3) bilateral molar class I and minor or no crowding, (4) absence of crossbite, (5) no previous orthodontic treatment, (6) no diagnosis or family history of scoliosis.

2.1 | Procedures

The recordings of the chewing cycles were carried out for all the patients with the same protocol, by the same skilled operator. The subject was comfortably seated on a chair and was asked to fix his/her eyes on a target (the red beak of a Donald Duck drawing) on the wall, 90 cm directly in front of the seating position and to avoid movements of the head. The measurements were performed in a quiet and comfortable environment. Each recording began with the largest number of teeth in contact (maximum intercuspation) and the test bolus centred on the tongue. Each recording consisted of chewing for a period of 10 s and was repeated, for each recording session, three times for mastication on the right side, three times for mastication on the left side and three times for free mastication. This



TABLE 1 Characteristics of included subjects (N = 64)

	Total (N)	Age (mean \pm SD) ^a	Males (N)	Females (N)
AIS group	32	14 \pm 3	8	24
Control group	32	13 \pm 6	8	24
	Molar class I	Molar class II	Molar class III	Neutral molar class
AIS group	N = 21 (65.6%)	N = 5 (15.6%)	N = 4 (12.5%)	N = 2 (6.3%)
Control group	N = 32 (100%)	-	-	-

^aAge in years (rounded).

Abbreviation: AIS, adolescent idiopathic scoliosis.

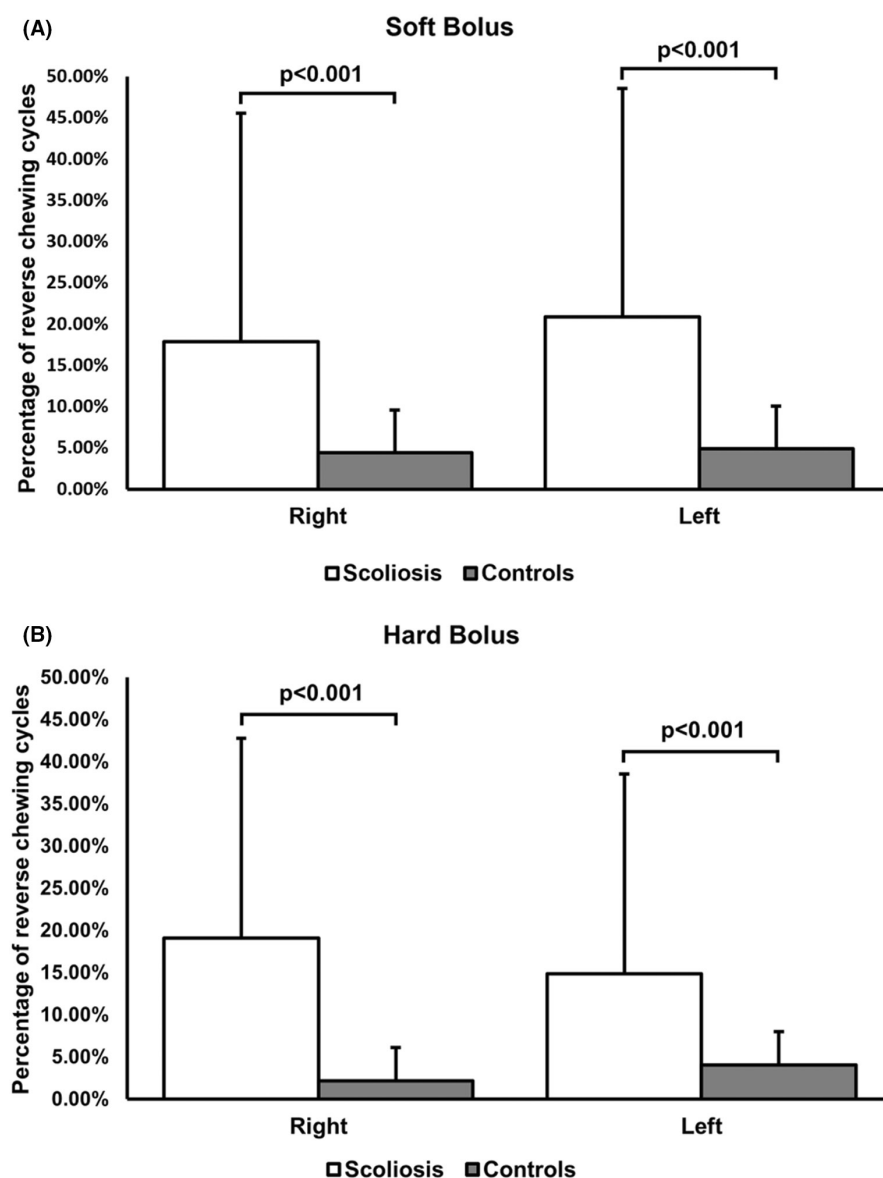


FIGURE 1 Different percentage of the dyskinetic reverse chewing cycles when chewing a soft bolus (A) and a hard bolus (B) in patients with AIS compared to control subjects (right: mastication on the right side; left: mastication on the left side).

sequence of nine recordings was repeated with a soft bolus (chewing gum) and subsequently a hard bolus (wine gum), for a total of eighteen recordings per session. A skilled operator indicated the side of mastication and visually controlled the correct performance of the subject. Both hard and soft boluses were of the same size (20 mm in

length, 1.2 mm in height and 0.5 mm in width) but of different weight (2 g for the soft bolus and 3 g for the hard bolus). The wine gum was chosen to provide a rubber-like resistance without sticking to the teeth and was changed for a new one at each recording in order to preserve its characteristics.



2.2 | Kinematic analysis

Mandibular motion was tracked using a Kinesiograph (K7-I; Myotronics, Tukwila, WA, USA) that measures jaw movements with an accuracy of 0.1 mm. Multiple sensors (Hall effect) in a lightweight (113 g) array tracked the motion of a tiny magnet attached at the lower inter-incisor point.²⁷ The Kinesiograph was interfaced with a computer for data storage and subsequent analysis.

2.3 | Signal analysis

The kinematic signals were analysed using custom-made software (University of Turin, Italy) that allows for automatic data segmentation and analysis. This approach has been described elsewhere.²⁸ The first cycle, during which the bolus was transferred from the tongue to the dental arches, was excluded from the analysis. Jaw movements between two consecutive masticatory pauses were also excluded if they did not represent a chewing cycle based on the presence of at least one of the following characteristics: (1) minimum opening smaller than 4 mm; (2) duration shorter than 300 ms; or (3) vertical opening smaller than 3 mm. From each cycle was extracted the variable 'closure angle' [°]. The values computed were averaged over all cycles recorded for the same side of mastication and the same bolus. The chewing cycles were divided into non-reverse and reverse (RCCs), based on the vectorial direction of closure. The closure angle was measured between a straight line obtained by a robust regression procedure on the last part of the curve (from 2.0 to 0.1 mm from the closing point in vertical direction) and the horizontal line of the side of mastication. Next, cycles with a closure angle larger than 90° were grouped in the reverse set.

2.4 | Statistical analysis

Before comparison, the variables were tested for normality using the Shapiro–Wilk test and the normal distribution of the data were confirmed. The prevalence of reverse chewing cycles (RCCs) in the two groups was analysed with Student's *t*-test. The significance level was set at $P < .05$. Statistical analysis was performed with the STATA software (StataCorp, 4905 Lakeway Drive, College Station, Texas, 77845, USA).

3 | RESULTS

This study included 64 subjects: 32 patients with AIS and 32 control subjects. The characteristics of the included subjects are listed in Table 1. Patients with AIS showed a significantly higher percentage of reverse cycles (RC) when chewing on both sides, both with soft and hard bolus when compared to the control group (Right side soft bolus: 17.96% for patients AIS and 3.97% for control patients,

$P < .001$; right side hard bolus: 19.12% for patients with AIS and 2.31% for control patients, $P < .001$; left side soft bolus: 20.9% for patients with AIS and 4% for control patients, $P < .001$; left side hard bolus: 14.87% for patients with AIS and 3.9% for control patients, $P < .001$) (Figure 1). According to these results, it was possible to reject the null hypothesis (H0).

4 | DISCUSSION

This study was aimed at evaluating the masticatory function of a group of patients with AIS when chewing different types of boluses by means of the prevalence of reverse-sequence chewing patterns. To the authors' knowledge, no previous research assessed this topic.

The results showed that patients with AIS had a significantly higher percentage of RCC compared to the control group, with both hard and soft boluses and on both sides of mastication ($P < .001$). It was, therefore, possible to reject the null hypothesis, confirming that there is a significant difference between the groups.

The imbalance of the vertebral column and the consequential tilt of the cervical spine affects the vertical alignment of the entire spine. Indeed, changing the functionality of the cervical muscles may convey its effects on the posture of the mandible that would in turn compensate the muscular and kinetic imbalance. The jaw opening/closing dynamic is not simply executed by reflex isolated mandibular movements: it is rather the combined outcome of concomitant mandibular and head-neck movements, as described in the introduction.^{4–6} This reflects a well-coordinated activation of jaw and neck muscles, leading to simultaneous and adequate movements in the temporomandibular, atlas-occipital and cervical spine joints.^{11,15}

The influence of malocclusions on chewing patterns is well known.^{28–31} Unusual chewing patterns called RCCs (Figure 2) have been described in a number of publications, confirming highly significant results in different patient groups. RCCs have been shown to be dyskinetic patterns, present in low percentages in subjects with normal occlusion^{2,29} and in a higher percentage in patients with neurological diseases or TMDs, as well as in a very high percentage in patients with crossbites, especially when chewing hard boluses.^{26,32} RCC refers to the reverse direction of closure of the mandibular movement during the closing phase of the chewing stroke, compared to the physiological chewing pattern. The reverse direction of closure is associated with serious alterations of the mandibular kinematic.²⁵ In fact, RCCs are related to specific features of the chewing pattern, that is narrow kinematic developing near the vertical axis in the frontal plane, with one or more cross over of the opening and closing traces and a severely limited lateral displacement of the mandible that moves mainly along the vertical axis, with a very limited freedom of movement (Figure 2). All the parameters of the RCC are indicative of a lower masticatory efficiency.^{28,33} Interestingly, as previously explained, when RCC are related to the dental malocclusion, that is posterior crossbites, their prevalence is higher with a hard bolus and lower with a soft bolus.^{28,29} In patients with AIS, there was no difference in the prevalence of the RCCs between soft

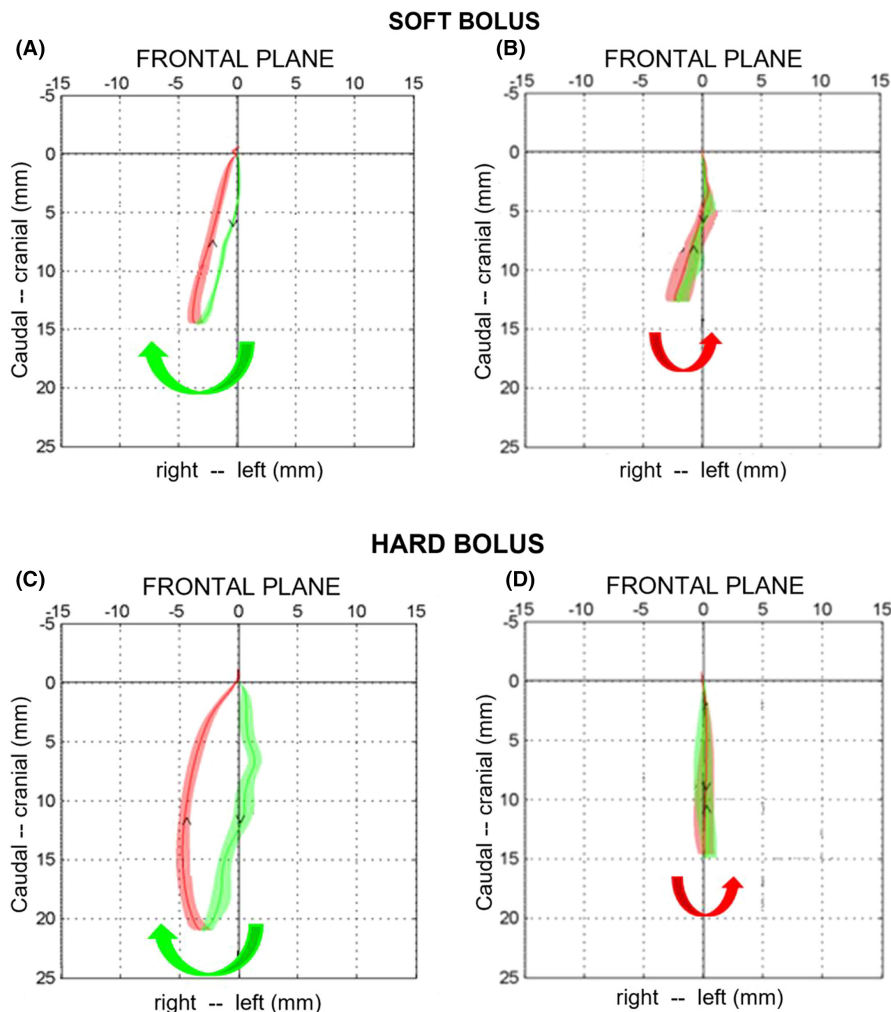


FIGURE 2 Masticatory kinematic pattern in the frontal plane. Deliberate chewing of a soft bolus on the right side, control subject (A) and patient with adolescent idiopathic scoliosis (AIS) (B). Deliberate chewing of a hard bolus on the right side, control subject (C) and patient with AIS (D). The solid line, green for the opening and red for the closing pattern, represents the average chewing cycle of 3 trials lasting 10 s each; the green and red areas represent the standard deviation over the average cycle. Observe the anomalous reverse chewing pattern (see the text) with a reverse direction of closure (arrow) of the patient with AIS (B,D).

and hard bolus. This confirms that the dyskinesia of the chewing pattern is likely to originate from the body posture.

The central hypothesis of this research is the existence of a functional relationship between the stomatognathic apparatus and the spinal column.³⁴ The precision of the information conveyed by the periodontal mechanoreceptors³⁵ plays an important role in the activation and coordination of the masticatory muscles during chewing, aimed at compensating the mandibular function. To this end, the RCCs have potential diagnostic and therapeutic relevance, allowing the clinician to monitor the progress and to functionally assess the outcome of orthopaedic and orthognathodontic treatment.

Considering the results of the present study, it is advisable to plan both orthodontic and orthopaedic treatment in a joined multidisciplinary environment. The evidence of a link between dyskinetic chewing patterns and asymmetrical posture of the spinal column suggests that orthopaedic and orthodontic treatment, especially in subjects with asymmetries of the spine, should be planned in concert to maximize treatment outcome and reduce the risk of relapse and treatment failure.

The main limitation of this study is that the outcome of orthopaedic therapy was not evaluated, and it was, therefore, not possible to investigate its functional effects on the masticatory function. As

a future direction, multidisciplinary prospective studies are advisable for a deeper understanding of this topic and to find possible correlations between the amount of spinal deviation or the features of spinal deviation and the reverse chewing patterns. Also of clinical interest would be the investigation of subclinical/non-symptomatic AIS patients, in order to highlight the potential presence of early signs in the chewing pattern analysis indicative of risk of developing scoliosis.

5 | CONCLUSIONS

In conclusion, the results of this study indicate that the presence of AIS influences mastication, one of the main functions of the stomatognathic system. A multidisciplinary approach to these patients may be relevant in providing the best possible treatment outcomes.

AUTHOR CONTRIBUTIONS

M.G. Piacino was involved in conceptualization, supervision and funding acquisition; M.G. Piacino, U. Garagiola were involved in methodology; A. Tortarolo provided the software; M. Brayda-Bruno, F. Macdonald were involved in investigation; M. Brayda-Bruno, F.



Macdonald provided the resources; L. Nucci, A. Tortarolo were involved in data curation, wrote the original draft; M.G. Piacino, U. Garagiola, M. Brayda-Bruno, F. Macdonald reviewed and edited the draft. All authors have read and agreed to the published version of the manuscript.

ACKNOWLEDGEMENTS

This research has been partially supported by a grant of the Italian Ministry of Research, Ex 60% 2020. Open Access Funding provided by Università degli Studi di Torino within the CRUI-CARE Agreement.

CONFLICT OF INTEREST

The authors declare no conflict of interest. The funders had no role in the design of the study; in the collection, analyses or interpretation of data; in the writing of the manuscript; or in the decision to publish the results.

DATA AVAILABILITY STATEMENT

The data that support the findings of this study are available on request from the corresponding author. The data are not publicly available due to privacy or ethical restrictions.

INFORMED CONSENT

Informed consent was obtained from all subjects involved in the study.

REFERENCES

- Piacino MG, Kyrkanides S. *Understanding Masticatory Function in Unilateral Crossbites*. John Wiley & Sons; 2016. doi:10.1002/9781118971901
- Piacino MG, Bracco P, Vallelonga T, Merlo A, Farina D. Effect of bolus hardness on the chewing pattern and activation of masticatory muscles in subjects with normal dental occlusion. *J Electromyogr Kinesiol*. 2008;18(6):931-937. doi:10.1016/j.jelekin.2007.05.006
- Bhatka R, Throckmorton GS, Wintergerst AM, Hutchins B, Buschang PH. Bolus size and unilateral chewing cycle kinematics. *Arch Oral Biol*. 2004;49(7):559-566. doi:10.1016/j.archoralbio.2004.01.014
- Carlsson GE. Neuromuscular problems in the orofacial region: aetiology and organic pathology. *Int Dent J*. 1981;31(3):198-201.
- Häggman-Henrikson B, Nordh E, Eriksson PO. Increased sternocleidomastoid, but not trapezius, muscle activity in response to increased chewing load. *Eur J Oral Sci*. 2013;121(5):443-449. doi:10.1111/eos.12066
- Végh A, Fábian G, Jianu R, Segatto E. Orofacial characteristics of adolescents with diagnosed spinal disorders. *Biomed Tech (Berl)*. 2012;57(1):65-69. doi:10.1515/bmt-2011-0036
- Hartvigsen J, Hancock MJ, Kongsted A, et al. What low back pain is and why we need to pay attention. *Lancet*. 2018;391(10137):2356-2367. doi:10.1016/S0140-6736(18)30480-X
- Lippold C, van den Bos L, Hohoff A, Danesh G, Ehmer U. Interdisciplinary study of orthopedic and orthodontic findings in pre-school infants. *J Orofac Orthop*. 2003;64(5):330-340. doi:10.1007/s00056-003-0236-4
- Segatto E, Lippold C, Végh A. Craniofacial features of children with spinal deformities. *BMC Musculoskelet Disord*. 2008;9:169. doi:10.1186/1471-2474-9-169
- Park YS, Lim YT, Koh K, et al. Association of spinal deformity and pelvic tilt with gait asymmetry in adolescent idiopathic scoliosis patients: investigation of ground reaction force. *Clin Biomech Bristol Avon*. 2016;36:52-57. doi:10.1016/j.clinbiomech.2016.05.005
- Amat P. Occlusion, orthodontics and posture: are there evidences? The example of scoliosis. *Int J Stomatol Occlusion Med*. 2009;2(1):2-10. doi:10.1007/s12548-009-0001-4
- Zaydman AM, Strokova EL, Kiseleva EV, et al. A new look at etiological factors of idiopathic scoliosis: neural crest cells. *Int J Med Sci*. 2018;15(5):436-446. doi:10.7150/ijms.22894
- Trobisch P, Suess O, Schwab F. Idiopathic scoliosis. *Dtsch Arzteblatt Int*. 2010;107(49):875-884. doi:10.3238/arztebl.2010.0875
- Riseborough EJ, Wynne-Davies R. A genetic survey of idiopathic scoliosis in Boston, Massachusetts. *J Bone Joint Surg Am*. 1973;55(5):974-982.
- Saccucci M, Tettamanti L, Mummolo S, Polimeni A, Festa F, Tecco S. Scoliosis and dental occlusion: a review of the literature. *Scoliosis*. 2011;6:15. doi:10.1186/1748-7161-6-15
- Korbel K, Kozinoga M, Stoliński Ł, Kotwicki T. Scoliosis Research Society (SRS) criteria and Society of Scoliosis Orthopaedic and Rehabilitation Treatment (SOSORT) 2008 guidelines in non-operative treatment of idiopathic scoliosis. *Pol Orthop Traumatol*. 2014;79:118-122.
- Ben-Bassat Y, Yitschaky M, Kaplan L, Brin I. Occlusal patterns in patients with idiopathic scoliosis. *Am J Orthod Dentofac Orthop*. 2006;130(5):629-633. doi:10.1016/j.ajodo.2005.01.032
- Korbmacher H, Koch L, Eggers-Stroeder G, Kahl-Nieke B. Associations between orthopaedic disturbances and unilateral crossbite in children with asymmetry of the upper cervical spine. *Eur J Orthod*. 2007;29(1):100-104. doi:10.1093/ejo/cjl066
- Pedrotti L, Mora R, Bertani B, Tuvo G, Crivellari I. Association among postural and skull-cervico-mandibular disorders in childhood and adolescence. Analysis of 428 subjects. *Pediatr Med Chir*. 2007;29(2):94-98.
- Langella F, Fusini F, Rossi G, et al. Spinal deformity and malocclusion association is not supported by high-quality studies: results from a systematic review of the literature. *Eur Spine J*. 2019;28(7):1638-1651. doi:10.1007/s00586-019-05896-4
- D'Attilio M, Filippi MR, Femminella B, Festa F, Tecco S. The influence of an experimentally-induced malocclusion on vertebral alignment in rats: a controlled pilot study. *Cranio J Craniomandib Pract*. 2005;23(2):119-129. doi:10.1179/crn.2005.017
- D'Attilio M, Cesaretti G, Viganò P, et al. Effects of induced malocclusion on vertebral alignment in rats: a controlled study by CBCTs. *Animals*. 2021;11(10):2808. doi:10.3390/ani11102808
- Ramirez-Yanez GO, Mehta L, Mehta NR. The effect of dental occlusal disturbances on the curvature of the vertebral spine in rats. *Cranio*. 2015;33(3):217-227. doi:10.1179/2151090314Y.0000000017
- Piacino MG, MacDonald F, Laponte I, Cannavale R, Crincoli V, Dalmaso P. Juvenile/adolescent idiopathic scoliosis and rapid palatal expansion. A pilot study. *Children*. 2021;8(5):362. doi:10.3390/children8050362
- Uçar İ, Batın S, Arık M, et al. Is scoliosis related to mastication muscle asymmetry and temporomandibular disorders? A cross-sectional study. *Musculoskelet Sci Pract*. 2022;58:102533. doi:10.1016/j.msksp.2022.102533
- Piacino MG, Talpone F, Dalmaso P, Debernardi C, Lewin A, Bracco P. Reverse-sequencing chewing patterns before and after treatment of children with a unilateral posterior crossbite. *Eur J Orthod*. 2006;28(5):480-484. doi:10.1093/ejo/cjl014
- Jankelson B. Measurement accuracy of the mandibular kinesiograph—a computerized study. *J Prosthet Dent*. 1980;44(6):656-666. doi:10.1016/0022-3913(80)90464-3



28. Piacino MG, Farina D, Talpone F, Merlo A, Bracco P. Muscular activation during reverse and non-reverse chewing cycles in unilateral posterior crossbite. *Eur J Oral Sci.* 2009;117(2):122-128. doi:10.1111/j.1600-0722.2008.00601.x
29. Piacino MG, Comino E, Talpone F, Vallelonga T, Frongia G, Bracco P. Reverse-sequencing chewing patterns evaluation in anterior versus posterior unilateral crossbite patients. *Eur J Orthod.* 2012;34(5):536-541. doi:10.1093/ejo/cjr109
30. Piacino MG, Frongia G, Dalessandri D, Bracco P, Ramieri G. Reverse cycle chewing before and after orthodontic-surgical correction in class III patients. *Oral Surg Oral Med Oral Pathol Oral Radiol.* 2013;115(3):328-331. doi:10.1016/j.ooolo.2012.04.025
31. Ferrario VF, Piacino MG, Dellavia C, Castroflorio T, Sforza C, Bracco P. Quantitative analysis of the variability of unilateral chewing movements in young adults. *Cranio J Craniomandib Pract.* 2006;24(4):274-282. doi:10.1179/crn.2006.043
32. Piacino MG, Cordero-Ricardo M, Cannavale R, Vallelonga T, Garagiola U, Merlo A. Improvement of masticatory kinematic parameters after correction of unilateral posterior crossbite: reasons for functional retention. *Angle Orthod.* 2017;87(6):871-877. doi:10.2319/020917-98.1
33. Piacino MG, Falla D, Merlo A, et al. Effects of therapy on masseter activity and chewing kinematics in patients with unilateral posterior crossbite. *Arch Oral Biol.* 2016;67:61-67. doi:10.1016/j.archoralbio.2016.03.013
34. D'Attilio M, Epifania E, Ciuffolo F, et al. Cervical lordosis angle measured on lateral cephalograms; findings in skeletal class II female subjects with and without TMD: a cross sectional study. *Cranio J Craniomandib Pract.* 2004;22(1):27-44. doi:10.1179/crn.2004.005
35. Piacino MG, Isola G, Cannavale R, et al. From periodontal mechanoreceptors to chewing motor control: a systematic review. *Arch Oral Biol.* 2017;78:109-121. doi:10.1016/j.archoralbio.2017.02.010

How to cite this article: Piacino MG, Tortarolo A, Macdonald F, Garagiola U, Nucci L, Brayda-Bruno M. Spinal disorders and mastication: The potential relationship between adolescent idiopathic scoliosis and alterations of the chewing patterns. *Orthod Craniofac Res.* 2023;26:178-184. doi: [10.1111/ocr.12598](https://doi.org/10.1111/ocr.12598)