



# Home monitoring of lung mechanics by oscillometry before, during and after severe COVID-19 disease: a case study

Copyright ©The authors 2023

This version is distributed under the terms of the Creative Commons Attribution Non-Commercial Licence 4.0. For commercial reproduction rights and permissions contact [permissions@ersnet.org](mailto:permissions@ersnet.org)

Received: 31 Aug 2022  
Accepted: 16 Jan 2023

## To the Editor:

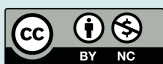In November 2020, Europe faced the second wave of the coronavirus disease 2019 (COVID-19) pandemic. The need to manage patients while reducing potential exposure and healthcare system overload led to renewed interest in home monitoring of respiratory variables. Together with variables related to COVID-19 infection [1], home-based lung imaging [2] and lung mechanics [3, 4] were used to monitor COVID-19 and chronic respiratory patients during limited access to traditional care. Home monitoring respiratory-specific variables may provide important information about patient health status and clinical course.

Lung mechanics monitoring may be particularly valuable in COVID-19 patients with respiratory comorbidities. Spirometry was successfully used at home during the pandemic [4]; however, testing requires guidance, is difficult in naïve patients, prone to erroneous results [5] and may release contaminated aerosols. Oscillometry allows noninvasive monitoring of respiratory resistance (mainly reflecting airway resistance) and reactance (primarily related to peripheral airway and lung volume recruitment/derecruitment) during spontaneous breathing [6]. Moreover, oscillometry is suitable for home monitoring and provides accurate results and high patient adherence [7].

We report a unique dataset of weekly oscillometry measurements over 1 year for a patient before, during and while recovering from severe COVID-19 disease.

The study was approved by the ethics committee of Politecnico di Milano University (n. 21/2022). Informed written consent for publication of his clinical details and images was obtained from the patient. The patient is a 59-year-old Caucasian man with a body mass index of 20.0 kg·m<sup>-2</sup>. Past medical history included mild controlled type-two diabetes since 2010 treated with metformin 500 mg·day<sup>-1</sup>. He was a former cigarette smoker (20 pack-years until 2005). He did not report respiratory symptoms since quitting smoking, or drug allergies. He led a normal active life with moderate physical activity. As he is a clinical and commercial expert in the field of lung physiopathology, his diffusing capacity of the lungs for carbon monoxide ( $D_{LCO}$ ), spirometry (forced expiratory volume in 1 s (FEV<sub>1</sub>) 102% predicted; forced vital capacity (FVC) 108% pred; FEV<sub>1</sub>/FVC ratio 94% pred), oscillometry (figure 1) and lung volumes (vital capacity (VC) 108% pred; inspiratory capacity (IC) 103% pred) measurements for months before the onset of COVID-19 were available.

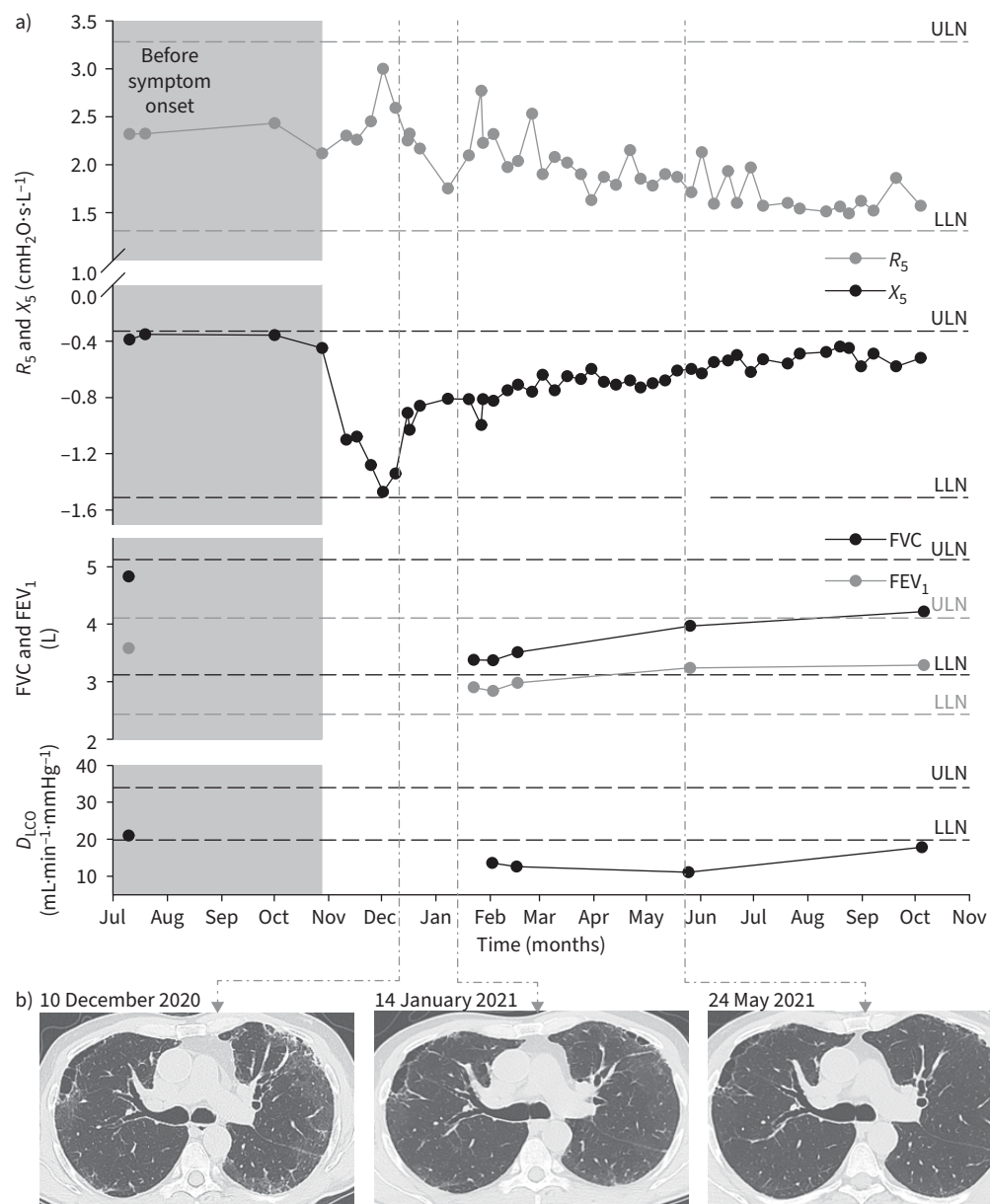
On 28 October 2020, the patient experienced shivers and moderate fatigue, and sudden shortness of breath a few days later. After 3 days of persistent symptoms, a nasopharyngeal swab test confirmed COVID-19 infection. Room-air oxygen saturation ( $S_{pO_2}$ ) dropped to 82% on 6 November. Blood testing (11 November) confirmed severe inflammation with an increase of D-dimer index (2500 ng·mL<sup>-1</sup>; normal values <500 ng·mL<sup>-1</sup>). Home thoracic chest ultrasounds on 11 and 16 November demonstrated diffuse bilateral B-lines compatible with COVID-19 interstitial pneumonia. The disease severity was “severe” per World Health Organization classification. However, the patient was apprehensive about attending a busy hospital and opted for home-treatment, including oxygen by portable concentrator (up to 2–3 L·min<sup>-1</sup> for 24/24 h), azithromycin and low-molecular-weight heparin. From the onset of symptoms, the patient performed weekly oscillometry measurements according to technical standards [6] in a seated position using a signal combining 5, 11 and 19 Hz (ResmonPro FULL; Restech, Milan, Italy). After the onset of



Shareable abstract (@ERSpublications)

**A patient regularly self-performing home oscillometry developed severe COVID-19 pneumonia and continued testing during and after the disease. COVID-19 suddenly worsened oscillatory reactance, which took almost 1 year to recover to pre-COVID-19 values.** <https://bit.ly/3WCpWCO>

**Cite this article as:** Veneroni C, Perissin R, Di Marco F, *et al.* Home monitoring of lung mechanics by oscillometry before, during and after severe COVID-19 disease: a case study. *ERJ Open Res* 2023; 9: 00480-2022 [DOI: 10.1183/23120541.00480-2022].



**FIGURE 1** Respiratory resistance at 5 Hz ( $R_5$ ), respiratory reactance at 5 Hz ( $X_5$ ), forced vital capacity (FVC), forced expiratory volume in 1 s (FEV<sub>1</sub>) and diffusing capacity of the lungs for carbon monoxide ( $D_{LCO}$ ) data over 15 months. Spirometry and  $D_{LCO}$  data were not recorded during the acute phase of the disease. Upper (ULN) and lower limits of normality (LLN) are reported. **b)** Images from computed tomography scans.

symptoms, oscillatory resistance at 5 Hz ( $R_5$ ) increased and reactance at 5 Hz ( $X_5$ ) decreased (figure 1), despite remaining within the normal range [8]. Intratidal changes in  $X_5$  were always  $<0.2$  cmH<sub>2</sub>O, indicating the absence of expiratory flow limitation during tidal breathing [9].

On 10 December, a chest computed tomography (CT) scan demonstrated bilateral paraseptal emphysematous lesions (most likely pre-existing and due to prolonged exposure to cigarette smoke) and bilateral diffuse ground-glass opacities. A systemic steroid (prednisone starting at 25 mg daily), initially avoided because of the subject's diabetes, was administered from 14 December. An initial fast partial improvement in lung mechanics was followed by a longer period of slower improvements in lung mechanics and clinical conditions. Resolution of hypoxaemia took several weeks. Room-air  $S_{pO_2}$   $>94\%$  was achieved 30 days after peak acute worsening.

Two subsequent CT scans showed the disappearance of the ground-glass opacities (figure 1). 3 months after symptom onset, complete cardiopulmonary exercise testing (CPET) showed a mild reduction of exercise capacity (maximum oxygen consumption ( $V_{O_{2max}}$ ) 76% pred; nadir  $S_{pO_2}$  87%), normal forced spirometry (figure 1), moderate reduction of lung volumes (VC 85% pred; IC 64% pred) and severe reduction in  $D_{LCO}$ , membrane conductivity ( $D_m$ ) and volume of alveolar capillary blood ( $V_c$ ) to 46% pred, 54% pred and 35% pred, respectively. 6 months after symptom onset, lung volumes (VC 99% pred; IC 71% pred) and CPET improved ( $V_{O_{2max}}$  76% pred; 93%  $S_{pO_2}$ ), but  $D_{LCO}$  was still abnormal ( $D_{LCO}$  40% pred;  $D_m$  41% pred;  $V_c$  34% pred). 1 year after symptom onset,  $D_{LCO}$  improved (68% pred), approaching its baseline value, similar to  $X_5$ .  $R_5$  remained lower than pre-COVID values. Lung volumes (VC 103% pred; IC 85% pred) and spirometry parameters (FEV<sub>1</sub> 102% pred; FVC 103% pred; FEV<sub>1</sub>/FVC 102% pred) further improved, but remained below pre-COVID values.

Our results show that home longitudinal monitoring of lung function by oscillometry allowed a unique evaluation of the mechanical properties of the lung before, during and after COVID-19 interstitial pneumonia, including the long recovery phase. Despite not exceeding the lower limit of normality,  $X_5$  decreased >400% from baseline values. The wide range of normality provided by existing oscillometry reference equations, together with fast improvement after commencement of steroid treatment, may explain the normal  $X_5$  values found in several severe COVID-19 patients [10]. Spirometry results were also within the range of normality, despite being worse than pre-COVID values. These data underline that alterations in lung mechanics are difficult to detect when only considering the lower limit of normality. Conversely, monitoring longitudinal changes may provide a more sensitive tool for evaluating disease evolution and the impact of treatments. Oscillometry can facilitate longitudinal monitoring, as it allows measurements in dyspnoeic patients and when spirometry is difficult or not indicated (any forced or maximal manoeuvre during the acute pathology).

Follow-up data of COVID-19 patients showed pulmonary structural abnormalities and abnormal  $D_{LCO}$  for several months post-infection [11]. Our data seem to indicate that  $X_5$  can also require a long time for full recovery, with values approaching baseline 1 year post-infection.  $R_5$  remained lower than pre-COVID. Possible explanations may be tidal breathing occurring at higher lung volume (IC was still lower than pre-COVID), increased parenchymal elastic recoil, or reduced interstitial oedema [12].

Measurements were performed in standardised conditions and with the same set-up. However, changes in the patient's breathing patterns may have influenced oscillometry parameters. Additionally, the clinical care that the patient agreed to did not follow standardised protocols, as he refused hospitalisation and steroid administration was delayed. Finally, because of the observational design of the study, causality could not be inferred. Despite these limitations, our study shows that longitudinal assessment of respiratory mechanics by oscillometry at home allowed changes in lung function to be tracked in a patient with severe interstitial COVID-19 pneumonia when limited monitoring data were available.

Chiara Veneroni<sup>1</sup>, Roberto Perissin<sup>2</sup>, Fabiano Di Marco<sup>3,4,5</sup> and Raffaele L. Dellaca<sup>1,5</sup>

<sup>1</sup>TechRes Lab, Department of Electronics, Information and Biomedical Engineering, Politecnico di Milano University, Milan, Italy. <sup>2</sup>MGC Diagnostics Corp, St. Paul, MN, USA. <sup>3</sup>Unit of Pneumology, Azienda Ospedaliera Socio Sanitaria Territoriale Papa Giovanni XXIII, Bergamo, Italy. <sup>4</sup>Department of Health Sciences, University of Milan, Milan, Italy. <sup>5</sup>These authors contributed equally.

Corresponding author: Chiara Veneroni ([chiara.veneroni@polimi.it](mailto:chiara.veneroni@polimi.it))

Provenance: Submitted article, peer reviewed.

Acknowledgements: We gratefully acknowledge Mar Janna Dahl (University of Utah, Salt Lake City, UT, USA) for revising the manuscript. We would like to thank Pasqualino Berardinelli (H San Raffaele Resnati Srl, Milan, Italy) and Sandro Amaducci (Columbus Clinic Center, Milan, Italy) for the clinical management of the patient.

Author contributions: C. Veneroni conceived and designed the study, analysed the data and drafted the manuscript. R. Perissin managed data acquisition and critically revised the manuscript. F. Di Marco conceived and designed the study, interpreted data and drafted the manuscript. R.L. Dellaca' conceived and designed the study, interpreted data and critically revised the manuscript. All the authors approved the final version of the manuscript.

Conflict of interest: C. Veneroni and F. Di Marco have nothing to disclose. R. Perissin is the Vice President, Worldwide FOT and Asthma Management Business Development, MGC Diagnostics International. R.L. Dellacà reports grants from Restech and personal fees from Philips Healthcare, outside the submitted work; in addition, he has a patent on the detection of EFL by FOT with royalties paid to Philips Respironics and Restech Srl, a patent on monitoring lung volume recruitment by FOT with royalties paid to Vyair, and a patent on early detection of exacerbations by home monitoring of FOT with royalties paid to Restech, and is cofounder and shareholder of Restech Srl, a spin-off company of the Politecnico di Milano University producing medical devices for lung function testing based on FOT.

## References

- 1 Lukas H, Xu C, Yu Y, *et al.* Emerging telemedicine tools for remote COVID-19 diagnosis, monitoring, and management. *ACS Nano* 2020; 14: 16180–16193.
- 2 Shokoohi H, Duggan NM, García-de-Casasola Sánchez G, *et al.* Lung ultrasound monitoring in patients with COVID-19 on home isolation. *Am J Emerg Med* 2020; 38: 2759–2759.
- 3 Davies B, Kenia P, Nagakumar P, *et al.* Paediatric and adolescent asthma: a narrative review of telemedicine and emerging technologies for the post-COVID-19 era. *Clin Exp Allergy* 2021; 51: 393–401.
- 4 Richardson CH, Orr NJ, Olsson SL, *et al.* Initiating home spirometry for children during the COVID-19 pandemic – a practical guide. *Paediatr Respir Rev* 2022; 42: 43–48.
- 5 Wensley DC, Silverman M. The quality of home spirometry in school children with asthma. *Thorax* 2001; 56: 183–185.
- 6 King GG, Bates J, Berger KI, *et al.* Technical standards for respiratory oscillometry. *Eur Respir J* 2020; 55: 1900753.
- 7 Walker PP, Pompilio PP, Zanaboni P, *et al.* Telemonitoring in chronic obstructive pulmonary disease (CHROMED). A randomized clinical trial. *Am J Respir Crit Care Med* 2018; 198: 620–628.
- 8 Oostveen E, Boda K, van der Grinten CPM, *et al.* Respiratory impedance in healthy subjects: baseline values and bronchodilator response. *Eur Respir J* 2013; 42: 1513–1523.
- 9 Dellacà RL, Duffy N, Pompilio PP, *et al.* Expiratory flow limitation detected by forced oscillation and negative expiratory pressure. *Eur Respir J* 2007; 29: 363–374.
- 10 Torregiani C, Veneroni C, Confalonieri P, *et al.* Monitoring respiratory mechanics by oscillometry in COVID-19 patients receiving non-invasive respiratory support. *PLoS One* 2022; 17: e0265202.
- 11 Bellan M, Baricich A, Patrucco F, *et al.* Long-term sequelae are highly prevalent one year after hospitalization for severe COVID-19. *Sci Rep* 2021; 11: 22666.
- 12 Dellacà RL, Zannin E, Sancini G, *et al.* Changes in the mechanical properties of the respiratory system during the development of interstitial lung edema. *Respir Res* 2008; 9: 51.