

Hippocampal atrophy and white matter lesions characteristics can predict evolution to dementia in patients with vascular mild cognitive impairment

Carlo Manco^a, Rosa Cortese^{a,*}, Matteo Leoncini^b, Domenico Plantone^a, Giordano Gentile^{a,b}, Ludovico Luchetti^{a,b}, Jian Zhang^b, Ilaria Di Donato^c, Emilia Salvadori^g, Anna Poggesi^d, Mirco Cosottini^e, Mario Mascalchi^f, Antonio Federico^a, Maria Teresa Dotti^a, Marco Battaglini^{a,b}, Domenico Inzitari^d, Leonardo Pantoni^g, Nicola De Stefano^a, on behalf of the VMCI-Tuscany Study Group

^a Department of Medicine, Surgery and Neuroscience, University of Siena, 53100 Siena, Italy

^b Siena Imaging SRL, 53100 Siena, Italy

^c Neurology, San Giuseppe Hospital, Empoli, Italy

^d NEUROFARBA Department, Neuroscience Section, University of Florence, Florence, Italy

^e Department of Translational Research and New Technologies in Medicine and Surgery, University of Pisa, Pisa, Italy

^f Department of Clinical and Experimental Biomedical Sciences - "Mario Serio", University of Florence, Florence, Italy

^g Department of Biomedical and Clinical Sciences, University of Milano, Italy

ARTICLE INFO

Keywords:

Vascular cognitive impairment
Neuroimaging
Dementia
hippocampus
Cerebral small vessel disease

ABSTRACT

Background: Vascular mild cognitive impairment (VMCI) is a transitional condition that may evolve into Vascular Dementia (VaD). Hippocampal volume (HV) is suggested as an early marker for VaD, the role of white matter lesions (WMLs) in neurodegeneration remains debated.

Objectives: Evaluate HV and WMLs as predictive markers of VaD in VMCI patients by assessing: (i) baseline differences in HV and WMLs between converters to VaD and non-converters, (ii) predictive power of HV and WMLs for VaD, (iii) associations between HV, WMLs, and cognitive decline, (iv) the role of WMLs on HV.

Methods: This longitudinal multicenter study included 110 VMCI subjects (mean age: 74.33 ± 6.63 years, 60 males/50 females) from the VMCI-Tuscany Study database. Subjects underwent brain MRI and cognitive testing, with 2-year follow-up data on VaD progression. HV and WMLs were semi-automatically segmented and measured. ANCOVA assessed group differences, while linear and logistic regression models evaluated predictive power.

Results: After 2 years, 32/110 VMCI patients progressed to VaD. Converting patients had lower HV ($p = 0.015$) and higher lesion volumes in the posterior thalamic radiation ($p = 0.046$), splenium of the corpus callosum ($p = 0.016$), cingulate gyrus ($p = 0.041$), and cingulum hippocampus ($p = 0.038$). HV alone did not fully explain progression ($p = 0.059$), but combined with WMLs volume, the model was significant ($p = 0.035$). The best prediction model ($p = 0.001$) included total HV ($p = 0.004$) and total WMLs volume of the posterior thalamic radiation ($p = 0.005$) and cingulate gyrus ($p = 0.005$), achieving 80% precision, 81% specificity, and 74% sensitivity. Lower HV were linked to poorer performance on the Rey Auditory-Verbal Learning Test delayed recall (RAVLT) and Mini Mental State Examination (MMSE).

Conclusions: HV and WMLs are significant predictors of progression from VMCI to VaD. Lower HV correlate with worse cognitive performance on RAVLT and MMSE tests.

1. Introduction

Vascular Mild Cognitive Impairment (VMCI) represents a critical

stage within the spectrum of Vascular Cognitive Impairment (VCI), characterized by a gradual decline in cognitive abilities attributed to various vascular factors such as ischemia, hemorrhage, or

* Corresponding author.

E-mail address: rosa.cortese@unisi.it (R. Cortese).

<https://doi.org/10.1016/j.jns.2024.123163>

Received 13 June 2024; Received in revised form 1 August 2024; Accepted 4 August 2024

Available online 6 August 2024

0022-510X/© 2024 The Authors. Published by Elsevier B.V. This is an open access article under the CC BY license (<http://creativecommons.org/licenses/by/4.0/>).

neurodegeneration [1,2]. Individuals experiencing VMCI typically exhibit mild impairments in activities of daily living (ADLs), signaling the initial stages of cognitive decline that could potentially progress to Vascular Dementia (VaD), or as replaced by DSM-V into major neurocognitive disorder (major-NCD), a more severe form of cognitive impairment. Notably, the risk factors associated with VMCI and subsequent major-NCD include arterial hypertension, high cholesterol, diabetes, and smoking, collectively elevating the risk of dementia by 20–40% in general population [3,4].

Cerebral small vessel disease (CSVD) is a significant contributor to the development of VCI and age-related functional decline. This condition entails the chronic and progressive deterioration of the small blood vessels within the brain, comprising small arteries, arterioles, capillaries, and small veins [5,6]. The relentless damage inflicted by CSVD disrupts the intricate network of cerebral vasculature, leading to compromised blood flow and subsequent cognitive impairments commonly observed in individuals with VMCI.

Within the VCI spectrum, VaD represents the most severe manifestation, involving the most profound cognitive deficits and functional impairments. Serving as an overarching term for the most severe subtypes of VCI, VaD delineates the advanced stages of vascular-related cognitive decline, as outlined in the latest Vascular Impairment of Cognition Classification Consensus Study (VICCCS) [7]. This hierarchical classification underscores the progressive nature of vascular-related cognitive disorders, with VMCI serving as a crucial precursor to the debilitating effects of VaD. There is an urgent need for biomarkers to predict disease onset and track its progression, as the management of risk factors can prevent the development of dementia [6]. Magnetic resonance imaging (MRI) markers are crucial in assessing and diagnosing VaD, revealing structural and vascular changes in the brain. For example, in patients with VCI, MRI allows the estimation of total cerebral and medial temporal lobe atrophy, ventricular size, and the degree of white matter lesions (WMLs) by using appropriate assessment scales, such as the Cardiovascular Health Study scale (CHS Scale), medial temporal atrophy score (Schelten's Scale), and age-related white matter changes scale (ARWMC scale) [8–10]. The hippocampus, a significantly affected region in patients with VCI, undergoes detectable structural alterations observable through MRI, with volumetric evaluation now recommended in recent consensus study [7,11]. However, the precise diagnostic and prognostic implications of the hippocampal alterations remain incompletely defined. In our previous work using the VMCI Tuscany cohort, we observed a correlation between increased frequency of white matter lesions (WMLs) along association tracts and deficits in psychomotor speed and constructional praxis. Additionally, we noted a prevalence of lesions in the frontal white matter, particularly among VMCI patients exhibiting involvement in non-amnesic domains [12]. To date, only few studies have investigated the role of hippocampal volume in VMCI, using automatic segmentation methods and analyzing cognitive outcomes, and their relationship with the degree of severity of WMLs [13–16]. These works demonstrated that low hippocampal volume influences the extent of future cognitive decline, whereas the impact of WMLs on the severity of hippocampal atrophy is still a subject of debate, requiring further investigation [17–21].

Against this background, the main objective of this study was to examine the relevance of hippocampal atrophy and WMLs characteristics as a predictive marker of progression to dementia in patients with VMCI associated with CSVD, through the assessment of: i) differences in hippocampal volume and WMLs characteristics at baseline between patients who converted to major-NCD and those who did not; ii) predictive power of hippocampal atrophy and WMLs characteristics on major-NCD progression, iii) associations between total hippocampal volume/WMLs characteristics and cognitive decline; iii) the potential role of WMLs burden in hippocampal atrophy.

2. Materials and methods

2.1. Study subjects

In this multicenter, retrospective, longitudinal study, we assessed patients with VMCI due to CSVD who were enrolled at the University Hospitals of Florence, Pisa and Siena in the context of the VMCI-Tuscany study. The study's methodology and the timeframe for enrolling patients are detailed elsewhere [22]. From the original cohort, we selected patients with the following inclusion criteria: i) diagnosis of MCI according to the Winblad criteria [23] operationalized by Salvadori et al. 2016 [24], ii) MRI evidence on FLAIR/T2-weighted images of moderate or severe degree of white matter lesions (WMLs), iii) having CSVD. Exclusion criteria were: i) the presence of WMLs from other neurological conditions, ii) the inability to provide informed consent, iii) the presence of non-lacunar infarcts in the gray matter (GM) or hemorrhagic lesions, whose tissue damage may be a confounder in the interpretation of ischemic WMLs mapping.

At enrollment, each patient performed a complete neuropsychological [25] and an MRI examination. A clinical longitudinal assessment was performed after 24 months and the information on the evolution in major-NCD was recorded.

2.2. Standard protocol approvals, registrations, and patient consent

The study was performed in accordance with the Helsinki Declaration and approved by local ethics boards. A written informed consent was obtained from all study participants.

2.3. MRI data acquisition and analysis

MRI data were acquired using 1.5 T scanners and Philips machine for subjects related to the centers of Siena and Florence ($n = 91$), 3 T scanner and GE machine for the subject's afferent to the center of Pisa ($n = 19$). For the purposes of this study, we assessed high-resolution 3D T1-weighted (T1-W) images and FLAIR images.

The image analysis involved the following steps (Fig. 1):

- First, WMLs were semi-automatically outlined on FLAIR images using a segmentation technique based on user-supervised local thresholding (Jim; www.xinapse.com/Manual/). Total lesion volume was computed by multiplying lesion area by slice thickness. Hippocampi were semi-automatically segmented; for each subject, a first hippocampi mask was obtained using FIRST (<https://fsl.fmrib.ox.ac.uk/fsl/fslwiki>). Then, the mask was visually checked and manually refined where needed according to the EADC-ADNI protocol [26] by two raters (C.M. e M.L.) by consensus.
- Second, WMLs on the 3D T1-W images were refilled using FSL and all the hippocampal volumes obtained were subsequently normalized for the size of the head of each subject through the Vscaling (Volumetric Scaling Factor) of the SIENAX2 software [27] and before perform the analysis, a template was obtained registering all the 3D T1-W images to the MNI152 atlas using a nonlinear registration. Then, the registered images were merged to create a template. The JHU-ICBM-labels 1 mm atlas, a white matter bundles atlas from the FSL dataset atlases (Supplementary Table 1), was registered to the template using a combination of linear and nonlinear registration. Then, we registered each 3D T1-W image to the template using again a combination of linear and nonlinear registration; the translation matrix obtained was then inverted in order to move back the JHU-ICBM-labels 1 mm atlas to the corresponding T1.
- Third, for each substructure and bundle included in the atlas, a mask representative of the intersection cluster between the structure itself and the lesion mask was obtained, and the volume was calculated.

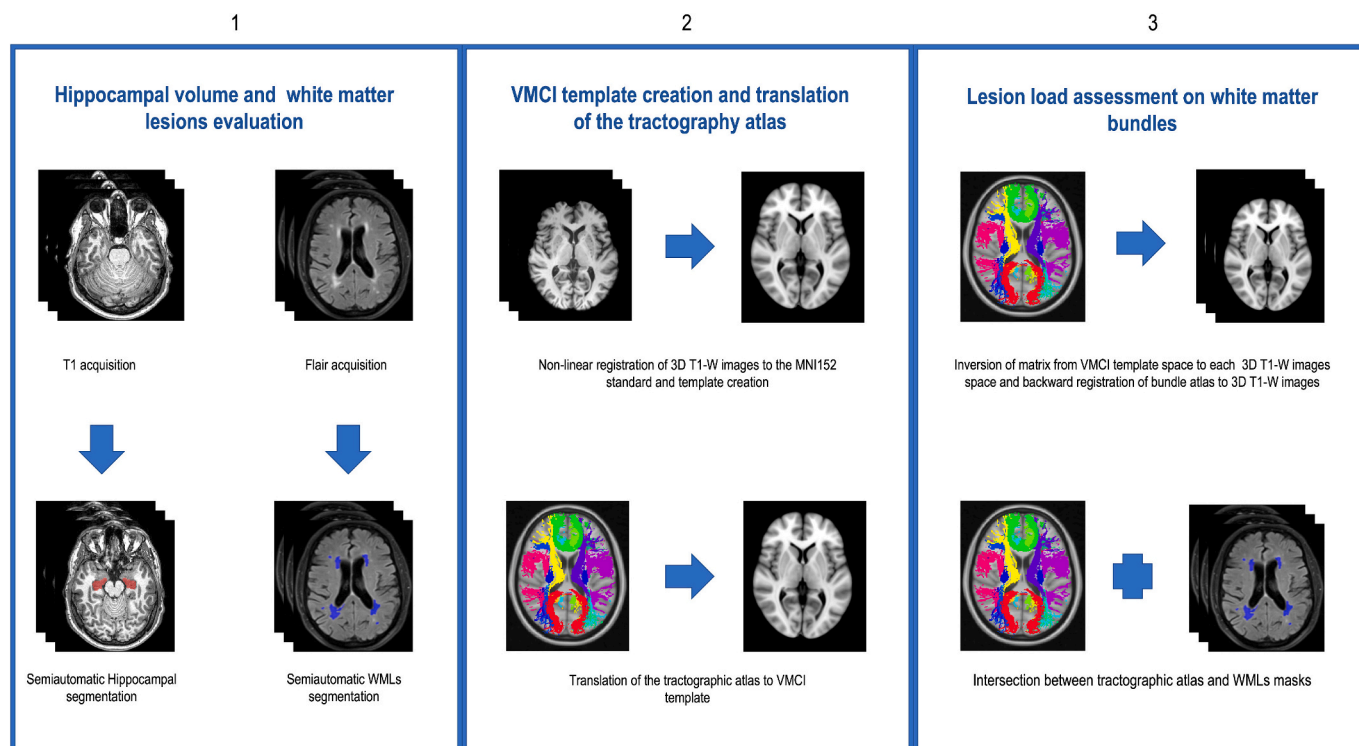


Fig. 1. Representation of the image analysis pipeline.

1) The masks of the hippocampus and the WMLs were initially acquired using semi-automatic methods, and afterwards revised by two raters.; 2) All T1-W 3D images were non-linearly registered to the MNI152 and a standard template was created, followed by the addition of the tractographic atlas.; 3) Finally, after a backward recording of the tractographic atlas on the T1W 3D images and the intersection with the WMLs masks, the lesional volume for each bundle was obtained.

2.3.1. Neuropsychological assessment

The VMCI-Tuscan Neuropsychological Battery [25] is based on 14 tests, with corresponding age- and education-adjusted scores. In detail, it includes two tests of global mental functioning as Mini Mental State Examination (MMSE) and the Montreal Cognitive Assessment Battery (MoCA). The battery also includes 12 domain-specific or second-level tests, targeting a wide range of cognitive abilities: four tests for memory (Rey Auditory-Verbal Learning Test [RAVLT] immediate and delayed recall and Short Story for verbal memory; Rey-Osterrieth Complex Figure [ROCF] recall for visuospatial memory), five tests for attention and executive functions (Trail Making Test [TMT] Part A for psychomotor speed; Visual Search [number of matrices] for focused attention; Symbol Digit Modalities Test [SDMT] for sustained attention; Color Word Stroop Test for selective attention; TMT Part B for divided attention), two tests for language (Phonemic and Semantic Verbal Fluency) and one test for constructional praxis (ROCF copy).

Cognitive scores were available for all patients in all tests except 47 patients for TMT Part A and B, due to the time limit of their administration procedure, so that if a patient does not complete the task within 5 min, the examiner stops the test administration, and scores are not obtained. The full list of cognitive tests performed was previously described [25].

The diagnosis of mild cognitive impairment required at least one borderline score (an adjusted score between the outer and inner 95% confidence limits for the 5th percentile of the normal population according to Italian normative data) among the 12 scores from second-level test, while diagnosis of major-NCD was assigned in according with operationalized DSM-5 criteria for major neurocognitive disorders (NCD) [24,28], in this way, were selected cases with a worsened functional and cognitive outcome or cases with stable cognitive and worsened functional outcome but not consequent to other disease or physical limitations.

2.4. Statistical analysis

First, we analyzed the descriptive characteristics of whole our population, consisting of 110 subjects, reporting the mean/median 25° and 75° percentile, standard deviation, and the normal distribution of our data by the Shapiro-Wilk test considered significant if $p < 0.05$ and the same characteristics in the converting and non-converting groups (Table 1). An ANCOVA analysis was used to compare total hippocampal volume and WMLs characteristics of between converting and non-converting groups. Multiple comparisons corrections were applied in both cases. The covariates included in the analysis were age, education, MRI source, and Vscaling with the addition of gender and total WMLs volume for comparison of total hippocampal volume between converting and non-converting groups (Table 1).

Models of binomial logistic regression tested for the predictors: age, gender, MRI source, education, and Vscaling, with and without total WMLs volume was used to evaluate the total hippocampal volume's ability to predict the progression to major-NCD and the influence of the total WMLs volume on the model, the goodness of the model has been evaluated considering the Pseudo- R^2 of Cox and Snell and of Nagelkerke.

The same analysis with exclusion of the total WMLs volume variable was used to evaluate the predictive role of the volume of the WMLs in selected white matter bundles on the progression to major-NCD. Finally, models of binomial logistic regression were compared, the first formed by the predictors age, gender, MRI source, education, Vscaling and total hippocampal volume, the subsequent ones with progressive addition of the variables found significant to the previous analyses in order to determine the model with the best predictive measures and significant variables; the accuracy, sensitivity and specificity of the best model has been measured.

Models of linear regression analysis tested for the covariates: age, gender, MRI source, education, total WML volume, Vscaling, was used to assess: i) the correlation between total hippocampal volume and

Table 1
Clinical and imaging characteristics of the cohort.

	Whole cohort (n. 110)	Converting patients (n. 32)	Non-converting (n. 78)	Shapiro-Wilk test in Whole group (n. 110), p value	
Age, mean (SD), years	74.33 (6.63)	75.25 (6.58)	74 (6.66)	0.984	
Sex (F/M)	49 females /61 males	12/20	38/40		
Education, median (25 th percentile-75 th percentile)	8 (5–11.75)	6 (5–11.2)	8 (5–11.7)	< 0.0001	
Score at MOCA, median (25 th percentile-75 th percentile)	21.7 (18.1–24.9)	19.1 (16.1–22.1)	22.3 (19.5–25.3)	0.017	
Score MMSE, median (25 th percentile-75 th percentile)	27.9 (25.9–30)	26.2 (23.6–28.3)	28.5 (26.8–30)	< 0.001	
Score RAVLT immediate, median (25 th percentile-75 th percentile)	33.1 (27.1–37.8)	28.3 (24.9–33)	34.6 (28–40)	0.080	
Score RAVLT delayed recall, median (25 th percentile-75 th percentile)	5.8 (3.9–7.8)	4.1 (3.1–5.8)	6.2 (4.8–8.4)	< 0.001	
Score TMT part A, median (25 th percentile-75 th percentile)	49.5 (34.1–86.6)	69 (49.6–93.6)	44.7 (32.5–78.8)	< 0.001	
Score TMT part B, median (25 th percentile-75 th percentile)	96.7 (58.9–150)	158 (91.7–194.8)	94 (55.3–130.6)	0.130	
Score Short Story, median (25 th percentile-75 th percentile)	11.8 (8.7–14.1)	10.7 (6.8–13.2)	12 (9.4–14.7)	0.776	
Score ROCF immediate, median (25 th percentile-75 th percentile)	26.6 (18.1–30.8)	22.8 (11.8–31)	27 (19.7–30.6)	< 0.001	
Score ROCF recall, median (25 th percentile-75 th percentile)	11.3 (8.04–14.7)	8.04 (6.6–11.4)	11.9 (9.8–16.4)	< 0.001	
Score SDMT, median (25 th percentile-75 th percentile)	33.4 (26–39.9)	30.2 (25.3–34.5)	35.3 (28.3–43)	0.035	
Score Color Word Stroop Test, median (25 th percentile-75 th percentile)	26.3 (18.8–45.8)	32 (22–59.7)	24.7 (17.89–38.2)	< 0.001	
Score Visual Search [number of matrices], median (25 th percentile-75 th percentile)	32.6 (26–38.4)	29.1 (23.5–33.3)	33.7 (27.7–40.2)	0.028	
Score Phonemic Verbal fluency, median (25 th percentile-75 th percentile)	27.2 (21.5–34.4)	22.7 (20.2–31.3)	27.5 (23.5–35.6)	0.751	
Score Semantic Verbal Fluency, median (25 th percentile-75 th percentile)	34.5 (29.4–38.5)	30.2 (25.6–35.7)	35.5 (31.4–39.6)	< 0.001	
	Whole cohort (n. 110)	Converting patients (n. 32)	Non-converting (n. 78)	Shapiro-Wilk test in Whole group (n. 110), p value	Comparison Converting -Non converting (ANCOVA Analysis)
Total hippocampal volume mm ³ , median (25 th percentile-75 th percentile)	5091 (4457–5601)	4763 (4222.2–5294)	5269 (4575–5682)	0.604	0.015
Total lesion number mm ³ , median (25 th percentile-75 th percentile)	54.4 (40–78)	44.5 (33–75.2)	58 (41.5–78)	< 0.001	0.917
Total lesion volume mm ³ , median (25 th percentile-75 th percentile)	25,350 (15,876 –38995)	32,666 (16,716.5–48,748)	23,235 (15846–38,164.2)	< 0.001	0.119

*Refers to differences between converting and non-converting, and the normal data distribution. ANCOVA analysis with age, education, hippo_vol.*vs scaling (total WMLs volume and gender for total hippocampal volume evaluation) as covariate.

neuropsychological test scores, the same analysis with exclusion of the total WMLs volume variable was used to test the relation between ii) total hippocampal volume and WMLs characteristics (i.e., total lesion number and volume, lesion volume in selected white matter bundles), the adaptation of the models was evaluated by R².

Significance was set at $p < 0.05$ and Jamovi (<https://www.jamovi.org/>) were used to perform the analyses.

3. Results

3.1. Descriptive analysis

A total of 110 VMCI were identified with mean age [\pm SD]: 74.33 [\pm 6.63] years, 60 males/50 females, mean education [\pm SD]: 8.28 [\pm 4.24]. A normal distribution was respected for the total hippocampal volume and corrected scores of some neuropsychological tests (RAVLT immediate recall, TMT—B, Short story, visual search test, phonemic verbal fluency test), whereas the total volume of lesions, the number and

volume of lesions in the white matter bundles did not show a normal distribution (Table 1). At 24 months follow-up, 32/110 (29%) of VMCI converted to major-NCD.

3.2. Differences in imaging measures between converting and non-converting patients

At baseline, the total hippocampal volume of converting patients was lower than that of non-converting patients ($p = 0.015$, $F = 6.011$, $\eta^2 p = 0.056$) (Fig. 2).

There were no differences between the two groups in total WMLs number and volume (Table 1). In all cases, the correction for multiple comparisons did not alter the statistical significance. Lesions had a different distribution between the bundles of the white matter converting patients had a significantly higher lesion volume on the following bundles: posterior thalamic radiation ($p = 0.046$), splenium of corpus callosum ($p = 0.016$), cingulate gyrus ($p = 0.041$) and cingulum hippocampus ($p = 0.038$); the bundles mainly involved are reported in

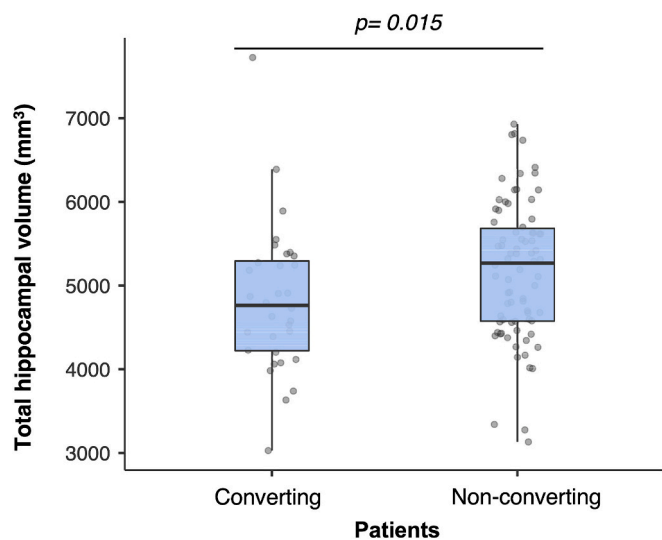


Fig. 2. The boxplots shows lower total hippocampal volume in the converting patient group compared to the non-covering patient group.

the Supplementary Table 1.

3.3. Correlations at baseline between imaging and clinical measures

The binomial logistic regression model was used to explore the predictive role of hippocampal atrophy. The model was found to be not significant ($X^2(7) = 13.612, p = 0.059$) without considering the total volume of WMLs (although hippocampal atrophy was a significant predictor: $\beta = -0.0007; SE = 0.0003, p = 0.030$), with a percentage of explained variance of 11%–16% in terms of probability of conversion probability in major-NCD. On the contrary, it was statistically significant ($X^2(8) = 16.555, p = 0.035$) when the total volume of WMLs was considered, with a percentage between 13%–20% the variance explained in terms of evolution in major-NCD, in this latter case hippocampal atrophy significantly predicted the conversion in major-NCD ($\beta = -0.0008; SE = 0.0003, p = 0.016$), albeit the total volume of WMLs was not a significant predictor ($\beta = 0.0000; SE = 0.0000, p = 0.090$).

For each selected white matter bundle, a linear regression model was created to investigate the predictive role of the volume of WMLs of the bundle itself; among these models, only four were significant: Posterior thalamic radiation model $X^2(8) = 19.356, p = 0.013$; cingulate gyrus model $X^2(8) = 18.9623, p = 0.015$; Splenium of corpus callosum model $X^2(8) = 18.686, p = 0.017$; Sagittal stratum model $X^2(8) = 19.208, p = 0.014$. In each model the volume of WMLs in posterior thalamic radiation ($\beta = 0.0004; SE = 0.0002, p = 0.020$), Splenium of corpus callosum ($\beta = 0.0008; SE = 0.0003, p = 0.028$); Cingulate gyrus ($\beta = 0.0561; SE = 0.0243, p = 0.021$), Sagittal stratum ($\beta = 0.0021; SE = 0.0009, p = 0.028$) significantly predicted the evolution in major-NCD.

Finally, we compared four binomial logistic regression models created with the predictors already mentioned in paragraph 2.4, more the progressive addition of the WMLs volume of the bundles of the previous analysis (model 1 with WMLs volume of posterior thalamic radiation, model 2 like model 1 plus WMLs volume of cingulate gyrus, model 3 like model 2 plus WMLs volume of Splenium of corpus callosum, model 4 like model 3 plus WMLs volume of Sagittal stratum), all four models were statistically significant to predict the conversion to major-NCD (all $p < 0.01$). When all predictors were considered: the model 4 ($X^2(11) = 29.04, p = 0.002$) explained a percent between 23 and 33% of variance in terms of probability of conversion in major-NCD; although from the model comparison analysis, there was no better statistically significant predictive capability of model 3 ($X^2(1) = 1.02, p = 0.313$) and model 4 ($X^2(1) = 0.43, p = 0.513$) than model 1–2 ($X^2(1) = 8.24, p = 0.004$). In the model 2 ($X^2(9) = 27.597, p = 0.001$) total

hippocampal volume ($\beta = -0.0010; SE = 0.0004, p = 0.004$), posterior thalamic radiation ($\beta = 0.0005; SE = 0.0002, p = 0.005$) and cingulate gyrus ($\beta = 0.0753 SE = 0.0269, p = 0.005$) were good predictors of evolution in major-NCD with a variance explained of 22–31% (Fig. 3). The model 2 showed a precision of 80%, specificity and sensitivity respectively of 81% and 74%, with an AUC (area under curve) of the ROC curve of 80% (Fig. 3).

From the analysis of association between total hippocampal volume and neuropsychological tests, a lower hippocampal volume was associated to worse performance in the RAVLT delayed recall ($\beta = 77.107, t = 2.943, p = 0.004, R^2 = 0.287$) and MMSE ($\beta = 74.698, t = 2.770, p = 0.007, R^2 = 0.281$) after adjusting for age, gender, MRI source, education, Vscaling and total WMLs volume (Fig. 4). Notably, there were no statistically significant correlations observed between: i) the total volume of WMLs and the total volume of the hippocampus ($\beta = 0.004, t = 1.301, p = 0.196, R^2 = 0.266$), or between the number of WMLs and the total volume of the hippocampus ($\beta = 3.627, t = -1.319, p = 0.190, R^2 = 0.227$). Similarly, no significant associations were found between the volume of lesions in any white matter bundle and the total volume of the hippocampus (all $p > 0.05$), except for the volume of WMLs in the fornix ($\beta = 19.461, t = 1.987, p = 0.050, R^2 = 0.243$). Additionally, there were no significant associations between the total lesion volume in any white matter bundle and neuropsychological test scores (all $p > 0.05$).

4. Discussion

In this work, we evaluated the role of hippocampal volume at baseline in patients converting to major-NCD versus those non-converting after 24 months, using an accurate hippocampal segmentation method and found that this can be related to cognitive impairment. The key findings are as follows: (i) VMCI patients with lower hippocampal volume at baseline and with higher lesion load on crucial bundles had a higher risk of progression to major-NCD over 24 months; (iii) at baseline, lower hippocampal volumes were linked to poorer performance on the RAVLT delayed recall and MMSE, (iv) hippocampal atrophy seems to be partially independent of WMLs characteristics and (v) the lesion volume of the WMLs in selected white matter bundles does not significantly affect the neuropsychological test scores.

These findings suggest that patients with VMCI who have smaller hippocampal volumes are at a heightened risk of developing major-NCD within a relatively short timeframe; and this risk seems in part significantly explained by a higher lesional load on crucial white matter connection bundles. This is in line with previous works showing that in non-demented participants hippocampal atrophy had a cumulative effect on the future level of cognitive decline [13,14] and that, in patient with VMCI, it is an MRI feature with good predictive value of transition into dementia [16]. One possible explanation for this association may arise from the vulnerability of the hippocampus, due to the specific gene and protein expression [29], to various stimuli (such as hypoxia and hypoperfusion) and risk factors (such as dyslipidemia, diabetes, metabolic syndrome, and hypertension) that may contribute to the development of hippocampal atrophy. This association is shared with AD [30,31], as well as secondary degeneration or subclinical ischemia [15]. In addition, the hippocampal vulnerability in our case, is supported by the association between a higher lesional load in the fornix and hippocampal atrophy, a hippocampal disconnection could mediate the symptomatology and facilitate neuronal loss [32,33].

Our predictive model became significantly predictive when in addition to hippocampal atrophy was also considered injury loads were placed on certain bundles. The destruction and dysfunction of some neuronal fibers of connection seem to have a particular role in clinical deterioration, and among them are the posterior thalamic radiation, cingulate gyrus, splenium of corpus callosum and the sagittal stratum. Destruction of thalamic connectivity has also been demonstrated in Alzheimer's disease [34] and has also been associated with cognitive vascular deterioration from atherosclerotic cerebrovascular disease and

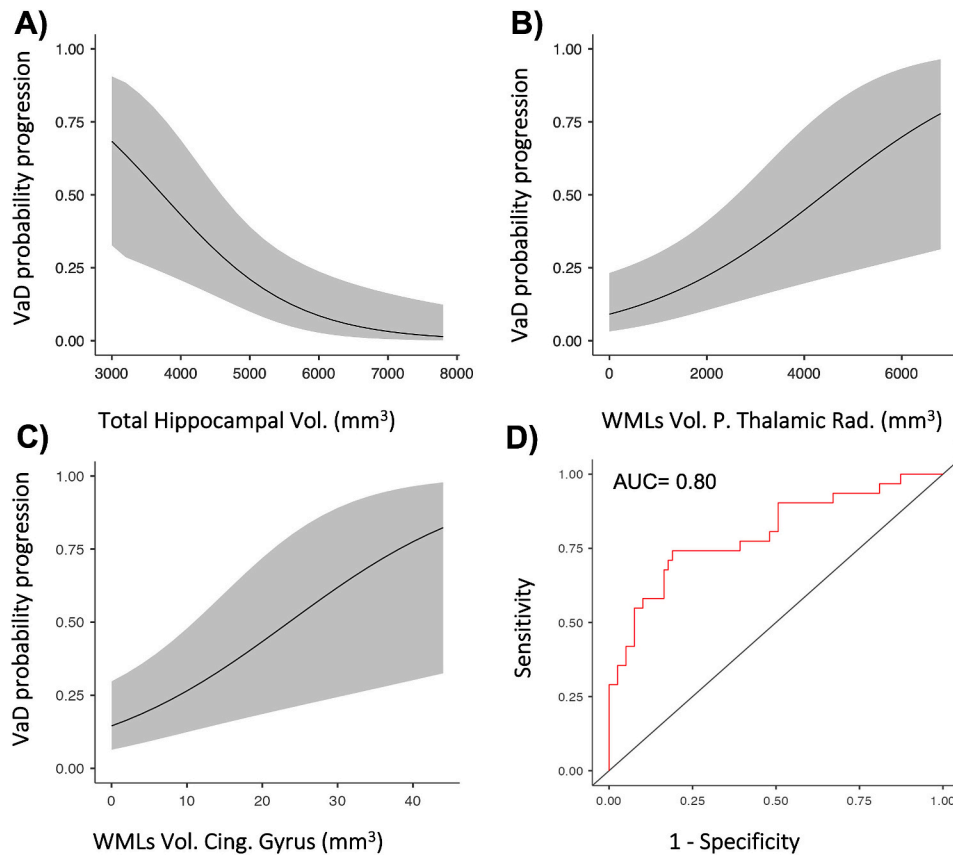


Fig. 3. Graphs of marginal averages and ROC curve showing: A) the relationship between the mean values of total hippocampal volume (mm^3) and the probability of progress in VaD/major-NCD, B) the relationship between the mean values of volume of WMLs on the posterior thalamic radiation and probability of progression in VaD/ major-NCD, C) the relationship between the average values of volume of WMLs on cingulate gyrus and probability of progression in VaD/ major-NCD, D) ROC curve with an AUC of 0.80 for Model 2, a binomial logistic regression model that considers total hippocampal volume (mm^3) along with total WML volume on the posterior thalamic radiation and the cingulate gyrus.

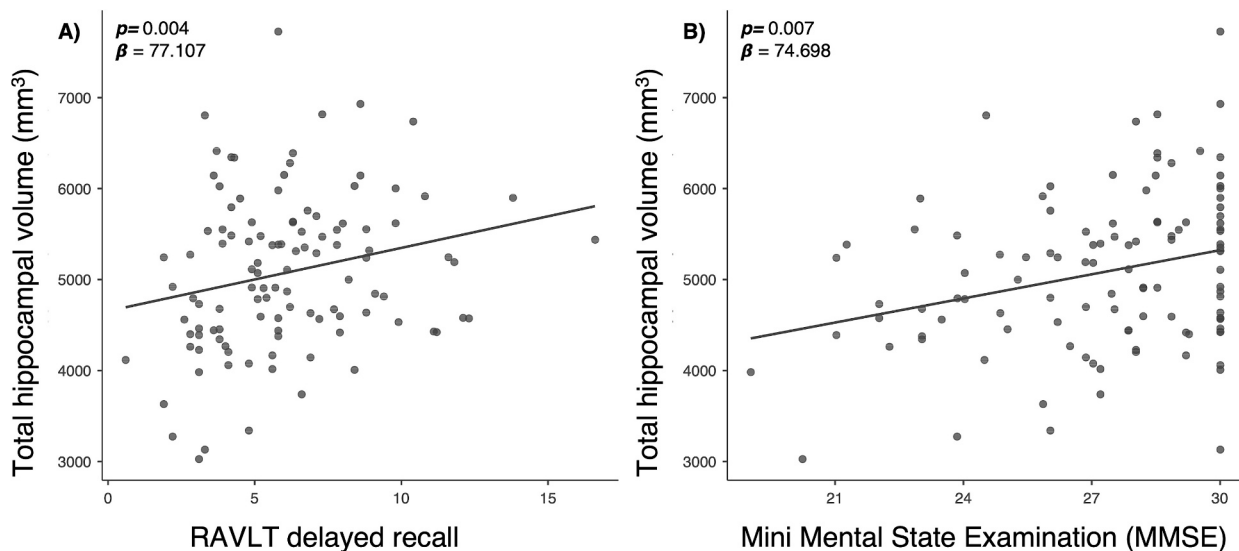


Fig. 4. Scatter plots showing significant association between neuropsychological test scores (RAVLT delayed recall, MMSE) and total hippocampal volume values in the whole group (A, B).

Moya Moya syndrome [35]. Other studies have shown that in vascular dementia the sites most frequently affected by lesions correspond to those found from our analyses and that make our model significantly predictive of conversion [36,37]. We can therefore say that the

hippocampal atrophy largely explains the conversion to a major-NCD, however the etiopathological mechanisms that underlie are complex and can be explained significantly, although not completely, also considered the role of white matter lesions.

The association between lower hippocampal volumes and poorer performance on the RAVLT delayed recall and MMSE found in our work is a critical observation. The RAVLT is one of the most used neuropsychological tests in clinical protocols for evaluating functions such as attention, short and long-term memory and learning ability in the auditory-verbal domain [38]. In a recent study on patients with subcortical ischemic vascular disease, subiculum and CA1 volumes were positively correlated with immediate memory and delayed memory scores on the RAVLT [19]. MMSE is a generic cognitive function assessment test, including the evaluation of spatial, temporal orientation, and memory in which the hippocampal plays a crucial role. The MMSE test has a specificity of 94% for converting MCI to dementia in general, and up to 80% for VaD [39]. This test is widely used to recognize cognitive impairment, enabling follow-up and predicting the progression of dementia [39]. Consistent with previous findings, our results align with the established connection between poorer performance on the MMSE and reduced hippocampal volumes observed in MCI, AD and subcortical ischemic vascular disease [15,40–42]. Importantly, the independence of hippocampal atrophy from total WMLs volume is an intriguing result. The significance of the volume and number of WMLs for the development of atrophy is still debated, concerning their impact on hippocampal atrophy [17,18,20,21,43–45]. It has been hypothesized that the amount of WMLs could be more relevant for the development of cortical gray matter atrophy instead, [15] since hippocampal atrophy is more likely driven by a distinct pathogenetic process, although in our case, there seems to be an association with the volume of WMLs on a certain bundle, specifically the fornix. In fact, it is known that stroke has an impact on the hippocampal volume homolaterally [46] and that some bundles would seem more important for hippocampal trophy (such as those in the cingulum bundle, the cingulate gyrus, uncinate fasciculus and the fornix) [47,48].

The results of our study can guide further research and may have useful implications for clinical practice. The use of hippocampal atrophy and the assessment of injuries on crucial bundles can serve as a valuable tool for identifying individuals with VMCI who are at a higher risk of progressing to VCI and early identification may enable healthcare professionals to offer appropriate and supportive interventions, such as proper management of risk factors, hence lifestyle change [49] and promote an appropriate follow-up.

However, this study is not without limitations. Firstly, it is important to note that, during patient recruitment, CSF biomarkers and amyloid PET scans were not routinely obtained as part of the diagnostic pathway, therefore, there was a risk of enrolling some patients with non-vascular neurodegenerative diseases. However, a high level of diagnostic accuracy was maintained by selecting patients from specialized centers with expertise in evaluating VCI. Secondly, the neuropsychological evaluation was incomplete for TMT part A and B tests for 47 patients, preventing exploration of their relationship with hippocampal involvement. While current data suggest an influence of WMLs on the scores of these tests, conducting targeted assessments with TMT in VCI patients could be beneficial for examining their predictive capability in the degenerative processes of the hippocampus [50]. Thirdly, the use of data collected in an already completed study has prevented the possibility of extending the clinical control time beyond two years.

In conclusion, our study provides new insights into the understanding of the relationship existing between hippocampal volume, WMLs characteristics and cognitive impairment in patients with VMCI. Further studies are warranted to better define the clinical and prognostic utility of hippocampal volume and WMLs assessment in the diagnostic phase of vascular cognitive disorders.

CRediT authorship contribution statement

Carlo Manco: Writing – review & editing, Writing – original draft, Methodology, Investigation, Formal analysis, Data curation, Conceptualization. **Rosa Cortese:** Writing – review & editing, Writing – original

draft, Supervision, Methodology, Data curation. **Matteo Leoncini:** Software, Resources, Methodology. **Giordano Gentile:** Supervision, Software. **Ludovico Luchetti:** Software. **Jian Zhang:** Data curation. **Ilaria Di Donato:** Visualization. **Emilia Salvadori:** Writing – review & editing, Resources, Methodology. **Anna Poggesi:** Resources. **Mirco Cosottini:** Visualization. **Mario Mascalchi:** Visualization. **Antonio Federico:** Visualization. **Maria Teresa Dotti:** Visualization. **Marco Battaglini:** Methodology, Data curation. **Domenico Inzitari:** Methodology, Data curation. **Leonardo Pantoni:** Writing – review & editing, Visualization, Validation, Project administration, Conceptualization. **Nicola De Stefano:** Writing – review & editing, Writing – original draft, Visualization, Validation, Project administration, Conceptualization.

Acknowledgements

The VMCI-Tuscany was funded by Tuscany Region Health Programme in the framework of the “Bando Regione Salute 2009”.

Appendix A. Supplementary data

Supplementary data to this article can be found online at <https://doi.org/10.1016/j.jns.2024.123163>.

References

- [1] E.E. Smith, Introduction to focused update vascular cognitive impairment and dementia: better diagnosis, more avenues for prevention, *Stroke* 55 (2024) 788–790, <https://doi.org/10.1161/STROKEAHA.124.046673>.
- [2] P. Sachdev, R. Kalara, J. O'Brien, I. Skoog, S. Alladi, S.E. Balck, D. Blacker, D. G. Blazer, C. Chen, H. Chui, M. Ganguli, K. Jellinger, D.V. Jeste, F. Pasquier, J. Paulsen, N. Prins, K. Rockwood, G. Roman, P. Scheltens, International Society for Vascular Behavioral and Cognitive Disorders, Diagnostic criteria for vascular cognitive disorders: a VASCOG statement, *Alzheimer Dis. Assoc. Disord.* 28 (2014) 206–218, <https://doi.org/10.1097/WAD.0000000000000034>.
- [3] X. Zhang, J. Su, C. Gao, W. Ni, X. Gao, Y. Li, J. Zhang, Y. Lei, Y. Gu, Progression in vascular cognitive impairment: pathogenesis, neuroimaging evaluation, and treatment, *Cell Transplant.* 28 (2019) 18–25, <https://doi.org/10.1177/0963689718815820>.
- [4] R.A. Whitmer, S. Sidney, J. Selby, S.C. Johnston, K. Yaffe, Midlife cardiovascular risk factors and risk of dementia in late life, *Neurology* 64 (2005) 277–281, <https://doi.org/10.1212/01.WNL.0000149519.47454.F2>.
- [5] B.V. Zlokovic, The blood-brain barrier in health and chronic neurodegenerative disorders, *Neuron* 57 (2008) 178–201, <https://doi.org/10.1016/J.NEURON.2008.01.003>.
- [6] L. Pantoni, Cerebral small vessel disease: from pathogenesis and clinical characteristics to therapeutic challenges, *Lancet Neurol.* 9 (2010) 689–701, [https://doi.org/10.1016/S1474-4422\(10\)70104-6](https://doi.org/10.1016/S1474-4422(10)70104-6).
- [7] O.A. Skrobot, S.E. Black, C. Chen, C. DeCarli, T. Erkinjuntti, G.A. Ford, R. N. Kalara, J. O'Brien, L. Pantoni, F. Pasquier, G.C. Roman, A. Wallin, P. Sachdev, I. Skoog, VICCS group, Y. Ben-Shlomo, A.P. Passmore, S. Love, P.G. Kehoe, Progress toward standardized diagnosis of vascular cognitive impairment: guidelines from the vascular impairment of cognition classification consensus study, *Alzheimer's Dement.* 14 (2018) 280–292, <https://doi.org/10.1016/j.jalz.2017.09.007>.
- [8] N.C. Yue, A.M. Arnold, W.T. Longstreth Jr., A.D. Elster, C.A. Jungreis, D. H. O'Leary, V.C. Poirier, R.N. Bryan, Sulcal, ventricular, and white matter changes at MR imaging in the aging brain: data from the cardiovascular health study, *Radiology* 202 (1997) 33–39, <https://doi.org/10.1148/RADIOLOGY.202.1.8988189>.
- [9] P. Scheltens, D. Leys, F. Barkhof, D. Huglo, H.C. Weinstein, P. Vermersch, M. Kuiper, M. Steinling, E.C. Wolters, J. Valk, Atrophy of medial temporal lobes on MRI in 'probable' Alzheimer's disease and normal ageing: diagnostic value and neuropsychological correlates, *J. Neurol. Neurosurg. Psychiatry* 55 (1992) 967–972, <https://doi.org/10.1136/JNPP.55.10.967>.
- [10] L.O. Wahlund, F. Barkhof, F. Fazekas, L. Bronge, M. Augustin, M. Sjögren, A. Wallin, H. Ader, D. Leys, L. Pantoni, F. Pasquier, T. Erkinjuntti, P. Scheltens, European Task Force on Age-Related White Matter Changes, A new rating scale for age-related white matter changes applicable to MRI and CT, *Stroke* 32 (2001) 1318–1322, <https://doi.org/10.1161/01.STR.32.6.1318>.
- [11] N. Dolek, S. Saylisoy, D. Ozbabalik, B. Adapinar, Comparison of hippocampal volume measured using magnetic resonance imaging in Alzheimer's disease, vascular dementia, mild cognitive impairment and pseudodementia, *J. Int. Med. Res.* 40 (2012) 717–725, <https://doi.org/10.1177/147323001204000236>.
- [12] A. Giorgio, I.D. Donato, A.D. Leucio, J. Zhang, E. Salvadori, A. Poggesi, S. Diciotti, M. Cosottini, S. Ciulli, D. Inzitari, L. Pantoni, M. Mascalchi, A. Federico, M.T. Dotti, N. De Stefano, VMCI-Tuscany Study Group, Relevance of brain lesion location for cognition in vascular mild cognitive impairment, *Neuroimage Clin.* 22 (2019) 101789, <https://doi.org/10.1016/j.nicl.2019.101789>.

- [13] H. Jokinen, J. Koikkalainen, H.M. Laakso, S. Melkas, T. Nieminen, A. Brander, A. Korvenoja, D. Rueckert, F. Barkhof, P. Scheltens, R. Schmidt, F. Fazekas, S. Madureira, A. Verdelho, A. Wallin, L. Wahlund, G. Waldemar, H. Chabriat, M. Hennerici, J. O'Brien, D. Inzitari, J. Lötjönen, L. Pantoni, T. Erkinjuntti, Global burden of small vessel disease-related brain changes on MRI predicts cognitive and functional decline, *Stroke* 51 (2020) 170–178, <https://doi.org/10.1161/STROKEAHA.119.026170>.
- [14] O. Godin, C. Tzourio, O. Rouaud, Y. Zhu, P. Maillard, F. Pasquier, F. Crivello, A. Alperovitch, B. Mazoyer, C. Dufouil, Joint effect of white matter lesions and hippocampal volumes on severity of cognitive decline: the 3C-Dijon MRI study, *J. Alzheimers Dis.* 20 (2010) 453–463, <https://doi.org/10.3233/JAD-2010-1389>.
- [15] G. Fein, V. Di Sclafani, J. Tanabe, V. Cardenas, M.W. Weiner, W.J. Jagust, B. R. Reed, D. Norman, N. Schuff, L. Kusdra, T. Greenfield, H. Chui, Hippocampal and cortical atrophy predict dementia in subcortical ischemic vascular disease, *Neurology* 55 (2000) 1626–1635, <https://doi.org/10.1212/WNL.55.11.1626>.
- [16] C. Marzi, R. Scheda, E. Salvadori, A. Giorgio, N. De Stefano, A. Poggesi, D. Inzitari, L. Pantoni, M. Mascalchi, S. Diciotti, Fractal dimension of the cortical gray matter outweighs other brain MRI features as a predictor of transition to dementia in patients with mild cognitive impairment and leukoariosis, *Front. Hum. Neurosci.* 17 (2023) 1231513, <https://doi.org/10.3389/FNHUM.2023.1231513>.
- [17] C. Eckerström, E. Olsson, N. Klasson, M. Bjerke, M. Göthlin, M. Jonsson, S. Rolstad, H. Malmgren, A. Wallin, A. Edman, High white matter lesion load is associated with hippocampal atrophy in mild cognitive impairment, *Dement. Geriatr. Cogn. Disord.* 31 (2011) 132–138, <https://doi.org/10.1159/000323014>.
- [18] M. O'Sullivan, E. Ngo, A. Viswanathan, E. Jouvett, A. Gschwendtner, P. G. Saemann, M. Duering, C. Pachai, M.-G. Boussier, H. Chabriat, M. Dichgans, Hippocampal volume is an independent predictor of cognitive performance in CADASIL, *Neurobiol. Aging* 30 (2009) 890–897, <https://doi.org/10.1016/j.neurobiolaging.2007.09.002>.
- [19] M. He, Y. Li, L. Zhou, Y. Li, T. Lei, W. Yan, J. Song, L. Chen, Relationships between memory impairments and hippocampal structure in patients with subcortical ischemic vascular disease, *Front. Aging Neurosci.* 14 (2022) 823535, <https://doi.org/10.3389/FNAGI.2022.823535>.
- [20] A.G.W. Van Norden, W.F. Fick, K.F. de Laat, I.W.M. van Uden, L.J.B. van Oudheusden, I. Tendolkar, M.P. Zwiers, F.E. de Leeuw, Subjective cognitive failures and hippocampal volume in elderly with white matter lesions 71 (2008) 1152–1159, <https://doi.org/10.1212/01.wnl.0000327564.44819.49>.
- [21] C.M. Fjorid, E.N. Manning, J.W. Bartlett, D.M. Cash, I.B. Malone, G.R. Ridgway, M. Lehmann, K.K. Leung, C.H. Sudre, S. Ourselin, G.J. Biessels, O.T. Carmichael, N. C. Fox, M.J. Cardoso, J. Barnes, Alzheimer's Disease Neuroimaging Initiative, White matter hyperintensities are associated with disproportionate progressive hippocampal atrophy, *Hippocampus* 27 (2017) 249–262, <https://doi.org/10.1002/hipo.22690>.
- [22] A. Poggesi, E. Salvadori, L. Pantoni, G. Pracucci, F. Cesari, A. Chiti, L. Ciolli, M. Cosottini, A. Del Bene, N. De Stefano, S. Diciotti, M.T. Dotti, A. Ginestroni, B. Giusti, A.M. Gori, S. Nannucci, G. Orlandi, F. Pescini, R. Valentini, R. Abbate, A. Federico, M. Mascalchi, L. Murri, D. Inzitari, Risk and determinants of dementia in patients with mild cognitive impairment and brain subcortical vascular changes: a study of clinical, neuroimaging, and biological markers—the VMCI-Tuscany study: rationale, design, and methodology, *Int. J. Alzheimers Dis.* 2012 (2012) 608013, <https://doi.org/10.1155/2012/608013>.
- [23] B. Winblad, K. Palmer, M. Kivipelto, V. Jelic, L. Fratiglioni, L.-O. Wahlund, A. Nordberg, L. Bäckman, M. Albert, O. Almkvist, H. Arai, H. Basun, K. Blennow, M. de Leon, C. DeCarli, T. Erkinjuntti, E. Giacobini, C. Graff, J. Hardy, C. Jack, A. Jorm, K. Ritchie, C. van Duijn, P. Visser, R.C. Petersen, Mild cognitive impairment—beyond controversies, towards a consensus: report of the International Working Group on Mild Cognitive Impairment, *J. Intern. Med.* 256 (2004) 240–246, <https://doi.org/10.1111/J.1365-2796.2004.01380.X>.
- [24] E. Salvadori, A. Poggesi, R. Valentini, G. Pracucci, F. Pescini, M. Pasi, S. Nannucci, S. Marini, A. Del Bene, L. Ciolli, A. Ginestroni, S. Diciotti, G. Orlandi, I. Di Donato, N. De Stefano, M. Cosottini, A. Chiti, A. Federico, M. Teresa Dotti, U. Bonuccelli, D. Inzitari, L. Pantoni, VMCI-Tuscany Study Group, Operationalizing mild cognitive impairment criteria in small vessel disease: the VMCI-Tuscany Study, *Alzheimers Dement.* 12 (2016) 407–418, <https://doi.org/10.1016/J.JALZ.2015.02.010>.
- [25] E. Salvadori, A. Poggesi, G. Pracucci, D. Inzitari, L. Pantoni, VMCI-Tuscany Study Group, Development and psychometric properties of a neuropsychological battery for mild cognitive impairment with small vessel disease: the VMCI-Tuscany Study, *J. Alzheimers Dis.* 43 (2015) 1313–1323, <https://doi.org/10.3233/JAD-141449>.
- [26] A. Zandifar, V.S. Fonov, J.C. Pruessner, D.L. Collins, Alzheimer's Disease Neuroimaging Initiative, The EADC-ADNI harmonized protocol for hippocampal segmentation: A validation study, *Neuroimage* 181 (2018) 142–148, <https://doi.org/10.1016/J.NEUROIMAGE.2018.06.077>.
- [27] L. Luchetti, G. Gentile, M. Battaglini, A. Giorgio, N. De Stefano, SIENAX2.0, an update of SIENAX tool for cross sectional brain volumes assessment, in: AIRMM (Italian Association of Magnetic Resonance Imaging in Medicine) CONGRESS, 2019 <https://bvent.biomedica.net/evento/programma>.
- [28] E. Salvadori, A. Poggesi, G. Pracucci, A. Chiti, L. Ciolli, M. Cosottini, A. Del Bene, N. De Stefano, S. Diciotti, I. Di Donato, A. Ginestroni, S. Marini, M. Mascalchi, S. Nannucci, G. Orlandi, M. Pasi, F. Pescini, R. Valentini, A. Federico, M.T. Dotti, U. Bonuccelli, D. Inzitari, L. Pantoni, VMCI-Tuscany Study Group, Application of the DSM-5 Criteria for Major Neurocognitive Disorder to Vascular MCI Patients, *Dement. Geriatr. Cogn. Dis. Extra.* 8 (2018) 104–116, <https://doi.org/10.1159/000487130>.
- [29] R. Schmidt-Kastner, Genomic approach to selective vulnerability of the hippocampus in brain ischemia-hypoxia, *Neuroscience* 309 (2015) 259–279, <https://doi.org/10.1016/J.NEUROSCIENCE.2015.08.034>.
- [30] H.M.A. Abraham, L. Wolfson, N. Moscufo, C.R.G. Guttmann, R.F. Kaplan, W. B. White, Cardiovascular risk factors and small vessel disease of the brain: blood pressure, white matter lesions, and functional decline in older persons, *J. Cereb. Blood Flow Metab.* 36 (2016) 132–142, <https://doi.org/10.1038/JCBFM.2015.121>.
- [31] V. Dhikav, K. Anand, Potential predictors of hippocampal atrophy in Alzheimer's disease, *Drugs Aging* 28 (2011) 1–11, <https://doi.org/10.2165/11586390-000000000-00000>.
- [32] L.E.M. Wisse, Y.D. Reijmer, A. ter Telgte, H.J. Kuijf, A. Leemans, P.R. Luijten, H. L. Koek, M.I. Geerlings, G. Jan Biessels, Utrecht Vascular Cognitive Impairment (VCI) Study Group, Hippocampal disconnection in early Alzheimer's disease: a 7 tesla MRI study, *J. Alzheimers Dis.* 45 (2015) 1247–1256, <https://doi.org/10.3233/JAD-142994>.
- [33] P. Srisaikaew, N. Wongpakaran, N.D. Anderson, J.J. Chen, S. Kothan, P. Varnado, K. Unsrison, P. Mahakkanukrauh, Fornix integrity is differently associated with cognition in healthy aging and non-amnesic mild cognitive impairment: a pilot diffusion tensor imaging study in Thai older adults, *Front. Aging Neurosci.* 12 (2020) 594002, <https://doi.org/10.3389/FNAGI.2020.594002>.
- [34] Q.Y. Zhu, S. Bi, X.T. Yao, Z.-Y. Ni, Y. Li, B.-Y. Chen, G.-G. Fan, X.-L. Shang, Disruption of thalamic connectivity in Alzheimer's disease: a diffusion tensor imaging study, *Metab. Brain Dis.* 30 (2015) 1295–1308, <https://doi.org/10.1007/S11011-015-9708-7>.
- [35] J. Bin Su, S.-D. Xi, S.-Y. Zhou, X. Zhang, S.-H. Jiang, B. Xu, L. Chen, Y. Lei, C. Gao, Y.-X. Gu, Microstructural damage pattern of vascular cognitive impairment: a comparison between moyamoya disease and cerebrovascular atherosclerotic disease, *Neural Regen. Res.* 14 (2019) 858–867, <https://doi.org/10.4103/1673-5374.249234>.
- [36] F. Palesi, A. De Rinaldis, P. Vitali, G. Castellazzi, L. Casiraghi, G. Germani, S. Bernini, N. Anzalone, M.C. Ramusino, F.M. Denaro, E. Sinfiorani, A. Costa, G. Magenes, E. D'Angelo, C.A.M. Gandini Wheeler-Kingshott, G. Miceli, Specific patterns of White matter alterations help distinguishing Alzheimer's and vascular dementia, *Front. Neurosci.* 12 (2018) 274, <https://doi.org/10.3389/FNINS.2018.00274>.
- [37] H. Tohgi, Vascular dementia, *Tohoku J. Exp. Med.* 161 (1990) 39–47, <https://doi.org/10.1620/TJEM.161.SUPPLEMENT.39>.
- [38] D. Putcha, M. Brickhouse, D.A. Wolk, B.C. Dickerson, Alzheimer's Disease Neuroimaging Initiative, Fractionating the Rey Auditory Verbal Learning Test: Distinct roles of large-scale cortical networks in prodromal Alzheimer's disease, *Neuropsychologia* 129 (2019) 83–92, <https://doi.org/10.1016/j.neuropsychologia.2019.03.015>.
- [39] I. Arevalo-Rodriguez, N. Smailagic, M.R.L. Figuls, A. Ciapponi, E. Sanchez-Perez, A. Giannakou, O.L. Pedraza, X.B. Cosp, S. Cullum, Mini-Mental State Examination (MMSE) for the detection of Alzheimer's disease and other dementias in people with mild cognitive impairment (MCI), *Cochrane Database Syst. Rev.* 2015 (2015) CD010783, <https://doi.org/10.1002/14651858.CD010783.PUB2>.
- [40] G.P. Peng, Z. Feng, F.-P. He, Z.-Q. Chen, X.-Y. Liu, P. Liu, B.-Y. Luo, Correlation of hippocampal volume and cognitive performances in patients with either mild cognitive impairment or Alzheimer's disease, *CNS Neurosci. Ther.* 21 (2015) 15–22, <https://doi.org/10.1111/CNS.12317>.
- [41] N. Legdure, P.J. Visser, D.C. Woodworth, M. Muller, E. Fletcher, P. Maillard, P. Scheltens, C. DeCarli, C.H. Kawas, M.M. Corrada, White matter Hyperintensities and hippocampal atrophy in relation to cognition: the 90+ study, *J. Am. Geriatr. Soc.* 67 (2019) 1827–1834, <https://doi.org/10.1111/JGS.15990>.
- [42] D.C. Steffens, M.E. Payne, D.L. Greenberg, C.E. Byrum, K.A. Welsh-Bohmer, H. R. Wagner, J.R. MacFall, Hippocampal volume and incident dementia in geriatric depression, *Am. J. Geriatr. Psychiatr.* 10 (2002) 62–71, <https://doi.org/10.1097/00019442-200201000-00008>.
- [43] F.C.C. Wong, C. Yatawara, A. Low, H. Foo, B.Y.X. Wong, L. Lim, B. Wang, D. Kuma, K.P. Ng, N. Kandiah, Cerebral small vessel disease influences hippocampal subfield atrophy in mild cognitive impairment, *Transl. Stroke Res.* 12 (2021) 284–292, <https://doi.org/10.1007/s12975-020-00847-4>.
- [44] R.L. Nosheny, P.S. Insel, D. Truran, N. Schuff, C.R. Jack Jr., P.S. Aisen, L.M. Shaw, J.Q. Trojanowski, M.W. Weiner, Alzheimer's Disease Neuroimaging Initiative, Variables associated with hippocampal atrophy rate in normal aging and Mild Cognitive Impairment, *Neurobiol. Aging* 36 (2015) 273, <https://doi.org/10.1016/J.NEUROBIOLAGING.2014.07.036>.
- [45] Y. Sun, H.Y. Hu, H. Hu, L.Y. Huang, L. Tan, J.T. Yu, Alzheimer's Disease Neuroimaging Initiative, Cerebral small vessel disease burden predicts neurodegeneration and clinical progression in prodromal Alzheimer's disease, *J. Alzheimers Dis.* 93 (2023) 283–294, <https://doi.org/10.3233/JAD-221207>.
- [46] E.B. Aamodt, S. Lydersen, D. Alnæs, T. Schellhorn, I. Saltvedt, M.K. Beyer, A. Håberg, Longitudinal brain changes after stroke and the association with cognitive decline, *Front. Neurol.* 13 (2022) 856919, <https://doi.org/10.3389/FNEUR.2022.856919>.
- [47] F. Rémy, N. Vayssière, L. Saint-Aubert, E. Barbeau, J. Pariente, White matter disruption at the prodromal stage of Alzheimer's disease: relationships with hippocampal atrophy and episodic memory performance, *Neuroimage Clin.* 7 (2015) 482–492, <https://doi.org/10.1016/J.NICL.2015.01.014>.
- [48] N. Villain, B. Desgranges, F. Viader, V. de la Sayette, F. Mézenge, B. Landeau, J. C. Baron, F. Eustache, G. Chételat, Relationships between hippocampal atrophy, white matter disruption, and gray matter hypometabolism in Alzheimer's disease,

- J. Neurosci. 28 (2008) 6174–6181, <https://doi.org/10.1523/JNEUROSCI.1392-08.2008>.
- [49] S. Jongsiriyanyong, P. Limpawattana, Mild cognitive impairment in clinical practice: a review article, *Am. J. Alzheimers Dis. Other Dement.* 33 (2018) 500–507, <https://doi.org/10.1177/1533317518791401>.
- [50] J.M. Boomsma, L.G. Exalto, F. Barkhof, A.E. Leeuwis, N.D. Prins, P. Scheltens, C. E. Teunissen, H.C. Weinstein, G.J. Biessels, W.M. van der Flier, On-Behalf-Of-The-Trace-Vci-Study-Group 1, Vascular Cognitive Impairment and cognitive decline; a longitudinal study comparing different types of vascular brain injury - The TRACE-VCI study, *Cereb. Circ. Cogn. Behav.* 3 (2022), <https://doi.org/10.1016/J.CCCB.2022.100141>.