

# Do we need imaging to diagnose appendicitis in children?

Antonio Di Cesare, Filippo Parolini, Anna Morandi, Ernesto Leva, Maurizio Torricelli

Access this article online

Website:  
www.afripaedsurg.org

DOI:  
10.4103/0189-6725.115024

Quick Response Code:



## ABSTRACT

**Background:** To evaluate the role of clinical assessment with selective use of imaging studies in the management of suspected acute appendicitis in children. **Patients and Methods:** Medical records of children referred to Emergency Room in 2010 for suspected appendicitis were retrospectively reviewed. Diagnostic investigations divided by age and sex were related to pathological findings. Negative appendectomy and complication rates were calculated. **Results:** 923 children needed surgical assessment: In 75.7% of them surgical indication was excluded and 24.3% were admitted to surgical ward for observation. Appendectomy was eventually performed in 137 patients (61.9%), 82.4% of them without any preoperative imaging while 17.6% underwent selective studies, mainly abdominal ultrasonography (14.6%). Imaging was requested twice as frequently in not operated admitted children (39.3%) than in the operated ones (17.5%,  $P < 0.001$ ). Overall complicated appendicitis rate (peritonitis and abscess) resulted 26.4% and negative appendectomy rate 8.8%. Females older than 10 years presented histologically not-confirmed appendicitis in 22.2% of cases, while the younger ones presented more frequently complicated appendicitis (29.3%). **Conclusions:** Clinical assessment is the key to diagnose appendicitis. Nevertheless, in girls older than 10 years, selected use of imaging should be implemented to avoid unnecessary appendectomies. Imaging of choice in equivocal cases should be ultrasonography.

**Key Words:** Appendicitis, children, computed tomography, negative appendectomy rate, ultrasonography

## INTRODUCTION

Acute appendicitis (AA) is the condition that most commonly requires urgent abdominal surgery in the paediatric population.<sup>[1,2]</sup> Abdominal pain is indeed one of the most common symptoms that leads children to medical attention at emergency department, even if appendicitis is ultimately diagnosed only in 2% of them.<sup>[3,4]</sup> Diagnosis of appendicitis may represent a challenge for both paediatricians and paediatric surgeons, particularly in patients younger than four.<sup>[2,5-7]</sup> On the one hand, early diagnosis and surgery of AA can prevent complications, on the other equivocal presentation of AA implies risk of misdiagnosis, thus, requiring diagnostic imaging studies with consequent delayed definitive surgical treatment.<sup>[5,8]</sup> In this study, we present the results of our clinical-evaluation based, which allows to discriminate children that should undergo immediate surgical evaluation for potential appendectomy and those with equivocal presentations that may benefit from further diagnostic imaging studies.

## PATIENTS AND METHODS

This retrospective review was based on medical records of paediatric patients (0-18 years of age) referred to Emergency Room (ER) or admitted to the surgical ward for suspected appendicitis with admission date between January 1, 2010, and December 31, 2010. We restricted the retrospective analysis to patients who had both an ICD-9-CM (International Classification of Diseases, Ninth Revision–Clinical Modification) admission diagnosis code of abdominal pain (789.x, 543.9) or suspected appendicitis (540, 541, 542) and ICD-9-CM procedure code of appendectomy (47.01, 47.09, 47.2 × 47.99) during the same hospital stay. Incidental appendectomy were excluded from this study. Unique patient identifiers were used to guarantee that each child had been included in the population only once.

Antibiotics are not used unless a definitive diagnosis has been reached or a severe infection is clearly

Department of Pediatric Surgery, Fondazione IRCCS Ca 'Granda–Ospedale Maggiore Policlinico Milano, Italy

**Address for correspondence:**

Dr. Antonio Di Cesare,  
Department of Pediatric Surgery,  
Fondazione IRCCS Ca 'Granda – Ospedale Maggiore Policlinico,  
Milano, Italy.  
E-mail: articles.chped@gmail.com

suspected. All patients had their full blood count with differential white cell count and C-reactive protein level determined. Some patients underwent radiologic imaging ((Ultrasound scan [US], Computed tomography [CT] scan, abdominal X-ray, upper gastrointestinal contrast imaging) when the clinical diagnosis was equivocal, otherwise the diagnosis of appendicitis was basically clinical. Appendectomies were performed by the senior surgeons in the department. Postoperatively, the reports of the radiologic investigations of each case were related to the post-operative findings and histopathological reports. Imaging rate was defined as the total number of patients that underwent at least one imaging examinations. Negative appendectomy rate was defined as the total number of normal appendices identified at histopathological examination over all performed appendectomies. Complicated acute appendicitis (AA) rate was defined as the number of both perforated appendices identified at histopathology and appendiceal abscesses at surgery, over all cases of appendicitis. In all patients, who underwent surgery the negative appendectomy rate and the appendiceal complication rate were calculated and compared to those reported in recent literature on the topic. To assess whether there were variations of diagnostic investigations or pathological findings due to age or sex, all children were divided into 3 groups for each gender: Younger than 4 years (group A = male or A1=female), 4-10 years old (group B = male or B1=female), and over 10 years (group C = male or C1=female).

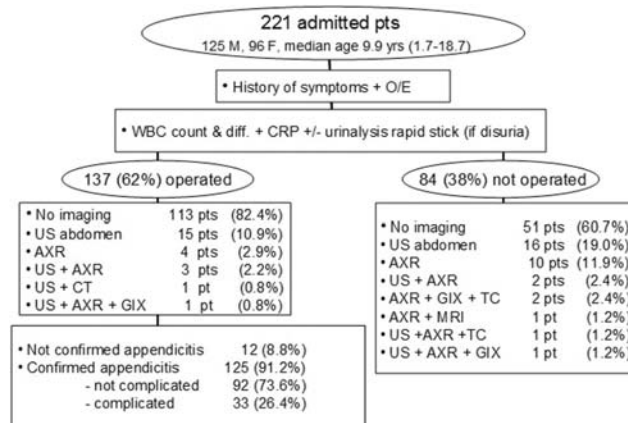
**Statistical analysis**

The data were analyzed using descriptive statistics. Personal characteristics of the population were compared between males and females and age groups by using two-tailed Fischer’s exact probability test for dichotomous variables (gender, imaging exams, complications, and histologically confirmed AA rates) and *t*-test for continuous variables (age, length of stay [LOS]). The adopted level of significance was *P* value < 0.01.

**RESULTS**

During 2010 in our institutional, ER 2772 children (age 0-18 years) were evaluated for abdominal pain. Among them, 1849 patients (67%) were fully managed and eventually discharged by ER paediatricians with no need of surgical counselling, while for the remaining 923 patients (33%) a surgical assessment was required. In 75.7% of all children assessed by the surgeon (699 cases) a surgical condition was excluded, however, for the remaining 221 cases (24.3%) a decision was taken

to admit the child to the surgical ward for suspected appendicitis [Figure 1]. A summary of outcomes and imaging used in the study series is reported in Tables 1 and 2. Of these patients, 125 (56.6%) were males, and 96 (43.4%) were females. Mean age was 10.4 years. Females resulted more liable to abdominal pain (*P* = 0.025), both in patients’ group that finally underwent appendectomy (*P* = 0.038) and in not operated one (*P* = 0.008). A comparison of population variables between males and females is given in Table 3. Eighty-four of these patients (38%) didn’t under-go any operation, because a surgical condition was finally excluded during the time of in-hospital observation, 51 (60.7%) of them without requiring any imaging studies [Figure 1]. The remaining 33 patients (39.3%) required imaging studies before definitive surgical discharge without operation: US alone was the most required study (16/84, 19% of cases). To our knowledge, none of these children ended up with appendicitis later on. Appendectomy was finally performed in 137/221 patients (62% of cases). Within male groups surgery was undertaken more frequently in group C rather than group B (*P* < 0.001) and in group B rather than group A (*P* < 0.001) [Table 4]. Pathological findings showed that 33 patients had a complicated AA (complication rate 26.4%). Complicated AA was more common in female groups A1 and B1 rather than C1 (*P* = 0.03 and *P* = 0.001 respectively) [Table 5]. Ninety-two patients (73.6%) had the inflamed appendix removed before perforation. In 12 patients (8.8%) appendicitis was not confirmed at histopathology. This event in both males and females appears to increase in older age classes, although, not in a statistically significant way. In particular, the number of unnecessary appendectomies in the subgroup of females older than 10 years of age (Group C1) accounted for more than 66% of the total (8/12). However, in one of these patients a carcinoid tumor at initial stage was found and surgically removed;



**Figure 1:** O/E: Objective examination; WBC: White blood cells; C-reactive protein; abdominal X-ray; Magnetic Resonance Imaging; gastrointestinal X-ray (contrast) study

**Table 1: Summary of outcomes in the study series**

	Total	Male	Female	Male 0-3 (A)	Male 4-9 (B)	Male 10+ (C)	Female 0-3 (A1)	Female 4-9 (B1)	Female 10+ (C1)
No. (%)	221	125 (56.6)	96 (43.4)	3 (2.4)	67 (53.6)	55 (44)	6 (6.3)	35 (36.4)	55 (57.3)
Non-op	84 (38)	46 (36.8)	38 (39.6)	3 (100)	34 (50.7)	9 (16.4)	1 (16.7)	18 (51.4)	19 (34.5)
Operated	137 (62)	79 (63.2)	58 (60.4)	0	33 (49.3)	46 (83.6)	5 (83.3)	17 (48.6)	36 (65.5)
Not confirmed	12 (8.8)	3 (3.8)	9 (15.5)	0	0	3 (6.5)	0	1 (5.9)	8 (22.2)
Confirmed	125 (91.2)	76 (96.2)	49 (84.5)	0	33 (100)	43 (93.5)	5 (100)	16 (94.1)	28 (77.8)
Non-complicated	92 (73.6)	58 (76.3)	34 (69.4)	0	28 (84.8)	30 (69.8)	2 (40)	7 (43.8)	25 (89.3)
Complicated	33 (26.4)	18 (23.7)	15 (30.6)	0	5 (15.2)	13 (30.2)	3 (60)	9 (56.2)	3 (10.7)

**Table 2: Summary of imaging used in the study series**

	No imaging (%)	Imaging (%)	U/S (%)	Rx (%)	GIX (%)	CT (%)	MR (%)
Total (221)	164 (74.2)	57 (25.8)	40 (18.1)	25 (11.3)	4 (1.8)	4 (1.8)	1 (0.5)
Male (125)	97 (77.6)	28 (22.4)	20 (16)	13 (10.4)	4 (3.2)	2 (1.6)	0
Female (96)	67 (69.8)	29 (30.2)	20 (20.8)	12 (12.5)	0	2 (2.1)	1 (1)
A (Male 0-3) (3)	1 (33.3)	2 (66.7)	0	2 (66.7)	0	0	0
B (Male 4-9) (67)	52 (77.6)	15 (22.4)	9 (13.4)	6 (9)	3 (4.5)	2 (3)	0
C (Male 10+) (56)	44 (78.6)	11 (19.6)	10 (17.9)	5 (8.9)	1 (1.8)	0	0
A1 (Female 0-3) (6)	4 (66.7)	2 (33.3)	2 (33.3)	1 (16.7)	0	2 (33.3)	0
B1 (Female 4-9) (35)	23 (65.7)	12 (34.3)	9 (25.7)	5 (14.3)	0	0	1 (2.9)
C (Female 10+) (55)	40 (72.7)	15 (27.3)	9 (16.4)	6 (10.9)	0	0	0
Operated (137)	113 (82.5)	24 (17.5)	20 (14.6)	8 (5.8)	1 (0.7)	1 (0.7)	0
Non-operated (84)	51 (60.7)	33 (39.3)	20 (23.8)	17 (20.2)	3 (3.5)	3 (3.5)	1 (1.2)
Confirmed (125)	103 (82.4)	22 (17.6)	18 (14.4)	7 (5.6)	1 (0.8)	0	0
Not confirmed (12)	10 (83.3)	2 (16.7)	2 (16.7)	1 (8.3)	1 (8.3)	0	0

RX: abdominal X-ray; GIX: gastrointestinal contrast study; CT: computed tomography scan ; MR: magnetic resonance

**Table 3: Statistics between genders**

	Males (n = 125)	Females (n = 96)	P value
Age, mean±SD, year	8.94 ± 3.38	11.25 ± 4.16	0.025*
Not surgery age, mean±SD, year	7.60 ± 3.03	11.16 ± 4.00	0.008*
Surgery Age, mean±SD, year	10.78 ± 3.00	11.09 ± 4.29	0.038*
Surgery, n (%)	79 (47.2)	58 (60.4)	0.68°
Complicated, n (%)	18 (23.7)	15 (30.6)	0.41°
Histologically confirmed AA, n (%)	76 (96.2)	49 (84.5)	0.03°
Total LOS, mean±SD, days	3.74 ± 1.89	4.88 ± 5.75	0.18*

LOS: Length of stay; AA: Acute appendicitis; \* t Student test; °: two-tailed Fisher exact probability test.

the tumor was not diagnosed pre-operatively. In 113 patients (82.4%) no pre-operative imaging was carried out, while in 24 (17.6%) at least a selective study was performed, mainly abdominal US [Figure 1, Table 2]. The use of imaging in children who weren't finally operated resulted twice than in the operated group (39.3% vs. 17.5%,  $P < 0.001$ ) [Table 6]. No statistically significant differences in use of imaging were recorded between age-matched male and female groups [Table 7]. The LOS progressively decreased with increasing age,

**Table 4: Statistics in males**

	A (0-3 year)	B (4-9 year)	C (10+ year)	P value#
No. (%)	3 (2.4)	67 (53.6)	55 (44)	NA
Surgery (%)	0	33 (49.3)	46 (83.6)	A-B: <.001 A-C: .007 BC: <.001
Complicated (%)	0	5 (15.2)	13 (30.2)	A-B: 1 A-C: 1 B-C: .17
Histologically confirmed AA (%)	0	33 (100)	43 (93.5)	A-B: 1 A-C: 1 B-C: .26
Imaging (%)	2 (66.7)	15 (22.4)	11 (19.6)	A-B: .14 A-C: .12 B-C: .83

#Two-tailed Fisher exact probability test

both for females and males; this difference, however, was not statistically significant.

## DISCUSSION

AA is the most common surgical urgency in children (0-18 years), with a developing lifespan risk of 8.6% in males and 6.7% in females.<sup>[9]</sup> The yearly incidence ranges from 1 to 2 cases/10000 in the age group 0-4 years up to

**Table 5: Statistics in females**

	A1 (0-3 year)	B1 (3-9 year)	C1 (10+ year)	P value <sup>#</sup>
No. (%)	6 (6.3)	35 (36.4)	55 (57.3)	NA
Surgery (%)	5 (83.3)	17 (48.6)	36 (65.5)	A1-B1: .19 A1-C1: .65 B1-C1: .13
Complicated (%)	3 (60)	9 (56.2)	3 (10.7)	A1-B1: 1 A1-C1: .03 B1-C1: .001
Histologically confirmed AA (%)	5 (100)	16 (94.1)	28 (77.8)	A1-B1: 1 A1-C1: .56 B1-C1: .42
Imaging (%)	2 (33.3)	12 (34.3)	15 (27.3)	A1-B1: 1 A1-C1: 1 B1-C1: .64

<sup>#</sup>Two-tailed Fisher exact probability test; AA: Acute appendicitis

**Table 6: Statistics on imaging in different outcomes categories**

	Imaging (%)	P value <sup>#</sup>
Surgery	24 (17.5)	<0.001
Not surgery	33 (39.3)	
Histologically confirmed AA	22 (17.6)	1
Histologically not confirmed AA	2 (16.7)	
Non complicated AA	8 (24.2)	0.44
Complicated AA	14(15.22)	

<sup>#</sup>Two-tailed Fisher exact probability test; AA: Acute appendicitis

**Table 7: Statistics on imaging between males and females considering different age groups**

	Males	Females	P value <sup>#</sup>
<4 years (%)	2 (66.7)	2 (33.3)	0.52
4-10 years (%)	15 (22.4)	12 (34.3)	0.24
>10 years (%)	11 (19.6)	15 (27.3)	0.5

<sup>#</sup>Two-tailed Fisher exact probability test

25 cases/10000 in the age group 10-17 years.<sup>[8]</sup> In our series, AA was ultimately diagnosed in 4.5% (125/2772) of all children presenting to the ER with acute abdominal pain, fully according to what is reported in literature (1-8%).<sup>[8,10]</sup> Diagnosis of appendicitis is essentially clinical, based on the classical triad of symptoms: Typical abdominal pain worsening over time, gastrointestinal disorders like anorexia or vomit and systemic immune response with positive laboratory blood test (left shift leukocytosis and raised C-reactive protein level) and possible fever.<sup>[1,2,6,8]</sup> Nevertheless, this classical pattern of symptoms occurs only in about 50-60% of cases: Misleading anamnesis or equivocal findings are mainly reported in young children, in pubertal/adolescent girls and in case of pelvic or retrocecal appendix.<sup>[2,5,7,8,10]</sup> These cases are often lately referred to ER and require a more careful and time demanding work-up for differential diagnosis (mesenteric lymphadenitis, gastroenteritis, constipation, lower right lobe pneumonia, gynaecological

problems) with a higher rate of delayed or missed diagnosis (>70% in infants and toddlers).<sup>[1-4,7,8]</sup> If the diagnosis is delayed appendiceal complication occurs. Literature reported that rates of appendiceal complication vary depending on age: Overall paediatric population 17-33%, 10-20% in the 10-17 year-old group, up to 80-100% in children younger than 4 years.<sup>[2,7,8]</sup> Complications increase mortality from 0.002% to 3% and morbidity from 3% to 47%.<sup>[9-11]</sup> On the other hand, wrongly diagnosed appendicitis with unnecessary appendectomy are reported in 15-40%.<sup>[11,12]</sup> A rate of 10-20% negative appendectomies is considered acceptable and is justified by a surgical approach to the equivocal cases in order to reduce appendiceal complication.<sup>[3,9,13]</sup> Nevertheless, appendectomy is a procedure performed under general anaesthesia and even an unnecessary appendectomy accounts a complication rate of 3-15%, with 2% of cases requiring a reoperation. Furthermore, the total cost for an unnecessary appendectomy (exams, surgery, hospitalization) is about \$3000.<sup>[14,15]</sup> In our series, the unnecessary appendectomy rate (8.8%) resulted fairly low. Many clinical and technological tools can be used in order to perform a more accurate and prompt diagnosis of AA, thus, reducing both complication and negative appendectomy rates. First of all, patients presenting with equivocal signs and symptoms of AA should be admitted for inpatient observation and serial physical examinations until a clear diagnosis is reached, as we do at our Centre. Several clinical scoring systems of symptoms and signs have been proposed by Alvarado, Samuel and Lintula in order to achieve a more confident approach to these patients, however, their absolute utility, especially, in pediatric setting, is not universally accepted. In our opinion, their strongest limit is the automatic and rigid evaluation they offer. Experienced clinicians may not improve their diagnostic performance with scoring systems.<sup>[2,8,16-19]</sup> Imaging studies are indeed useful to achieve a more correct diagnosis but they should be used appropriately. Plain abdominal X-ray studies result normal or misleading in up to 77% of AA, unless a typical calcified appendicolith is found.<sup>[8,20]</sup> Despite this exam was often wrongly over-requested by ER paediatricians before surgical consultation for not specific abdominal pain, it rarely altered patient's surgical management. US can better help in diagnosing AA if the typical direct or indirect signs are visualized. It can also be useful in identifying a different cause of abdominal pain in 24-41% of cases.<sup>[8,9,14,16,20-23]</sup> Anyway non-visualization of the appendix at US is reported in 33-51% of normal appendices and in 10% of inflamed appendices because of air or stool interposition, fat constitution, patient's un-cooperation or low operator's skills, thus a negative US doesn't exclude AA.<sup>[14,16,22]</sup> Most of the patients in our

series with equivocal symptoms were studied by US. CT is more reliable than US and it is the most used imaging technique in the United States in order to accurately confirm, eventually rule-out AA (sensitivity 90-100%, specificity 91-99%) or identify a differential diagnosis (reported in 80% of query AA cases studied by CT).<sup>[8,9,14,16,20-22]</sup> However, the appropriate use of CT scan is strongly debated.<sup>[23-25]</sup> The risk of high radiation dose connected to the use of CT in children is not negligible: Since children are 10-50 times more sensitive than adults and have a longer expected lifespan to develop a malignancy, it has been stated that 1/1000 children who are exposed to 1 abdominal CT scan will develop a cancer during lifetime.<sup>[23,26]</sup> In our series, we performed CT scan in 4 patients, all younger than 10 years: A 2-year-old girl having mild abdominal tenderness, despite high-inflammatory indices, who was found with an appendiceal abscess and subsequently under-went urgent appendectomy, and in 3 patient of the non-operated group also presenting with equivocal signs. Magnetic resonance imaging (MRI) results as sensitive and specific as CT, anyway it has a little role in detecting AA because it is much more cost and time demanding and it requires a general anaesthesia in children.<sup>[9,20]</sup> We used MRI only once in a 5-year-old girl without general anaesthesia. Four patients of our series under-went gastrointestinal contrast study because they presented with equivocal symptoms including acute pain. None of these studies was diagnostic and all these patients were finally discharged without surgery when the pain settled down. It has been reported that the accuracy of diagnosis for AA relying on plain clinical evaluations can be improved from 80% up to 95% when imaging technique are used.<sup>[9,11,14,27]</sup> It has been demonstrated that an appropriate routine use of imaging techniques like US and CT in children presenting with equivocal signs and symptoms of AA is effective in reducing the rate of complications from 35.4% to 15.5% as well as unnecessary appendectomy rates from 14.7% to 4.1%.<sup>[5,11]</sup> In our series, the use of imaging in children who were not operated resulted twice than in those with confirmed appendicitis at surgery (39.3 vs. 17, 6%,  $P < 0.0001$ ). This is consistent with the fact that imaging is requested essentially in the diagnostic process of those cases presenting with equivocal signs and symptoms. The male to female ratio (M/F) resulted to be 1.36 in the overall population receiving appendectomy, 1.42 in not-complicated appendectomies and 1.2 in the complicated ones. The rate of unnecessary appendectomies was greater in females (M/F=0.33). Among the patients with not-confirmed appendicitis at histopathology (negative appendectomy group), only 16.7% received some kind of pre-operative imaging, with no gender differences. It should be worthwhile to consider the employment of

imaging studies (especially US) in females older than 10 years, as this group represents 66% of the total unnecessary appendectomies. In fact in female patients signs and symptom of AA are often equivocal and may be referred to gynaecological conditions, making the diagnostic process more challenging.<sup>[2,5,8,10]</sup> Our clinical assessment-based protocol with limited use of imaging resulted in an acceptable overall peritonitis and abscess rate (26.4%) and negative appendectomy rate (8.8%). Similar experience have already been reported in literature.<sup>[6,19]</sup> However, our series confirms that some subclasses of age and sex present significantly higher negative or complication rates: In particular in females over 10 years the number of histologically not confirmed appendicitis is unacceptably high. In this group of patients, a selected use of imaging should be implemented to improve diagnostic accuracy and to avoid unnecessary appendectomies. There are several limitations to our analysis. First, the retrospective nature of this study implies no surgical follow-up for children who did not undergo surgical counselling. Second, the imaging rate may also be the result of bias due to variability of the ER examiners, since the choice to require an imaging study depends on the experience of the ER clinician. Third, in some cases the relatively low number of admitted patients has compromised the statistical significance. Nevertheless, one of the purpose of this observational study was to identify preliminary clinical data that will allow us to develop a well-designed, prospective randomized study, in order to prove if US does support the diagnosis of AA. Despite these limitations, our data confirm that clinical assessment is still the milestone to diagnose appendicitis. Use of imaging should be limited to cases with misleading anamnesis or equivocal findings and in girls over 10 years. Imaging of choice in equivocal cases should be US.

## REFERENCES

1. Hartman GE. Acute appendicitis. In: Behrman RE, editor. Nelson Textbook of Pediatrics. 18<sup>th</sup> ed. Philadelphia, PA: Saunders; 2007. p. 1628-34.
2. Bundy DG, Byerley JS, Liles EA, Perrin EM, Katznelson J, Rice HE. Does this child have appendicitis? JAMA 2007;298:438-51.
3. Chang YJ, Chao HC, Kong MS, Hsia SH, Yan DC. Misdiagnosed acute appendicitis in children in the emergency department. Chang Gung Med J 2010;33:551-7.
4. McCollough M, Sharieff GQ. Abdominal surgical emergencies in infants and young children. Emerg Med Clin North Am 2003;21909-35.
5. Rosendahl K, Aukland SM, Fosse K. Imaging strategies in children with suspected appendicitis. Eur Radiol 2004;14:L138-45.
6. Kosloske AM, Love CL, Rohrer JE, Goldthorn JF, Lacey SR. The diagnosis of appendicitis in children: Outcomes of a strategy based on pediatric surgical evaluation. Pediatrics 2004;113:29-34.
7. Brisighelli G, Morandi A, Parolini F, Leva E. Appendicitis in a 14-month-old infant with respiratory symptoms. Afr J Paediatr Surg 2012;9:148-51.

8. Rothrock SG, Pagane J. Acute appendicitis in children: Emergency department diagnosis and management. *Ann Emerg Med* 2000;36:39-51.
9. Rybkin AV, Thoeni RF. Current concepts in imaging of appendicitis. *Radiol Clin North Am* 2007;45:3.
10. Jaffe BM, Berger DH. The appendix. In: Brunicaardi FC, Andersen DK, Billiar TR, Dunn DL, Hunter JG, Pollock RE, editors. *Schwartz's Principles of Surgery*. New York: McGraw-Hill; 2005. p. 1119-37.
11. Peña BM, Taylor GA, Fishman SJ, Mandl KD. Effect of an imaging protocol on clinical outcomes among pediatric patients with appendicitis. *Pediatrics* 2002;110:1088-93.
12. Peña BM, Taylor GA, Lund DP, Mandl KD. Effect of computed tomography on patient management and costs in children with suspected appendicitis. *Pediatrics* 1999;104:440-6.
13. Binnebösel M, Otto J, Stumpf M, Mahnken AH, Gassler N, Schumpelick V, *et al.* Acute appendicitis. Modern diagnostics – Surgical ultrasound. *Chirurg* 2009;80:579-87.
14. Holscher HC, Heij HA. Imaging of acute appendicitis in children: EU versus U.S.... or US versus CT? A European perspective. *Pediatr Radiol* 2009;39:497-9.
15. Bijnen CL, van den Broek WT, Bijnen AB, de Ruiter P, Gouma DJ. Implications of removing a normal appendix. *Dig Surg* 2003;20:215-9.
16. Hernandez JA, Swischuk LE, Angel CA, Chung D, Chandler R, Lee S. Imaging of acute appendicitis: US as the primary imaging modality. *Pediatr Radiol* 2005;35:392-5.
17. Lintula H, Kokki H, Kettunen R, Eskelinen M. Appendicitis score for children with suspected appendicitis. A randomized clinical trial. *Langenbecks Arch Surg* 2009;394:999-1004.
18. Mandeville K, Pottker T, Bulloch B, Liu J. Using appendicitis scores in the pediatric ED. *Am J Emerg Med* 2011;29:972-7.
19. Adibe OO, Amin SR, Hansen EN, Chong AJ, Perger L, Keijzer R, *et al.* An evidence-based clinical protocol for diagnosis of acute appendicitis decreased the use of computed tomography in children. *J Pediatr Surg* 2011;46:192-6.
20. Parks NA, Schroepfel TJ. Update on imaging for acute appendicitis. *Surg Clin North Am* 2011;91:141-54.
21. Al-Khayal KA, Al-Omran MA. Computed tomography and ultrasonography in the diagnosis of equivocal acute appendicitis. A meta-analysis. *Saudi Med J* 2007;28:173-80.
22. Friday JH. Update on appendicitis: Diagnosis and presurgical management. *Curr Opin Pediatr* 2006;18:234-8.
23. Strouse PJ. Pediatric appendicitis: An argument for US. *Radiology* 2010;255:8-13.
24. Rhea JT, Halpern EF, Ptak T, Lawrason JN, Sacknoff R, Novelline RA. The status of appendiceal CT in an urban medical center 5 years after its introduction: Experience with 753 patients. *AJR Am J Roentgenol* 2005;184:1802-8.
25. Stephen AE, Segev DL, Ryan DP, Mullins ME, Kim SH, Schnitzer JJ, *et al.* The diagnosis of acute appendicitis in a pediatric population: To CT or not to CT. *J Pediatr Surg* 2003;38:367-71.
26. Hall EJ. Lessons we have learned from our children: Cancer risks from diagnostic radiology. *Pediatr Radiol* 2002;32:700-6.
27. SCOAP Collaborative, Cuschieri J, Florence M, Flum DR, Jurkovich GJ, Lin P, *et al.* Negative appendectomy and imaging accuracy in the Washington State Surgical Care and Outcomes Assessment Program. *Ann Surg* 2008;248:557-63.

**Cite this article as:** Cesare AD, Parolini F, Morandi A, Leva E, Torricelli M. Do we need imaging to diagnose appendicitis in children?. *Afr J Paediatr Surg* 2013;10:68-73.

**Source of Support:** Nil, **Conflict of Interest:** Non declared.