


CASE REPORT

Identical *EP300* variant leading to Rubinstein–Taybi syndrome with different clinical and immunologic phenotype

Francesco Saettini^{1,2}  | Grazia Fazio² | Maria Teresa Bonati³ |
Daniele Moratto⁴ | Valentina Massa⁵ | Elisabetta Di Fede⁵ | Silvia Castiglioni⁵ |
Daniela Marchetti⁶ | Marco Chiarini⁴ | Alessandra Sottini⁷ | Maria Iascone⁶ |
Giovanni Cazzaniga² | Luisa Imberti⁷ | Andrea Biondi^{1,2} | Cristina Gervasini⁵ |
Raffaele Badolato⁸

¹Pediatric Hematology Outpatient Clinic, Pediatric Department, Fondazione MBBM, Monza, Italy

²Centro Ricerca M. Tettamanti, University of Milano Bicocca, Fondazione MBBM/San Gerardo Hospital, Monza, Italy

³Ambulatorio di Genetica Medica, Istituto Auxologico Italiano, IRCCS, Milano, Italy

⁴Flow Cytometry Laboratory, Diagnostic Department, ASST Spedali Civili, Brescia, Italy

⁵Department of Medical Genetics, University of Milan, Milan, Italy

⁶Laboratorio di Genetica Medica, ASST-Papa Giovanni XXIII, Bergamo, Italy

⁷Centro di Ricerca Emato-oncologica ALL (CREA), ASST Spedali Civili, Brescia, Italy

⁸Pediatrics Clinic and A. Nocivelli Institute for Molecular Medicine A, Department of Clinical and Experimental Sciences, University of Brescia, ASST-Spedali Civili, Brescia, Italy

Correspondence

Francesco Saettini, Pediatric Hematology Outpatient Clinic, Pediatric Department, Fondazione MBBM, Monza, Italy.
Email: f.saettini@gmail.com

Funding information

Telethon Italy, Grant/Award Number: GTB18001

Abstract

The Rubinstein–Taybi syndrome (RSTS) is a rare developmental disorder characterized by craniofacial dysmorphisms, broad thumbs and toes, intellectual disability, growth deficiency, and recurrent infections. Mutations in the cyclic adenosine monophosphate response element-binding protein (CREB)-binding protein (*CREBBP*) or in the E1A-associated protein p300 (*EP300*) genes have been demonstrated in 55% (RSTS1) and up to 8% of the patients (RSTS2), respectively. Dysfunction of immune response has been reported in a subgroup of individuals with RSTS. Here we characterize two patients carrying the same *EP300* variant and distinctive RSTS features (including congenital heart abnormalities, short stature, feeding problems, and gastroesophageal reflux). Whole exome sequencing did not support a dual molecular diagnosis hypothesis. Nonetheless, patients showed distinct clinical manifestations and immunological features. The most severe phenotype was associated with reduced T-cell production and diversity. This latter feature was confirmed in a control group of four RSTS patients.

KEYWORDS

CREBBP, EP300, inborn errors of immunity, Rubinstein–Taybi syndrome, syndromic immunodeficiency

1 | INTRODUCTION

Rubinstein–Taybi syndrome (RSTS; OMIM #180849, #613684) is an autosomal-dominant condition that affects one in 125,000 newborns. It is defined as a congenital neurodevelopmental disorder

characterized by craniofacial dysmorphisms, postnatal growth deficiency, intellectual disability, and broad thumbs and toes. Two genes are currently known to be responsible for RSTS: *CREBBP*, causing RSTS type 1 (RSTS1) and encoding for the cAMP response element binding protein (CREB)-binding protein (also known as CBP), and

This is an open access article under the terms of the Creative Commons Attribution License, which permits use, distribution and reproduction in any medium, provided the original work is properly cited.

© 2022 The Authors. *American Journal of Medical Genetics Part A* published by Wiley Periodicals LLC.

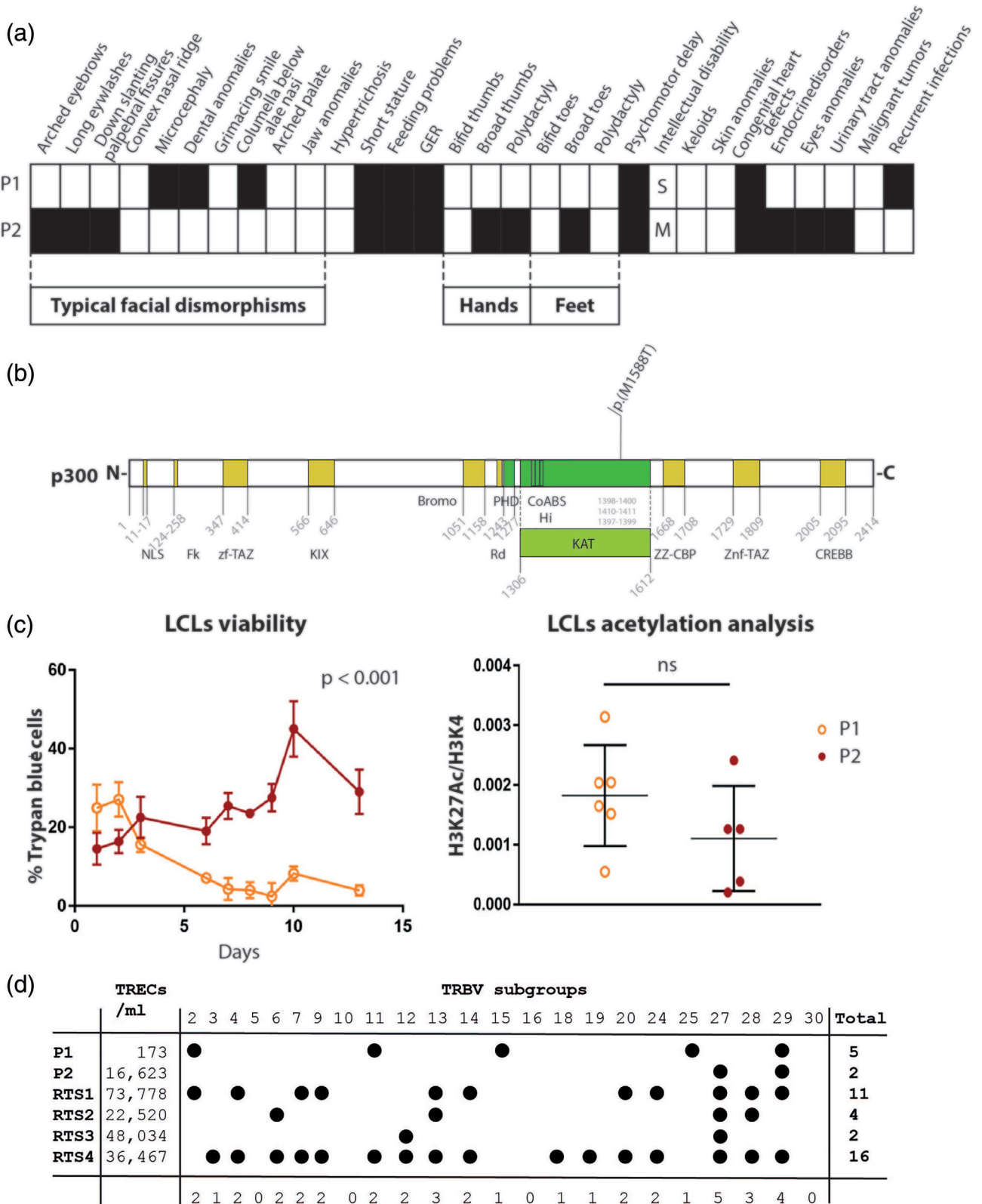


FIGURE 1 Legend on next page.

EP300 encoding for the E1A associated protein p300, highly homologous to CBP, causing RSTS type 2 (RSTS2). CBP and p300 are transcriptional co-activators with intrinsic lysine acetyltransferase activity. They both act in different signal transduction pathways involved in the control of cell growth, cellular differentiation, DNA repair, apoptosis, and tumor suppression (Saettini et al., 2020).

We have recently described a large cohort of 97 RSTS patients with variable immunodeficiency (Saettini et al., 2020). Here we characterize two patients (the first of whom has been previously described; Saettini et al., 2018, 2021) who, despite carrying the same *EP300* variant, show distinctive RSTS features (including congenital heart abnormalities, short stature, feeding problems, and gastroesophageal reflux; Figure 1a) but distinct clinical manifestations and immunological features.

2 | CLINICAL DESCRIPTIONS AND DISCUSSION

Patients were both evaluated at our Immunology Outpatient clinic at 17 years of age (Table 1). Trio whole exome sequencing (trio-WES) (Pezzani et al., 2018) performed in the family of P1 did not identify any significant variant in known syndromic primary immunodeficiencies (PID) genes (Bousfiha et al., 2020). A novel de novo heterozygous missense variant (NM_001429.3:c.4763T>C, p.(Met1588Thr)) in the exon 29 of *EP300* was detected, which was not present in public databases or in our internal databases. The identical variant was found in P2 initially by means of next-generation sequencing (NGS) panel and then by trio-WES, with the same setting as for P1 family. No additional variants were detected when the analysis was extended to known PID variants associated variants (Bousfiha et al., 2020). The single nucleotide change c.4763T>C in *EP300* gene leads to the substitution of the nonpolar amino acid Met1588 with the polar amino acid threonine. This substitution is predicted to disrupt the lysine acetyltransferase (KAT) domain, a highly conserved zinc finger domain affecting acetyltransferase activity, promoting histone acetylation, and DNA access for gene transcription (Figure 1b).

Despite patients carrying the same *EP300* variant (p.(Met1588Thr)), the immunological phenotype was rather diverse. P1 suffers from profound combined immunodeficiency, as defined by recurrent and severe infections, failure to thrive, splenomegaly,

reduced vaccine responses, early onset of multiple cytopenia (recurrent episodes of autoimmune hemolytic anemia, intermittent neutropenia, and thrombocytopenia), severe lymphopenia ($0.5\text{--}0.8$ lymphocytes $\times 10^9/\text{L}$, associated with an increased proportion of T- and B- cell subsets such as $\text{CD}3^+\text{CD}4^-\text{CD}8^-\alpha\beta^+$ and $\text{CD}19^{\text{hi}}\text{CD}21^{\text{lo}}$), hypgammaglobulinemia (IgG: <400 mg/dl, IgA: 1 mg/dl, and IgM: 50 mg/dl), and reduced T-lymphocyte proliferation to mitogens and specific T-cell stimuli. He was treated with steroids and high dose immunoglobulin when cytopenia occurred, sirolimus to control splenomegaly, trimethoprim sulfamethoxazole prophylaxis due to lymphopenia (Saettini et al., 2018), and acyclovir due to HSV-1 reactivation in the setting of secondary hemophagocytic lymphohistiocytosis (Saettini et al., 2021). On the contrary, P2 did not experience any type of infections and did not require any infection prophylaxis. P2's immunological workup (i.e., complete blood count, lymphocyte subsets, response to mitogens, and immunoglobulin levels) was unremarkable, except for partial IgA deficiency (Table 1).

Additional analyses performed on lymphoblastoid cell lines (LCLs; Lopez-Atalaya et al., 2012) derived from the two patients demonstrated reduced cell viability in P1, whose because trypan blue staining revealed significantly higher cell death rate (Figure 1c) compared to P2.

On the opposite, analysis of acetylation state (i.e., K27H3Ac) of chromatin, reported to be impaired in RSTS patients with *CREBBP* variants (Baldo et al., 2016), did not reveal any statistically significant difference between the LCLs derived from the two patients when assessed by AlphaLISA assay, suggesting that the *EP300* variant carried by both patients exerts similar epigenetic alterations in the LCLs.

Although the trio-WES analysis makes a dual molecular diagnosis extremely unlikely, the presence of distinct immunological features in the two patients does not exclude the presence of deep intronic variants or the influence of not-yet-known genes. A significant proportion of patients with RSTS suffers from immunodeficiency, autoimmune, and autoinflammatory conditions, but the reason for the switch from typical RSTS to syndromic PID is not known (Saettini et al., 2020). The immune tolerance to self is an essential mechanism to prevent untoward immune responses and autoimmunity. The reduced immune tolerance in RSTS patients could be impaired through different mechanisms. One hypothesis involves the iatrogenic effect of cardiac surgery, since partial or complete thymectomy cannot be excluded

FIGURE 1 (a) Schematic representation of the clinical phenotype of the index patients. (b) Schematic representation (not in scale) of the Met1588Thr mutation both at aminoacidic and domain level, above and below the figures, respectively. In order (from N terminus to C-terminus), p300 protein domains are as follows: zf-TAZ, TAZ zinc finger; KIX, CREB interaction; Bromo, bromodomain; Ring, ring domain; PHD, plant homeodomain; KAT, lysine acetyltransferase; COaBS, CoA-binding site; ZZ_CBP, zinc finger; ZnF_TAZ, TAZ zinc finger; CREBB, Creb_binding. The protein domains are indicated accordingly to NCBI reference sequence: NP_001420.2 (p300). (c) Cell viability data from trypan blue staining and acetylation state (i.e., K27H3Ac) of chromatin (right) in lymphoblastoid cell lines (LCLs) derived from the two patients. (d) T-cell receptor spectratyping analysis. Map representing the distribution of perturbations at the single-TCRBV, single patient level. Black dots represent the TCRBV families whose perturbations are higher than the mean + 2 SD standard deviation of the value seen in the corresponding TCRBV family found in healthy controls. The number of these over-perturbed TCRBV subgroups is indicated in right column, while the number of each perturbed TCRBV subgroups is reported at the bottom. *Range of TRECs/mL in age-matched healthy controls: 16,341–81,767. GER, gastroesophageal reflux; LCLs, lymphoblastoid cell lines; M, mild; S, severe

TABLE 1 Immunological characteristics of the index patients

	Patient 1	Patient 2	Age-matched normal values
	c.4763C>T p.Met1588Thr	c.4763C>T p.Met1588Thr	
Hemoglobin, g/dl	13.3	15.1	13.0–16.0
Platelets, × 10 ⁹ /L	70	251	>140
White blood cells, × 10 ⁹ /L	4.82	6.39	4.4–8.1
Neutrophils, × 10 ⁹ /L	3.48	3.11	>1.5
Monocytes, × 10 ⁹ /L	0.40	0.64	>0.2
Lymphocytes, × 10 ⁹ /L	0.82	2.49	1.4–3.3
CD3 ⁺ , × 10 ⁹ /L	0.70	2.30	0.72–2.56
CD3 ⁺ CD4 ⁺ , × 10 ⁹ /L	0.27	1.68	0.27–1.88
CD4 ⁺ HLADR ⁺ , %	19.2	0.8	1.6–12.2
Naïve CD4 ⁺ CD45RA ⁺ CCR7 ⁺ , %	10.7	45.6	20.4–63.6
Recent thymic emigrants CD4 ⁺ CD45RA ⁺ CCR7 ⁺ CD31 ⁺ , × 10 ⁹ /L	0.004	0.33	0.12–0.91
Central memory CD4 ⁺ CD45RA ⁻ CCR7 ⁺ , %	63.1	32.5	18.7–46.2
Effector memory CD4 ⁺ CD45RA ⁻ CCR7 ⁻ , %	24.7	21.7	7.1–38.0
Terminally differentiated CD4 ⁺ CD45RA ⁺ CCR7 ⁻ , %	1.7	0.2	0.3–9.1
CD3 ⁺ CD8 ⁺ , × 10 ⁹ /L	0.39	0.56	0.18–0.78
CD8 ⁺ HLADR ⁺	44.8	2.3	2.7–31.7
Naïve CD8 ⁺ CD45RA ⁺ CCR7 ⁺ , %	9.5	65.2	13.1–66.5
Central memory CD8 ⁺ CD45RA ⁻ CCR7 ⁺ , %	4.4	6.1	2.6–24.5
Effector memory CD8 ⁺ CD45RA ⁻ CCR7 ⁻ , %	62.7	21.2	10.1–47.4
Terminally differentiated CD8 ⁺ CD45RA ⁺ CCR7 ⁻ , %	23.5	7.4	5.2–63.5
CD19 ⁺ , × 10 ⁹ /L	0.02	0.59	0.09–0.65
Recent B emigrants CD19 ⁺ CD38 ⁺⁺ CD10 ⁺ , %	7.7	9.5	2.1–26.1
Naïve CD19 ⁺ IgD ⁺ IgM ⁺ CD27 ⁻ , %	40.3	56.0	33.7–74.0
CD19 ⁺⁺ CD21 ^{low}	31.0	4.7	1.4–13.6
Switched memory CD19 ⁺ IgD ⁻ IgM ⁻ CD27 ⁺ , %	1.3	7.1	2.8–23.4
IgM memory CD19 ⁺ IgD ⁺ IgM ⁺ CD27 ⁺ , %	11.1	22.3	5.1–25.5
Terminally differentiated CD19 ⁺ CD38 ⁺ +CD27 ⁺ CD20 ⁻ , %	4.7	0.4	0.2–8.1
Plasma cells, CD38 ⁺⁺ CD27 ⁺⁺ CD20 ⁻ CD138 ⁺	0.7	0.1	0.0–2.2
CD3 ⁻ CD16 ⁺ CD56 ⁺ , × 10 ⁹ /L	0.09	0.32	0.04–0.74
IgG, mg/dl	655 ^a	651	604–1909
IgM, mg/dl	59	183	59–297
IgA, mg/dl	1	47	61–301
Vaccine response Tetanus	Absent	Normal	
Lymphocyte proliferation			
antiCD3		Normal	
antiCD3+ IL2		Normal	
PHA	Reduced	Normal	

^aDuring immunoglobulin replacement therapy.

after an open-heart surgery. Indeed, both patients underwent surgical correction of the congenital heart defects, but only P1 showed an extremely reduced recent thymic emigrant (RTE) count and a reduced number of T-cell receptor excision circles (TRECs) and expansion of T cells bearing different T-cell receptor beta (TRBV) chains, that

may explain the development of recurrent cytopenia, and lymphoproliferation. On the contrary, RTE and TRECs were within normal range in P2 and the number of T-cell restrictions was limited.

We have previously described one RSTS patient who underwent hematopoietic stem cell transplantation due to a clinical picture of

Omenn syndrome (Saettini et al., 2020), a condition with known TRBV perturbation (Corneo et al., 2001). Unfortunately, at that time, T-cell diversity and TRECs were not studied. We have therefore investigated four further RSTS patients (RSTS1, RSTS2, RSTS3, and RSTS4). These patients displayed a high heterogeneity of both new T-cell production and T-cell diversity, being T cells of RSTS4 patient highly perturbed (Figure 1d), despite the normal production of TRECs.

Defective T-cell development might lead to the production and expansion of autoreactive T cells. In the setting of a defective T-cell developmental program, we may speculate that selected antigens (i.e., antigenic hypothesis), either genetically encoded (autoantigen) or derived from the environment (exoantigen) in a fraction of RSTS patients, could trigger the emerging autoreactive clones resulting in T cell activation and expansion of specific T-cell receptor subgroups (Corneo et al., 2001; Savola et al., 2020).

3 | CONCLUSION

In summary, the analysis of two patients carrying the same EP300 mutation, despite the absence of additional variants to the trio-WES re-evaluation, highlighted the presence of a different immunological phenotype and a different cell viability of the LCLs, with lymphopenia and reduced thymic output only in one of the patients.

B cell defects, mostly resulting in hypogammaglobulinemia and/or impaired vaccine response, have been reported in RSTS patients (Saettini et al., 2021). Immunological assessment (immunoglobulin levels, vaccine titers, and lymphocyte subsets with B cell phenotyping) in RSTS patients, who may require specific treatment if immune workup results impaired, is recommended. Given the results we have here described, quantification of peripheral RTE and TRECs can be a useful tool for screening T-cell defects (Adams et al., 2018). Our results, if confirmed in a larger cohort of patients, could lead to careful follow up of patients with reduced T-cell diversity and prompt administration of immunosuppressive treatments (in case of lymphoproliferation or autoimmune phenomena) or long-term antibiotic or antiviral prophylaxis (if CD4+ counts are severely reduced or in case of severe viral infection/reactivation).

This study confirms the extreme phenotypic variability associated with EP300 variants, in particular from the immunological perspective, which could be potentially clarified with further studies on somatic mutations and T-cell clonality, variants in noncoding region, or deepening environmental factors assessment.

ACKNOWLEDGMENTS

The authors thank the patients and their families for participating in the study. The authors thank the Biobank of the Laboratory of Human Genetics, member of the "Network Telethon of Genetic Biobanks" (project no. GTB18001), funded by Telethon Italy, and the EuroBioBank network and the AssiGulliver Associazione Sindrome di Sotos Italia for providing lymphoblastoid cell lines. This study was approved by the institutional review boards/ethic committee of

Comitato Etico Brianza (Monza, Italy; PID-GENMET) and Ethics Committee of Università degli Studi di Milano (Comitato Etico number 99/20). All study participants provided written informed consent.

CONFLICT OF INTEREST

The authors declare no conflict of interest.

DATA AVAILABILITY STATEMENT

Data sharing is not applicable to this article as no new data were created or analyzed in this study.

ORCID

Francesco Saettini  <https://orcid.org/0000-0003-0767-3905>

REFERENCES

- Adams, S. P., Kricke, S., Ralph, E., Gilmour, N., & Gilmour, K. C. (2018). A comparison of TRECs and flow cytometry for naive T cell quantification. *Clinical and Experimental Immunology*, 191(2), 198–202. <https://doi.org/10.1111/cei.13062>
- Baldo, C., Casareto, L., Renieri, A., Merla, G., Garavaglia, B., Goldwurm, S., Pegoraro, E., Moggio, M., Mora, M., Politano, L., Sangiorgi, L., Mazzotti, R., Viotti, V., Meloni, I., Pellico, M. T., Barzaghi, C., Wang, C. M., Monaco, L., & Filocamo, M. (2016). The alliance between genetic biobanks and patient organisations: The experience of the telethon network of genetic biobanks. *Orphanet Journal of Rare Diseases*, 11(1), 142. <https://doi.org/10.1186/s13023-016-0527-7>
- Bousfiha, A., Jeddane, L., Picard, C., Al-Herz, W., Ailal, F., Chatila, T., Cunningham-Rundles, C., Etzioni, A., Franco, J. L., Holland, S. M., Klein, C., Morio, T., Ochs, H. D., Oksenhendler, E., Puck, J., Torgerson, T. R., Casanova, J. L., Sullivan, K. E., & Tangye, S. G. (2020). Human inborn errors of immunity: 2019 update of the IUIS phenotypical classification. *Journal of Clinical Immunology*, 40(1), 66–81. <https://doi.org/10.1007/s10875-020-00758-x>
- Corneo, B., Moshous, D., Güngör, T., Wulffraat, N., Philippet, P., Le Deist, F. L., Fischer, A., & de Villartay, J. P. (2001). Identical mutations in RAG1 or RAG2 genes leading to defective V(D)J recombinase activity can cause either T-B-severe combined immune deficiency or Omenn syndrome. *Blood*, 97(9), 2772–2776. <https://doi.org/10.1182/blood.v97.9.2772>
- Lopez-Atalaya, J. P., Gervasini, C., Mottadelli, F., Spena, S., Piccione, M., Scarano, G., Selicorni, A., Barco, A., & Larizza, L. (2012). Histone acetylation deficits in lymphoblastoid cell lines from patients with Rubinstein-Taybi syndrome. *Journal of Medical Genetics*, 49(1), 66–74. <https://doi.org/10.1136/jmedgenet-2011-100354>
- Pezzani, L., Marchetti, D., Cereda, A., Caffi, L. G., Manara, O., Mamoli, D., Pezzoli, L., Lincasso, A. R., Perego, L., Pellicoli, I., Bonanomi, E., Salvoni, L., & Iascone, M. (2018). Atypical presentation of pediatric BRAF RASopathy with acute encephalopathy. *American Journal of Medical Genetics. Part A*, 176(12), 2867–2871. <https://doi.org/10.1002/ajmg.a.40635>
- Saettini, F., Herriot, R., Prada, E., Nizon, M., Zama, D., Marzollo, A., Romaniouk, I., Lougaris, V., Cortesi, M., Morreale, A., Kosaki, R., Cardinale, F., Ricci, S., Domínguez-Garrido, E., Montin, D., Vincent, M., Milani, D., Biondi, A., Gervasini, C., & Badolato, R. (2020). Prevalence of immunological defects in a cohort of 97 Rubinstein-Taybi syndrome patients. *Journal of Clinical Immunology*, 40(6), 851–860. <https://doi.org/10.1007/s10875-020-00808-4>
- Saettini, F., Moratto, D., Grioni, A., Maitz, S., Iascone, M., Rizzari, C., Pavan, F., Spinelli, M., Bettini, L. R., Biondi, A., & Badolato, R. (2018). A novel EP300 mutation associated with Rubinstein-Taybi syndrome type 2 presenting as combined immunodeficiency.

Pediatric Allergy and Immunology, 29(7), 776–781. <https://doi.org/10.1111/pai.12968>

- Saettini, F., Radaelli, S., Ocello, L., Ferrari, G. M., Corti, P., Dell'Acqua, F., Ippolito, D., Foresti, S., Gervasini, C., Badolato, R., & Biondi, A. (2021). Secondary hemophagocytic lymphohistiocytosis in a Rubinstein Taybi syndrome patient. *Pediatric Hematology and Oncology*, 39, 1–6. <https://doi.org/10.1080/08880018.2021.1928802>
- Savola, P., Martelius, T., Kankainen, M., Huuhtanen, J., Lundgren, S., Koski, Y., Eldfors, S., Kelkka, T., Keränen, M. A. I., Ellonen, P., Kovanen, P. E., Kytölä, S., Saarela, J., Lähdesmäki, H., Seppänen, M. R. J., & Mustjoki, S. (2020). Somatic mutations and T-cell clonality in patients with immunodeficiency. *Haematologica*, 105(12), 2757–2768. <https://doi.org/10.3324/haematol.2019.220889>

How to cite this article: Saettini, F., Fazio, G., Bonati, M. T., Moratto, D., Massa, V., Di Fede, E., Castiglioni, S., Marchetti, D., Chiarini, M., Sottini, A., Iascone, M., Cazzaniga, G., Imberti, L., Biondi, A., Gervasini, C., & Badolato, R. (2022). Identical EP300 variant leading to Rubinstein–Taybi syndrome with different clinical and immunologic phenotype. *American Journal of Medical Genetics Part A*, 1–6. <https://doi.org/10.1002/ajmg.a.62719>