

SPECIAL ARTICLE

# Squamous cell carcinoma of the oral cavity, larynx, oropharynx and hypopharynx: EHNS—ESMO—ESTRO Clinical Practice Guidelines for diagnosis, treatment and follow-up<sup>†</sup>

J.-P. Machiels<sup>1,2†</sup>, C. René Leemans<sup>3†</sup>, W. Golusinski<sup>4</sup>, C. Grau<sup>5</sup>, L. Licitra<sup>6</sup> & V. Gregoire<sup>7</sup>, on behalf of the EHNS Executive Board<sup>\*</sup>, ESMO Guidelines Committee<sup>\*</sup> and ESTRO Executive Board<sup>\*</sup>

<sup>1</sup>Service d'Oncologie Médicale, Institut Roi Albert II, Cliniques Universitaires Saint-Luc, Brussels; <sup>2</sup>Institut de Recherche Clinique et Expérimentale, Université Catholique de Louvain (UCLouvain), Brussels, Belgium; <sup>3</sup>Department of Otolaryngology-Head and Neck Surgery, Amsterdam University Medical Centres, Cancer Centre Amsterdam, Vrije Universiteit, Amsterdam, The Netherlands; <sup>4</sup>Department of Head and Neck Surgery, Poznan University of Medical Sciences and The Greater Poland Cancer Centre, Poznan, Poland; <sup>5</sup>Department of Oncology and Danish Centre for Particle Therapy, Aarhus University Hospital, Aarhus, Denmark; <sup>6</sup>Head and Neck Cancer Medical Oncology Department, Fondazione IRCCS Istituto Nazionale dei Tumori and University of Milan, Milan, Italy; <sup>7</sup>Department of Radiation Oncology, Centre Léon Bérard, Lyon, France



Available online 23 October 2020

**Key words:** SCCHN, Clinical Practice Guidelines, diagnosis, treatment, follow-up

## INCIDENCE AND EPIDEMIOLOGY

Squamous cell carcinoma of the head and neck (SCCHN) arises from epithelial cells and occurs in the oral cavity, pharynx and larynx. Nasopharyngeal carcinoma (NPC) is a disease with unique features and is therefore not covered in this Clinical Practice Guideline. Updated recommendations for the management of NPC are described in a separate Clinical Practice Guideline (submitted).

SCCHN is the seventh most common cancer worldwide with an annual incidence of approximately 700 000 and a mortality rate estimated at 350 000 in 2018.<sup>1</sup> In Europe, between 2000 and 2007, the annual crude incidence rates were 4.6/100 000 for laryngeal squamous cell carcinoma (SCC), 3.5/100 000 for oral cavity SCC, 3.3/100 000 for oropharyngeal SCC and 1.3/100 000 for hypopharyngeal SCC, corresponding to approximately 90 000 new cases per year.<sup>2</sup> Five-year relative survival was 61%, 49%, 41% and

25% for laryngeal, oral cavity, oropharyngeal and hypopharyngeal SCC, respectively.<sup>2</sup>

Around 75%–85% of SCCHN is due to tobacco use and alcohol consumption, although human papillomavirus (HPV) infection as a cause of oropharyngeal cancer is increasing. The prevalence of oropharyngeal cancer attributable to HPV varies widely across the globe but is estimated at around 30%–35%.<sup>3</sup> HPV-positive patients with oropharyngeal cancer have a significantly better outcome than patients diagnosed with HPV-negative disease.<sup>4</sup> HPV-positive SCCHN outside of the oropharynx is rare (<6%). Other much weaker risk factors include radiation exposure, chronic infection, long-term immunosuppression, poor oral hygiene, poor nutrition, betel nut chewing and ill-fitting dentures. Fanconi anaemia, ataxia telangiectasia, Bloom's syndrome, Li-Fraumeni syndrome and dyskeratosis congenita are rare inherited causes of SCCHN. Genetic counselling should be considered in cases of cytopaenia, young age and history of several cancers in the family, particularly in the absence of the other risk factors.

Specific polymorphisms in genes encoding for enzymes that metabolise carcinogens such as glutathione *S*-transferase (*GSTM1*), glutathione *S*-transferase (*GSTT1*) or human microsomal epoxide hydrolase (*EPHX1*) have been associated with SCCHN development.<sup>5</sup>

## DIAGNOSIS AND PATHOLOGY/MOLECULAR BIOLOGY

### Diagnosis

The following symptoms should prompt clinicians to examine patients for an SCCHN: chronic pain in the throat, persistent hoarseness, chronic sore tongue or non-healing

### \*Correspondence to:

EHNS Executive Board, Barbaros Caddesi Akdogan Sok. No: 23/2, 34353 Besiktas, Istanbul, Turkey. E-mail: [secretariat@ehns.org](mailto:secretariat@ehns.org) (EHNS Executive Board).

ESMO Guidelines Committee, ESMO Head Office, Via Ginevra 4, 6900 Lugano, Switzerland. E-mail: [clinicalguidelines@esmo.org](mailto:clinicalguidelines@esmo.org) (ESMO Guidelines Committee).

ESTRO Executive Board, Rue Martin V 40, 1200 Brussels, Belgium. E-mail: [info@estro.org](mailto:info@estro.org) (ESTRO Executive Board).

<sup>†</sup> These Guidelines were developed by the European Head and Neck Society (EHNS), the European Society for Medical Oncology (ESMO) and the European Society for Radiotherapy & Oncology (ESTRO). The three societies nominated authors to write the guidelines as well as reviewers to comment on them. These guidelines were approved by the EHNS Executive Board, the ESMO Guidelines Committee and the ESTRO Executive Board in June 2020.

<sup>‡</sup> Similar contribution.

0923-7534/© 2020 European Society for Medical Oncology. Published by Elsevier Ltd. All rights reserved.

ulcers or red/white patches in the mouth, painful or difficulty swallowing and neck masses.

A summary of clinical work-up recommendations for staging and diagnosis is shown in Table 1. Clinical evaluation should include a history of symptoms, complete physical examination including neck palpation and flexible head and neck fiberoptic endoscopy, performance status (PS), nutritional status with weight assessment, dental examination, speech and swallowing function and psychosocial evaluation [IV, A]. A complete blood count, assessment of liver enzymes, serum creatinine, albumin, coagulation parameters and thyroid-stimulating hormone (TSH) should be routinely carried out. Pathological confirmation is mandatory [IV, A]. Examination and biopsy can be carried out transorally under local anaesthesia. For pharyngolaryngeal tumours, this is often best carried out using an endoscopic route under general anaesthesia [IV, A]. Stomatological evaluation with tooth extraction when required [especially if radiotherapy (RT) is being considered] is also usually carried out. Systematic bronchoscopy and oesophagoscopy are not advised but should be driven by symptoms and/or other diagnostic findings [IV, C].

Contrast-enhanced (CE) computed tomography (CT) scan and/or magnetic resonance imaging (MRI) are mandatory to assess the primary tumour and regional lymph nodes as well as cartilage invasion for laryngeal or hypopharyngeal cancer [III, A]. The two imaging techniques are complementary and their respective indications should be discussed with a radiologist specialised in head and neck cancer. CT and MRI have similar diagnostic value in the radiological evaluation of the neck.

Chest imaging is important to assess the presence of distant metastases in high-risk tumours (i.e. presence of neck adenopathies) or a second lung primary in heavy smokers [III, A]. As a minimum, a chest CT should be carried out. The combination of 2'-deoxy-2'-[<sup>18</sup>F] fluoro-D-glucose (FDG) positron emission tomography (PET) and CE-CT of the chest have a higher sensitivity than chest CT or whole-body FDG-PET as separate modalities to detect tumours [II, B].<sup>6</sup> FDG-PET is also recommended for the work-up of a

carcinoma of unknown primary to direct specific mucosal biopsy.<sup>7</sup> Finally, FDG-PET is recommended to evaluate the neck response to RT or chemoradiotherapy (CRT) 10–12 weeks after completing treatment, or in cases of suspected recurrence.<sup>8</sup>

### Pathology assessment

SCCHN should be classified according to the 4th edition of the World Health Organization (WHO) classification.<sup>9</sup> This classification recognises the oropharynx as a distinctive subsite.

HPV evaluation using p16 immunohistochemistry (IHC) should be carried out on all patients with newly diagnosed oropharyngeal SCC [I, A]. p16 IHC is a reliable surrogate marker for HPV positivity in the oropharynx, although 10%–15% of false-positive results occur.<sup>10</sup> For neck metastases of unknown origin, p16 status should also be assessed, and in case of positivity, another specific HPV test [e.g. DNA, RNA or *in situ* hybridisation (ISH)] should be carried out in order to confirm the HPV status [III, A].<sup>11,12</sup> In case of neoplastic lymph node(s) with an unknown primary, the Epstein-Barr virus (EBV) status should also be determined by Epstein-Barr-encoded RNA (EBER) using ISH to exclude a nasopharyngeal cancer [III, A].

The prognostic value of p16 has only been observed in oropharyngeal SCC, and not in laryngeal, hypopharyngeal or oral cavity tumours. Thus, for non-oropharyngeal cancers of the head and neck, determination of p16 status is not mandatory.

Pathological assessment of the surgical specimens should include the size of tumour, growth pattern, depth of invasion (DOI) for oral cavity cancer, total number of lymph nodes removed, number of invaded lymph nodes and their location, presence of extracapsular nodal extension, perineural and lymphatic infiltration and the surgical margins (i.e. R0 and R1 resection) [I, A]. These features are important for pathological staging and prognosis, and to determine the postoperative adjuvant treatment.

For recurrent and/or metastatic SCCHN, tumour programmed death-ligand 1 (PD-L1) expression should be

**Table 1. Work-up for staging and diagnosis**

	Strongly recommended	Alternative	If indicated
General	<ul style="list-style-type: none"> <li>• Tumour biopsy</li> <li>• Medical history</li> <li>• Physical examination including head and neck examination</li> <li>• PS</li> <li>• Dental examination</li> <li>• Blood test<sup>a</sup></li> </ul>		<ul style="list-style-type: none"> <li>• Speech and swallowing function</li> <li>• Nutritional status with weight assessment</li> <li>• Social and psychological evaluation</li> </ul>
Local and regional assessment	<ul style="list-style-type: none"> <li>• Head and neck CE-CT and/or MRI</li> <li>• Rigid head and neck endoscopy under general anaesthesia</li> </ul>		<ul style="list-style-type: none"> <li>• Teeth extraction<sup>b</sup></li> </ul>
Assessment of distant metastases	<ul style="list-style-type: none"> <li>• FDG-PET</li> </ul>	<ul style="list-style-type: none"> <li>• Chest CT</li> </ul>	
Second primaries	<ul style="list-style-type: none"> <li>• Head and neck endoscopy</li> </ul>		<ul style="list-style-type: none"> <li>• Oesophagoscopy</li> <li>• Bronchoscopy</li> </ul>

CE, contrast-enhanced; CT, computed tomography; FDG-PET, 2'-deoxy-2'-[<sup>18</sup>F] fluoro-D-glucose positron emission tomography; MRI, magnetic resonance imaging; PS, performance status; RT, radiotherapy; TSH, thyroid-stimulating hormone.

<sup>a</sup> Complete blood count, assessment of liver enzymes, serum creatinine, albumin, coagulation parameters and TSH if RT is foreseen.

<sup>b</sup> Ideally to be carried out during the head and neck endoscopy under general anaesthesia if indicated.

evaluated by an approved PD-L1 test within the framework of quality assurance.<sup>13</sup> PD-L1 expression is assessed either by the tumour proportion score (TPS), defined as the percentage of tumour cells with membranous PD-L1 staining, or by the combined positive score (CPS), defined as the number of PD-L1-positive cells (tumour cells, lymphocytes and macrophages) divided by the total number of tumour cells multiplied by 100. The CPS can help to define the first-line treatment strategy for recurrent/metastatic SCCHN [II, B].

### Molecular biology

Tobacco- and/or alcohol-induced SCCHN and HPV-positive oropharyngeal cancer are two distinct entities that differ significantly at both a clinical and molecular level.<sup>14</sup>

For HPV-negative SCCHN, the two most frequent genomic alterations are *p53* (83%) and *CDKN2A* (57%) according to The Cancer Genome Atlas (TCGA) data.<sup>14,15</sup> In HPV-positive oropharyngeal cancer, 56% harbour *PI3KCA* amplifications/mutations whereas other genetic alterations are rare. Different subgroups (mesenchymal, basal, classical and atypical) have also been defined based on gene expression profiles.<sup>16-18</sup> In addition, HPV-positive SCCHN can be subclassified into different gene profile groups, some of which are prognostic.<sup>19</sup>

However, despite a better understanding of the molecular biology of SCCHN, the current management of these patients is not based on genomic alterations or gene expression profiles.

### Recommendations

- Clinical examination and pathological confirmation are mandatory [IV, A].
- Rigid head and neck endoscopy, head and neck CE-CT and/or MRI and chest imaging (with CT and/or FGD-PET) are strongly recommended [IV, A].
- For oropharyngeal cancer, p16 IHC is strongly recommended [I, A].
- For SCCHN of unknown primary, p16 and EBER are recommended. If p16 staining is positive, another specific HPV test should be carried out to confirm the HPV status [III, A].
- On the surgical specimens, DOI of oral cavity cancer, assessment of the number of invaded lymph nodes as well as the presence extracapsular extension, perineural and lymphatic infiltration and the surgical margins must be evaluated [I, A].
- For recurrent and/or metastatic SCCHN, tumour PD-L1 expression should be evaluated [II, B].

## STAGING/RISK ASSESSMENT

### Staging

The Union for International Cancer Control (UICC) Tumour Node Metastasis (TNM) Cancer Staging Manual 8th edition head and neck chapters introduce significant changes from the 7th edition ([supplementary Table S1](https://doi.org/10.1016/j.annonc.2020.07.011), available at

<https://doi.org/10.1016/j.annonc.2020.07.011>).<sup>20</sup> The 8th edition takes new prognostic factors into account to better predict patient survival based on disease stage. In this context, it is important to outline that TNM staging is a prognostic factor and that current treatment strategies of SCCHN should not be modified based on any new classifications. The main modifications to the UICC TNM 8th edition are described in the [supplementary text](https://doi.org/10.1016/j.annonc.2020.07.011), available at <https://doi.org/10.1016/j.annonc.2020.07.011>.

### Pre-treatment risk assessment

The objective of any treatment strategy for SCCHN is to achieve the highest possible cure rate with the lowest risk of morbidity. As such, treatment proposals should integrate both objective tumour parameters (e.g. tumour location, tumour histology, T stage, N stage) and patient parameters (e.g. physiological age, comorbidities, previous history of cancer, occupation, expected functional outcome, personal preference).

In this framework, in addition to locoregional staging, every patient should undergo evaluation of their nutritional status, comorbidities, cardiopulmonary and renal function, frailty index (for geriatric patients), psychological and social status and dental status with rehabilitation in case of foreseen RT [III, A]. In case of significant malnutrition, defined as weight loss of more than 10% during the 6 months before diagnosis, nutritional improvement via enteral route through a feeding tube is highly recommended before starting treatment [II, A]. Percutaneous gastrostomy is generally preferred to a nasogastric feeding tube for long-term enteral support.

The optimal treatment strategy must be discussed in a multidisciplinary team (MDT) including not only the main treatment disciplines (surgery, radiation oncology, medical oncology) but also the disciplines involved in diagnosis (radiology, nuclear medicine, pathology) and treatment support (e.g. nutritionist, research nurse, psychologist) [III, A]. Patients should also be treated at high-volume facilities as this has been reported as a strong and significant prognostic factor [II, A].<sup>21</sup>

### Recommendation

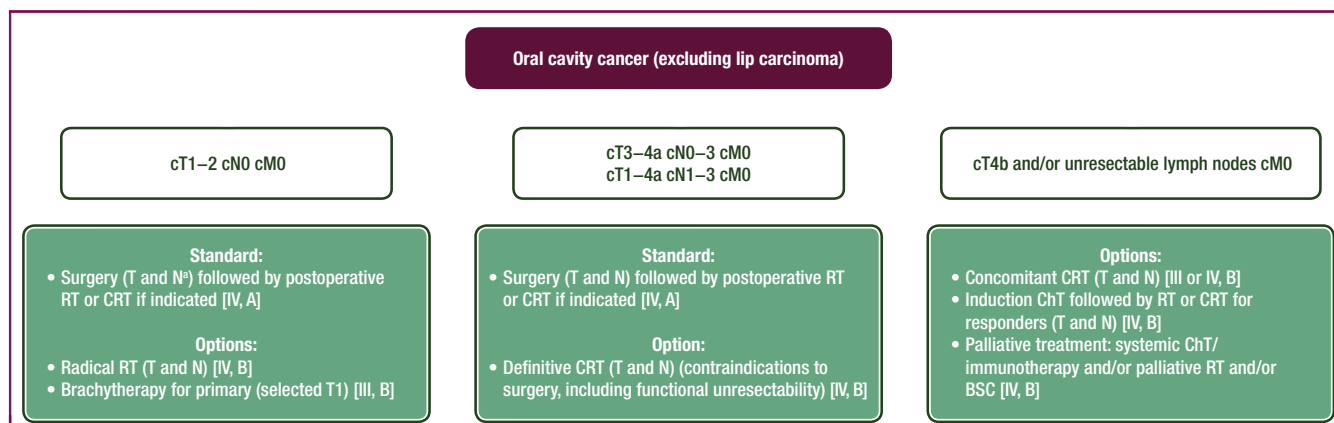
- The UICC TNM 8th edition staging system should be used.

## TREATMENT

### Management of local/locoregional disease

A summary of therapeutic regimens for SCCHN is shown in [supplementary Table S2](https://doi.org/10.1016/j.annonc.2020.07.011), available at <https://doi.org/10.1016/j.annonc.2020.07.011>, and proposed management strategies for oral cavity, laryngeal, oropharyngeal and hypopharyngeal cancers are illustrated in [Figures 1–4](#). All treatment recommendations are based on staging according to the UICC TNM 8th edition.

In case of RT, all patients should be treated by intensity-modulated RT (IMRT) or its variant volumetric-modulated arc therapy (VMAT) [I, A]. The overall treatment



**Figure 1. Management of oral cavity cancer (stage I–IVB) excluding lip carcinoma.**

BSC, best supportive care; ChT, chemotherapy; CRT, chemoradiotherapy; DOI, depth of invasion; M, metastasis; N, node; RT, radiotherapy; T, tumour.

<sup>a</sup> if DOI <10 mm: sentinel lymph node biopsy is a valid option; if DOI <5 mm and cT1N0, active surveillance of the neck is a valid option.

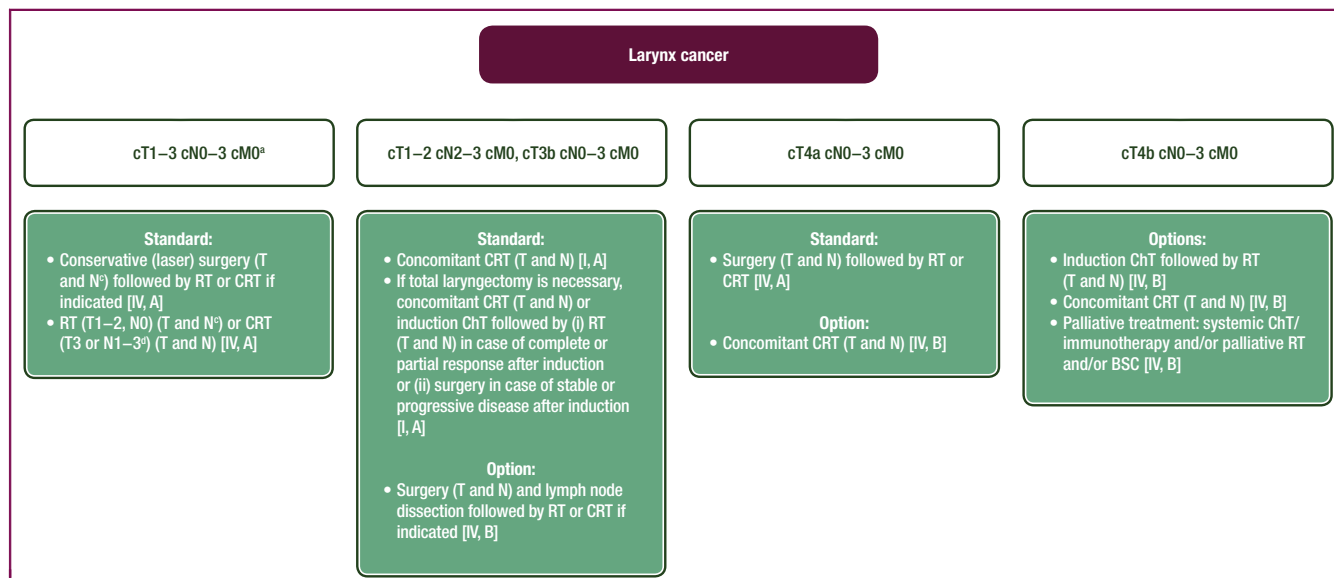
time of RT has been shown to influence the probability of local control, and any treatment delays should be avoided or compensated. International consensus guidelines have been published for the optimal selection of node levels as a function of tumour location as well as for the delineation of these levels in the neck.<sup>22,23</sup> Consensus guidelines have also been published for the delineation of the primary tumour target volumes.<sup>24</sup> Although promising data have been published favouring the use of proton therapy instead of megavoltage X-rays, there are no randomised clinical trial data available to recommend the routine use of intensity-modulated proton therapy (IMPT).<sup>25</sup>

**Early stage disease.** Early stage disease is defined as either T1–2N0 (stage I and II) oral cavity, laryngeal, hypopharyngeal and p16-negative oropharyngeal cancer or T1–2N0 p16-positive oropharyngeal cancer according to the UICC TNM 8th edition.

In early-stage disease, conservative surgery or RT [external beam RT (EBRT) or brachytherapy for selected stage I oropharyngeal or oral cavity subsites] gives similar locoregional control [IV, A]. However, this is based on retrospective studies only and there are no randomised trials available for reference.

In the absence of high-level evidence, the choice between these two modalities should be based on assessment of functional outcome and treatment morbidity for an individual patient as well as institutional and patient preferences and experience. Early disease should be treated as much as possible with a single-modality treatment (surgery or RT) [IV, A].

**Surgery.** Minimally-invasive surgical treatments, including transoral laser microsurgery (TLM) and transoral robotic surgery (TORS), offer the potential for organ preservation with less functional morbidity than open surgery and often



**Figure 2. Management of laryngeal cancer (stage I–IVB).**

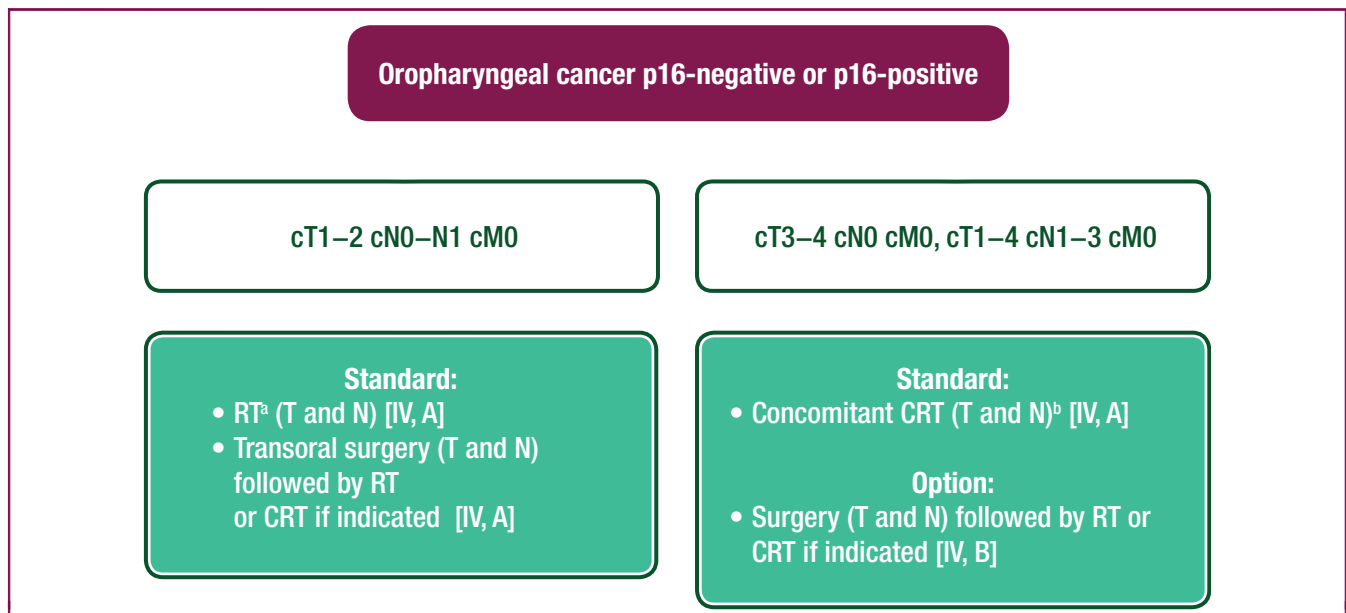
BSC, best supportive care; ChT, chemotherapy; CRT, chemoradiotherapy; M, metastasis; N, node; RT, radiotherapy; T, tumour.

<sup>a</sup> Not requiring total laryngectomy.

<sup>b</sup> Requiring total laryngectomy.

<sup>c</sup> cT1–2N0 glottic cancer does not require neck dissection or neck RT.

<sup>d</sup> Altered fractionation (accelerated or hyperfractionated) RT is a valid option for selected T3 or T3N1.



**Figure 3. Management of oropharyngeal cancer (p16-negative stage I–IVB; p16-positive stage I–III).**

CRT, chemoradiotherapy; M, metastasis; N, node; RT, radiotherapy; T, tumour.

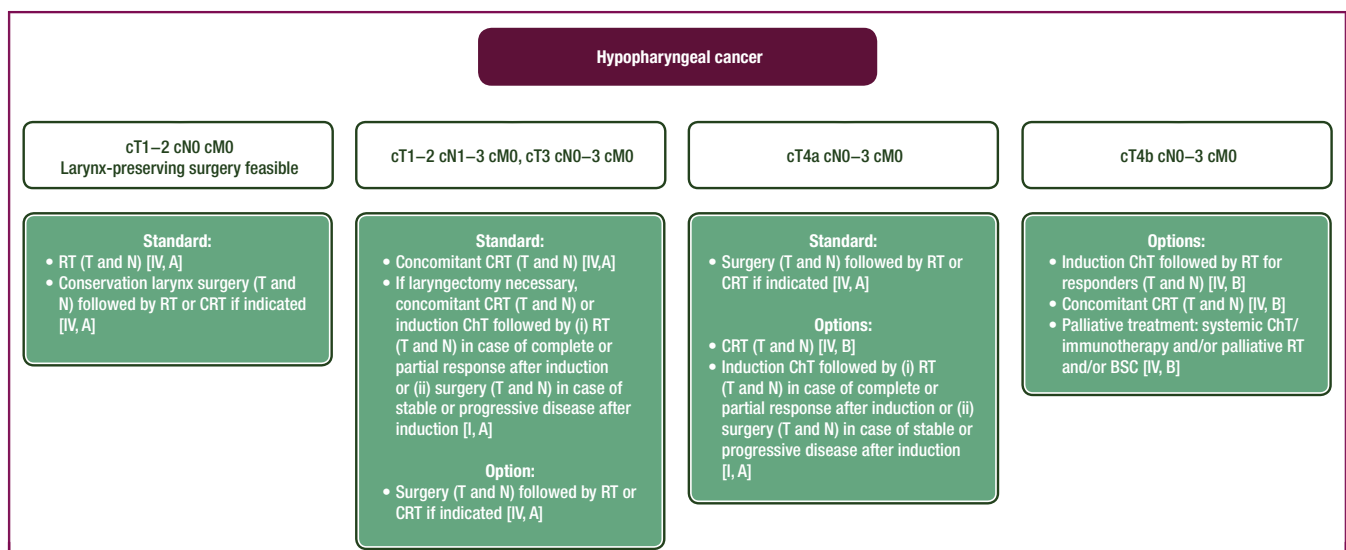
<sup>a</sup> Altered fractionation (accelerated or hyperfractionated) RT is a valid option for T1–N1, T2–N0 or T2–N1.

<sup>b</sup> Altered fractionation (accelerated or hyperfractionated) RT is a valid option for T1–N1 or T2–N1.

less long-term toxicity than RT providing the extent of resection does not jeopardise the functional outcome (e.g. speech and swallowing) and is unlikely to require postoperative RT [V, B].<sup>26</sup> This is especially relevant given the increasing incidence of HPV-positive SCCHN as these patients tend to be younger and have a better long-term prognosis than those with HPV-negative SCCHN. This changing patient profile has strengthened interest in functional organ preservation surgery to improve functional outcomes and quality of life (QoL) in these patients. However, this issue is still not settled, as demonstrated by the randomised ORATOR trial which did not demonstrate any QoL advantage at 2 years when TORS (with or without

postoperative RT) was compared with RT [with or without concomitant chemotherapy (ChT)] for the treatment of oropharyngeal SCC, although long-term outcomes with TORS have not yet been reported.<sup>27</sup>

In early-stage disease, transoral surgery is usually recommended as a single-modality treatment for oral cavity, oropharyngeal and laryngeal lesions [IV, A]. The surgical technique will depend on the location of the tumours and patient-related factors. Despite the lack of randomised trials, recent data suggest that the oncological outcomes of TORS for oropharyngeal cancer is comparable to open surgery and (C)RT [IV, A].<sup>28</sup> Despite the growing popularity of TORS in the treatment of oropharyngeal cancer, this



**Figure 4. Management of hypopharyngeal cancer (stage I–IVB).**

BSC, best supportive care; ChT, chemotherapy; CRT, chemoradiotherapy; M, metastasis; N, node; RT, radiotherapy; T, tumour.

approach has several potential drawbacks. Importantly, the use of TORS does not obviate the need for postoperative RT in some cases. Although the head and neck are relatively accessible, access and manoeuvrability are sometimes limited by anatomical restrictions. Although TLM is currently considered a standard of care for early glottic cancer, TORS has also been used to treat early-stage glottic carcinomas but data are currently limited.<sup>29</sup>

With the exception of T1–2 glottic cancer, ipsilateral selective neck dissection (bilateral in near-midline tumours) or sentinel node biopsy is recommended for cT1–2 SCCHN tumours that are treated with primary surgery [I, A].<sup>30–32</sup>

**RT.** Early-stage disease can be treated by RT alone without any use of concomitant or induction ChT [IV, A]. For stage I disease, a standard fractionation regimen with a primary tumour dose ranging from 66 to 70 Gy depending on the tumour volume and location is recommended [IV, A]. For stage II disease, a slightly more intense RT delivery is recommended with either hyperfractionation with slightly higher total dose (e.g. 80.5 Gy delivered in 70 fractions of 1.15 Gy twice daily over 7 weeks) or moderately accelerated RT with a similar RT dose (e.g. 66–70 Gy delivered in 33–35 fractions of 2 Gy over 5.5–6 weeks) [I, A].<sup>33</sup> It is beyond the scope of this publication to distinguish the respective merit of these regimens, and interested readers should refer to specialised publications on this topic. Such regimens could also be offered to patients with T1 or T2 tumours and neck disease with a single positive lymph node of <3 cm.

Several randomised controlled trials and a meta-analysis have demonstrated that the use of hypoxic sensitisers improved locoregional control and disease-specific survival after RT [I, A].<sup>34</sup> This radiosensitisation is achieved irrespective of the RT fractionation regimen and the modification of hypoxia used.

Except for T1 glottic laryngeal tumours, prophylactic nodal RT is required up to an equivalent dose of 50 Gy delivered in fractions of 2 Gy; in case of a single positive lymph node of <3 cm, the RT dose should be increased to 70 Gy.

Altered fractionation RT results in a significant increase in acute grade 3–4 mucositis to around 40% compared with 25% for standard RT, an increase in the need for a feeding tube during RT and a non-significant increase in late RT-induced morbidity.<sup>33</sup>

Although HPV-driven SCCHN is known to be more sensitive to RT, there are no data to suggest that the total RT dose can be decreased in p16-positive oropharyngeal tumours [IV, A]. No robust, mature clinical trial data are available to convincingly guide treatment between minimally invasive surgery or RT for node negative p16-positive T1 or T2 tumours [V, B].<sup>26</sup>

Finally, for appropriately selected stage I oral cavity and oropharyngeal tumours, brachytherapy remains an option [IV, A].<sup>35</sup> The use of brachytherapy in the head and neck region is, however, on the decline due to lack of physician expertise, the need to combine it with EBRT (or surgery) to treat the neck and the availability of alternative surgical

options with very low morbidity, especially for oral cavity tumours.

**Locally advanced disease.** Locally advanced disease is defined as either stage III or IV oral cavity, larynx, hypopharynx and p16-negative oropharyngeal cancer, or T3–4/N0–3 and T0–4/N1–3 p16-positive oropharyngeal cancer according to the UICC TNM 8th edition.

Standard options for locally advanced SCCHN are either surgery plus adjuvant (C)RT or primary CRT alone. In principle, the use of hypoxic radiosensitisers can also be used with CRT, although the published meta-analysis only reviewed patients treated with RT alone. The surgical option includes reconstruction plus risk-adapted postoperative RT or CRT [I, A]. Primary combined concomitant CRT is the standard treatment in non-resectable patients and is also indicated in resectable patients when the anticipated functional outcome and/or the prognosis is so poor that mutilating surgery is not justified.

**Surgery.** Primary surgical treatment is recommended for T3/T4 oral cavity and T4 laryngeal cancers [III, A]. Advanced hypopharyngeal cancers may also be treated surgically, especially when there is laryngeal cartilage invasion (i.e. stage T4) or a non-functional larynx [III, A]. Treatment of advanced oropharyngeal lesions is currently non-surgical for both HPV-positive and -negative disease, but surgery can be employed if RT is contraindicated.<sup>36</sup>

For oral cavity cancers, wide surgical excision followed by appropriate reconstruction needs to be employed: a free vascularised soft tissue flap when the continuity of the mandible is intact and a bony flap if not. The radial forearm and anterolateral thigh flaps and the fibula flap are the preferred options, respectively. During total laryngopharyngectomy, the pharyngeal mucosa may need reinforcing or patching with a free soft tissue flap or a pedicled flap. The smaller oropharyngeal lesions may be resected transorally (with or without TORS), but the larger ones may require a mandibular swing approach.<sup>36</sup>

Almost invariably, surgically treated tumours will need postoperative RT or CRT depending on the pathological report. When the patient has a relatively small primary tumour but a large neck mass, the appropriate treatment must be decided by an MDT. Except for oral cavity cancer, a primary non-surgical option will usually be chosen with surgery reserved for salvage treatment; occasionally, neck surgery before CRT may be considered.<sup>36</sup>

**Concomitant CRT.** For locally advanced disease, the use of concomitant CRT has resulted in greater locoregional control and improved overall survival (OS) compared with RT alone [I, A].<sup>37</sup> This benefit was observed irrespective of the tumour location in the oral cavity, pharynx or larynx.<sup>38</sup> The largest benefit was observed with cisplatin-based RT, and a total dose of  $\geq 200$  mg/m<sup>2</sup> cisplatin is recommended [II, A].<sup>39,40</sup> The benefit of concomitant CRT has been observed with a standard fractionation regimen as well as for altered fractionation regimens. However, when

accelerated RT is used (i.e. 70 Gy in 6 weeks), the addition of two courses of cisplatin (100 mg/m<sup>2</sup>) has been shown to be equivalent to three courses given concomitantly to a 7-week RT regimen but with the advantage of improved ChT compliance [I, A].<sup>41</sup> A comparison of weekly cisplatin (30 mg/m<sup>2</sup>) and 3-weekly cisplatin carried out in a randomised trial of mainly postoperative patients showed that weekly cisplatin was inferior [II, E].<sup>42</sup> Whether weekly cisplatin at a dose of 40 mg/m<sup>2</sup> is equivalent to 3-weekly dosing (at 100 mg/m<sup>2</sup>) has never been directly compared as the primary curative treatment, but for fit patients, the indirect evidence favours the latter [II, A].<sup>42</sup> Platinum combined with 5-fluorouracil (5-FU) has also been shown to improve survival and is a valid option in patients who cannot tolerate high-dose cisplatin [II, A].<sup>37,43,44</sup>

RT with concomitant cetuximab has demonstrated improved locoregional control, progression-free survival (PFS) and OS compared with RT alone [II, A].<sup>45</sup> Recently, two randomised trials have reported results in patients with p16-positive oropharyngeal SCCHN treated with either concomitant 3-weekly cisplatin (100 mg/m<sup>2</sup>) and RT (70 Gy) or weekly concomitant cetuximab (250 mg/m<sup>2</sup>) and the same RT regimen. Although these two trials enrolled slightly different patient populations (i.e. low-risk patients in the UK De-Escalate study and all-risk patients in the RTOG 1016 study), both trials demonstrated a shorter OS in the cetuximab arm with no reduction in acute or late morbidity rates.<sup>46,47</sup> How concomitant cetuximab-RT compares with concomitant cisplatin-RT in patients with locally advanced, HPV-negative tumours is unknown but CRT is recommended, with cetuximab reserved for patients considered unfit for platinum-based CRT [II, A]. In these patients, the use of altered fractionation RT should be considered since this improves survival [I, A].<sup>33</sup> Also, the use of cetuximab has not been shown to improve OS or PFS when given with concomitant 3-weekly cisplatin and RT in patients with locally advanced, stage III and IV SCCHN [I, E].<sup>48</sup> Finally, the use of induction ChT followed by concomitant CRT irrespective of tumour response for non-laryngeal or hypopharyngeal tumours has not been shown to be superior to concomitant CRT alone [I, E].<sup>49</sup>

There are no data to suggest that treatment intensity should be de-escalated in patients with p16-positive oropharyngeal SCC [IV, A] and so omitting concomitant ChT or replacing ChT with cetuximab is not endorsed.<sup>50</sup>

The use of concomitant CRT results in a significant increase in acute and late treatment-related morbidity, including treatment-related death, underlining the need for careful patient selection.<sup>51</sup> RT-induced swallowing impairment and aspiration is thought to be responsible for the lower 10-year OS of concomitant CRT compared with induction ChT followed by RT for responders in locally advanced laryngeal SCC, although the larynx preservation rate is higher for concomitant CRT. In the latter study,<sup>51</sup> patients were not treated with IMRT or VMAT. It is likely that the use of modern RT techniques could substantially decrease the rate of late RT-related morbidity.

**Induction ChT.** For larynx preservation, two approaches are validated: concomitant CRT and induction ChT (three courses) followed by RT alone [I, A]. The rate of larynx preservation is higher with concomitant CRT but survival is similar to induction ChT followed by RT.<sup>52</sup> In patients with locally advanced laryngeal or hypopharyngeal SCCHN who would require a total laryngectomy or pharyngolaryngectomy, the use of induction ChT with a platinum-based combination has been associated with organ preservation by identifying those patients who could benefit from RT alone [I, A].<sup>53,54</sup> The introduction of taxane/platinum/5-FU (TPF) combinations has proven superior to platinum/5-FU schedules and TPF is now the standard induction ChT regimen [I, A].<sup>55-57</sup> The use of organ preservation with induction ChT (three courses) has not been shown to improve OS compared with surgery, although patients undergoing organ preservation tend to have a reduction in distant metastasis. It should be emphasised that induction ChT followed by concomitant CRT has not been shown to improve outcome and the overall toxicity of this approach can be substantial, thus compromising the final results. Also, not all patients with locally advanced laryngeal or hypopharyngeal cancer should be offered induction ChT. Patients with massive larynx cartilage invasion (T4a), extra-laryngeal extension (T4a) or with severely impaired laryngeal function should be excluded from a larynx preservation strategy and offered upfront surgery [III, A].

Outside of a laryngeal-preservation strategy, the role of induction ChT is not recommended and the standard regimen is concomitant CRT with high-dose (100 mg/m<sup>2</sup>) cisplatin when a non-surgical approach is preferred [I, A]. In the locally advanced setting, induction ChT has been prospectively compared with concomitant CRT in five trials without any strong evidence of improving patient outcomes.<sup>58-62</sup>

**Neck dissection after CRT.** For patients with nodal disease treated by RT or concomitant CRT, the necessity to carry out a systematic neck node dissection before or after the locoregional treatment has always been debated. A randomised trial compared systematic neck node dissection before or after concomitant CRT for locally advanced nodal disease to a neck node dissection carried out only in patients with a positive or equivocal FDG-PET/CT at 12 weeks after the completion of locoregional treatment.<sup>8</sup> With a medial follow-up of 36 months, the 2-year OS rate was similar in both arms (81.5% in the systematic neck dissection group and 84.9% in the surveillance group), thus validating a surveillance policy in case of negative FDG-PET and normal size lymph nodes at 12 weeks post-CRT [I, A]. However, evaluation of FDG-PET response can be challenging. The five-point scale (Hopkins Criteria) to assess response is therefore recommended.<sup>63</sup>

**Postoperative (C)RT.** When a surgical option is preferred as the primary treatment modality, postoperative RT may be required to decrease the risk of locoregional recurrence. Several risk factors for locoregional recurrence have

been identified such as pT3–4 (UICC TNM 8th edition), positive margin (tumour ≤1 mm from the margin), close resection margin (between 1 and 5 mm), perineural infiltration, lymphovascular spread, >1 invaded lymph node and the presence of extracapsular nodal infiltration.<sup>64</sup> It should be noted that these risk factors have been established mainly for oral cavity cancers; margins at other sites (especially oropharynx and larynx) should be interpreted with caution and lesser distance to the margin is often appropriate.

For patients with one or more of these risk factors, prospective studies have validated the use of postoperative RT up to a dose of 58 Gy (only one risk factor) or 63–64 Gy (several risk factors) [II, A].<sup>64,65</sup> For patients with only one lymph node invaded without other adverse features, postoperative RT is optional as long as at least 15 lymph nodes have been analysed. Furthermore, pooled data from two randomised studies (EORTC 22931 and RTOG 9501) have shown that for patients with an R1 resection and extracapsular spread, concomitant CRT (66 Gy) with high-dose cisplatin (100 mg/m<sup>2</sup> every 3 weeks) improved OS compared with the same dose of RT alone [I, A].<sup>66,67</sup> Recently, weekly cisplatin at a dose of 40 mg/m<sup>2</sup> plus RT has been shown to be non-inferior to high-dose cisplatin (100 mg/m<sup>2</sup>) plus RT for postoperative high-risk SCCHN patients.<sup>68</sup> Irrespective of the regimen, postoperative RT should be started within 6–7 weeks after surgery and/or the treatment regimen of surgery and postoperative RT should be delivered within 11 weeks [II, A].<sup>69</sup>

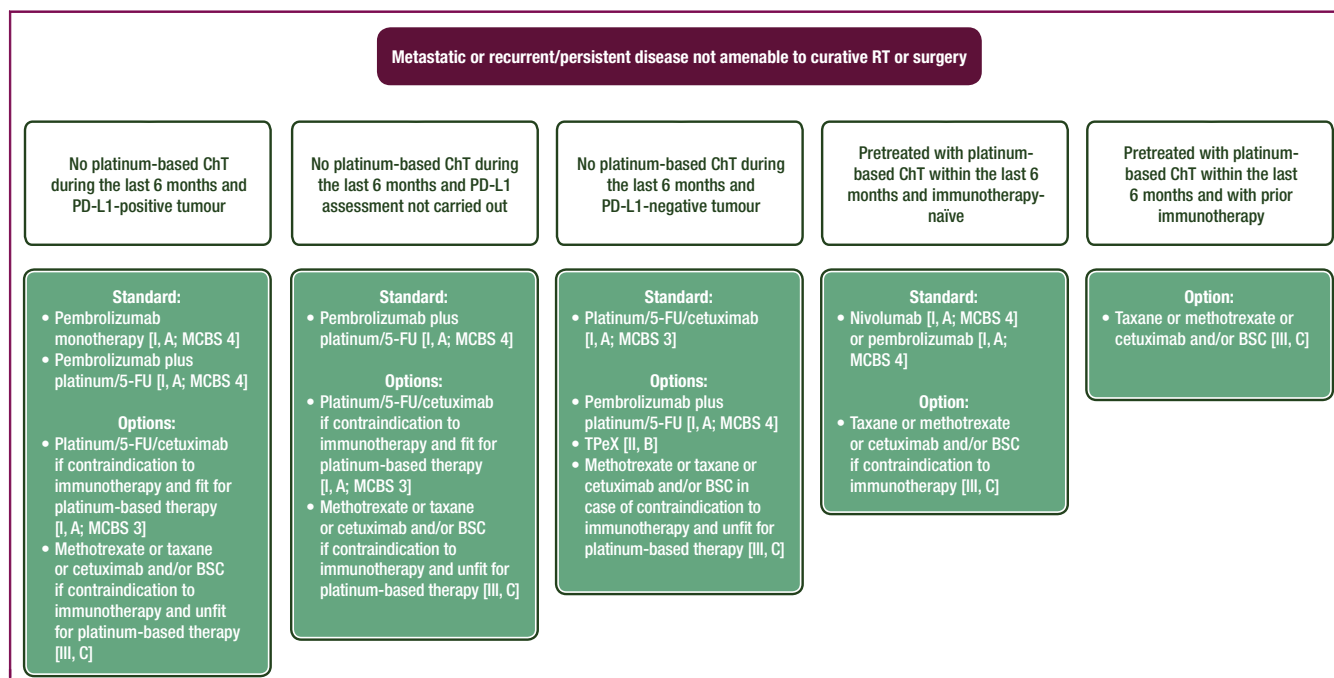
**Unknown primary.** An SCCHN with an unknown primary is an SCC localised in (a) neck lymph node(s) but without any

mucosal primary identified. The diagnostic work-up of these patients includes an FDG-PET, head and neck imaging (preferably MRI), and a panendoscopy under general anaesthesia with bilateral tonsillectomy and a mucosectomy of the base of the tongue in case of HPV-positive disease [III, A].<sup>70</sup> For p16-positive SCC, HPV status should be confirmed with a specific HPV (DNA, RNA or ISH) test. However, the treatment of HPV-positive and -negative disease is the same.

Treatment of SCCHN with an unknown primary is either primary surgery (neck dissection) alone or followed by RT or CRT based on the same postoperative risk factors as other SCCHN subsites,<sup>64,65</sup> or primary RT or CRT (see above for doses and combinations with ChT) followed by neck dissection in case of residual disease [III, A].<sup>66,67</sup> The type of neck dissection should be based on the extent of nodal disease both in the non-operated situation and after prior nodal excision [e.g. for a single level II node, selective (levels Ib, II and III) dissection is indicated]. Patients with pN1 disease and no other risk factor do not require postoperative RT if at least 15 nodes have been analysed. Total mucosal RT is controversial; it is associated with significant morbidity even in the IMRT/VMAT era and is not recommended. Oropharynx RT can be considered as an option in some cases [III, B].<sup>71</sup>

**Management of recurrent and/or metastatic disease**

Few patients (<5%) present with upfront metastases. Around 50% of patients with locally advanced SCCHN will recur after primary treatment with distant metastases and/or local or regional disease.<sup>72</sup>



**Figure 5. Management of recurrent and/or metastatic disease not amenable to curative RT or surgery.**

5-FU, 5-fluorouracil; BSC, best supportive care; ChT, chemotherapy; CRT, chemoradiotherapy; M, metastasis; N, node; PD-L1, programmed death-ligand 1; RT, radiotherapy; T, tumour; TPeX, cisplatin/docetaxel/cetuximab.



A summary of management strategies for recurrent and/or metastatic SCCHN is illustrated in Figure 5. In selected patients with oligometastatic disease at diagnosis, local and/or regional treatment (with surgery or RT) can be considered for treatment with curative intent, especially after a response to upfront systemic treatment [II, C].<sup>72</sup> On the other hand, in the presence of a high burden of distant metastases (e.g. more than two distant sites, mainly visceral involvement), starting systemic treatment is a priority and locoregional treatment should be carried out only if symptoms occur [II, C].

Patients with local or locoregional recurrence should be referred to a reference tertiary centre where they will be discussed within an MDT to consider the possibility of a curative treatment strategy, e.g. salvage surgery or re-irradiation in very selected cases [III, A]. Patients with a good PS and an early-stage laryngeal recurrence occurring more than 2 years after primary treatment can be offered salvage surgery with a reasonable oncological outcome. Conversely, patients with a poor PS and a locally advanced oropharyngeal or hypopharyngeal SCC will likely be offered a palliative local or systemic treatment.

Patients with locoregional recurrence not amenable to surgery and/or RT as well as those with metastatic disease are eligible for systemic treatment. The standard of care first-line therapy for recurrent and/or metastatic disease changed recently. The KEYNOTE-048 study showed that a combination of ChT (cisplatin or carboplatin plus 5-FU) plus pembrolizumab, a monoclonal antibody targeting programmed cell death protein 1 (PD-1), significantly improved OS compared with the EXTREME regimen (cisplatin or carboplatin plus 5-FU plus cetuximab): median OS 13 versus 10.7 months ( $P = 0.0034$ ).<sup>73</sup> Objective response rate (ORR) and PFS were similar between the ChT plus cetuximab and ChT plus pembrolizumab arms [ORR 35.6% and 36.3%, PFS 4.9 and 5.1 months, grade 3–5 adverse events (AEs) 85.1% versus 83.3%, respectively].

In the same trial, pembrolizumab monotherapy also improved median OS in patients with PD-L1-expressing SCCHN: 14.9 versus 10.7 months in the CPS  $\geq 20$  subgroup and 12.3 versus 10.3 months in the CPS  $\geq 1$  subgroup.<sup>73</sup> As expected, pembrolizumab monotherapy was better tolerated than EXTREME (grade 3–5 AEs 54.7% versus 83.3%, respectively). However, PFS with pembrolizumab monotherapy was not satisfactory compared with EXTREME: 3.4 versus 5.0 months in CPS  $\geq 20$  and 3.2 versus 5.0 months in CPS  $\geq 1$ . Similarly, ORR for pembrolizumab monotherapy versus EXTREME was 23.3% versus 36.1% and 19.1% versus 34.9% in the CPS  $\geq 20$  and CPS  $\geq 1$  groups, respectively.

Therefore, based on the KEYNOTE-048 results, two different approaches are validated for patients with locoregional relapse not amenable to locoregional salvage treatment and/or with distant metastases. A 'chemo-free' approach with pembrolizumab monotherapy in patients

with CPS  $\geq 1$  SCCHN should be considered, especially when a rapid tumour shrinkage is not needed [I, A]. A second option, independent of PD-L1 status, is the combination of pembrolizumab and ChT (cisplatin or carboplatin plus 5-FU), particularly in symptomatic patients or when a rapid tumour shrinkage is needed [I, A]. Of note, based on current evidence, we do not know if platinum/5-FU/pembrolizumab improves survival compared with platinum/5-FU/cetuximab in patients with SCCHN not expressing PD-L1. The impact of pembrolizumab on survival in patients with SCCHN and a CPS between 1 and 19 also needs to be clarified.

The Food and Drug Administration (FDA) recently approved pembrolizumab in combination with ChT as first-line treatment regardless of PD-L1 expression and pembrolizumab alone for patients with PD-L1-expressing tumours (CPS  $\geq 1$ ). In contrast, the European Medicines Agency (EMA) has approved pembrolizumab with or without ChT only for patients with a CPS  $\geq 1$  [I, A; ESMO-Magnitude of Clinical Benefit Scale (ESMO-MCBS) v1.1 score: 4].

EXTREME improves OS compared with platinum/5-FU (10.1 versus 7.4 months) and is EMA-approved as first-line treatment in patients with recurrent or metastatic SCCHN [I, A; ESMO-MCBS v1.1 score: 3].<sup>74</sup> Cisplatin/docetaxel/cetuximab (TPeX) showed comparable results to EXTREME in a phase III trial.<sup>75</sup> A retrospective analysis from French sites showed an ORR of 30%, a median PFS of 3.6 months and a median OS of 7.8 months with salvage ChT for patients who progressed on immune checkpoint inhibitors.<sup>76</sup> In the first-line treatment of recurrent SCCHN, EXTREME is standard of care for patients with contraindications to anti-PD-1 inhibitors [I, A] and in patients with a tumour not expressing PD-L1 [II, B]. EXTREME can also be considered as second-line treatment after progression on an immune checkpoint inhibitor in fit patients considered eligible for platinum-based ChT [IV, B]. Similarly, TPeX can be considered as a treatment alternative to EXTREME for some patients [for example, in case of dihydropyrimidine dehydrogenase deficiency (DPD)].

For patients who progress within 6 months of platinum therapy, given either as palliative treatment or with multimodal curative treatment, nivolumab has been shown to improve OS compared with single-agent systemic treatment (cetuximab, docetaxel or methotrexate): 7.5 versus 5.1 months (CheckMate 141).<sup>77</sup> In a very similar study design (KEYNOTE-040), pembrolizumab prolonged median OS compared with standard of care (8.4 versus 6.9 months), although the difference was not statistically significant.<sup>78</sup> In the population with a PD-L1 TPS of  $\geq 50\%$ , median OS was 11.6 months with pembrolizumab and 6.6 months with standard of care.

Nivolumab is both FDA- and EMA-approved in this setting [I, A; ESMO-MCBS v1.1 score: 4]. Pembrolizumab is also approved by the FDA for the same indication and is approved by the EMA for patients whose tumours express PD-L1 with a TPS of  $\geq 50\%$  [I, A].

After progression on platinum-based ChT and anti-PD-1 inhibitors, no standard of care exists. Cetuximab is approved by the FDA after platinum failure [III, C]. This approval was not based on a randomised trial but on data from prospective single-arm studies, which showed that patients progressing on platinum-based ChT treated with cetuximab had a median OS of between 5.2 and 6.1 months.<sup>79</sup>

Taxanes with or without cetuximab and/or methotrexate are frequently used after platinum failure, although no randomised trials have demonstrated their benefit in this setting [III, C].

### Recommendations

- The optimal treatment strategy must be discussed in an MDT including not only the treating physicians but all the supportive specialities [III, A].
- Patients should be treated at high-volume facilities [II, A].
- In case of RT, all patients should be treated by IMRT or VMAT [I, A].
- The treatment strategy for HPV-positive SCCHN should be the same as HPV-negative SCCHN [I, A].
- The recommended treatment option should be based on patient- and treatment-related factors (e.g. side effects, complications, etc.) since conservative surgery and RT may often provide similar locoregional control [IV, A].
- Early disease should be treated as much as possible with a single-modality treatment [IV, A].
- Standard options for locally advanced disease are either surgery plus adjuvant (C)RT or primary concomitant CRT [I, A].
- Primary surgical treatment followed by RT or CRT is the preferred treatment for T3/T4 oral cavity and T4 laryngeal cancers [III, A].
- A hypoxic radiosensitiser increases locoregional control and disease-free survival compared with RT alone [I, A].
- Concomitant CRT increases locoregional control and OS compared with RT alone [I, A].
- The standard of care for ChT is cisplatin at a dose of 100 mg/m<sup>2</sup> given on days 1, 22 and 43 of concomitant RT (70 Gy) [II, A].
- In patients unfit for cisplatin, carboplatin combined with 5-FU or cetuximab concomitant to RT as well as hyperfractionated or accelerated RT without ChT are treatment alternatives [II, A].
- For larynx preservation, induction ChT with TPF (three courses) followed by RT alone is a validated treatment option [I, A].
- Besides larynx preservation, induction ChT is not routinely recommended.
- Neck dissection is not recommended in cases of negative FDG-PET and normal size lymph nodes at 12 weeks post-CRT [I, A].
- Postoperative RT is recommended for patients with pT3–4 tumours, resection margins with macroscopic (R2) or microscopic (R1) residual disease, perineural infiltration, lymphatic infiltration, >1 invaded lymph node and the presence of extracapsular infiltration [II, A].
- Postoperative CRT is recommended for patients with an R1 resection and extracapsular rupture [I, A].
- Postoperative RT or CRT should start within 6–7 weeks of surgery [II, A].
- Pembrolizumab in combination with platinum/5-FU and pembrolizumab monotherapy are two approved regimens for patients with recurrent/metastatic SCCHN expressing PD-L1 (CPS ≥1) [I, A; ESMO-MCBS v1.1 score: 4]. ChT plus pembrolizumab is recommended when rapid tumour shrinkage is needed.
- Platinum/5-FU/cetuximab remains the standard therapy for recurrent/metastatic patients with SCCHN not expressing PD-L1 [I, A; ESMO-MCBS v1.1 score: 3]. TPEx is also a treatment option in this population [II, B].
- Nivolumab is both FDA- and EMA-approved for recurrent/metastatic patients who progress within 6 months of platinum therapy [I, A; ESMO-MCBS v1.1 score: 4].
- DPD testing is recommended before initiating 5-FU.

### PERSONALISED MEDICINE

The primary treatment of local and locoregional disease should be individualised based on disease location, stage and the expected functional outcome.

Opportunities for personalised medicine in SCCHN are shown in Table 2. HPV-induced oropharyngeal cancer has a better prognosis compared with HPV-negative SCCHN.<sup>4</sup> However, treatment de-escalation for HPV-positive oropharyngeal cancer is still investigational and so the treatment strategy for HPV-positive SCCHN should be the same as for HPV-negative SCCHN [I, A].

The efficacy of pembrolizumab or nivolumab is higher in patients with PD-L1-expressing tumours.<sup>73,77,78</sup> PD-L1 staining (CPS) for recurrent/metastatic SCCHN is

**Table 2. Personalised medicine in SCCHN**

Biomarker	Method	Validated use	LoE, GoR
p16	p16 IHC	1. Surrogate marker for HPV-induced oropharyngeal cancer 2. Prognostic factor for oropharyngeal cancer	I, A
PD-L1	PD-L1 IHC (FDA-approved test)	First-line recurrent/metastatic disease to identify patients that may benefit from pembrolizumab monotherapy	I, A

FDA, Food and Drug Administration; GoR, grade of recommendation; HPV, human papilloma virus; IHC, immunohistochemistry; LoE, level of evidence; PD-L1, programmed death-ligand 1.

recommended since pembrolizumab is a first-line treatment option for patients with PD-L1-positive SCCHN [I, A].

### FOLLOW-UP

Patients must be followed closely to detect early locoregional recurrence or new primaries and to monitor long-term treatment toxicities. Therefore, the follow-up should include the whole head and neck MDT, including not only the physicians but the dietician and the speech/swallowing/hearing and psychological specialists.

The risk of disease relapse is estimated at between 40% and 60% for patients with locally advanced disease, with most recurrences occurring within the first 2 years after the primary diagnosis.<sup>37</sup> The incidence of second primaries is 2%–4% per year and remains relatively constant over time.<sup>80</sup>

Clinical follow-up, including a head and neck examination by flexible endoscopy, should be carried out every 2–3 months during the first 2 years, every 6 months for years 3–5 and annually thereafter [III, A]. For locally advanced disease, head and neck imaging is recommended 3 months after the primary treatment to assess the patient status and to have a baseline post-treatment imaging assessment. FDG-PET/CT is recommended 3 months after CRT for patients with node-positive disease to assess the necessity of neck dissection. Otherwise imaging should be carried out if symptoms occur or in case of abnormalities found at the clinical examination [III, A].<sup>81</sup>

For patients treated with RT, daily teeth fluorination, dental evaluation every 6 months and yearly TSH dosage are recommended; tobacco and alcohol withdrawal counselling and psychological support are also recommended, as clinically indicated.

Prevention and screening for other cancers sharing the same risk factors (i.e. lung cancer in smokers, cervical cancer, etc.) should be carried out according to their respective guidelines.<sup>82,83</sup> This is not limited to tobacco and alcohol risks since patients diagnosed with HPV-associated invasive or pre-invasive tumours also have an increased risk of a second HPV-associated cancer.<sup>83</sup>

### Recommendations

- Clinical follow-up including head and neck examination by flexible endoscopy should be carried out every 2–3 months during the first 2 years, every 6 months for years 3–5 and annually thereafter [III, A].
- Imaging should be carried out if symptoms occur or in cases of abnormalities found at the clinical examination [III, A].
- FDG-PET/CT is recommended 3 months after CRT for patients with node-positive disease to assess the necessity of neck dissection [I, A].

### METHODOLOGY

These Clinical Practice Guidelines were developed in accordance with the ESMO standard operating procedures for Clinical Practice Guidelines development, available

at <http://www.esmo.org/Guidelines/ESMO-Guidelines-Methodology>. The relevant literature has been selected by the expert authors. ESMO-MCBS v1.1<sup>84</sup> table with MCBS scores for new therapies/indications as approved by the EMA is included in [supplementary Table S3](#), available at <https://doi.org/10.1016/j.annonc.2020.07.011>. Levels of evidence and grades of recommendation have been applied using the system shown in [supplementary Table S4](#), available at <https://doi.org/10.1016/j.annonc.2020.07.011>.<sup>85</sup> Statements without grading were considered justified standard clinical practice by the experts and the ESMO, EHNS and ESTRO Faculty. This article has been subjected to an anonymous peer review process.

### ACKNOWLEDGEMENTS

The EHNS Executive Board, ESMO Guidelines Committee and ESTRO Executive Board would like to thank the Faculty and other experts who provided critical reviews of these EHNS–ESMO–ESTRO Clinical Practice Guidelines. The authors wish to thank Annalisa Trama and Salvatore Alfieri for their constructive contribution during the writing process. Manuscript editing support was also provided by Angela Corstorphine of Kstorfin Medical Communications Ltd; this support was funded by ESMO.

### FUNDING

No external funding has been received for the preparation of these guidelines. Production costs have been covered by ESMO from central funds.

### DISCLOSURE

JPM reports acting in an advisory role for Merck Serono and MSD; CRL reports acting in an advisory role for Rakuten Medical and MSD. LL reports participation for public speaking/teaching in medical meetings and/or for providing expert opinion in advisory boards for AstraZeneca, Bayer, BMS, Eisai, MSD, Merck Serono, Boehringer Ingelheim, Novartis, Roche, Debiopharm International SA, Sobi, Ipsen, Incyte Biosciences Italy SRL, Doxa Pharma, Amgen, Nanobiotics and GSK. All other authors have declared no potential conflicts of interest.

### REFERENCES

1. Bray F, Ferlay J, Soerjomataram I, et al. Global cancer statistics 2018: GLOBOCAN estimates of incidence and mortality worldwide for 36 cancers in 185 countries. *CA Cancer J Clin*. 2018;68(6):394-424.
2. Gatta G, Capocaccia R, Botta L, et al. Burden and centralised treatment in Europe of rare tumours: results of RARECAREnet-a population-based study. *Lancet Oncol*. 2017;18(8):1022-1039.
3. Taberna M, Mena M, Pavón MA, et al. Human papillomavirus-related oropharyngeal cancer. *Ann Oncol*. 2017;28(10):2386-2398.
4. Ang KK, Harris J, Wheeler R, et al. Human papillomavirus and survival of patients with oropharyngeal cancer. *N Engl J Med*. 2010;363(1):24-35.
5. Cadoni G, Boccia S, Petrelli L, et al. A review of genetic epidemiology of head and neck cancer related to polymorphisms in metabolic genes, cell cycle control and alcohol metabolism. *Acta Otorhinolaryngol Ital*. 2012;32(1):1-11.

6. Senft A, de Bree R, Hoekstra OS, et al. Screening for distant metastases in head and neck cancer patients by chest CT or whole body FDG-PET: a prospective multicenter trial. *Radiother Oncol*. 2008;87(2):221-229.
7. Wong WL, Sonoda LI, Gharpurhy A, et al. 18F-fluorodeoxyglucose positron emission tomography/computed tomography in the assessment of occult primary head and neck cancers—an audit and review of published studies. *Clin Oncol (R Coll Radiol)*. 2012;24(3):190-195.
8. Mehanna H, Wong WL, McConkey CC, et al. PET-CT surveillance versus neck dissection in advanced head and neck cancer. *N Engl J Med*. 2016;374(15):1444-1454.
9. El-Naggar AK, Chan JKC, Takata T, et al. The fourth edition of the head and neck World Health Organization blue book: editors' perspectives. *Hum Pathol*. 2017;66:10-12.
10. Nauta IH, Rietbergen MM, van Bokhoven A, et al. Evaluation of the eighth TNM classification on p16-positive oropharyngeal squamous cell carcinomas in the Netherlands and the importance of additional HPV DNA testing. *Ann Oncol*. 2018;29(5):1273-1279.
11. Fakhry C, Lacchetti C, Rooper LM, et al. Human papillomavirus testing in head and neck carcinomas: ASCO Clinical Practice Guideline endorsement of the College of American Pathologists guideline. *J Clin Oncol*. 2018;36(31):3152-3161.
12. Rassy E, Nicolai P, Pavlidis N. Comprehensive management of HPV-related squamous cell carcinoma of the head and neck of unknown primary. *Head Neck*. 2019;41(10):3700-3711.
13. Cohen EEW, Bell RB, Bifulco CB, et al. The Society for Immunotherapy of Cancer consensus statement on immunotherapy for the treatment of squamous cell carcinoma of the head and neck (HNSCC). *J Immunother Cancer*. 2019;7(1):184.
14. Comprehensive genomic characterization of head and neck squamous cell carcinomas. *Nature*. 2015;517(7536):576-582.
15. Leemans CR, Snijders PJF, Brakenhoff RH. The molecular landscape of head and neck cancer. *Nat Rev Cancer*. 2018;18(5):269-282.
16. Chung CH, Parker JS, Karaca G, et al. Molecular classification of head and neck squamous cell carcinomas using patterns of gene expression. *Cancer Cell*. 2004;5(5):489-500.
17. Keck MK, Zuo Z, Khattri A, et al. Integrative analysis of head and neck cancer identifies two biologically distinct HPV and three non-HPV subtypes. *Clin Cancer Res*. 2015;21(4):870-881.
18. De Cecco L, Nicolau M, Giannoccaro M, et al. Head and neck cancer subtypes with biological and clinical relevance: meta-analysis of gene-expression data. *Oncotarget*. 2015;6(11):9627-9642.
19. Zhang Y, Koneva LA, Virani S, et al. Subtypes of HPV-positive head and neck cancers are associated with HPV characteristics, copy number alterations, PIK3CA mutation, and pathway signatures. *Clin Cancer Res*. 2016;22(18):4735-4745.
20. O'Sullivan B. Head and neck tumours. In: Brierley J, Gospodarowicz MK, Wittekind C, eds. *UICC TNM Classification of Malignant Tumours*. 8 ed. Chichester: Wiley; 2017:17-54.
21. Torabi SJ, Benchetrit L, Kuo Yu P, et al. Prognostic case volume thresholds in patients with head and neck squamous cell carcinoma. *JAMA Otolaryngol Head Neck Surg*. 2019;145:708-715.
22. Biau J, Lapeyre M, Troussier I, et al. Selection of lymph node target volumes for definitive head and neck radiation therapy: a 2019 update. *Radiother Oncol*. 2019;134:1-9.
23. Grégoire V, Ang K, Budach W, et al. Delineation of the neck node levels for head and neck tumors: a 2013 update. DAHANCA, EORTC, HKNPCSG, NCIC CTG, NCRI, RTOG, TROG consensus guidelines. *Radiother Oncol*. 2014;110(1):172-181.
24. Grégoire V, Evans M, Le QT, et al. Delineation of the primary tumour clinical target volumes (CTV-P) in laryngeal, hypopharyngeal, oropharyngeal and oral cavity squamous cell carcinoma: AIRO, CACA, DAHANCA, EORTC, GEORCC, GORTEC, HKNPCSG, HNCIG, IAG-KHT, LPRHHT, NCIC CTG, NCRI, NRG Oncology, PHNS, SBRT, SOMERA, SRO, SSHNO, TROG consensus guidelines. *Radiother Oncol*. 2018;126(1):3-24.
25. Moreno AC, Frank SJ, Garden AS, et al. Intensity modulated proton therapy (IMPT) - the future of IMRT for head and neck cancer. *Oral Oncol*. 2019;88:66-74.
26. Huang SH, Hahn E, Tsang RK, et al. The interplay of IMRT and transoral surgery in HPV-mediated oropharyngeal cancer: getting the balance right. *Oral Oncol*. 2018;86:171-180.
27. Nichols AC, Theurer J, Prisman E, et al. Radiotherapy versus transoral robotic surgery and neck dissection for oropharyngeal squamous cell carcinoma (ORATOR): an open-label, phase 2, randomised trial. *Lancet Oncol*. 2019;20(10):1349-1359.
28. Golusiński W. Functional organ preservation surgery in head and neck cancer: transoral robotic surgery and beyond. *Front Oncol*. 2019;9:293.
29. Kayhan FT, Koc AK, Erdim I. Oncological outcomes of early glottic carcinoma treated with transoral robotic surgery. *Auris Nasus Larynx*. 2019;46(2):285-293.
30. Liao LJ, Hsu WL, Wang CT, et al. Analysis of sentinel node biopsy combined with other diagnostic tools in staging cN0 head and neck cancer: a diagnostic meta-analysis. *Head Neck*. 2016;38(4):628-634.
31. Schilling C, Stoeckli SJ, Haerle SK, et al. Sentinel European Node Trial (SENT): 3-year results of sentinel node biopsy in oral cancer. *Eur J Cancer*. 2015;51(18):2777-2784.
32. D'Cruz AK, Vaish R, Kapre N, et al. Elective versus therapeutic neck dissection in node-negative oral cancer. *N Engl J Med*. 2015;373(6):521-529.
33. Lacas B, Bourhis J, Overgaard J, et al. Role of radiotherapy fractionation in head and neck cancers (MARCH): an updated meta-analysis. *Lancet Oncol*. 2017;18(9):1221-1237.
34. Overgaard J. Hypoxic modification of radiotherapy in squamous cell carcinoma of the head and neck—a systematic review and meta-analysis. *Radiother Oncol*. 2011;100(1):22-32.
35. Mazon JJ, Ardiet JM, Haie-Méder C, et al. GEC-ESTRO recommendations for brachytherapy for head and neck squamous cell carcinomas. *Radiother Oncol*. 2009;91(2):150-156.
36. Wong RJ, Shah JP. The role of the head and neck surgeon in contemporary multidisciplinary treatment programs for advanced head and neck cancer. *Curr Opin Otolaryngol Head Neck Surg*. 2010;18(2):79-82.
37. Pignon JP, le Maître A, Maillard E, et al. Meta-analysis of chemotherapy in head and neck cancer (MACH-NC): an update on 93 randomised trials and 17,346 patients. *Radiother Oncol*. 2009;92(1):4-14.
38. Blanchard P, Baujat B, Holostenco V, et al. Meta-analysis of chemotherapy in head and neck cancer (MACH-NC): a comprehensive analysis by tumour site. *Radiother Oncol*. 2011;100(1):33-40.
39. Szturz P, Wouters K, Kiyota N, et al. Low-dose vs. high-dose cisplatin: lessons learned from 59 chemoradiotherapy trials in head and neck cancer. *Front Oncol*. 2019;9:86.
40. Spreafico A, Huang SH, Xu W, et al. Impact of cisplatin dose intensity on human papillomavirus-related and -unrelated locally advanced head and neck squamous cell carcinoma. *Eur J Cancer*. 2016;67:174-182.
41. Nguyen-Tan PF, Zhang Q, Ang KK, et al. Randomized phase III trial to test accelerated versus standard fractionation in combination with concurrent cisplatin for head and neck carcinomas in the Radiation Therapy Oncology Group 0129 trial: long-term report of efficacy and toxicity. *J Clin Oncol*. 2014;32(34):3858-3866.
42. Noronha V, Joshi A, Patil VM, et al. Once-a-week versus once-every-3-weeks cisplatin chemoradiation for locally advanced head and neck cancer: a phase III randomized noninferiority trial. *J Clin Oncol*. 2018;36(11):1064-1072.
43. Bourhis J, Sire C, Graff P, et al. Concomitant chemoradiotherapy versus acceleration of radiotherapy with or without concomitant chemotherapy in locally advanced head and neck carcinoma (GORTEC 99-02): an open-label phase 3 randomised trial. *Lancet Oncol*. 2012;13(2):145-153.
44. Denis F, Garaud P, Bardet E, et al. Final results of the 94-01 French Head and Neck Oncology and Radiotherapy Group randomized trial comparing radiotherapy alone with concomitant radiochemotherapy in advanced-stage oropharynx carcinoma. *J Clin Oncol*. 2004;22(1):69-76.
45. Bonner JA, Harari PM, Giralt J, et al. Radiotherapy plus cetuximab for squamous-cell carcinoma of the head and neck. *N Engl J Med*. 2006;354(6):567-578.

46. Mehanna H, Robinson M, Hartley A, et al. Radiotherapy plus cisplatin or cetuximab in low-risk human papillomavirus-positive oropharyngeal cancer (De-ESCALaTE HPV): an open-label randomised controlled phase 3 trial. *Lancet*. 2019;393(10166):51-60.
47. Gillison ML, Trotti AM, Harris J, et al. Radiotherapy plus cetuximab or cisplatin in human papillomavirus-positive oropharyngeal cancer (NRG Oncology RTOG 1016): a randomised, multicentre, non-inferiority trial. *Lancet*. 2019;393(10166):40-50.
48. Ang KK, Zhang Q, Rosenthal DI, et al. Randomized phase III trial of concurrent accelerated radiation plus cisplatin with or without cetuximab for stage III to IV head and neck carcinoma: RTOG 0522. *J Clin Oncol*. 2014;32(27):2940-2950.
49. Budach W, Bölke E, Kammers K, et al. Induction chemotherapy followed by concurrent radio-chemotherapy versus concurrent radio-chemotherapy alone as treatment of locally advanced squamous cell carcinoma of the head and neck (HNSCC): a meta-analysis of randomized trials. *Radiother Oncol*. 2016;118(2):238-243.
50. O'Sullivan B, Huang SH, Siu LL, et al. Deintensification candidate subgroups in human papillomavirus-related oropharyngeal cancer according to minimal risk of distant metastasis. *J Clin Oncol*. 2013;31(5):543-550.
51. Machtay M, Moughan J, Trotti A, et al. Factors associated with severe late toxicity after concurrent chemoradiation for locally advanced head and neck cancer: an RTOG analysis. *J Clin Oncol*. 2008;26(21):3582-3589.
52. Forastiere AA, Zhang Q, Weber RS, et al. Long-term results of RTOG 91-11: a comparison of three nonsurgical treatment strategies to preserve the larynx in patients with locally advanced larynx cancer. *J Clin Oncol*. 2013;31(7):845-852.
53. Lefebvre JL, Chevalier D, Lubinski B, et al. Larynx preservation in pyriform sinus cancer: preliminary results of a European Organization for Research and Treatment of Cancer phase III trial. EORTC Head and Neck Cancer Cooperative Group. *J Natl Cancer Inst*. 1996;88(13):890-899.
54. Wolf GT, Fisher SG, Hong WK, et al. Induction chemotherapy plus radiation compared with surgery plus radiation in patients with advanced laryngeal cancer. *N Engl J Med*. 1991;324(24):1685-1690.
55. Vermorken JB, Remenar E, van Herpen C, et al. Cisplatin, fluorouracil, and docetaxel in unresectable head and neck cancer. *N Engl J Med*. 2007;357(17):1695-1704.
56. Posner MR, Hershock DM, Blajman CR, et al. Cisplatin and fluorouracil alone or with docetaxel in head and neck cancer. *N Engl J Med*. 2007;357(17):1705-1715.
57. Janoray G, Pointreau Y, Garaud P, et al. Long-term results of a multicenter randomized phase III trial of induction chemotherapy with cisplatin, 5-fluorouracil, ± docetaxel for larynx preservation. *J Natl Cancer Inst*. 2016;108(4):d36368.
58. Cohen EE, Karrison TG, Kocherginsky M, et al. Phase III randomized trial of induction chemotherapy in patients with N2 or N3 locally advanced head and neck cancer. *J Clin Oncol*. 2014;32(25):2735-2743.
59. Ghi MG, Paccagnella A, Ferrari D, et al. Induction TPF followed by concomitant treatment versus concomitant treatment alone in locally advanced head and neck cancer. A phase II-III trial. *Ann Oncol*. 2017;28(9):2206-2212.
60. Hitt R, Grau JJ, López-Pousa A, et al. A randomized phase III trial comparing induction chemotherapy followed by chemoradiotherapy versus chemoradiotherapy alone as treatment of unresectable head and neck cancer. *Ann Oncol*. 2014;25(1):216-225.
61. Haddad R, O'Neill A, Rabinowits G, et al. Induction chemotherapy followed by concurrent chemoradiotherapy (sequential chemoradiotherapy) versus concurrent chemoradiotherapy alone in locally advanced head and neck cancer (PARADIGM): a randomised phase 3 trial. *Lancet Oncol*. 2013;14(3):257-264.
62. Geoffrois L, Martin L, De Raucourt D, et al. Induction chemotherapy followed by cetuximab radiotherapy is not superior to concurrent chemoradiotherapy for head and neck carcinomas: results of the GORTEC 2007-02 phase III randomized trial. *J Clin Oncol*. 2018;36(31):3077-3083.
63. Marcus C, Ciarallo A, Tahari AK, et al. Head and neck PET/CT: therapy response interpretation criteria (Hopkins Criteria)-interreader reliability, accuracy, and survival outcomes. *J Nucl Med*. 2014;55(9):1411-1416.
64. Peters LJ, Goepfert H, Ang KK, et al. Evaluation of the dose for postoperative radiation therapy of head and neck cancer: first report of a prospective randomized trial. *Int J Radiat Oncol Biol Phys*. 1993;26(1):3-11.
65. Rosenthal DI, Mohamed ASR, Garden AS, et al. Final report of a prospective randomized trial to evaluate the dose-response relationship for postoperative radiation therapy and pathologic risk groups in patients with head and neck cancer. *Int J Radiat Oncol Biol Phys*. 2017;98(5):1002-1011.
66. Bernier J, Dommange C, Ozsahin M, et al. Postoperative irradiation with or without concomitant chemotherapy for locally advanced head and neck cancer. *N Engl J Med*. 2004;350(19):1945-1952.
67. Cooper JS, Pajak TF, Forastiere AA, et al. Postoperative concurrent radiotherapy and chemotherapy for high-risk squamous-cell carcinoma of the head and neck. *N Engl J Med*. 2004;350(19):1937-1944.
68. Kiyota N, Tahara M, Fujii H, et al. Phase II/III trial of postoperative chemoradiotherapy comparing 3-weekly cisplatin with weekly cisplatin in high-risk patients with squamous cell carcinoma of head and neck (JCOG1008). *J Clin Oncol*. 2020;38(15\_suppl):abstr 6502.
69. Ang KK, Trotti A, Brown BW, et al. Randomized trial addressing risk features and time factors of surgery plus radiotherapy in advanced head-and-neck cancer. *Int J Radiat Oncol Biol Phys*. 2001;51(3):571-578.
70. Fu TS, Foreman A, Goldstein DP, et al. The role of transoral robotic surgery, transoral laser microsurgery, and lingual tonsillectomy in the identification of head and neck squamous cell carcinoma of unknown primary origin: a systematic review. *J Otolaryngol Head Neck Surg*. 2016;45(1):28.
71. Maghami E, Ismaila N, Alvarez A, et al. Diagnosis and management of squamous cell carcinoma of unknown primary in the head and neck: ASCO Guideline. *J Clin Oncol*. 2020;38:2570-2596.
72. Leeman JE, Li JG, Pei X, et al. Patterns of treatment failure and post-recurrence outcomes among patients with locally advanced head and neck squamous cell carcinoma after chemoradiotherapy using modern radiation techniques. *JAMA Oncol*. 2017;3(11):1487-1494.
73. Burtneess B, Harrington KJ, Greil R, et al. Pembrolizumab alone or with chemotherapy versus cetuximab with chemotherapy for recurrent or metastatic squamous cell carcinoma of the head and neck (KEYNOTE-048): a randomised, open-label, phase 3 study. *Lancet*. 2019;394(10212):1915-1928.
74. Vermorken JB, Mesia R, Rivera F, et al. Platinum-based chemotherapy plus cetuximab in head and neck cancer. *N Engl J Med*. 2008;359(11):1116-1127.
75. Guigay J, Fayette J, Mesia R, et al. TPEX extreme randomized trial: TPEX versus Extreme regimen in 1st line recurrent/metastatic head and neck squamous cell carcinoma (R/M HNSCC). *J Clin Oncol*. 2019;37(15\_suppl):6002.
76. Saleh K, Daste A, Martin N, et al. Response to salvage chemotherapy after progression on immune checkpoint inhibitors in patients with recurrent and/or metastatic squamous cell carcinoma of the head and neck. *Eur J Cancer*. 2019;121:123-129.
77. Ferris RL, Blumenschein Jr G, Fayette J, et al. Nivolumab for recurrent squamous-cell carcinoma of the head and neck. *N Engl J Med*. 2016;375(19):1856-1867.
78. Cohen EEW, Soulieres D, Le Tourneau C, et al. Pembrolizumab versus methotrexate, docetaxel, or cetuximab for recurrent or metastatic head-and-neck squamous cell carcinoma (KEYNOTE-040): a randomised, open-label, phase 3 study. *Lancet*. 2019;393(10167):156-167.
79. Vermorken JB, Herbst RS, Leon X, et al. Overview of the efficacy of cetuximab in recurrent and/or metastatic squamous cell carcinoma of the head and neck in patients who previously failed platinum-based therapies. *Cancer*. 2008;112(12):2710-2719.
80. León X, García J, López M, et al. Risk of onset of second neoplasms and successive neoplasms in patients with a head and neck index tumour. *Acta Otorrinolaringol Esp*. 2020;71(1):9-15.
81. Imbimbo M, Alfieri S, Botta L, et al. Surveillance of patients with head and neck cancer with an intensive clinical and radiologic follow-up. *Otolaryngol Head Neck Surg*. 2019;161(4):635-642.

82. Postmus PE, Kerr KM, Oudkerk M, et al. Early and locally advanced non-small-cell lung cancer (NSCLC): ESMO Clinical Practice Guidelines for diagnosis, treatment and follow-up. *Ann Oncol*. 2017;28(suppl\_4):iv1-iv21.
83. Marth C, Landoni F, Mahner S, et al. Cervical cancer: ESMO Clinical Practice Guidelines for diagnosis, treatment and follow-up. *Ann Oncol*. 2018;29(suppl\_4):iv262.
84. Cherny NI, Dafni U, Bogaerts J, et al. ESMO-Magnitude of Clinical Benefit Scale version 1.1. *Ann Oncol*. 2017;28(10):2340-2366.
85. Dykewicz CA. Summary of the guidelines for preventing opportunistic infections among hematopoietic stem cell transplant recipients. *Clin Infect Dis*. 2001;33(2):139-144 (adapted from: Gross PA, Barrett TL, Dellinger EP, et al. Purpose of quality standards for infectious diseases. *Clin Infect Dis*. 1994;1918:1421).