

Axillary web syndrome in women after breast cancer surgery referred to an Oncological Rehabilitation Unit: which are the main risk factors? A retrospective case-control study

A. DE SIRE^{1,2}, L. LOSCO³, C. CISARI^{1,4}, A. GENNARI⁵, R. BOLDORINI⁶, N. FUSCO^{7,8}, E. CIGNA³, M. INVERNIZZI¹

¹Department of Health Sciences, Physical and Rehabilitative Medicine, University of Eastern Piedmont, "A. Avogadro", Novara, Italy

²Rehabilitation Unit, "Mons. L. Novarese" Hospital, Moncrivello, Vercelli, Italy

³Department of Translational Research and New Technologies in Medicine and Surgery, Plastic Surgery Unit, University of Pisa, Pisa, Italy

⁴Physical Medicine and Rehabilitation Unit, University Hospital "Maggiore della Carità", Novara, Italy

⁵Division of Medical Oncology, University Hospital "Maggiore della Carità", Novara, Italy

⁶Department of Health Sciences, Pathology Unit, Novara Medical School, Novara, Italy

⁷Department of Oncology and Hemato-Oncology, University of Milan, Milan, Italy

⁸Division of Pathology, IEO, European Institute of Oncology IRCCS, Milan, Italy

Abstract. – **OBJECTIVE:** Axillary web syndrome (AWS) is a complication of surgical procedures in breast cancer (BC) patients. This condition with poorly understood incidence and etiology is characterized by the locoregional development of scar tissue, leading to subcutaneous cording, motion impairment and pain. The early identification of patients at risk for AWS would improve their clinical management. Here, we sought to characterize the prevalence of and the risk factors associated with AWS in BC women after surgery.

PATIENTS AND METHODS: All patients with BC that underwent axillary surgery referred to an Outpatient Service for Oncological Rehabilitation were retrospectively collected. These women were assessed two weeks after the surgical procedure for their clinicopathologic features, type of therapeutic interventions, and AWS presence, laterality, pain, localization, cords type, and number of cords.

RESULTS: Altogether, 177 patients (mean aged 60.65 ± 12.26 years) were included and divided into two groups: AWSPOS ($n=52$; 29.4%) and AWSNEG ($n=125$; 70.6%). Patients with tumor $N \geq 1$ (OR=3.7; $p<0.001$), subjected to mastectomy, axillary lymph node dissection (ALND) and chemotherapy showed significant correlations with AWS onset ($p<0.05$). The range of shoulder motion limitation (OR=11.2; $p<0.001$) and the presence of breast cancer related lymphedema (OR=3.5; $p=0.020$) were associated with AWS.

CONCLUSIONS: Mastectomy, ALND, chemotherapy, low staging tumors, shoulder range of motion limitations, and BCRL represent risk factors for AWS onset. Realizing new strategies for assessing the individual risk of AWS is a crucial clinical need to improve the health-related quality of life of BC survivors.

Key Words:

Axillary web syndrome, Breast cancer, Breast surgery, Rehabilitation, Breast cancer related lymphedema.

Introduction

Breast cancer (BC) is the most common malignant tumor in women and a leading cause of mortality. In the recent past, due to the advances in early diagnosis and effective treatments, the number of long-term survivors has progressively increased¹. Surgical treatment and post-surgery breast reconstruction represent milestones of BC therapeutic interventions²⁻⁴. However, these procedures may lead to post-traumatic stress disorder⁵, wound complications⁶, breast cancer related lymphedema (BCRL)⁷⁻¹¹, BC fatigue¹², and axillary web syndrome (AWS)^{13,14}. All these adverse

events lead to an impairment of the health-related quality of life, thus requiring a prompt, precise, and effective treatment.

AWS is one of the least studied disorders affecting BC survivors, as evidenced by the few papers addressing this topic available in the literature. This condition, also known as cording, is clinically characterized by a visible and/or palpable web of string-like structures (i.e., cords) localized at the subcutaneous level of the site of surgery¹³. The most common sites of AWS are the armpit, the ventral side of the arm, along the forearm, the wrist, hands or on the base of the thumb¹⁵⁻¹⁸. The clinical manifestations of AWS might include dull or burning pain, traction sensation, and range of motion (ROM) limitations in flexion and abduction of the shoulder¹⁹⁻²¹. The incidence of AWS after BC surgery is unclear, ranging from 6%¹³ to 85.4%²². As previously noticed, however, only a handful of studies investigated the prevalence and the main risk factors associated with AWS development^{19,21,23,24}. Among these, axillary lymph node dissection (ALND), the number of lymph nodes removed, and the extent of axillary surgery are currently considered risk factors for AWS development^{23,25}. Moreover, the pathophysiological involvement of the lymphatic and vascular system in AWS development is controversial and a possible correlation between AWS and BCRL is still debated¹⁶.

Realizing new strategies for assessing the individual risk of AWS in BC survivors after surgery is a crucial clinical need, and, to our knowledge, the correlation between AWS onset and tumor-specific biological features and patients' clinical and therapeutic data has not yet been investigated. In this study, we sought to characterize the prevalence of AWS in BC women after surgery referred to an Oncological Rehabilitation Unit. Moreover, we sought to improve AWS risk stratification in BC survivors identifying the role of tumor-specific biological features, coupled with clinical and therapeutic data.

Patients and Methods

Participants

All data from medical records of surgically-treated BC patients referred to the Oncological Rehabilitation Unit of the University Hospital "Maggiore della Carità" in Novara, Italy in a 2-year period from January 2018 to December 2019 were retrospectively collected. The exclu-

sion criteria were the following: a) age <18 years; b) first clinical evaluation after >2 weeks from surgery; c) unavailability of BC pathologic features (i.e., TNM classification, cancer stage, histologic subtype, grading; d) unavailability of therapeutic data; e) other active malignant tumors; f) presence of systemic metastases; g) previous surgery for BC. The study protocol was approved by the local Institutional Review Board and was compliant with the Ethical Guidelines of the responsible governmental agency. Researchers were instructed to protect the participants' privacy, and all the procedures were conducted according to the principles of the Declaration of Helsinki.

Outcome Measures

All patients were clinically assessed by a physiatrist experienced in the evaluation of oncological rehabilitation patients at 2 weeks after BC surgery. The presence of AWS was detected through visual inspection, palpation, passive shoulder ROM evaluation, active shoulder abduction, elbow extension, and wrist extension. The patient was specifically cross-examined on referred pain, upper limb tension and/or functional limitations. A paradigmatic example of AWS after BC surgery is portrayed in Figure 1. The study cohort was divided into two groups, based on the presence or absence of AWS, namely AWS^{POS} and AWS^{NEG}. The study flow-chart is depicted in Figure 2. The following data were collected:

1. BC characteristics: (a) TNM classification; (b)

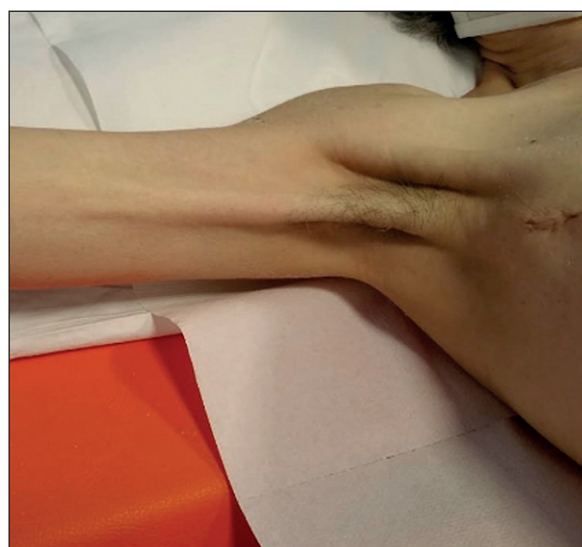

Figure 1. Example of breast cancer women with axillary web syndrome.

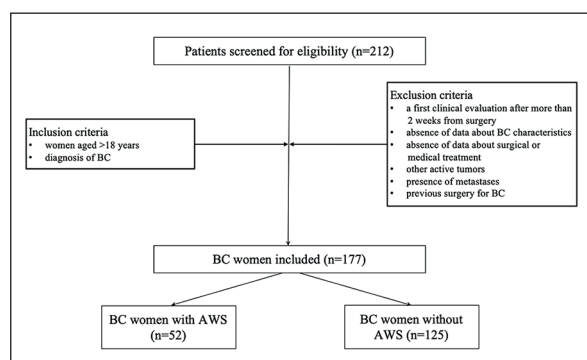


Figure 2. Study flow-chart.

cancer stage; (c) histologic grading; (d) histologic subtype; (e) lymphovascular invasion (LVI); (f) extracapsular extension (ECE) of the lymph node metastasis; (g) estrogen receptor (ER), progesterone receptor (PR), Ki67, and HER2 status.

- Therapeutic data: (a) type of breast surgery (i.e., breast-conserving or mastectomy); (b) ALND; (c) sentinel lymph node biopsy (SLNB); (d) presence of prosthesis; (e) radiation therapy; (f) hormone therapy; (g) chemotherapy; (h) neo-adjuvant chemotherapy; (i) taxanes; (j) trastuzumab; (k) calcium channel blocker (CCB); (l) corticosteroids.
- Clinical features: (a) age; (b) menopause; (c) diabetes type II; (d) other endocrinopathies; (e) shoulder flexion and/or abduction ROM limitations; (f) presence of BCRL; (g) presence of seroma; (h) presence of tissue necrosis; (i) presence of hematoma; (j) presence of scar infection.
- AWS characteristics: (a) laterality; (b) pain; (c) localization; (d) type of cords consistency (i.e. soft or sclerotic); (e) number of cords.

Statistical Analysis

The Shapiro-Wilk test was used to analyze the normal distribution of the variables. The categorical variables were expressed as absolute numbers and percentages, whereas the continuous variables were expressed as means and standard deviations. The differences between the groups were assessed by Fisher exact test for categorical variables and Wilcoxon rank-sum test for continuous variables. Furthermore, odds ratios (OR) with 95% confidence intervals were calculated in terms of all the risk factors, considered as categorical variables. Only *p*-values lower than

0.05 were considered statistically significant. The analyses were performed using GraphPad 6 Package® software (Version 7.0 GraphPad Software Inc. San Diego, CA, USA).

Results

A total of 177 women (mean age: 60.65 ± 12.26 years) were enrolled; 52 (29.4%) were AWS^{POS}, as shown in Figure 2. The presence of AWS was significantly higher in patients with tumor $N \geq 1$ (OR=3.7; $p < 0.001$), compared to those with stage 1 BC (OR=2.4; $p = 0.013$). There were no statistically significant differences between groups in terms of histological grading, type, and all the other specific tumor characteristics assessed (see Table I for further details). Data about surgical and pharmacological treatments are summarized in Table II. Patients that were subjected to performed mastectomy (OR=2.0; $p = 0.039$), ALND (OR=6.8; $p < 0.001$), neo-adjuvant chemotherapy (OR=4.1; $p = 0.016$), and chemotherapy with taxanes (OR=4.0; $p = 0.014$) showed higher risk of AWS development. No significant differences were observed between groups for the other surgical and pharmacological intervention. Shoulder ROM limitation was strongly associated with the presence of AWS after surgery (OR=11.2; $p < 0.001$); BCRL incidence was significantly higher in AWS^{POS} patients (OR=3.5; $p = 0.020$). No significant differences emerged between groups in all the other clinical and demographical characteristics evaluated (Table III). Among AWS^{POS} patients ($n = 52$), 38 (73.1%) had the right arm affected, while and 67.3% of the patients reported pain. The most frequent localization of AWS was at axillary level (59.6%), whereas few patients reported AWS localized at the arm (17.3%), at the cubital fossa (11.5%), and at the forearm (11.5%). The sclerotic consistency was more frequent than the soft type (28.8%). Lastly, considering the number of cords in the AWS group: 33 (63.5%) had a single cord, 15 (28.9%) had 2 cords, and 4 (7.7%) had three cords which were the highest number found in this group.

Discussion

In this study, 29.4% of patients in the entire study cohort of BC women developed AWS within two weeks after surgery. This prevalence was higher compared to previous studies in litera-

Table I. Breast cancer characteristics in the study cohort and differences according to presence of axillary web syndrome.

	Total (n = 177)	BC women AWS ^{POS} (n = 52)	BC women AWS ^{NEG} (n = 125)	p-values
TNM classification				
T1	118 (66.7)	29 (55.8)	89 (71.2)	0.158
N ≥ 1	45 (25.4)	23 (44.2)	22 (17.6)	< 0.001
Cancer stage				
Stage 1	95 (53.7)	20 (38.5)	75 (60.0)	0.013
Histological grading				
G3	65 (36.7)	23 (44.2)	42 (33.6)	0.171
Histological type				
IDC	134 (75.7)	41 (78.8)	93 (74.4)	0.570
LVI	36 (20.3)	15 (28.8)	21 (16.8)	0.099
ECI	28 (15.8)	11 (21.1)	17 (13.6)	0.258
ER+	142 (80.2)	42 (80.8)	100 (80.0)	0.835
PR+	126 (71.2)	38 (73.1)	88 (70.4)	0.856
KI-67 antigen > 15	87 (49.1)	30 (57.7)	57 (45.6)	0.570
HER2/neu+	42 (23.7)	17 (32.7)	25 (20.0)	0.082
FISH+	59 (33.3)	20 (38.5)	39 (31.2)	0.082

Categorical variables are expressed as counts (percentages). Fisher exact test was performed as statistical analysis test. A p value of 0.05 was considered statistically significant. Abbreviations: BC = breast cancer; AWSPOS = with axillary web syndrome; AWSNEG = without axillary web syndrome; IDC: invasive ductal carcinoma; LCIS: lobular carcinoma in situ; ILC: invasive lobular carcinoma; LVI: lymphovascular invasion; ECI: extracapsular invasion; ER: estrogen receptor; PR: progesterone receptor; HER2/neu: human epidermal growth factor receptor 2; FISH: fluorescence in situ hybridization.

ture^{25,26}, confirming that AWS screening should be implemented after BC surgery in order to set up prompt and effective diagnostic and therapeutic interventions.

Our study findings confirm the strong correlation between ALND and AWS development, suggesting that more invasive surgical interventions targeting the lymphatic system could be the cause of a significant increase in the risk of AWS onset.

Although in a 2019 prospective study¹⁷ the type of surgery and TNM “N” classification were excluded as risk factors, we found a higher risk of AWS in women affected by BC with classification N≥1 (OR=3.7; p<0.001). Moreover, for the first time in literature, our data suggest a possible impact of neoadjuvant chemotherapy (OR=4.1; p=0.016) and taxanes in AWS onset (OR=4.0; p=0.014). It is recognized that AWS might affect the func-

Table II. Therapeutic data in the study cohort and differences according to presence of axillary web syndrome.

	Total (n = 177)	BC women AWS ^{POS} (n = 52)	BC women AWS ^{NEG} (n = 125)	p-values
Type of breast surgery				
Conservative	113 (63.8)	27 (51.9)	86 (68.8)	0.039
Mastectomy	64 (36.2)	25 (48.1)	39 (31.2)	0.039
ALND	36 (20.3)	23 (44.2)	13 (10.4)	< 0.001
SLNB	141 (79.7)	29 (55.8)	112 (89.6)	< 0.001
Prosthesis after surgery	43 (24.3)	13 (25)	30 (24)	> 0.999
Radiotherapy	124 (70.1)	35 (67.3)	89 (71.2)	0.595
Hormone therapy	134 (75.7)	38 (73.1)	96 (76.8)	0.701
Neo-adjuvant chemotherapy	11 (6.2)	7 (13.5)	4 (3.2)	0.016
Chemotherapy with taxanes	57 (32.2)	24 (46.1)	33 (26.4)	0.013
Trastuzumab	29 (16.4)	11 (21.1)	18 (14.4)	0.273
Corticosteroids	21 (11.9)	8 (15.4)	13 (10.4)	0.444

Categorical variables are expressed as counts (percentages). Fisher exact test was performed as statistical analysis test. A p value of 0.05 was considered statistically significant. Abbreviations: BC = breast cancer; AWSPOS = with axillary web syndrome; AWSNEG = without axillary web syndrome; ALND: axillary lymph node dissection; SLNB: sentinel lymph node biopsy.

Table III. Clinical features in the study cohort and differences according to presence of axillary web syndrome.

	Total (n = 177)	BC women AWS^{POS} (n = 52)	BC women AWS^{NEG} (n = 125)	p-values
Age (years)	60.7 ± 12.3	60.0 ± 11.8	61.0 ± 12.5	0.737*
Menopause	131 (74.0)	40 (76.9)	91 (79.8)	0.707**
Type 2 diabetes mellitus	11 (6.2)	2 (3.8)	9 (7.2)	0.511**
Other endocrinopathies	41 (23.16)	10 (19.2)	31 (24.8)	0.558**
Shoulder ROM limitation	52 (29.4)	34 (65.4)	18 (14.4)	< 0.001**
Presence of BCRL	16 (9.0)	9 (17.3)	7 (5.6)	0.020**
Presence of seroma	72 (40.7)	23 (44.2)	49 (39.2)	0.615**
Presence of tissue necrosis	3 (1.7)	1 (1.9)	2 (1.6)	0.615**
Presence of hematoma	26 (14.7)	6 (11.5)	20 (16.0)	0.495**
Presence of scar infection	4 (2.3)	1 (1.9)	3 (2.4)	> 0.999**

Continuous variables are expressed as means ± standard deviations; categorical variables are expressed as counts (percentages). Statistical analysis tests performed were: *=Wilcoxon rank sum test; **=Fisher exact test. A p-value of 0.05 was considered statistically significant. Abbreviations: BC = breast cancer; AWSPOS = with axillary web syndrome; AWSNEG = without axillary web syndrome; ROM = range of motion; BCRL = breast cancer related lymphedema; a: in flexion and/or abduction.

tionality of the shoulder. Hence, we observed that 65.4% of AWS^{POS} women suffer ROM limitation in terms of shoulder flexion and/or abduction (OR=11.2; $p < 0.001$). Moreover, more than 2/3 of AWS^{POS} patients reported pain mainly localized at shoulder level, a symptom highly correlated with the functional limitation of the shoulder. Lastly, we confirmed that the most frequent localization of AWS was the axillary level (59.6%), in line with previous data in literature²¹⁻²⁴. Similarly, despite the lack of agreement in the literature about a possible correlation between BCRL and AWS¹⁶, we found a significantly higher prevalence of BCRL in AWS^{POS} women compared to AWS^{NEG}. It has to be noticed that BCRL is strongly related to pain and functional limitation at shoulder level, suggesting a possible overlap between AWS and BCRL as synergistic disability generators in BC survivors. Lastly, in contrast with previous literature^{27,28}, no significant differences were observed in terms of perioperative infections or tissue inflammation.

Albeit AWS is commonly a self-limited condition, which spontaneously resolves usually within 3 months after the onset¹³ a substantial proportion of patients developed chronic AWS lasting for years after surgery and relapses after resolution²³. The incidence is higher in patients who suffered a greater number of lymph nodes removed^{23,29}, which is also a well-known risk factor for the development of BCRL³⁰. Thus, the interruption of axillary lymphatics appears to play a pivotal role in AWS development and this hypothesis is supported by Moskovitz et al¹³ who found no cases of AWS after isolated breast sur-

gery in the absence of axillary node dissection. If AWS cords development is due to an impairment of the lymphatic vessels, recent advancement in reconstructive microsurgery³¹⁻³⁴ might help to downgrade the risk of AWS onset. In this context, vascularized lymph node transfer is a well-established method for the treatment of lymphedema, aimed at improving/restoring the lymphatic drainage of the affected limb and it might help to minimize permanent injury to the lymphatic vessels and surround tissues and slow down the progression of tissue damage³⁵. Some studies^{36,37} also showed the role of lympho-venular anastomosis as an effective surgical strategy to treat lymphoedema. However, at present, data about a possible role of lymph node transfer in reducing AWS onset after BC surgery are lacking; assuming lymphatic dysfunction pathogenesis of AWS, rehabilitation intervention is the most commonly used therapeutic approach to treat this condition.

It is crucial that rehabilitation should be performed by health professionals specialized in oncological rehabilitation treatment. This type of intervention consists of therapeutic exercise and manual therapy protocols, including myofascial release techniques, scar massage, manual lymphatic drainage, and complex decongestive therapy (CDT)³⁸. The latter is the most common therapy for many types of lymphedema, involving manual lymph drainage, compression bandage, skin hygiene practices, lymphedema reduction exercises and compression sleeves or garments application³⁹⁻⁴¹. More in detail, CDT aims at achieving and maintaining volume reduc-

tion⁴⁰, improving shoulder ROM in flexion and abduction, and reducing the number and consistency of cords in AWS patients. The fact that the same therapeutic rehabilitation protocols used for BCRL are the same for AWS treatment suggests again a possible overlap of these two highly disabling pathological conditions after BC surgery. However, to date, there is no clear evidence about the best therapeutic approach to treat BC women affected by AWS.

The main limitation of this study is the retrospective monocentric design that could hinder any robust conclusion about the results obtained. However, it should be noted that few papers in literature addressed this topic and the sample in this study was elevated for focusing on AWS, whose pathophysiological mechanisms underpinning have been not adequately investigated. Therefore, the present study might be considered as a starting point for realizing new strategies in assessing the individual risk of AWS in BC survivors after surgery.

Conclusions

To the best of our knowledge, this is the first study providing data on the correlation between AWS onset and tumor-specific biological features and patients' clinical and therapeutic data in BC survivors. Albeit AWS is a disabling consequence of BC surgery often overlooked in the scientific literature, in our sample it affects 29.4% of BC survivors. Taken together, our findings suggest that the number of lymph nodes involved, higher grading and staging of the tumor, mastectomy, ALND, chemotherapy, shoulder ROM limitation, and BCRL might be considered as main risk factors in AWS onset after BC surgery. Future studies should focus on improving the individual risk stratification of AWS in order to implement prompt and effective rehabilitative interventions to realize the potential of precision medicine in BC women after surgery.

Conflict of Interest

N.F. has received consultation honoraria from Merck Sharp & Dohme (MSD) and Boehringer Ingelheim. M.I. has received consultation honoraria from ErreKappa. These companies had no role in the design of the study; in the collection, analyses, or interpretation of data; in the writing of the manuscript, and/or in the decision to publish the results. All the other authors declare no conflicts of interest.

Acknowledgements

The authors wish to thank Sabrina Pasqua, MD, Laura Colli, Liviana Ferri, and Salvatore Scaduto for their support in this work.

Authors' Contribution

Study concept and design: MI; data collection: AdS; data analysis: AdS, MI; references: AdS, LL; manuscript writing (first draft): AdS; manuscript critical revision: MI, NF; supervision: MI, CC, NF, and EC; revision and approval of the final draft by all authors.

References

- 1) SIEGEL R.L, MILLER K.D, JEMAL, A. Cancer statistics, 2019. *CA Cancer J Clin.* 2019; 69: 7-34.
- 2) CASELLA D, DI TARANTO G, MARCASCIANO M, SORDI S, KOTHARI A, KOVACS T, LO TORTO F, CIGNA E, RIBUFFO D, CALABRESE C. Nipple-sparing bilateral prophylactic mastectomy and immediate reconstruction with TiLoop® Bra mesh in BRCA1/2 mutation carriers: a prospective study of long-term and patient reported outcomes using the BREAST-Q. *Breast* 2018; 39: 8-13.
- 3) KACIULYTE J, LOSCO L, MARUCCIA M, DELIA G, LO TORTO F, DI TARANTO G, CAPUTO GG, BERCHIOLLI R, RIBUFFO D, CIGNA E. Postsurgical antithrombotic therapy in microsurgery: our protocol and literature review. *Eur Rev Med Pharmacol Sci* 2019; 23: 4448-4457.
- 4) CIUDAD P, MARUCCIA M, ORFANIOTIS G, WENG HC, CONSTANTINESCU T, NICOLI F, CIGNA E, SOCAS J, SIRIMAHACHAIYAKUL P, SAPOUNTZIS S, KIRANANTAWAT K, LIN SP, WANG GJ, CHEN HC. The combined transverse upper gracilis and profunda artery perforator (TUG-PAP) flap for breast reconstruction. *Microsurgery.* 2016; 36: 359-366.
- 5) LOSCO L, CIGNA E. Aesthetic refinements in C-V flap: raising a perfect cylinder. *Aesthet Surg J.* 2018; 38: NP26-NP28.
- 6) MORTENSON MM, SCHNEIDER PD, KHATRI VP, STEVENSON TR, WHETZEL TP, SOMMERHAUG EJ, GOODNIGHT JE JR, BOLD RJ. Immediate breast reconstruction after mastectomy increases wound complications: however, initiation of adjuvant chemotherapy is not delayed. *Arch Surg* 2004; 139: 988-991.
- 7) INVERNIZZI M, CORTI, C, LOPEZ, G, MICHELOTTI, A., DESPINI, L., GAMBINI, D. LORENZINI D, GUERINI-ROCCO E, MAGGI S, NOALE M, FUSCO N. Lymphovascular invasion and extranodal tumour extension are risk indicators of breast cancer related lymphoedema: an observational retrospective study with long-term follow-up. *BMC Cancer* 2018; 18: 935.
- 8) INVERNIZZI M, LOPEZ G, MICHELOTTI A, VENETIS K, SAJJADI E, DE MATTOS-ARRUDA L, GHIDINI M, RUNZA L, DE SIRE A, BOLDORINI R, FUSCO N. Integrating biological advances into the clinical management of breast cancer related lymphedema. *Front Oncol* 2020; 10: 422.

- 9) MICHELOTTI A, INVERNIZZI M, LOPEZ G, LORENZINI D, NE-SA F, DE SIRE A, FUSCO N. Tackling the diversity of breast cancer related lymphedema: perspectives on diagnosis, risk assessment, and clinical management. *Breast* 2019; 44: 15-23.
- 10) INVERNIZZI M, RUNZA L, DE SIRE A, LIPPI L, BLUNDO C, GAMBINI D, BOLDORINI R, FERRERO S, FUSCO N. Integrating augmented reality tools in breast cancer related lymphedema prognostication and diagnosis. *J Vis Exp* 2020; 156: e60093.
- 11) DE SIRE A, LOSCO L, CIGNA E, LIPPI L, GIMIGLIANO F, GENNARI A, CISARI C, CHEN HC, FUSCO N, INV-ERNIZZI M. Three-dimensional laser scanning as a reliable and reproducible diagnostic tool in breast cancer related lymphedema rehabilitation: a proof-of-principle study. *Eur Rev Med Pharmacol Sci* 2020; 24: 4476-4485.
- 12) YANG, S, CHU S, GAO Y, AI Q, LIU Y, LI X, CHEN N. A narrative review of cancer-related fatigue (CRF) and its possible pathogenesis. *Cells* 2019; 8: 738.
- 13) MOSKOVITZ AH, ANDERSON BO, YEUNG RS, BYRD DR, LAWTON TJ, MOE RE. Axillary web syndrome after axillary dissection. *Am J Surg* 2001; 181: 434-439.
- 14) DE SIRE A, INVERNIZZI M., LIPPI L, CISARI C, ÖZÇAKAR L, FRANCHIGNONI F. Blurred lines between axillary web syndrome and Mondor's disease after breast cancer surgery: a case report. *Ann Phys Rehabil Med* 2020 Jul; 63: 365-367.
- 15) FIGUEIRA PVG, HADDAD CAS, DE ALMEIDA RIZZI SKL, FACINA G, NAZARIO ACP. Diagnosis of axillary web syndrome in patients after breast cancer surgery. *Am J Clin Oncol* 2018; 41: 992-996.
- 16) KOEHLER LA, HUNTER DW, BLAES AH, HADDAD TC. Function, shoulder motion, pain, and lymphedema in breast cancer with and without axillary web syndrome: an 18-month follow-up. *Phys Ther* 2018; 98: 518-527.
- 17) DINAS K, KALDER M, ZEPHIDIS L, MAVROMATIDIS G, PRA-TILAS G. Axillary web syndrome: incidence, pathogenesis, and management. *Curr Probl Cancer* 2019; 43: 100470.
- 18) LEDUC O, SICHÈRE M, MOREAU A, RIGOLET J, TINLOT A, DARC S, BORDET IJ. Axillary web syndrome: nature and localization. *Lymphology* 2009; 42: 176-181.
- 19) LEIDENIUS M, LEPPÄNEN E, KROGERUS L, VON SMITTEN K. Motion restriction and axillary web syndrome after sentinel node biopsy and axillary clearance in breast cancer. *Am J Surg* 2003; 185: 127-130.
- 20) FIGUEIRA PVG, HADDAD CAS, DE ALMEIDA RIZZI SKL, FACINA G, NAZARIO ACP. Diagnosis of axillary web syndrome in patients after breast cancer surgery: epidemiology, risk factors, and clinical aspects: a prospective study. *Am J Clin Oncol* 2018; 41: 992-996.
- 21) KOEHLER LA, BLAES AH, HADDAD TC, HUNTER, DW, HIRSCH, AT, LUDEWIG, PM. Movement, function, pain, and postoperative edema in axillary web syndrome. *Phys Ther* 2015; 95: 1345-1353.
- 22) YEUNG WM, MCPHAIL SM, KUYS SS. A systematic review of axillary web syndrome (AWS). *J Cancer Surviv* 2015; 9: 576-598.
- 23) O'TOOLE J, MILLER CL, SPECHT MC, SKOLNY MN, JAMMALO LS, HORICK, N, ELLIOTT K, NIEMIERKO A, TAGHIAN, AG. Cording following treatment for breast cancer. *Breast Cancer Res Treat* 2013; 140: 105-111.
- 24) WERNICKE AG, SHAMIS M, SIDHU KK, TURNER BC, GOLTS-ER Y, KHAN I, CHRISTOS PJ, KOMARNICKY-KOCHER LT. Complication rates in patients with negative axillary nodes 10 years after local breast radiotherapy after either sentinel lymph node dissection or axillary clearance. *Am J Clin Oncol* 2013; 36: 12-19.
- 25) HARRIS SR. Axillary web syndrome in breast cancer: a prevalent but under-recognized postoperative complication. *Breast Care (Basel)* 2018; 13: 132-135.
- 26) LUZ C, DEITOS J, SIOQUEIRA T, PALÚ M, HECK A. Management of axillary web syndrome after breast cancer: evidence-based practice. *Rev Bras Ginecol Obstet* 2017; 39: 632-639.
- 27) RASHTAK S, GAMBLE GL, GIBSON, LE, PITTELKOW, MR. From furuncle to axillary web syndrome: shedding light on histopathology and pathogenesis. *Dermatology* 2012; 224: 110-114.
- 28) WELSH P, GRYFE D. Atypical presentation of axillary web syndrome (AWS) in a male squash player: a case report. *J Can Chiropr Assoc* 2016; 60: 294-298.
- 29) KOEHLER LA, HUNTER DW. Lymphspiration: the axillary web and its lymphatic origin. *Lymphology*. 2016; 49:185-191.
- 30) UGUR S, ARICI C, YAPRAK M, MESCI A, ARICI GA, DOLAY K, OZMEN V. Risk factors of breast cancer-related lymphedema. *Lymphat Res Biol*. 2013; 11: 72-75.
- 31) DI TARANTO G, CHEN SH, ELIA R, SITPAHUL N, CHAN JCY, LOSCO L, CIGNA E, RIBUFFO D, CHEN HC. Outcomes following head neck free flap reconstruction requiring interposition vein graft or vascular bridge flap. *Head Neck* 2019; 41: 2914-2920.
- 32) LOSCO L, LO TORTO F, MARUCCIA M, DI TARANTO G, RIBUFFO D, CIGNA E. Modified single pedicle reverse adipofascial flap for fingertip reconstruction. *Microsurgery* 2019; 39: 221-227.
- 33) LOSCO L, CIAMARRA P, CIGNA E. Comments on "Fenestrated adipofascial reverse flap for the reconstruction of fingertip amputations". *Microsurgery* 2020; 40: 282.
- 34) MARUCCIA M, DI TARANTO G, SCHONAUER F, D'ANDREA F, LOSCO L, RIBUFFO D, CHEN HC, CIGNA E. Freestyle perforator puzzle flap for posterior trunk reconstruction. *Ann Plast Surg* 2020; 85: 56-60.
- 35) RAJU A, CHANG DW. Vascularized lymph node transfer for treatment of lymphedema: a comprehensive literature review. *Ann Surg* 2015; 261: 1013-1023.

- 36) GENNARO P, GABRIELE G, MIHARA M, KIKUCHI K, SALINI C, ABOH I, CASCINO F, CHISCI G, UNGARI C. Supramicrosurgical lymphatico-venular anastomosis (LVA) in treating lymphoedema: 36-months preliminary report. *Eur Rev Med Pharmacol Sci* 2016; 20: 4642-4653.
- 37) GENNARO P, GABRIELE G, SALINI C, CHISCI G, CASCINO F, XU JF, UNGARI C. Our supramicrosurgical experience of lymphaticovenular anastomosis in lymphoedema patients to prevent cellulitis. *Eur Rev Med Pharmacol Sci* 2017; 21: 674-679.
- 38) KOEHLER LA, HADDAD TC, HUNTER DW, TUTTLE TM. Axillary web syndrome following breast cancer surgery: symptoms, complications, and management strategies. *Breast Cancer* 2019; 11: 13-19.
- 39) COHEN SR, PAYNE DK, TUNKEL RS. Lymphedema: strategies for management. *Cancer* 2001; 92: 980-987.
- 40) EZZO, J, MANHEIMER E, MCNEELY ML, HOWELL, DM., WEISS R, JOHANSSON, KI., BAO T, BILY L, TUPPO CM, WILLIAMS AF, KARADIBAK, D. Manual lymphatic drainage for lymphedema following breast cancer treatment. *Cochrane Database Syst Rev* 2015; 5: CD003475
- 41) CHO Y, DO J, JUNG S, KWON O, JEON JY. Effects of a physical therapy program combined with manual lymphatic drainage on shoulder function, quality of life, lymphedema incidence, and pain in breast cancer patients with axillary web syndrome following axillary dissection. *Support Care Cancer* 2016; 24: 2047-2057.