

Accepted Manuscript

Development of a prognostic score to predict response to yttrium-90 radioembolization for hepatocellular carcinoma with portal vein invasion

Carlo Spreafico, Carlo Sposito, Marta Vaiani, Tommaso Cascella, Sherrie Bhoori, Carlo Morosi, Rodolfo Lanocita, Raffaele Romito, Carlo Chiesa, Marco Maccauro, Alfonso Marchianò, Vincenzo Mazzaferro

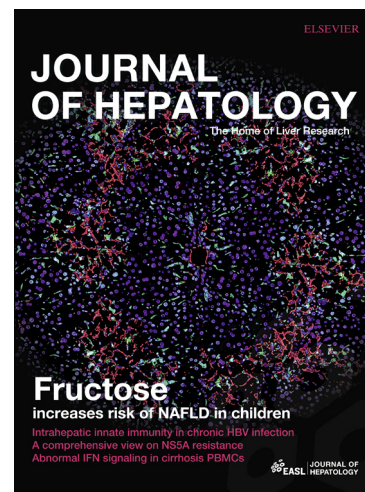
PII: S0168-8278(18)30010-2
DOI: <https://doi.org/10.1016/j.jhep.2017.12.026>
Reference: JHEPAT 6817

To appear in: *Journal of Hepatology*

Received Date: 16 August 2017
Revised Date: 18 December 2017
Accepted Date: 20 December 2017

Please cite this article as: Spreafico, C., Sposito, C., Vaiani, M., Cascella, T., Bhoori, S., Morosi, C., Lanocita, R., Romito, R., Chiesa, C., Maccauro, M., Marchianò, A., Mazzaferro, V., Development of a prognostic score to predict response to yttrium-90 radioembolization for hepatocellular carcinoma with portal vein invasion, *Journal of Hepatology* (2018), doi: <https://doi.org/10.1016/j.jhep.2017.12.026>

This is a PDF file of an unedited manuscript that has been accepted for publication. As a service to our customers we are providing this early version of the manuscript. The manuscript will undergo copyediting, typesetting, and review of the resulting proof before it is published in its final form. Please note that during the production process errors may be discovered which could affect the content, and all legal disclaimers that apply to the journal pertain.



DEVELOPMENT OF A PROGNOSTIC SCORE TO PREDICT RESPONSE TO YTTRIUM-90 RADIOEMBOLIZATION FOR HEPATOCELLULAR CARCINOMA WITH PORTAL VEIN INVASION

Carlo Spreafico¹, Carlo Sposito², Marta Vaiani¹, Tommaso Cascella¹, Sherrie Bhoori², Carlo Morosi¹, Rodolfo Lanocita¹, Raffaele Romito², Carlo Chiesa³, Marco Maccauro³, Alfonso Marchianò¹, Vincenzo Mazzaferro^{2,4}

Affiliations

1. Department of Radiology, Fondazione IRCCS Istituto Nazionale Tumori di Milano, Milan, Italy
2. Department of Gastrointestinal Surgery and Liver Transplantation, Fondazione IRCCS Istituto Nazionale Tumori di Milano, Milan, Italy
3. Department of Nuclear Medicine, Fondazione IRCCS Istituto Nazionale Tumori di Milano, Milan, Italy
4. University of Milan, Milan, Italy

Corresponding Author

Prof. Vincenzo Mazzaferro, M.D., Ph.D.

Department of Gastrointestinal Surgery and Liver Transplantation,
Fondazione IRCCS Istituto Nazionale Tumori
Via Venezian 1, Milan, 20133 Italy.

Email: vincenzo.mazzaferro@istitutotumori.mi.it

Tel. +39-02-23902760 Fax. +39-02-23903259

Keywords: radioembolization; hepatocellular carcinoma; portal vein thrombosis; liver neoplasms; prognosis

Electronic word count: 3226

Number of figures: 3 **Number of tables:** 3

Conflict of interest statement: Spreafico, Sposito, Cascella, Bhoori, Morosi, Romito, Chiesa, Maccauro, Marchianò and Mazzaferro received honoraria from BTG for training courses with educational purposes on radioembolization.

Financial support statement: No financial support was provided for the conduct of the research nor for the preparation of the article.

Authors contributions: Spreafico, Sposito, Mazzaferro: concept and design, analysis and interpretation of data, writing of article. Vaiani: writing of article, collection of radiological data. Cascella, Morosi, Lanocita, Marchianò: collection of radiological data, radiological procedures. Bhoori, Romito: collection clinical data and patients management. Maccauro, Chiesa: collection of Nuclear Medicine data, analysis and interpretation of data.

ABSTRACT

Background & Aims

Yttrium-90 trans-arterial radioembolization (TARE) has shown promising efficacy in the treatment of patients with hepatocellular carcinoma (HCC) associated with tumoral portal vein thrombosis (PVTT). Aim of this study is to identify prognostic factors for survival in patients with HCC and PVTT undergoing TARE, and build a prognostic classification for these patients.

Methods

This is a single Center retrospective study conducted over 6 years (2010-2015), on consecutive patients undergoing TARE. Patients were included if they met the following criteria: presence of at least one measurable HCC, presence of PVTT not occluding the main portal trunk, absence of extra-hepatic metastases, Child-Pugh score within B7, ECOG performance status 0-1. Uni- and multivariable analysis was used to explore the variables that showed an independent relationship with survival. A prognostic score was then derived, and three prognostic categories were identified.

Results

A total of 120 patients were included in the study. Median OS was 14.1 months (95%CI: 10.7-17.5) and median PFS was 6.5 months (95%CI: 3.8-9.2). The only variables independently correlated with OS were bilirubin, extension of PVTT and tumor burden. Three prognostic categories were identified: favourable prognosis (0 points), intermediate prognosis (2-3 points) and dismal prognosis (> 3 points). Median OS in the three categories was 32.2 months, 14.9 months and 7.8 months respectively ($p < .0001$). Also PFS ($p = .045$) and risk of liver decompensation ($p < .0001$) significantly differed along the same prognostic categories.

Conclusions

Radioembolization with Yttrium-90 is an effective therapy for patients with HCC and PVTT. The proposed prognostic stratification may help to better identify good candidates for the treatment, and those for whom TARE may be futile.

LAY SUMMARY

Yttrium-90 trans-arterial radioembolization (TARE) is a microembolic procedure that minimizes alterations of the hepatic arterial flow, and thus can be safely performed also in patients with hepatocellular carcinoma (HCC) and tumoral portal vein invasion (PVTT). In this study, we retrospectively evaluated the independent predictors of long-term outcomes in patients with HCC and PVTT treated with TARE. Bilirubin level, extension of PVTT and tumor burden were independently related to post-treatment survival: the combination of these factors allowed us to build a prognostic stratification that may help to better identify good candidates for the treatment, and those for whom TARE may be futile.

INTRODUCTION

Hepatocellular carcinoma (HCC) is a global health problem and one of the leading causes of cancer-related death especially in cirrhotic patients(1, 2). By reason of the improvements in surveillance protocols, diagnostic tools and therapeutic armamentaria, diagnosis of early HCC is feasible in 30–60% of cases(3). However, a substantial proportion of patients still present tumoral portal vein thrombosis (PVTT) either at onset of the disease or as result of HCC recurrence or progression, leading to an advanced stage of the disease not amenable to curative treatments(4). Patients with HCC and PVTT may present asymptomatic although in most instances have a significant degree of synthetic dysfunction and an impending liver decompensation that precludes any attempt of surgical cure. Moreover, when the portal circulation is compromised by thrombosis, trans-arterial embolo-therapies may increase the risk of liver failure; therefore, the presence of PVTT is generally considered as a contraindication to trans-arterial chemoembolization (TACE).(5, 6)

Two pivotal phase III trials have demonstrated a survival advantage for patients with advanced HCC treated with the oral multi-tyrosine kinase inhibitor sorafenib(7, 8) with respect to placebo, and a subgroup analysis has confirmed this result also in patients with PVTT(9, 10). Sorafenib has been therefore recognized as the standard of care for the treatment of advanced HCC by the American Association for the Study of Liver Diseases (AASLD)(11), the European Association for the Study of the Liver (EASL)(5) and the Asian Pacific Association for the Study of the Liver (APASL)(12). Nevertheless, sustained responses to sorafenib are rare, median survival in patients with advanced HCC remains limited to 6.5 - 10.7 months, and the treatment itself is associated with side effects that frequently lead to early treatment interruption(7, 8, 13, 14).

Trans-arterial radioembolization (TARE) is a form of brachytherapy performed by selective intra-arterial injection of microspheres loaded with Yttrium-90 (Y^{90}): a pure beta-emitter characterized by limited penetration, that enables selective tumor treatment with limited damage of the surrounding tissue(15). Unlike other trans-arterial therapies, TARE is a microembolic procedure that minimizes alterations of the hepatic arterial flow(16): several large series on TARE for patients with HCC and PVTT, mostly retrospective, showed an acceptable safety profile and good results in terms of local control of the disease(17-21). Only recently, two phase III randomized clinical trials (RCT) comparing TARE to the standard of care sorafenib in the population of patients with locally advanced HCC, have been made accessible(22),(23). In both trials the primary endpoint was not met, since TARE did not provide a significant gain in survival compared to sorafenib in the overall population nor in the subgroup of patients with PVTT. Incidentally, both studies clearly showed a significantly better treatment tolerance and quality of life in patients undergoing TARE.

Aim of this study is to identify, in a prospectively collected series of patients with PVTT treated with TARE, the prognostic factors with relevant impact on patients' survival (overall survival, OS), in order to build a prognostic classification that may allow to identify patients who would benefit most from the treatment.

METHODS

This is a retrospective single Center study on prospectively collected consecutive patients with HCC and PVTT, treated with yttrium-90 radioembolization (TARE) by means of glass microspheres (Therasphere® BTG International Ltd.) in a six years interval, from January 1st 2010 to December 31th 2015. Inclusion criteria were the following: a) presence of at least one measurable HCC lesion according to RECIST 1.1 criteria(24); b) presence of PVTT not occluding the main portal trunk c) absence of extra-hepatic metastases; d) Child-Pugh score within B7 e) ECOG performance status 0-1; f) age > 18 yrs. Patients with PVTT not meeting such criteria were not considered for TARE, and were indicated sorafenib or best supportive care according to liver function.

Approval for the study was obtained from the local Institutional Review Board.

Pre-treatment staging

Pre-treatment patients' assessment and tumor staging were performed the day before ⁹⁹Tc-macroaggregated albumin (⁹⁹Tc-MAA) scintigraphy and included: chest CT-scan, abdominal contrast-enhanced CT-scan or MRI, liver volumetry and calculation of tumor burden (% of tumor volume with respect to liver volume, measured with the CT-Volume Software Siemens Syngo Multimodality Workplace), collection of baseline demographic characteristics and history of previous treatments for HCC, etiology of the underlying liver disease, assessment of patients' performance status according to the Eastern Cooperative Oncology Group (ECOG) score, blood tests including alpha-fetoprotein (AFP). Liver function was evaluated according to the Child-Pugh score (CTP), the MELD score(25) and the ALBI grade(26).

Diagnosis of HCC was made according to radiographic findings or biopsy as defined by EASL/AASLD guidelines(5). Tumor-related PVTT was defined at baseline contrast-enhanced CT-scan or MRI as the presence of a filling defect in the portal venous phase, with evidence of enhancement during the arterial phase of dynamic imaging, associated to an HCC. PVTT extension was graded as PV1 (segmentary), PV2 (secondary order branch), PV3 (first order branch) as previously described(21). Invasion of hepatic veins was defined as presence of tumoral invasion of one or more of the main hepatic veins.

Treatment and dosimetry

Informed consent was obtained from all subjects before every angiographic procedure. TARE was performed in two sessions, as previously described(21): a simulation of treatment was performed by the injection of ⁹⁹Tc-MAA into the hepatic arterial vasculature reproducing Y⁹⁰ microspheres

distribution, in order to estimate the degree of extrahepatic deposition and tumor uptake by means of planar and SPECT scintigrams; coiling of extrahepatic arteries was performed when required to avoid unintentional deposition. The dose calculation was based on an individualized treatment planning based on ^{99m}Tc -MAA SPECT voxel dosimetry. The treatment planning evolved along the 5 years of the study and was aimed at delivering the maximal tolerable parenchyma absorbed dose to limit the risk of liver decompensation. This value was initially kept low (dosimetric method 1), resulting in about 40 Gy to parenchyma. Then it was raised to about 70 Gy (dosimetric methods 2 and 3) after our determination of the dose-toxicity curve for HCC patients treated with ^{90}Y glass microspheres (27). In both methods 1 and 2, patients were treated with one million microspheres per GBq while with method 3, patients were treated with 2.8 million of microspheres per GBq. The treatment was performed 2-3 weeks after the simulation, by the injection of glass microspheres loaded with ^{90}Y (TheraSphere ®) on the day of admission. Before injection, patients are given cefazoline 2 grams intravenously. After TARE, patients are hospitalized for 48 hours for clinical observation and according to safety regulation in our Region. During this period patients undergo blood tests 24 and 48 hours after TARE to check early toxicity, and given anti-emetics and analgesics if needed.

Follow-up

After TARE, patients were followed-up on an outpatient basis at months 1, 3, 6 and then every four months by means of contrast-enhanced thoraco-abdominal CT scan, physical examination and laboratory analysis including AFP. Adjunctive visits or hospitalizations were added whenever required depending on patients' or physicians' request and on detectable changes in clinical conditions.

Liver decompensation (LD) was defined as the occurrence of any of the following: clinically detectable ascites, bleeding from esophageal varices, hepatic encephalopathy, total bilirubin >3 mg/dL, and prothrombin time international normalized ratio >2.2 (21). Tumor progression was assessed according to RECIST criteria 1.1. The variations of PVTT extension during follow-up were not considered in tumor response evaluation. All CT scans were independently revised by two experienced radiologists (CSpr, MV); whenever evaluation was not overt, agreement was reached with a third radiologist on staff.

At progression, patients were treated according to disease presentation after multidisciplinary discussion. In particular, patients with a maintained liver function and an intrahepatic progression amenable to locoregional treatments were offered repeated TARE or percutaneous ablation; patients with a maintained liver function not amenable to locoregional treatments were offered sorafenib; patient presenting with liver decompensation were offered best supportive care.

Statistical analysis

Categorical variables were reported as the number of cases and percentages; continuous

variables were expressed as median and interquartile range (IQR). Overall survival, progression-free survival (PFS) and time to liver decompensation were estimated by the Kaplan-Meier method, and calculated from the date of TARE. Survival curves were compared by the log-rank test. Median follow-up was calculated with the reverse Kaplan Meier method.

For the survival analysis, continuous variables were transformed into qualitative or ordinal variables according to ranges of normality for laboratory values, clinical relevance or the median value of the given parameter. The event of interest was death for any cause: univariate analysis was performed for all the variables under study, and then multivariable analysis using the Cox proportional-hazards model was used to explore the variables that showed an independent relationship with survival. The proportionality assumption was verified by Schoenfeld residual analysis. A prognostic score was then derived using the independent variables weighed according to the estimated β regression coefficient of the final Cox model. The risk estimate associated with each point was then calculated using the Cox proportional hazards model. Three prognostic categories were identified according to the changes in the risk estimates for each point increase of the score. The OS curves, PFS curves and risk of liver decompensation were then obtained with the Kaplan-Meier method and compared by means of log-rank test.

All analyses were 2-tailed and the threshold of significance was assessed at $p < 0.05$. The statistical analysis was performed using IBM® SPSS® Statistics, version 20.

RESULTS

A total of 148 patients meeting the inclusion criteria underwent ^{99}Tc -MAA angioscintigraphy during the study period. Of these patients, 28 (18.9%) did not undergo subsequent TARE for the following reasons: 15 patients (53.6%) because of low/absent accumulation of ^{99}Tc -MAA in the tumor nodules, 8 patients (28.6%) because of extrahepatic (gastrointestinal) accumulation of ^{99}Tc -MAA and 5 patients (17.8%) because of lung shunting. Finally, 120 patients were eligible for the study and received the TARE treatment. Baseline characteristics are depicted in Table 1: overall, the median age was 64 years (IQR: 56-72), patients were mainly males (85.0%) and were predominantly classified as "fully active" (ECOG PS 0, 95.8%). In the majority of cases (45.8%), HCV was the etiology of liver disease; liver function was within CTP A in 93.3% of cases, median MELD score was 8 (IQR: 7-10) and ALBI grade was 1 and 2 in 51.7% and 47.5% of cases respectively. Thirty-seven patients (30.8%) had undergone one or more sessions of trans-arterial chemoembolization (TACE) before TARE. All patients were in the advanced stage according to the BCLC classification (BCLC-C): PVTT was extended to segmentary branches in 53 patients (PV1, 44.2%), to secondary order branches in 37 patients (PV2, 30.8%) and to first order branches in 30 patients (PV3, 25%). In most cases HCC was infiltrative (84 patients, 70.0%) and multifocal (99 patients, 82.5%), with a median diameter of the largest lesion of 7.3 cm (IQR: 5.8-10.9). The

median administered activity of Y^{90} was 2.6 GBq (1.9-3.7) and the treatment planning method was 1, 2 and 3 in 18 (15%), 77 (64.2%) and 25 (20.8%) cases respectively.

Survival analysis

Thirty-days mortality after treatment was 0%. Median follow-up was 27.0 months (95%CI: 9.98-44.02): during this time, 90 patients died, 77 patients showed tumor progression and 37 patients experienced at least one episode of liver decompensation. Median OS was 14.1 months (95%CI: 10.7-17.5), and 1yr and 3yrs-OS were 53.2% and 18.5% respectively (Figure 1, panel A). Median PFS was 6.5 months (95%CI: 3.8-9.2), and 1yr and 3yrs progression-free survival (PFS) were 35.2% and 0% respectively (Figure 1, panel B). The rate of liver decompensation (LD) was 10.8% at 3 months and 31.6% at 6 months.

No patients in the present series underwent subsequent resection. Only one patient (with PVT type 1) underwent liver transplant (LT) after showing a sustained complete response 1 year after TARE. He is alive and well after 24 months but his follow-up for this study was censored at the time of LT. The first site of tumor progression was intra-hepatic in 59 patients (76.6% of progressions): detectable in 11 patients in the TARE-treated lobe while in 43 patients upon appearance of new nodules in the contralateral lobe. In 18 patients (23.4% of progressions) the first site of progression was extra-hepatic only (10 patients) or combined intra-hepatic and extra-hepatic (8 patients). Treatment at progression consisted in retreatment with TARE in 14 patients, sorafenib or second-line experimental systemic therapies in 25 patients, percutaneous ablation in 3 patients and best available care in the remaining 35 patients. Such distribution was dependent on liver function status, as only 34 patients (44.1%) maintained a well-compensated Child A status at the time of post-TARE tumor progression(28).

Development of the prognostic classification

The results of the univariate analysis on baseline patients characteristics are presented in Table 2. Those variables identified as significant at univariate analysis were fitted in a multivariable Cox proportional hazards regression model: the only variables independently correlated with survival were bilirubin, PVTT grade and tumor burden at the time of TARE; the proportionality of hazard ratios for all levels of all prognostic factors was verified. The beta coefficients were transformed into relative points as shown in Figure 2. The hazard function identified a clear-cut change in the hazard ratio at the sum of 2 points and > 3 points. Thus, three prognostic categories were identified: favourable prognosis (0 points), intermediate prognosis (2-3 points) and dismal prognosis (> 3 points). Median OS in the three categories was 32.2 months, 14.9 months and 7.8 months respectively ($p < .0001$, Figure 2). Also PFS ($p = .045$) and risk of liver decompensation ($p < .0001$) were significantly stratified according to the three proposed prognostic categories, as reported in Table 3. Median PFS was 14.1 months (with a 42.1% 3-years OS) in patients with normal bilirubin, limited tumor burden and PVT limited to segmental branches (favourable

prognostic group); conversely TARE in patients with more than one risk factor (> 3 points) yielded a median PFS of 4.1 months, a risk of liver decompensation of 21.6% at 3 months and no survivors at 3 years. In Figure 3, three cases of patients with HCC and different grades of PVTT (type 1, 2 and 3 respectively) are showed before and after TARE treatment.

DISCUSSION

Despite consistent advancements in the clinical management of HCC, the therapeutic options for patients with locally advanced disease because of PVTT are very limited.

Radioembolization with Y^{90} has been recognized as a safe and effective treatment for unresectable HCC, as acknowledged in several guidelines(5, 11, 29). In several non-comparative studies(17-21, 30) published in the last decade on patients with HCC and PVTT, treatment with TARE has demonstrated an excellent safety profile, with median OS ranging from 10 to 13 months. These survival outcomes appeared superior to those obtained with sorafenib(7, 8) and this has fuelled retrospective comparative studies(31, 32) and two randomized clinical trials comparing TARE and sorafenib in the setting of locally advanced HCC. All these studies – although not specifically focused on the subset of patients with PVTT – failed to confirm a meaningful survival benefit provided by TARE with Y^{90} microsphere (22, 23).

In this study we report the long term outcomes of a consecutive series of patients with HCC and PVTT treated with TARE. As shown in Figure 1, median and 3-years OS were 14.1 months and 18.5% respectively. Overall, these results are superior than those previously reported by our group(21), and amongst the best reported in literature for patients offered such treatment outside clinical trials: this is probably related to the stringent application of refined selection criteria, derived from our previous experience. In fact, in the present series, patient with PVTT were treated with TARE only in presence of compensated liver function (within Child-Pugh A-B7 stage) and with no occlusion of the main portal trunk. This resulted also in a 0% treatment-related mortality, and in an acceptable rate of liver decompensation at 3 months of 10.8%.

Considering the resource impact of TARE in the current practice of HCC treatment, the main endpoint of our study was to identify the independent prognostic factors for OS in patients with HCC and PVTT treated with TARE and to assess whether or not different prognostic categories could correlate with predictable patient outcomes in advanced HCC maintaining sufficient liver function. At multivariable analysis, only 3 variables (PVTT extension, tumor burden in terms of liver volume replacement and baseline serum total bilirubin) were found to have an independent impact on post-treatment survival.

The extension of PVTT is known to directly affect patients prognosis: with respect to segmental invasion, thrombosis of more proximal branches increases the risk of tumor spread, and induces elevation of portal venous pressure causing higher risk of variceal hemorrhage, ascites, and liver

failure(33). The influence of PVTT extension on post-treatment outcomes has been demonstrated in several series of HCC patients treated with TARE(21, 33, 34), but also in patients treated by means of radical surgical resection(35). To be noted, patients with main PVTT were not treated at our Center. Based on the available literature(15, 17, 21) TARE in this setting provides a median OS from 3 to 6 months, not seeming to provide a meaningful survival benefit. This is probably due to the fact that main PVTT is vascularized by arterial feedings coming from the common hepatic artery, and thus and thus out of reach for microspheres injected when performing lobar or selective treatments (through first or second order arterial branches).

Tumoral burden replacing > 50% of total liver volume also independently affected survival. Not surprisingly, other morphological tumor variables (i.e. tumor size, number of nodules, presentation pattern) lost significance with respect to the overall tumor bulk, a common feature in the advanced stages of the disease. Most likely this correlated with a reduced functional liver remnant and a consequent higher risk of early liver decompensation; moreover, excessive tumor load may impede an effective treatment by means of a single session of TARE, and liver dysfunction may precede re-treatments.

Bilirubin was the only liver-related factor that showed an independent correlation with post-treatment survival. Again, this was relatively expected because the study population was relatively homogeneous in terms of liver function, being 97.2% of patients in Child-Pugh A and having an ALBI grade <3 in 99.2% of cases. Baseline bilirubin levels showed an independent influence on survival in other series of patients treated with TARE(19, 20): higher bilirubin at baseline is a sign of liver dysfunction and a predisposing factor for post-treatment bilirubin toxicity, which is a common adverse event after TARE, particularly in patients with PVTT(17).

A distinctive feature of this study is the development of a prognostic score derived from the estimated β regression coefficients of the final Cox model for extension of PVTT, tumor burden and serum bilirubin values at the time of treatment. According to the changes in risk estimates three prognostic categories were thus identified, that allowed a significant prognostic stratification in terms of OS, PFS and risk of liver decompensation at 3 months as shown in Figure 2 and Table 3. In particular, patients with 0 points (absence of adverse prognostic factors) were those with a favourable prognosis. These patients showed a median OS of 32.2 months and a median PFS of 14.1 months, with a negligible risk of TARE-related liver decompensation (3.2 % after 3 months). The favourable prognosis subgroup achieved in fact a remarkable survival outcome that is comparable to unresectable HCC undergoing trans-arterial chemoembolization in the absence of PVTT(36, 37). This result indirectly suggests that HCC patients with segmental PVTT and good liver function may be considered a sub-category of the intermediate stage HCC according to the BCLC classification(38). Thus, besides confirming that TARE may be considered as the first line treatment in such a patients' subgroup, the observed median PFS of 14.1 months may well justify consideration of TARE as a down-staging treatment to liver transplantation in selected patients

with segmental PVTT.

Patients expressing one of the aforementioned prognostic factors (2-3 points) can be considered a subgroup at intermediate prognosis. In this category of patients TARE works with a palliative purpose, even though the observed median OS of 14.9 months remains definitively higher than what expected with a first line systemic therapy. Considering the good tolerability of the treatment, and the acceptable risk of liver decompensation at 3 months (less than 10%), in field practice TARE can be proposed as a reasonable alternative to systemic treatments when the composite assessment of post-TARE prognosis turns out to be in the intermediate-risk category (Figure 2). According to the results of our prospective series, patients expressing more than one of the prognostic factors should be considered at a dismal prognosis. In this category median OS was 7.8 months, therefore with a much inferior benefit than what expected with systemic therapy. Considering also a risk of liver decompensation of 21.6% at 3 months, TARE for this patients' subgroup may be futile and potentially harmful, and thus should be avoided.

Our study has some limitations. Tumor or PVT absorbed doses were not specifically evaluated. Garin et al., in a study focusing on the impact of tumour dose based on 99mTc MAA quantification, found that a predicted tumor dose > 205 Gy and a good PVT targeting may significantly improve OS (39). In future studies, personalized dosimetry may be integrated into the proposed scoring system to further improve the prognostic prediction. Although this is one of the largest cohorts of consecutive patients with PVTT treated with TARE, the retrospective nature of the study and the relatively small sample size obviously limits the strength of evidence. In particular, the limited number of patients does not allow for a sensitivity analysis in order to evaluate the weight of the different components of the score within each prognostic category. Secondly, the previously discussed implications of our prognostic stratification for what regards treatment allocation are limited by the absence of a comparator. Most likely, the true survival benefit provided (or not) by TARE in the different prognostic classes of patients with PVTT compared to systemic treatments should be investigated in specifically designed prospective comparative studies: a condition that recent RCTs on TARE combined or compared to sorafenib did not specifically address. Finally, in this report the evaluation of radiological response to TARE was not specifically collected, being that beyond the objectives of a study specifically focused on clinical outcomes and on pre-treatment prognostication of survival.

Even considering these limitations, this study suggests that TARE is a safe and effective treatment for patients with HCC and PVTT. In patients with good liver function and no invasion of the main portal trunk, PVTT extension, tumor bulk and bilirubin level have an independent influence on long-term outcomes. The proposed score – easily determined on pre-treatment clinical variables – can help in the identification and selection of good candidates for the treatment, and conversely of those patients for whom TARE may be a futile therapy to offer.

ACKNOWLEDGEMENTS

The Authors would like to thank Drs Zuleyka Bianchi, Giuseppina Calareso, Alessandra Casale, Giorgio Greco and Maria Chiara De Nile for the help in clinical, radiological and physical data collection.

REFERENCE LIST

- (1) El-Serag HB. Hepatocellular carcinoma. *N Engl J Med* 2011 Sep 22;365(12):1118-1127.
- (2) Torre LA, Siegel RL, Ward EM, Jemal A. Global Cancer Incidence and Mortality Rates and Trends--An Update. *Cancer Epidemiol Biomarkers Prev* 2016 Jan;25(1):16-27.
- (3) Llovet JM, Bruix J. Novel advancements in the management of hepatocellular carcinoma in 2008. *J Hepatol* 2008;48 Suppl 1:S20-S37.
- (4) az-Gonzalez A, Reig M, Bruix J. Treatment of Hepatocellular Carcinoma. *Dig Dis* 2016;34(5):597-602.
- (5) EASL-EORTC clinical practice guidelines: management of hepatocellular carcinoma. *J Hepatol* 2012 Apr;56(4):908-943.
- (6) Raoul JL, Sangro B, Forner A, Mazzaferro V, Piscaglia F, Bolondi L, et al. Evolving strategies for the management of intermediate-stage hepatocellular carcinoma: available evidence and expert opinion on the use of transarterial chemoembolization. *Cancer Treat Rev* 2011 May;37(3):212-220.
- (7) Llovet JM, Ricci S, Mazzaferro V, Hilgard P, Gane E, Blanc JF, et al. Sorafenib in advanced hepatocellular carcinoma. *N Engl J Med* 2008 Jul 24;359(4):378-390.
- (8) Cheng AL, Kang YK, Chen Z, Tsao CJ, Qin S, Kim JS, et al. Efficacy and safety of sorafenib in patients in the Asia-Pacific region with advanced hepatocellular carcinoma: a phase III randomised, double-blind, placebo-controlled trial. *Lancet Oncol* 2009 Jan;10(1):25-34.
- (9) Bruix J, Raoul JL, Sherman M, Mazzaferro V, Bolondi L, Craxi A, et al. Efficacy and safety of sorafenib in patients with advanced hepatocellular carcinoma: subanalyses of a phase III trial. *J Hepatol* 2012 Oct;57(4):821-829.

- (10) Cheng AL, Guan Z, Chen Z, Tsao CJ, Qin S, Kim JS, et al. Efficacy and safety of sorafenib in patients with advanced hepatocellular carcinoma according to baseline status: subset analyses of the phase III Sorafenib Asia-Pacific trial. *Eur J Cancer* 2012 Jul;48(10):1452-1465.
- (11) Bruix J, Sherman M. Management of hepatocellular carcinoma: an update. *Hepatology* 2011 Mar;53(3):1020-1022.
- (12) Omata M, Cheng AL, Kokudo N, Kudo M, Lee JM, Jia J, et al. Asia-Pacific clinical practice guidelines on the management of hepatocellular carcinoma: a 2017 update. *Hepatol Int* 2017 Jul;11(4):317-370.
- (13) Ponziani FR, Bhoori S, Germini A, Bongini M, Flores M, Sposito C, et al. Inducing tolerability of adverse events increases sorafenib exposure and optimizes patient's outcome in advanced hepatocellular carcinoma. *Liver Int* 2016 Jul;36(7):1033-1042.
- (14) Bruix J, Takayama T, Mazzaferro V, Chau GY, Yang J, Kudo M, et al. Adjuvant sorafenib for hepatocellular carcinoma after resection or ablation (STORM): a phase 3, randomised, double-blind, placebo-controlled trial. *Lancet Oncol* 2015 Oct;16(13):1344-1354.
- (15) Salem R, Lewandowski RJ, Gates VL, Nutting CW, Murthy R, Rose SC, et al. Research reporting standards for radioembolization of hepatic malignancies. *J Vasc Interv Radiol* 2011 Mar;22(3):265-278.
- (16) Salem R, Mazzaferro V, Sangro B. Yttrium 90 radioembolization for the treatment of hepatocellular carcinoma: biological lessons, current challenges, and clinical perspectives. *Hepatology* 2013 Dec;58(6):2188-2197.
- (17) Kulik LM, Carr BI, Mulcahy MF, Lewandowski RJ, Atassi B, Ryu RK, et al. Safety and efficacy of 90Y radiotherapy for hepatocellular carcinoma with and without portal vein thrombosis. *Hepatology* 2008 Jan;47(1):71-81.
- (18) Hilgard P, Hamami M, Fouly AE, Scherag A, Muller S, Ertle J, et al. Radioembolization with yttrium-90 glass microspheres in hepatocellular carcinoma: European experience on safety and long-term survival. *Hepatology* 2010 Nov;52(5):1741-1749.
- (19) Salem R, Lewandowski RJ, Mulcahy MF, Riaz A, Ryu RK, Ibrahim S, et al. Radioembolization for hepatocellular carcinoma using Yttrium-90 microspheres: a comprehensive report of long-term outcomes. *Gastroenterology* 2010 Jan;138(1):52-64.

- (20) Sangro B, Carpanese L, Cianni R, Golfieri R, Gasparini D, Ezziddin S, et al. Survival after yttrium-90 resin microsphere radioembolization of hepatocellular carcinoma across Barcelona clinic liver cancer stages: a European evaluation. *Hepatology* 2011 Sep 2;54(3):868-878.
- (21) Mazzaferro V, Sposito C, Bhoori S, Romito R, Chiesa C, Morosi C, et al. Yttrium-90 radioembolization for intermediate-advanced hepatocellular carcinoma: a phase 2 study. *Hepatology* 2013 May;57(5):1826-1837.
- (22) Vilgrain V, Bouattour M, Sibert A, Lebtahi R, Ronot M, Pageaux G-P, et al. SARAH: a randomised controlled trial comparing efficacy and safety of selective internal radiation therapy (with yttrium-90 microspheres) and sorafenib in patients with locally advanced hepatocellular carcinoma., 66 ed 2017. p. S85-S86.
- (23) Chow PHW, Gandhi M, Asia-Pacific Hepatocellular Carcinoma Trials Group. Phase III multi-centre open-label randomized controlled trial of selective internal radiation therapy (SIRT) versus sorafenib in locally advanced hepatocellular carcinoma: The SIRveNIB study. 2017. p. 4002.
- (24) Eisenhauer EA, Therasse P, Bogaerts J, Schwartz LH, Sargent D, Ford R, et al. New response evaluation criteria in solid tumours: revised RECIST guideline (version 1.1). *Eur J Cancer* 2009 Jan;45(2):228-247.
- (25) Malinchoc M, Kamath PS, Gordon FD, Peine CJ, Rank J, ter Borg PC. A model to predict poor survival in patients undergoing transjugular intrahepatic portosystemic shunts. *Hepatology* 2000 Apr;31(4):864-871.
- (26) Johnson PJ, Berhane S, Kagebayashi C, Satomura S, Teng M, Reeves HL, et al. Assessment of liver function in patients with hepatocellular carcinoma: a new evidence-based approach-the ALBI grade. *J Clin Oncol* 2015 Feb 20;33(6):550-558.
- (27) Chiesa C, Mira M, Maccauro M, Spreafico C, Romito R, Morosi C, et al. Radioembolization of hepatocarcinoma with (90)Y glass microspheres: development of an individualized treatment planning strategy based on dosimetry and radiobiology. *Eur J Nucl Med Mol Imaging* 2015 Oct;42(11):1718-1738.
- (28) Memon K, Kulik L, Lewandowski RJ, Mulcahy MF, Benson AB, Ganger D, et al. Radioembolization for hepatocellular carcinoma with portal vein thrombosis: impact of liver function on systemic treatment options at disease progression. *J Hepatol* 2013 Jan;58(1):73-80.

- (29) Benson AB, III, Abrams TA, Ben-Josef E, Bloomston PM, Botha JF, Clary BM, et al. NCCN clinical practice guidelines in oncology: hepatobiliary cancers. *J Natl Compr Canc Netw* 2009 Apr;7(4):350-391.
- (30) Inarrairaegui M, Thurston KG, Bilbao JI, D'Avola D, Rodriguez M, Arbizu J, et al. Radioembolization with use of yttrium-90 resin microspheres in patients with hepatocellular carcinoma and portal vein thrombosis. *J Vasc Interv Radiol* 2010 Aug;21(8):1205-1212.
- (31) Gramenzi A, Golfieri R, Mosconi C, Cappelli A, Granito A, Cucchetti A, et al. Yttrium-90 radioembolization vs sorafenib for intermediate-locally advanced hepatocellular carcinoma: a cohort study with propensity score analysis. *Liver Int* 2015 Mar;35(3):1036-1047.
- (32) de la Torre MA, Buades-Mateu J, de la Rosa PA, Lue A, Bustamante FJ, Serrano MT, et al. A comparison of survival in patients with hepatocellular carcinoma and portal vein invasion treated by radioembolization or sorafenib. *Liver Int* 2016 Aug;36(8):1206-1212.
- (33) Lau WY, Sangro B, Chen PJ, Cheng SQ, Chow P, Lee RC, et al. Treatment for hepatocellular carcinoma with portal vein tumor thrombosis: the emerging role for radioembolization using yttrium-90. *Oncology* 2013;84(5):311-318.
- (34) Golfieri R, Mosconi C, Cappelli A, Giampalma E, Galaverni MC, Pettinato C, et al. Efficacy of radioembolization according to tumor morphology and portal vein thrombosis in intermediate-advanced hepatocellular carcinoma. *Future Oncol* 2015;11(23):3133-3142.
- (35) Shi J, Lai EC, Li N, Guo WX, Xue J, Lau WY, et al. Surgical treatment of hepatocellular carcinoma with portal vein tumor thrombus. *Ann Surg Oncol* 2010 Aug;17(8):2073-2080.
- (36) Burrel M, Reig M, Forner A, Barrufet M, de Lope CR, Tremosini S, et al. Survival of patients with hepatocellular carcinoma treated by transarterial chemoembolisation (TACE) using Drug Eluting Beads. Implications for clinical practice and trial design. *J Hepatol* 2012 Jun;56(6):1330-1335.
- (37) Facciorusso A, Mariani L, Sposito C, Spreafico C, Bongini M, Morosi C, et al. Drug-eluting beads versus conventional chemoembolization for the treatment of unresectable hepatocellular carcinoma. *J Gastroenterol Hepatol* 2016 Mar;31(3):645-653.
- (38) Bolondi L, Burroughs A, Dufour JF, Galle PR, Mazzaferro V, Piscaglia F, et al. Heterogeneity of patients with intermediate (BCLC B) Hepatocellular Carcinoma: proposal for a subclassification to facilitate treatment decisions. *Semin Liver Dis* 2012 Nov;32(4):348-359.

- (39) Garin E, Rolland Y, Pracht M, Le SS, Laffont S, Mesbah H, et al. High impact of macroaggregated albumin-based tumour dose on response and overall survival in hepatocellular carcinoma patients treated with (90) Y-loaded glass microsphere radioembolization. *Liver Int* 2017 Jan;37(1):101-110.

TABLES LEGEND

Table 1. Baseline characteristics of the study population

Table 2. Uni- and multivariable analysis on overall survival of 120 patients with PVTT-associated HCC receiving trans-arterial radioembolization (TARE) as elective treatment

Table 3. Comparison of outcomes among different prognostic categories

FIGURES LEGEND

Figure 1. Overall survival (panel A) and progression-free survival (panel B) of 120 patients with PVTT treated with TARE

Figure 2. Proposed point system according to β regression coefficients of the final Cox model built on the three variables independently related to post-TARE patients' survival. Overall survival according to prognostic stratification.

0 points, favourable prognosis: continuous line; 2-3 points, intermediate prognosis: interrupted line; >3 points, dismal prognosis: dotted line.

Figure 3. Baseline CT scans (A), planar scintigrams after $^{99}\text{Tc-MAA}$ (B) and CT scans 6 months after TARE (C) in patients with HCC and PVTT. Arrows show PVTT before and after treatment. a recanalization of the occluded portal branch may be observed, confirming a favourable response to the treatment.

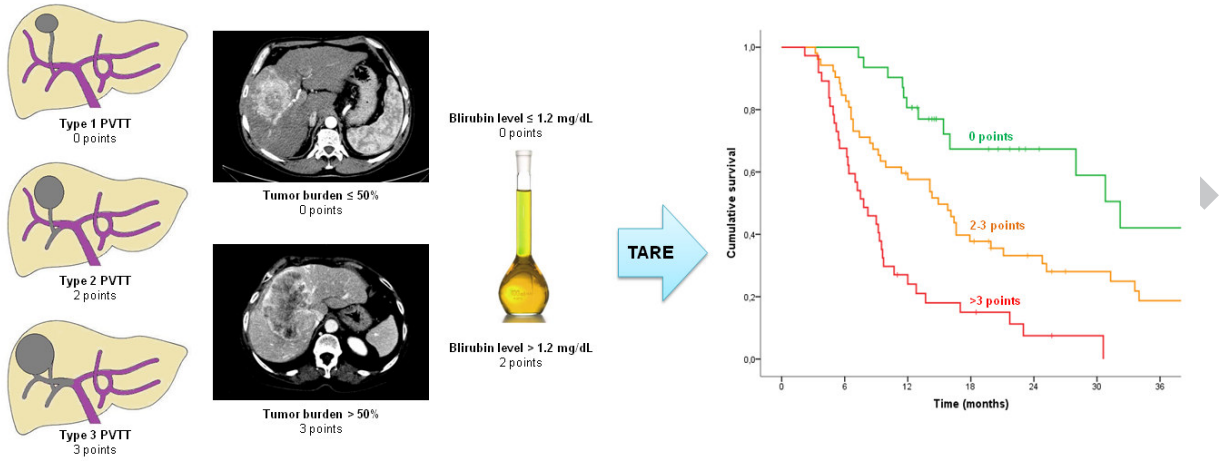
Panel 1: HCC of segment 4 associated with type 1 PVTT (segmental, branch for segment 4).

Panel 2: HCC of segments 5-8 associated with type 2 PVTT (secondary order branch, anterior branch of right portal vein).

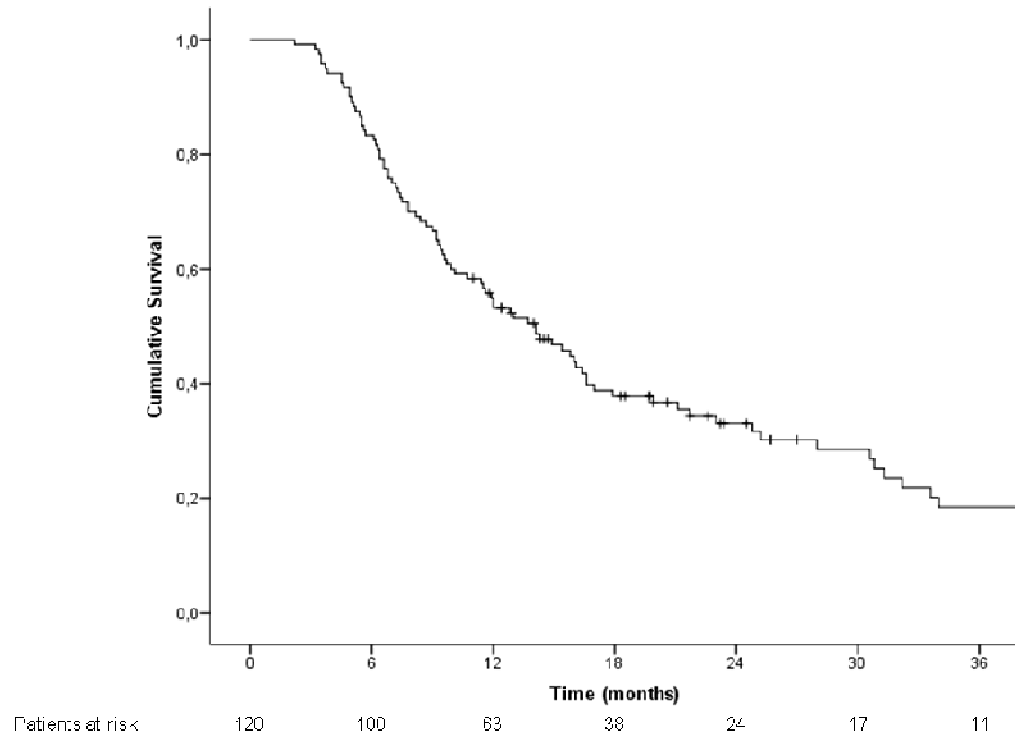
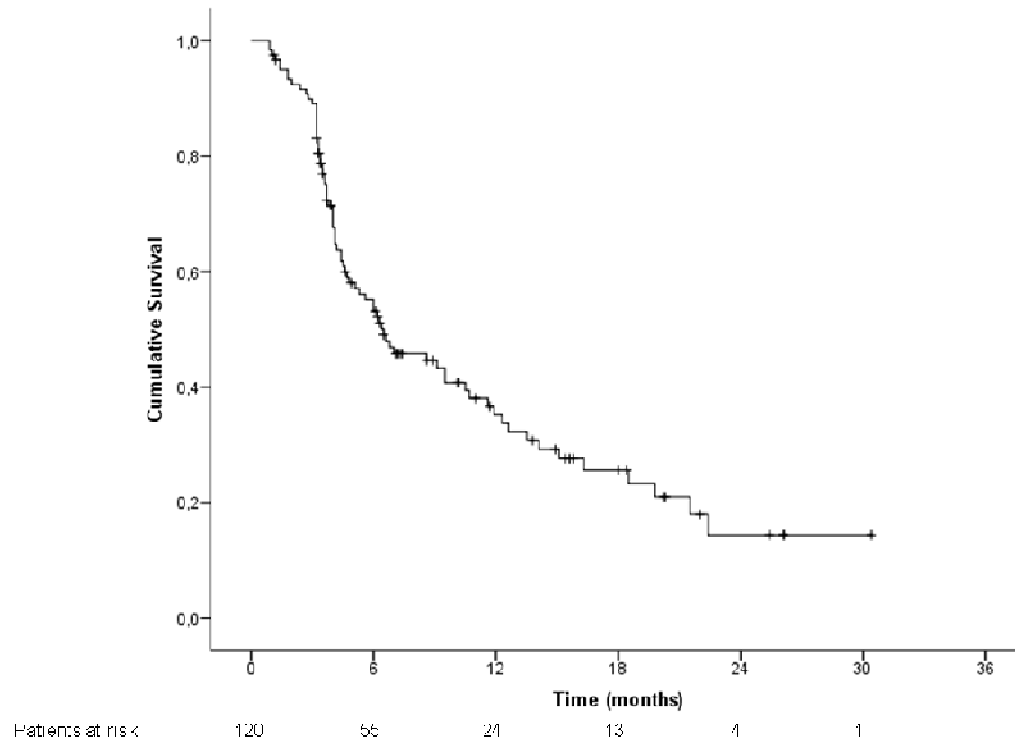
Panel 3: Bulky HCC of the right lobe of the liver associated with type 3 PVTT (first order branch, right portal vein).

HIGHLIGHTS

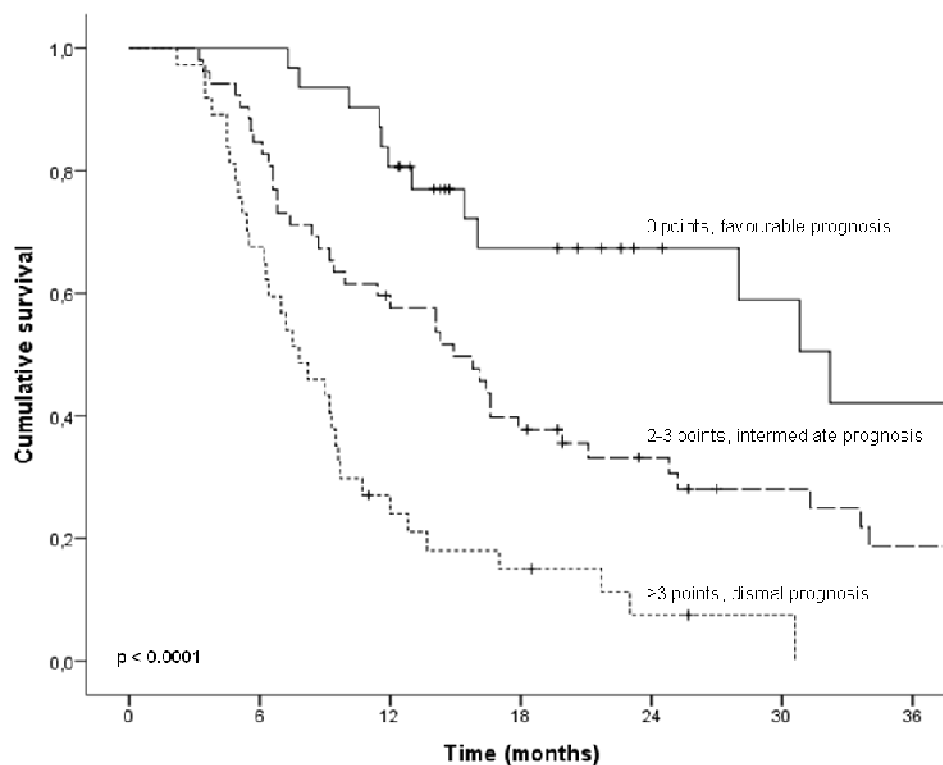
- A prognostic score for post-TARE survival in patients with HCC and PVTT is proposed
- Bilirubin, PVTT extension and tumor burden were independently related to survival
- The combination of these factors allowed identifying three prognostic categories
- The proposed prognostic categorization may allow better treatment allocation



ACCEPTED MANUSCRIPT

PANEL A: Overall Survival**PANEL B:** Progression-free Survival

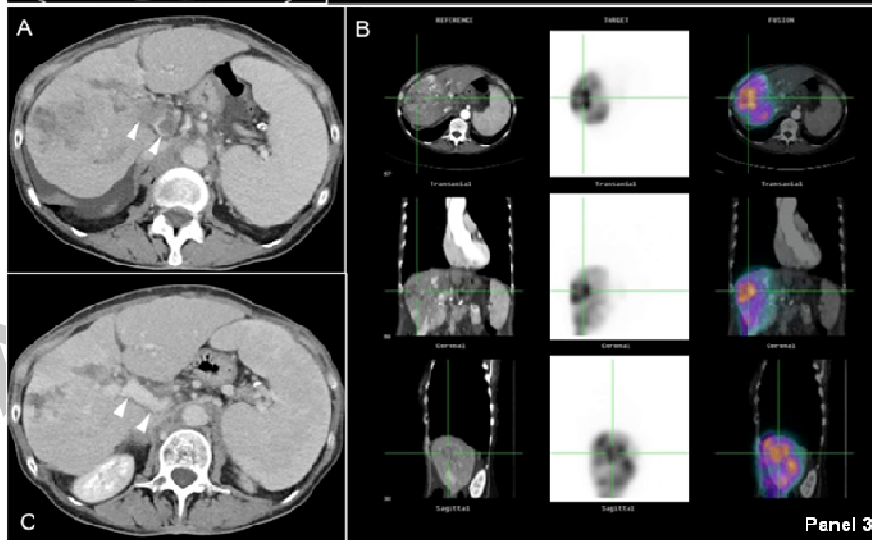
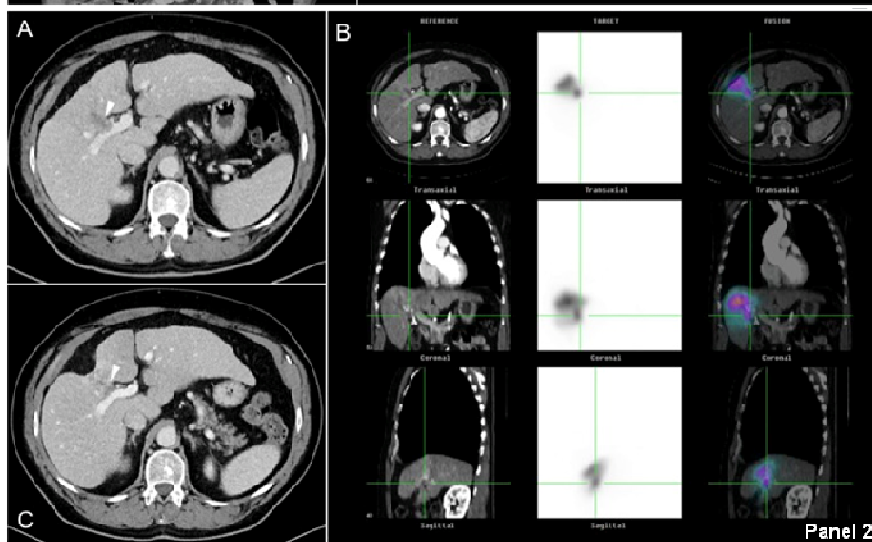
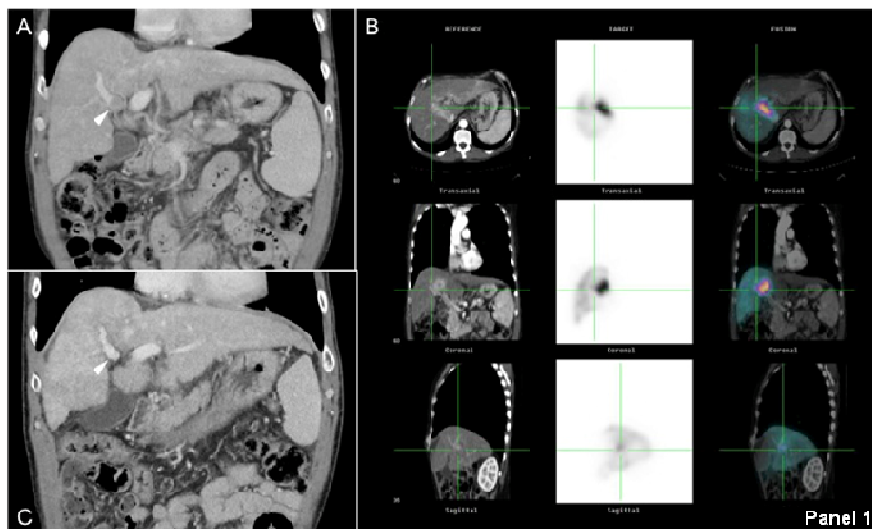
Variable	HR (95%CI)	p-value	β	Points
Bilirubin serum level				
≤ 1.2 mg/dL	ref.	0.37		0
> 1.2 mg/dL	1.636 (1.030-2.597)		.462	2
PVT extension				
-Pv1 (segmenta)	ref.	< .0001		0
-Pv2 (second order)	1.900 (1.126-3.205)		.642	2
-Pv3 (main right/left)	3.017 (1.793-5.074)		1.104	3
Tumor burden				
< 50% liver volume	ref.	< .0001		0
> 50% liver volume	2.612 (1.608-4.312)		.972	3



Patients at risk

0 points	31	30	25	14	9	7	5
2-3 points	52	44	30	19	13	9	6
>3 points	37	25	9	5	2	1	0

AC



SCRIPT

Table 1. Baseline characteristics of the study population

Variable	N (%) or Median (IQR)
Age	64 (56-72)
Sex (Male)	102 (85.0%)
Etiology of cirrhosis	
- HCV	55 (45.8%)
- HBV	28 (23.3%)
- HBV+HCV	6 (5.0%)
- Alcohol	18 (15.0%)
- Other	13 (10.8%)
ECOG Performance Status	
- 0	115 (95.8%)
- 1	5 (4.2%)
Bilirubin (mg/dL)	0,82 (0.57-1.31)
Presence of detectable ascites (yes)	9 (7.5%)
Child-Pugh score	
- A	112 (93.3%)
- B7	8 (6.7%)
MELD score	8 (7-10)
ALBI grade	
- grade 1	62 (51.7%)
- grade 2	57 (47.5%)
- grade 3	1 (0.8%)
AFP (ng/mL)	85,3 (9,2-1183,3)
Previous TACE (yes)	37 (30.8%)
PVT grade ²¹	
-PV1	53 (44.2%)
-PV2	37 (30.8%)
-PV3	30 (25.0%)
Invasion of hepatic veins	
- Absent	110 (91.7%)
- Present	10 (8.3%)
Maximum diameter (mm)	73.5 (58.3-109.8)
Multifocal (yes)	99 (82.5%)
Tumor burden (>50%)	24 (20.0%)
Pattern	
-Nodular	36 (30.0%)
-Infiltrative	84 (70.0%)
Tumor distribution	
- Unilobar	68 (56.7%)
- Bilobar	52 (43.4%)
Administered activity (GBq)	2.6 (1.9-3.7)
Administered spheres (*10 ⁶ /GBq)	1 (1-1)
Planning method for dosimetry§	
- Method 1	18 (15%)
- Method 2	77 (64.2%)
- Method 3	25 (20.8%)
Abbreviations: IQR, Interquartile Range; HCV, Hepatitis C Virus; HBV, Hepatitis B Virus; ECOG, Eastern Cooperative Oncology Group; MELD, Model for End stage Liver Disease; AFP, Alfa-Fetoprotein; TACE, Trans-Arterial Chemoembolization; PVT, tumoral Portal Vein Thrombosis.	
§ See text (methods section) for the description of the three different planning methods.	

Table 2. Uni- and multivariable analysis on overall survival on 120 patients with PVTT-associated HCC receiving trans-arterial radioembolization (TARE) as elective treatment

Variable	Univariable analysis		Multivariable analysis	
	Median OS, months (95% CI)	p	HR (95%CI)	p
Age		.010		.537
- ≤65	9.7 (7.1-12.3)		Ref	
- >65	21.1 (12.0-30.2)		.868 (.554-1.361)	
Sex		.258		
- Male	13.0 (10.0-16.0)			
- Female	23.0 (6.2-39.8)			
Etiology of cirrhosis		.617		
- HCV	14.1 (10.5-17.7)			
- HBV	12.8 (8.1-17.5)			
- HBV+HCV	9.5 (1.4-17.6)			
- Alcohol	30.8 (19.9-47.7)			
- Other	9.3 (7.3-11.3)			
ECOG PS		.207		
- 0	13.7 (10.5-16.9)			
- 1	40.5 (n.e.-n.e.)			
Bilirubin		.019		.037
- ≤ 1.2 mg/dL	16.0 (13.5-18.5)		Ref	
- > 1.2 mg/dL	9.5 (8.8-10.2)		1,636 (1,030-2,597)	
Presence of ascites		.617		
- no	14.1 (10.6-17.6)			
- yes	12.0 (5.2-18.8)			
Child-Pugh		.864		
- A	14.1 (10.9-17.3)			
- B7	7.5 (3.8-11.2)			
MELD		.484		
- ≤ 9	14.3 (10.9-17.7)			
- >9	11.4 (5.8-17.0)			
ALBI		.350		
- grade 1	16.0 (14.1-17.9)			
- grade 2-3	14.1 (10.7-17.5)			
AFP		.003		.151
- ≤ 1000 ng/mL	16.4 (11.9-21.0)		Ref	
- > 1000 ng/mL	9.2 (7.2-11.2)		1.433 (.877-2.344)	
Previous TACE		.166		
- no	14.3 (10.8-17.8)			
- yes	11.5 (7.0-16.0)			
PVT grade		<.0001		<.0001
-PV1	28.0 (10.7-45.3)		Ref	
-PV2	12.0 (6.1-17.9)		1,900 (1,126-3,205)	
-PV3	8.2 (5.7-10.8)		3,017 (1,793-5,074)	
Invasion of hepatic veins		.925		
- Absent	13.7 (10.4-16.9)			
- Present	15.8 (2.4-29.2)			
HCC Maximum diameter		.057		
- ≤ 50 mm	21.7 (12.6-30.8)			
- > 50 mm	11.6 (7.8-15.4)			
HCC Number of nodules		.350		
- single	16.6 (3.9-29.3)			
- multifocal	12.0 (8.8-15.2)			
Tumor burden		<.0001		<.0001

- ≤ 50% liver volume	16.0 (13.7-18.3)		Ref	
- > 50% liver volume	6.4 (5.2-7.6)		2,642 (1,608-4,342)	
HCC Pattern		.021	Ref	.216
-Nodular	25.2 (5.3-45.1)			
-Infiltrative	10.1 (6.7-13.4)		1.379 (.828-2.297)	
Tumor distribution		.244		
- Unilobar	16.1 (9.3-22.9)			
- Bilobar	12.0 (8.0-16.0)			
Planning method for dosimetry		.664		
- method 1	11.6 (4.3-18.9)			
- method 2	15.4 (11.5-19.3)			
- method 3	13.7 (9.6-17.8)			

Abbreviations: 95% CI, 95% Confidence Interval; HR, Hazard Ratio; HCV, Hepatitis C Virus; HBV, Hepatitis B Virus; ECOG, Eastern Cooperative Oncology Group; PS, Performance Status; n.e., not evaluable; MELD, Model for End stage Liver Disease; AFP, Alfa-Fetoprotein; TACE, Trans-Arterial Chemoembolization; PVT, tumoral Portal Vein Thrombosis.

Table 4. Comparison of outcomes among different prognostic categories

Category	Median OS, months (95% IC)	1-yr survival	3-yrs survival	Median PFS, months (95% IC)	HCC progression within 3 months	Liver decompensation within 3 months
0 points (31 pts): favourable prognosis	32.2 (25.9-38.5)	80.6%	42.1%	14.1 (6.9-21.3)	6.5%	3.2%
2-3 points (52 pts): intermediate prognosis	14.9 (10.6-19.2)	57.6%	18.7%	6.2 (4.2-8.2)	9.6%	9.6%
> 3 points (37 pts): dismal prognosis	7.8 (5.4-10.2)	24.0%	0%	4.1 (3.0-5.2)	16.9%	21.6%