Boston Scientific

54.8%

of first time ICD recipients were candidates for S-ICD.[1]

VIEW NOW

REFERENCE
1. Friedman DJ, et al. Trends and In-Hospital Outcomes Associated with Adoption of the Subcutaneous Implantable Cardioverter Defibrillator in the United States. JAMA Cardiology 2016.

SPECIAL ARTICLE

Venice Chart International Consensus Document on Ventricular Tachycardia/Ventricular Fibrillation Ablation

ANDREA NATALE, M.D.,* ANTONIO RAVIELE, M.D.,† AMIN AL-AHMAD, M.D.,‡ OTTAVIO ALFIERI, M.D.,¶ ETIENNE ALIOT, M.D.,** JESUS ALMENDRAL, M.D.,†† GÜNTER BREITHARDT, M.D.,‡‡ JOSEP BRUGADA, M.D.,¶¶ HUGH CALKINS, M.D.,*** DAVID CALLANS, M.D.,††† RICCARDO CAPPATO, M.D.,‡‡‡ JOHN A. CAMM, M.D.,¶¶¶ PAOLO DELLA BELLA, M.D.,**** GERARD M. GUIRAUDON, M.D.,†††† MICHEL HAÏSSAGUERRE, M.D.,‡‡‡‡ GERHARD HINDRICKS, M.D.,¶¶¶¶ SIEW YEN HO, M.D.,***** KARL H. KUCK, M.D.,††††† FRANCIS MARCHLINSKI, M.D.,‡‡‡‡‡ DOUGLAS L. PACKER, M.D.,¶¶¶¶¶ ERIC N. PRYSTOWSKY, M.D.,****** VIVEK Y. REDDY, M.D.,†††††† JEREMY N. RUSKIN, M.D.,‡‡‡‡‡‡ MAURICIO SCANAVACCA, M.D.,¶¶¶¶¶¶ KALYANAM SHIVKUMAR, M.D.,******* KYOKO SOEJIMA, M.D.,††††††† WILLIAM J. STEVENSON, M.D.,‡‡‡‡‡‡‡ SAKIS THEMISTOCLAKIS, M.D.,¶¶¶¶¶¶¶ ATUL VERMA, M.D.,******** and DAVID WILBER, M.D.,††††††††† for the Venice Chart members

From the *Texas Cardiac Arrhythmia Institute, St. David's Medical Center, Austin, TX, USA; †Cardiovascular Department, Ospedale dell'Angelo, Mestre-Venice, Italy; ‡Cardiac Arrhythmia Service, Stanford University Medical School, Stanford, USA; ¶Department of Cardiac Surgery, Ospedale San Raffaele, Milan, Italy; **Department of Cardio-Vascular Diseases, CHU de Nancy, Hôpital de Brabois, Vandoeuvre-les-Nancy, France; ††Division of Cardiology, Hospital General Gregorio Maranon, Madrid, Spain; ‡‡Department of Cardiology and Angiology, University Hospital of Münster, Münster, Germany; ¶¶Thorax Institute-Cardiology, Hospital Clinic, University of Barcelona, Barcelona, Spain; ***Department of Cardiology, The Johns Hopkins Hospital, Baltimore, MD, USA; †††Department of Medicine, Section of Cardiovascular Disease, Hospital of the University of Pennsylvania, Philadelphia, PA, USA; ‡‡‡Department of Electrophysiology, Policlinico San Donato, San Donato Milanese, Italy; ¶¶¶Cardiac and Vascular Sciences, St. George's Hospital Medical School, London, UK; ****Cardiology Division, Centro Cardiologico Monzino, Milan, Italy; ††††Cardiac Surgery, University of Western Ontario, London, Canada; ‡‡‡‡Hôpital Cardiologique du Haut Leveque, Bordeaux, France; ¶¶¶¶Heart Center, Department of Cardiology, University of Leipzig, Leipzig, Germany; *****Cardiac Morphology Unit, Royal Brompton Hospital, London and Imperial College, London, UK; †††††Department of Cardiology, Asklepios Klinik St. Georg, Hamburg, Germany; ‡‡‡‡‡Department of Medicine, Section of Cardiovascular Disease, University of Pennsylvania, Philadelphia, PA, USA; ¶¶¶¶¶Cardiac Translational and Electrophysiology Laboratory, Saint Mary's Hospital Complex, Mayo Clinic Foundation, Rochester, NY, USA; ******The Care Group, Indianapolis, IN, USA; ††††††Cardiac Arrhythmia Service, Miller School of Medicine, University of Miami, Miami, USA; ‡‡‡‡‡‡Arrhythmia Service, Massachusetts General Hospital, Boston, MA, USA; ¶¶¶¶¶¶Heart Institute, University of San Paulo Medical School, San Paulo, Brazil; *******Cardiac Arrhythmia Center, David Geffen School of Medicine at UCLA, Los Angeles, CA, USA; †††††††Cardiovascular Division, University of Miami Hospital, Miami USA; ‡‡‡‡‡‡‡Cardiovascular Division, Brigham and Women's Hospital, Boston, MA, USA; ¶¶¶¶¶¶¶Cardiovascular Department, Ospedale dell'Angelo, Mestre-Venice, Italy; ********Cardiology, Southlake Regional Health Center, Toronto, Canada; and ††††††††Department of Cardiology, Loyola University Medical Center, Chicago, IL, USA

(J Cardiovasc Electrophysiol, Vol. 21, pp. 339-379, March 2010)

catheter ablation, guidelines, heart failure, ventricular fibrillation, ventricular tachycardia

---

This manuscript was processed by a guest editor.

For the Venice Chart composition (committees, members, and affiliations) see the Appendix.

This document was made possible by an Educational Grant of Biosense Webster, a Johnson & Johnson Company.

Disclosures: A. Natale, research grant: St. Jude Medical, speaker's bureau: St. Jude Medical, Boston Scientific, Biosense Webster, Medtronic; A. Raviele, speaker's bureau: Biosense Webster, consultant/advisory board: Sanofi-aventis; A. Al-Ahmad, honoraria: Medtronic; J. Almendral, consultant: Medtronic, speaker's bureau and honoraria: unspecified; G. Breithardt, speaker's bureau and honoraria: Boston Scientific, Medtronic; J. Brugada, research grant: Boston Scientific, St. Jude Medical, Biotronik; P. Della Bella, honoraria: St. Jude Medical; K. Kuck, research grant: St. Jude Medical, speaker's bureau: St. Jude Medical, Biosense Webster; F. Marchlinski, speaker's bureau: Medtronic, Boston Scientific, St. Jude Medical, Biotronik, Biosense Webster, consultant/advisory board: Biosense Webster; D. Packer, research grant, honoraria, consultant/advisory board: Biosense Webster, EPT, CryoCath, Siemens, St. Jude Medical; E. Prystowsky, honoraria, consultant/advisory board: Medtronic, stock options: Stereotaxis; V. Reddy, research support, consultant/advisory board: Biosense Webster, St. Jude Medical; J. Ruskin, research support: Biosense Webster, St. Jude

Introduction

Sustained ventricular arrhythmias—ventricular tachycardia (VT) and ventricular fibrillation (VF)—are important causes of morbidity and sudden death (SD), especially in patients with structural heart disease. Therapeutic options for the treatment of these arrhythmias include antiarrhythmic drugs, implantable cardioverter-defibrillators (ICDs), and surgical and catheter ablation. Antiarrhythmic drugs have disappointing efficacy and adverse side effects that may outweigh benefits. ICDs effectively terminate VT/VF episodes and represent the mainstay therapy to prevent SD. However, ICD shocks are painful, reduce quality of life, and predict increased risk of death and heart failure.

Catheter ablation, as therapeutic option for ventricular arrhythmias, was first proposed in 1983.[1] Since then, significant developments in ablation and mapping technologies have been made. The most relevant developments include the use of radiofrequency (RF) energy, introduction of steerable, large-tip, and irrigated catheters, activation and entrainment mapping, electroanatomic mapping with the possibility of performing substrate-based ablation during sinus rhythm, multielectrode mapping with the possibility of ablating hemodynamically unstable VT, and epicardial mapping and ablation. All these advances have contributed to improved outcomes and to a substantial expansion in the indications of catheter ablation of ventricular arrhythmias. Moreover, they have generated the need to standardize the different aspects of the procedure.

Inspired by this need, the Organizers of Venice Arrhythmias 2009 assembled world-recognized experts in the field of ventricular arrhythmias to develop an international consensus document on VT/VF ablation. In this article, the work produced by this group of experts is reported.

Definition, Classification, and Clinical Presentation of VT/VF

Definition

Ventricular arrhythmias are defined as arrhythmias that originate below the bifurcation of His bundle, in the specialized conduction system, the ventricular muscle, or in combination of both tissues.

There are different classifications of ventricular arrhythmias, according to their duration, morphology of QRS complexes, and clinical characteristics.

Medical, honoraria: Boston Scientific, St. Jude Medical, consultant/advisory board: Biosense Webster, Medtronic, steering committee: CryoCath, CardioFocus (no compensation); S. Themistoclakis, research grant: CardioFocus, honoraria, consultant/advisory board: Biosense Webster; A. Verma, travel support: Venice Arrhythmias 2009 Conference; D. Wilber, research grant: Biosense Webster, St. Jude Medical, Medtronic, honoraria: Biosense Webster, St. Jude Medical, Medtronic, Boston Scientific. Other authors: No disclosures.

Address for correspondence: Antonio Raviele, M.D., Cardiovascular Department, Arrhythmia Center and Center for Atrial Fibrillation, Ospedale dell'Angelo, Mestre-Venice, Italy. Fax: +39 041 9657235; E-mail: araviele@tin.it

Manuscript received 21 October 2009; Revised manuscript received 17 November 2009; Accepted for publication 17 November 2009.

doi: 10.1111/j.1540-8167.2009.01686.x

Classification According to Duration

(1) *Premature ventricular complexes (PVC)*: isolated complexes originating from the His-Purkinje system or ventricular myocardium.
(2) *VT:* 3 or more consecutive QRS complexes at a rate greater than 100 beats per minute.
(3) *Nonsustained VT:* VT that terminates spontaneously within 30 seconds.
(4) *Sustained VT:* continuous VT lasting for ≥30 seconds or that requires an intervention for termination (such as cardioversion).

Classification According to Morphology of QRS Complexes

(1) *Monomorphic VT:* VT that has a similar QRS configuration from beat to beat. Some variability in QRS morphology at initiation is not uncommon.
(2) *Multiple monomorphic VT:* more than one morphologically distinct monomorphic VT, occurring as different episodes or induced at different times.
(3) *Polymorphic VT:* VT that has a continuously changing QRS configuration indicating a changing ventricular activation sequence.
(4) *Pleomorphic VT:* VT that has more than one morphologically distinct QRS complex occurring during the same episode of VT, but the QRS is not continuously changing.
(5) *Ventricular flutter:* rapid VT that has a sinusoidal QRS configuration that prevents identification of the QRS morphology.
(6) *VF:* ventricular tachyarrhythmia that has a totally chaotic morphology.

Classification According to Clinical Characteristics

(1) *Clinical VT:* VT that has occurred spontaneously based on analysis of 12-lead ECG QRS morphology and rate.
(2) *Hemodynamically unstable VT:* VT that causes hemodynamic compromise requiring prompt termination.
(3) *Incessant VT:* continuous sustained VT that recurs immediately despite repeated spontaneous or therapeutic termination.
(4) *Repetitive monomorphic VT:* continuously repeating episodes of self terminating nonsustained VT.
(5) *VT storm:* 3 or more separate episodes of sustained VT within 24 hours, each requiring termination by an intervention.
(6) *Unmappable VT:* VT that does not allow interrogation of multiple sites to define the activation sequence or perform entrainment mapping. It may be due to hemodynamic intolerance that necessitates immediate VT termination, spontaneous, or pacing-induced transition to other morphologies of VT, or repeated termination during mapping.

VT/VF Clinical Presentation

Coronary heart disease is the most frequent cause of clinically documented VT and VF (76–82% of the patients).[2-5] Other common causes of ventricular arrhythmias are nonischemic dilated cardiomyopathy (DCM), hypertrophic cardiomyopathy (HCM), arrhythmogenic right ventricular cardiomyopathy (ARVC), congenital heart disease, especially tetralogy of Fallot, aortic stenosis, transposition of the great

arteries, and hereditary arrhythmogenic syndromes, such as long QT syndrome (LQTS), short QT syndrome (SQTS), Brugada syndrome, and catecholaminergic polymorphic ventricular tachycardia (CPVT). In a limited number of patients with VT/VF (≈5%) no documented structural cardiac abnormalities can be identified.

Symptoms that occur during VT are highly variable and greatly depend upon the rate and the duration of the VT, and the extent of the concomitant underlying heart disease. According to the presence and intensity of hemodynamic compromise and symptoms, VT may be defined, from a clinical point of view, as hemodynamically stable and hemodynamically unstable. Hemodynamically stable VTs do not cause symptoms or are only associated with palpitations. Hemodynamically unstable VTs are responsible of severe symptoms, such as dyspnea, chest pain, lightheadedness, presyncope, and syncope. However, symptoms alone do not identify a cardiac rhythm as being due to VT. Moreover, the cumulative survival of each symptomatic subgroup of patients with VT is surprisingly similar and is approximately 70% at 3 years.[6] Sustained VT/VF are the usual cause of SD in the general population, reported to occur with an incidence of 0.1% to 0.2% per year.[7]

Anatomy of Right/Left Ventricles and Surrounding Structures

Catheter ablation of VT is a highly complex procedure that requires both advanced knowledge in the techniques of electrophysiologic mapping and also an in-depth understanding of the anatomy of the ventricles, the aortic root, and surrounding structures.

Normal Anatomy of Right and Left Ventricles

Disposition of the ventricular chambers and great arteries

The intricate spatial relationship between right and left ventricles reflects the anatomical fact that right ventricle, being the most anteriorly situated cardiac chamber, overlaps the left ventricle. In addition, the shapes of the left and right ventricles are dissimilar and the ventricular septum is not straight but curved. The inflow and outflow tracts of the left ventricle overlap each other when viewed from the frontal aspect whereas they are well separated in the right ventricle.

Particularly relevant to ablations in the outflow tracts is, to understand the "crossover" relationship between the right and left ventricular outlets. The right ventricular outlet passes cephalad in a posterior and slightly leftward direction. The left ventricular outlet passes underneath the right ventricular outlet in a rightward and cephalad direction, pointing toward the right shoulder. Furthermore, the pulmonary and aortic valves are not at the same level. The pulmonary valve is the most superiorly situated of the cardiac valves, whereas the aortic valve slopes inferiorly at an angle to the pulmonary valve.[8] The difference in levels between the 2 sets of arterial valves may be exaggerated by the length of the free-standing cone of muscle supporting the pulmonary valve known as the subpulmonary infundibulum (Fig. 1A,B).

Right ventricle

The posteroinferior wall of the subpulmonary infundibulum overlies the anterior walls of the left and right coronary sinuses to a greater or lesser extent and may give the impression of myocardial sleeves covering the aortic sinuses. In the sinuses nearest to the infundibulum are the orifices of the right and left coronary arteries.[9,10] As the coronary arteries descend toward their respective atrioventricular grooves, they pass within millimeters of the epicardial aspect of the infundibulum.[11]

A muscular fold known as the ventriculo-infundibular fold separates the tricuspid from pulmonary valves (Fig. 1A). On its epicardial aspect sits the right coronary sinus of the aortic root. The fold continues superiorly into the muscle of the subpulmonary infundibulum that adjoins the arterial wall of the pulmonary trunk at the ventriculo-arterial junction (Fig. 1B). The pulmonary sinuses are not as prominent as the aortic sinuses; there is a small segment of infundibular musculature at the nadirs of each sinus.[12] Distinctive of the septal surface of the right ventricle is a Y-shaped muscle band, the septomarginal trabeculation. The ventriculo-infundibular fold arises from between the limbs of the Y to form the supraventricular crest. The attachment of the medial papillary muscle to the inferior limb is the landmark for the right bundle branch that emerges from its transseptal course onto the subendocardium (Fig. 1A). The moderator band arising from the body of the septomarginal trabeculation carries a fascicle of the right bundle branch to the parietal wall of the right ventricle. The apical portion of the right ventricle is characterized by a meshwork of coarse muscular trabeculations. The ventricular wall in between the trabeculations is about 2 mm thick.

Left ventricle

The central location of the aortic valve in the heart places the outflow tract in between the mitral valve and the ventricular septum (Fig. 1C). The septal half of the aortic outlet is muscular, whereas the other half is an area of fibrous continuity between mitral and aortic valves. The curvature of the ventricular septum continuing into the free wall forms the anterosuperior wall of the left ventricular outflow tract. The semilunar hingelines of the aortic leaflets enclose a segment of ventricular myocardium in the nadir of the right coronary aortic sinus and the adjacent part of the left coronary aortic sinus (Fig. 1C). The interleaflet fibrous triangles between adjacent sinuses project like the prongs of a coronet above the ventricular chamber. The triangle between right and noncoronary leaflets proximally is continuous with the membranous septum making it a landmark for the atrioventricular conduction bundle that emerges in the left ventricle positioned between the membranous septum and muscular ventricular septum (Fig. 1C). The left bundle branch descends in the subendocardium of the muscular septum and fans into 3 interconnecting main fascicles that ramify distally into fine strands. Some strands may be carried within so-called false tendons. The left ventricle is characterized by fine apical trabeculations and thick muscular walls. However, the wall is thin at the very apex.

Arrhythmogenic Substrate of VT/VF

VT and VF are usually initiated by mechanisms of reentry in the ventricular myocardium. Reentry depends on the coexistence of an arrhythmogenic substrate, which is a preexistent structural pathological condition in the heart, and a "trigger," such as acute ischemia that initiates the electrical abnormality. *Infarcts* often show marked spatial heterogeneity, with areas of necrosis interspersed with bundles of viable myocytes, particularly at the periphery of the infarct and,

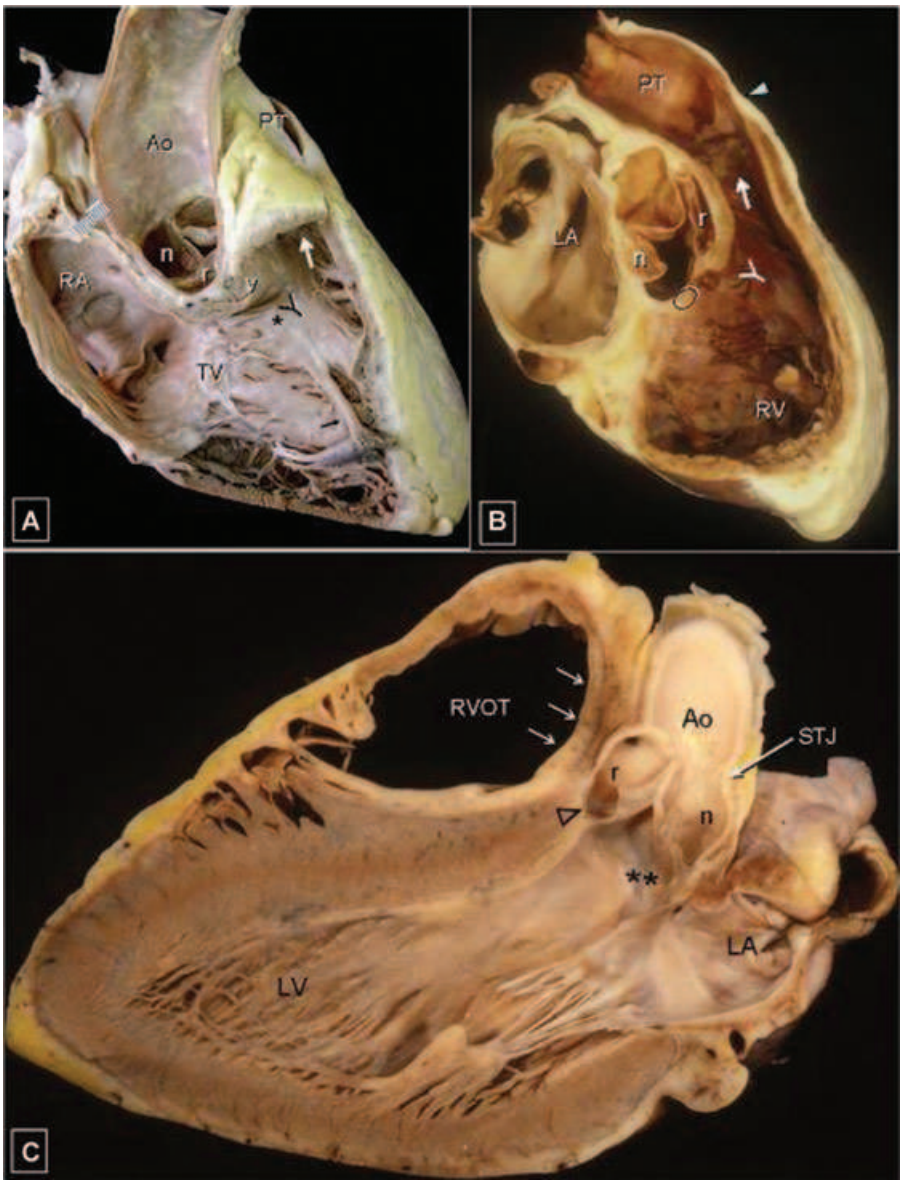

Figure 1. *(A) and (B) are dissections into the right ventricle and into the right ventricular outflow tract (white arrow). (A) The ventriculo-infundibular fold (v) continues into the muscle of the subpulmonary infundibulum that surrounds the outflow tract (arrow). Y marks the septomarginal trabeculation. The moderator band (black arrow) arises from its body while the medial papillarty muscle (asterisk) inserts into its inferior limb. (B) This deeper cut profiles the right ventricular outflow tract to show the muscular infundibulum leading to the pulmonary valve at the ventriculoarterial junction (triangle). The oval marks the area of the central fibrous body. (C) This longitudinal section shows the right ventricular outflow tract (RVOT) passing over the aortic outflow tract. The musculature of the RVOT (small white arrows) overlying the aortic sinuses and the ascending aorta can give the impression of there being an extensive muscular sleeve around the aorta. The triangle indicates the presence of muscle at the nadir of the right coronary aortic sinus (r). The location of the atrioventricular conduction bundle is depicted by asterisks. LA = left atrium; LV = left ventricle; n = noncoronary aortic sinus; STJ = sinutubular junction.*

in the reparative phase, this may lead to formation of fibrocellular, fibrosclerotic, or fibroadipose scars with irregular outlines. Heterogeneity in tissue composition and autonomic innervations in these regions may create areas of aberrant conduction that generate the substrate for lethal reentrant arrhythmias.[13] The pathologic hallmark of ARVC is myocyte loss with fibrofatty replacement. In *HCM*, the histopathological hallmarks are myocyte hypertrophy, disarray, and interstitial fibrosis. In *DCM*, the histological changes are mostly nonspecific and include myocyte attenuation, extensive myofibrillary loss with vacuolated appearance and perinuclear halo, dysmorphic and dysmetric nuclei, and interstitial fibrosis. Isolated *left ventricular noncompaction* is thought to be the consequence of the postnatal persistence of the embryonic pattern of myocyte architecture. Pathologically, the noncompacted layer of the myocardium consists of excessively prominent trabeculations with deep intertrabecular recesses extending into the compacted myocardial layer. In *myocarditis*, VT and VF may develop in the setting of unstable myocardial substrate, namely inflammatory infiltrate, interstitial edema, myocardial necrosis, and fibrosis.

Important Structures Near the Heart

Pericardium

The heart and the adjacent parts of the great arteries and veins are enclosed by pericardium consisting of 2 components: the fibrous and the serous pericardium. The *fibrous pericardium* is a sac made of tough connective tissue that completely surrounds the heart and is attached only at its arterial and venous poles. The *serous pericardium* consists of 2 layers of serous membrane. The inner (*visceral*) layer forms the epicardium of the heart, whereas the outer (*parietal*) layer is adherent to the internal surface of the fibrous pericardium.[14,15] The visceral layer is reflected from the heart and the great vessels to continue into the parietal layer thus enclosing between the layers a narrow space, the *pericardial cavity*, which is filled normally with 20–25 cc of serous fluid.

The pericardial space can be accessed via a subxiphoid puncture and it allows relatively free manipulation of catheters around the epicardial surface of the heart, especially the ventricles, except in cases with pericardial adhesions.

Phrenic nerves

The phrenic nerves accompanied by the pericardiophrenic vessels descend bilaterally onto the pericardium. The *right phrenic nerve* has a close anatomic relationship with the superior caval vein (minimal distance 0.3 ± 0.5 mm) and the right superior pulmonary vein (minimal distance 2.1 ± 0.4 mm) as it runs through the lateral and posterolateral wall of the right atrium.[16,17] The *left phrenic nerve* descends either anteriorly or anterolaterally over the area of the left ventricle to insert in the diaphragm behind the cardiac apex.[17]

Pathophysiology and Mechanisms of VT/VF

Electrophysiological Abnormalities Responsible for VT/VF

VT/VF may be caused by different electrogenetic mechanisms. They include abnormal automaticity, triggered activity, and single or multiple reentry. The cause of normal automaticity in subsidiary pacemakers (especially His-Purkinje fibers) is a spontaneous decline in the membrane potential during diastole, the pacemaker potential, that is, under autonomic control. When resting potentials are reduced, spontaneous diastolic depolarization may occur and cause repetitive impulse initiation by *abnormal automaticity*.[18] *Triggered activity* is dependent on afterdepolarizations. *Delayed afterdepolarizations* are caused by an increase in intracellular Ca2+ ("Ca overload").[19] *Early afterdepolarizations* are associated with prolongation of action potential duration and cause triggered torsades de pointe.[20] *Reentry* is dependent on unidirectional conduction block and an impulse wavelength (conduction velocity $\times$ refractory period) that is shorter than the path length of the reentrant circuit.

Pathophysiology and Mechanisms of VF

Experimental data support the hypothesis that VF is a result of *many spiraliform waves reentry* in the ventricular myocardium.[21,22] This chaotic arrhythmia is a final result of several pathogenetic expressions. To start VF, different factors are necessary, in particular (1) triggers (for example, single PVC, PVC runs, and VT) and (2) the occurrence of complex neuroendocrine interactions, electrolyte changes, hypoxia, inflammation, drugs, mechanical factors, among many others.[7] The most frequent cause of VF is *acute myocardial ischemia*. It provokes serious electrical instability, with enhanced automaticity, shortening, and different duration of cell action potentials (AP) in the area of ischemic tissue. In *ischemic cardiomyopathy*, other factors besides myocardial ischemia play a role. The zone bordering the scar area, where *live tissue coexists with fibrotic tissue*, is often the structural substrate in which ventricular arrhythmias are produced.[23] In this area there is a wide variability of the AP duration, so that it is the basis of the reentry and electrical instability. Recent studies have shown that *His-Purkinje fibers* may be involved in the genesis of early-onset PVC, which can trigger VT or VF.[24] The risk of developing malignant ventricular arrhythmias increases in patients with heart failure and left ventricular ejection fraction (EF) $<40\%$.[25] This has been observed also in *nonischemic cardiomyopathy*. *Idiopathic VF* occurs in about 5–10% of survivors of out-hospital cardiac arrest.[26] Recent attention has focused on the inherited aspects of *ion channelopathies* in these patients. Spatial electrical heterogeneity within the ventricular myocardium through different changes of diastolic potential genetically determined in LQTS,[27] SQTS and Brugada syndrome,[28] as well as CPVT, explains high electrical instability in these patients.[29] VF occurs when these alterations in depolarization are stressed by physical, emotional, metabolic, or drug-related factors. Genetic defects can also contribute to drug-induced channelopathies. Polymorphic genetic alterations in apparently normal patients cause an exaggerated drug action.

Pathophysiology and Mechanisms of VT

VT in structural heart disease

Sustained monomorphic VT is often the clinical manifestation of an underlying structural heart disease.[7,30] VT that occurs in this setting most frequently appears to be related to *reentry* arising from a stable substrate. Fibrosis or fibrofatty replacement of ventricular myocardium create scar regions that are regarded as the arrhythmogenic disease substrate.[31] Morphologic studies consistently demonstrate that the myocardial lesion responsible for VT is characterized by *islands of surviving ventricular myocardium embedded into scar tissue*.[30,31] This inhomogeneous histopathologic arrangement accounts for nonuniform intraventricular conduction in the surviving but electrophysiologically abnormal myocardial tissue, with slow regional activation and areas of functional block that promote reentrant excitation (reentrant circuits with a "figure of eight" pattern)[32] Fig. 2).

Old myocardial infarction is the most common source of ventricular scar that gives rise to monomorphic left VT.[33] In *HCM*, microreentry circuits related to intraseptal small scar areas produce rapid monomorphic/polymorphic VT that tends to degenerate into VF and SD.[34] Sustained monomorphic VT is also observed in *DCM*. The underlying mechanism is usually a scar-related reentry circuit predominantly located close to the valve annulus, although a bundle branch reentry or phase 4-dependent enhanced automaticity may be occasionally involved.[7,35] Scar-related right VT (with a left bundle branch block morphology) may occur in patients with *ARVC* and *cardiac sarcoidosis*.[36–39] Reentry circuits often develop around scars or aneurysms in the subtricuspidal, apical, or infundibular regions ("triangle of dysplasia"). Multiple VTs are commonly observed and suggest a widespread fibrofatty myocardial replacement resulting in multifocal arrhythmogenic scar regions. In *tetralogy of Fallot*, postexcisional myocardial fibrosis and/or synthetic patches used to close the septal defect and reconstruct the pulmonary infundibulum act as a substrate for the VT reentry circuit.[40]

Idiopathic VT

Idiopathic VT is classified into several categories, (1) verapamil-sensitive left VT or fascicular VT;[41,42] (2) outflow VT;[43,44] (3) inflow VT of mitral and tricuspid valve annulus origin; (4) left VT of papillary muscle origin;[45] and (5) epicardial VT arising from close proximity to the coronary venous system including the anterior interventricular vein, the distal great cardiac vein, the anterior interventricular vein-great cardiac vein junction.[46] The mechanism of typical *verapamil-sensitive left VT* is well demonstrated to be *macroreentry* involving the Purkinje system at the left posterior fascicular area with the estimated distance of approximately 2 cm between its entrance and exit. Rarely, there is left anterior fascicle VT with right bundle

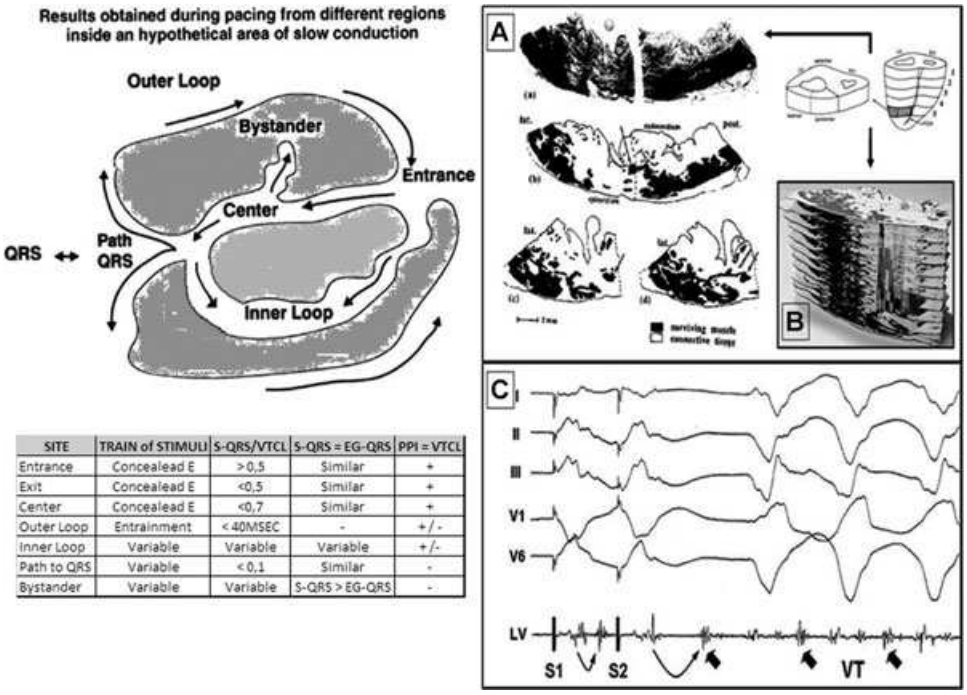

SITE	TRAIN of STIMULI	S-QRS/VTCL	S-QRS = EG-QRS	PPI = VTCL
Entrance	Concealead E	>0,5	Similar	+
Exit	Concealead E	<0,5	Similar	+
Center	Concealead E	<0,7	Similar	+
Outer Loop	Entrainment	< 40MSEC	-	+ / -
Inner Loop	Variable	Variable	Variable	+ /-
Path to QRS	Variable	< 0,1	Similar	-
Bystander	Variable	Variable	S-QRS > EG-QRS	-

Figure 2. *Panel A shows histologic view of the infarcted tissue in the inferoapical wall of the left ventricle (LV), as indicated by the schematic representation of the heart on the right upper corner. Bundles of surviving myocardium are seen (in black) connecting the 2 borders of scar (in white) at different levels. Panel B shows a 3-dimensional model of the infarct. Several connections among the bundles of surviving myocardium are seen at different levels, which may serve as possible substrates for a reentrant ventricular tachycardia (VT). By definition, a reentrant VT continuously depolarizes some quantity of myocardial tissue. As the mass of the myocardium in the protected channels inside the scar is small, it contributes only negligibly to the surface QRS complex. Therefore, the QRS complex during VT initiates when the activation wavefront emanates from the border of the scar (from an exit). Panel C shows induction of VT during ventricular-programmed stimulation (S1 and S2 represent pacing stimulus artifacts). Following S2, a long interval is seen on surface EKG followed by initiation of VT. However, intracardiac recordings from inside the scar (LV) reveal presence of mid-diastolic potentials (thick arrows). Although essential for initiation and maintenance of a reentrant VT, the electrical activation of these small bundles is not seen on surface EKG. Rather, they are only seen during electrical recordings from inside the scar. In order to confirm that the area where the mid-diastolic potential is being recorded is part of the VT circuit, entrainment maneuvers should be performed. The panel on the left summarizes entrainment findings that allow differentiation among possible regions inside the scar area. In this panel: E = entrainment; EG-QRS = electrogram to QRS interval; PPI = post pacing interval; S-QRS = stimuli to interval; VTCL = ventricular tachycardia cycle length. (Panel A and the panel on the left were obtained and modified from D'Avila et al. (371), while Panel B was kindly provided by JMT de Bakker.)*

branch block and right-axis deviation, and left upper septal VT with narrow QRS.

Outflow VT is characterized by the manifestation of repetitive monomorphic VT and exercise-induced sustained monomorphic VT. The basic electrophysiologic mechanism of outflow VT is widely accepted to be *triggered automaticity* due to cyclic AMP-mediated calcium-dependent delayed afterdepolarization or catecholamine-dependent abnormal automaticity. The actual origin of outflow VT determined by successful ablation distributes at various sites of the right and left ventricular outflow tracts below the pulmonic and aortic valves, above the pulmonic valve, or within aortic sinuses of Valsalva. Compared with outflow VT, idiopathic *VT arising from the mitral and tricuspid valve annulus,* the papillary muscles, and the coronary sinus systems is rare in incidence. The underlying electrophysiologic mechanism appears to be the same as outflow VT.

ECG Features of VT/VF as Expression of the Underlying Mechanisms and Site of Origin

The QRS morphology of VT on 12-lead ECGs is determined by the *site of origin*, that is, the site where the activation of the normal myocardium arises in a case of a focal origin or the exit site from a reentrant VT. The ability to localize the region of origin on the basis of the ECG morphology directs mapping to a specific area of the ventricles when VT ablation is planned. ECG features are useful not only to identify the region of interest but also to help differentiate an epicardial or endocardial VT origin.

General Rules

Some general rules can be applied to the QRS analysis during VT, regardless of the underlying substrate. First, *QRS width is affected by the proximity to the septum*, narrower with septal VTs; but also by the amount of myocardial disease, being wider with poor overall ventricular conduction.

The appearance of a left bundle branch block (*LBBB*)-like pattern suggests a right ventricular or left ventricular septal origin, dominant R waves in V1 or dominant negative deflections in Lead I indicating a left ventricular exit. The *frontal plane axis* indicates whether the exit is on the inferior wall (superior axis) or on the anterior wall (inferior axis). The axis direction, right versus left, may help to define further the region of origin. The *mid precordial leads (V3 and V4)* indicate if the exit site is at the base or the apex; basal sites producing dominant R waves and apical sites generating dominant S waves. The presence of QR/QS complexes indicates

TABLE 1

ECG Criteria for Localizing Site of Origin of Ventricular Tachycardia from Basal Left Ventricular Sites

	S-P	AMC	Superior MA	Superolateral MA	Lateral MA
Lead I	R or Rs	Rs or rs	rs or rS	rS or QS	rS or rs
Lead V1	QS or Qr	qR	R or Rs	R or Rs	R or Rs
Precordial transition*	Early	None	None	None	None or late S wave
QRS ratio in leads II and III	>1	≤1	≤1	≤1	>1

*Reversal of Q to R and vice versa ≤V3 (early) and ≥V5 (late S-wave appearance).
AMC = aorto-mitral continuity; MA = mitral annulus; S-P = septal-parahisian.

activation is moving away from the site where the complex is registered. Finally, VTs that originate at the *subepicardium* generally have slower QRS upstrokes in the precordial leads than those with an endocardial exit.

Idiopathic VT

Idiopathic VTs usually arises from the right ventricular outflow tract (RVOT) and less frequently from the left ventricular outflow tract (LVOT), but can also originate around the mitral or tricuspid annulus, from the papillary muscles, or involve the fascicles of the LV. ECG features can help us to distinguish the different regions of origin. *RVOT VTs* have an LBBB-like morphology, inferior axis in the frontal plane, and a precordial *QRS transition that begins no earlier than V3*. Free wall sites can be differentiated from the septal ones by a later QRS transition and wider QRS duration and notching.[47,48] *LVOT VTs* may arise from the LVOT and/or the aortic cusp region.[49,50] The ECG has also an LBBB-like configuration, inferior axis in the frontal plane and a precordial *QRS transition in lead V2 or V3* in VTs originating from the right coronary cusp, *and in lead V1 or V2* in VTs originating from the left coronary cusp. It has also been described that a *broad R-wave* duration in V1 or V2 is present in the cusp region (R-wave duration index ≥50%) versus the RVOT.[44] A small proportion of idiopathic VTs can arise from sites *around the tricuspid annulus*, more frequently at the septal portion. The QRS morphology is usually positive in lead I and aVL as well as V5 and V6.[51] Idiopathic VTs can also infrequently originate from the basal left ventricular endocardium. The ECG analysis of the QRS morphology in I and V1, the ratio of the QRS complexes in II/III, and the precordial transition pattern, may be helpful in differentiating medial from lateral locations *around the mitral annulus* (MA) (Table 1). Medial sites (septal parahisian and aortomitral continuity) have narrower QRS, initial negative forces in V1, and predominant positive forces in I. The QRS ratio in II/III is >1 in septal parahisian and lateral MA and <1 in aortomitral continuity, superior MA, and superolateral MA.[52] Annular VT as with preexcited tachycardia will show dominant R waves in V5 and V6.[53]

Idiopathic *fascicular left VTs* have also characteristic ECG features including a right bundle branch block (*RBBB*)-like pattern *left axis deviation* (in a small proportion right inferior axis deviation) with a *short QRS duration* (≤140 ms) and a rapid QRS upstroke due to initial activation of the Purkinje system. Recently, VT originating from the *papillary muscles* (PAP) in patients with or without prior myocardial infarction has been described. The ECG characteristics for PAP have been differentiated with those of the fascicular VTs.[54,55] The PAP had broader QRS complex (150 ± 15 ms vs 127 ± 11 ms). All of the fascicular arrhythmias (vs none of the PAPs) had an rsR' pattern in lead V1. All fascicular arrhythmias had a left anterior or posterior hemiblock pattern including discrete Q waves in leads I and aVL or I, II, III, respectively. The PAP arrhythmias from the posterolateral or anterolateral PAP showed the same axis as the fascicular VTs of the corresponding fascicle but without the discrete Q waves in limb leads.

ARVC

The typical LBBB VT morphologies are closely related to the area that is predisposed to fibrofatty replacement of myocardium, which is the "triangle of dysplasia."[56] Quite typically for VT in ARVC compared with idiopathic VT, the QRS complexes are fragmented and depolarizing forces suppressed, which leads to lesser steepness of the QRS upstroke. In the literature, the most frequently described VT morphologies are *intermediate or inferior axis and LBBB* or *superior left axis and LBBB*. In the study from Niroomand *et al.*, 48% of the tachycardias displayed an inferior axis, 27% an intermediate, and 20% left/superior axis.[57] In contrast, in only 10% of the cases with idiopathic VT the axis was intermediate or superior. *VT pleomorphism* is another frequent finding in patients with an ARVC, and the literature provides numbers ranging from 1 to 12 different morphologies/patient.[58]

Postinfarction VT

The12-lead ECG can be used to identify the exit site of postinfarction VT, although its localizing value has been questioned and is subject to many limitations.[59-61] The following criteria are helpful in assigning a specific endocardial exit area within the heart to a particular VT morphology:[59,61-63] *apical location* often displays Q waves in leads I, V1 through V6; *basal location* often displays R waves in leads I, V1-V6; *septal location* LBBB morphology; *posterior location* often Q waves in the inferior leads associated with R waves in lead I and precordial leads. The presence of RBBB versus LBBB morphology additionally influences the location of the VT exit site, in that LBBB morphologies have their exit from the septum, whereas RBBB morphologies can originate from the septum or the free wall.

There are specific VT morphologies that can be assigned to a particular endocardial exit site, depending on the location of a prior infarction.[61] In patients with *prior inferior wall infarction*, LBBB morphology with superior axis and increasing R-wave progression from V1-V6 suggests *inferobasal septum* origin; RBBB morphology with superior axis and reversed R-wave progression from V1-V6 suggests *inferobasal free wall* origin; and, RBBB morphology with inferior axis suggests *inferolateral free wall* origin. In patients with *prior anterior wall infarction*, LBBB morphology with

superior axis and negative precordial concordance suggests *inferoapical septum* origin; LBBB morphology with inferior axis, as well as RBBB morphology with inferior axis and abrupt loss of R waves, suggest *anteroapical septum* origin. The VT morphology with the least predictive pattern is the RBBB morphology with a superior axis, especially in patients with prior anterior wall myocardial infarction.

Epicardial Origin of VT

The discrimination between endocardial versus epicardial VTs is of great interest because the VT-ablation approach will be completely different, requiring pericardial access and epicardial mapping and ablation in a case of an epicardial VT. Berruezo *et al*. demonstrated that the epicardial origin of the ventricular activation can be recognized on the ECG by a slurring of the initial part of the QRS complex (*pseudodelta*).[64] The duration intervals and cutoff values obtained for the "pseudodelta wave" and "intrinsicoid deflection in V2" obtained a high sensitivity and specificity in identifying an epicardial origin of the VTs. Daniels *et al*.[46] quantified the slowed initial precordial QRS activation of the epicardial LVOT VT by a novel measurement, the *maximum deflection index* (MDI). The MDI is the result to divide the time to maximum deflection in precordial leads by the QRS duration. A delayed shortest precordial MDI $\geq$0.55 identified epicardial VT remote from aortic sinus of Valsalva with a high sensitivity and specificity. Later, Bazan *et al*.[65] showed that the presence of a Q wave in leads that reflect local ventricular activation may be useful to distinguish epicardial left VT in patients without ischemic heart disease.

Pre- and Intraablation Patient Management

Preprocedural Evaluation of the Patient Undergoing Catheter Ablation for the Treatment of VT

Routine preprocedural assessment in patients referred for catheter ablation of cardiac arrhythmias comprises a careful physical examination, electrocardiogram analysis, and laboratory evaluation. In patients scheduled to undergo catheter ablation for the treatment of VT/VF, additional steps in the evaluation process are necessary.

Identification of presence and extent of obstructive coronary artery disease

In patients with reversible myocardial ischemia, surgical or percutaneous revascularization may be pursued to improve patient outcome. Myocardial ischemia rarely results in recurrent sustained monomorphic VT. Therefore, in patients with known coronary artery disease, further testing is warranted only if the severity of coronary artery disease has not been previously established or prior episodes of VT caused hemodynamic compromise. In patients with frequent or incessant VT, catheter ablation may have to precede assessment for coronary artery disease in order to gain prompt control of the ventricular arrhythmia.

Identification of etiology and extent of myocardial disease

The etiology and extent of myocardial disease need to be defined prior to catheter ablation. At minimum, a transthoracic echocardiogram and usually assessment for coronary artery disease are recommended. In patients with nonischemic cardiomyopathy, further evaluation may include cardiac computed tomography (CT) or magnetic resonance imaging (MRI), in addition to endomyocardial biopsy.

Suspected peripheral vascular disease

In patients with suspected peripheral vascular disease, further evaluation may be reasonable. Anticipating a difficult arterial approach, the operator may select the transseptal route for left ventricular access.

Identification of type and burden of VT

The type and burden of VT needs to be identified. Ideally, a 12-lead electrocardiogram should be obtained. In patients with ICD, stored device data such as electrogram morphology and cycle length may be used to identify the clinical VT.

Imaging

Preprocedural imaging

Cardiac imaging, either *echocardiography, cardiac CT, or MRI,* is warranted in all patients with ventricular arrhythmias to assess for the presence and severity of cardiac disease. It facilitates identification of anatomic variations serving as substrate for VT initiation or impediment to successful catheter ablation. In particular, preprocedural MRI is useful for the identification of myocardial scar, ARVC, sarcoidosis, noncompaction of left ventricle, and left ventricular aneurysm. In patients with impaired ventricular function undergoing left ventricular mapping, the presence of a left ventricular thrombus needs to be excluded by transthoracic echocardiography[66-68] or other imaging tools. In patients with a history of atrial fibrillation, transesophageal echocardiography should be utilized to exclude the presence of a left atrial thrombus.

Intraoperative imaging

Coronary angiography is used to delineate the course of the coronary arteries in relation to site of ablation. Intraoperative *intracardiac echocardiography* (ICE) provides an alternative means if ablation is performed within the LVOT or the aortic cusps. Furthermore, ICE allows proper identification of the papillary muscles[55,69] Integrating electroanatomic mapping with ICE provides the operator with a 3-dimensional (3D) anatomical reconstruction of the ventricular chambers,[70] and may facilitate differentiation of normal from scarred myocardium and denote the presence of epicardial scar necessitating pericardial mapping and ablation. Newer strategies have integrated cardiac CT, positron emission (PET) CT or MRI with electroanatomic mapping systems. However, evidence is lacking that ICE or *preacquired volumetric imaging integrated into electroanatomic mapping systems* improves efficacy or safety of catheter ablation procedures.[71]

Anticoagulation Strategy

The thromboembolic risk of catheter ablation of VT/VF may differ in relation to individual patient factors and ablation site. Patients with structural heart disease undergoing ablation within the left ventricle are at particularly high risk. Therefore, it is recommended that left ventricular ablation procedures be performed using systemic anticoagulation. Table 2 summarizes different heparin regimens, thromboembolic events, and hemorrhagic complications during

TABLE 2

Postmyocardial Infarction Ventricular Tachycardia

Authors	No. Patients	No. Patients with Post-MI VT	No. Procedures	TE Prophylaxis	Thromboembolic Complications		Local Hemorrhage/ Tamponade	
					CVA/ TIA	Other	Hemorrhage/ Pseudoaneurism	Tamponade
Morady[72]	15	15	15	5,000 ini, 1,000/hour	0	0	0	0
Kim[73]	21	21	30	4,000 ini, 1,000/hour	0	0	0	0
Rothman[74]	35	35	44	NA	0	1	1	0
Stevenson[23]	52	52	69	5,000 ini, 1,000/hour	1	0	1	0
Callans[75]	66	66	95	5,000 ini, ACT 250—300	3	0	0	2
Ortiz[76]	34	34	42	5,000 ini, 1,000/hour	0	0	0	0
Calkins[77]	146	119	171	ACT >250	4	1	1	3
O'Callaghan[78]	55	55	55?	ACT >300	0	1	1	0
Borger *[79]	151	89	89	ACT >2.5–3 × baseline	2	0	0	1
Della Bella[80]	124	124	139	5,000–10,000 ini, ACT 200–250	1	2	0	0
O'Donnell[81]	109	109	109?	ACT >250	1	0	8	3
Segal *et al.*[82]	40	40	44	ACT >250	2	0	2	3
Stevenson[77]	231	231	252	Heparin dose not specified	0	0	11	1
Total	1,079	990	1,154		14 (1.3%)	5 (0.5%)	25 (2.3%)	13 (1.0)

*Data from this series refer to the 89 patients with post-MI VT.

CVA = cerebrovascular accident; ini = initial; MI = myocardial infartion; TE = thromboembolism; TIA = transient ischemic attack; VT = ventricular tachycardia; ACT = activated clotting time.

RF catheter ablation in 1,079 patients as published in 13 series including patients with a history of myocardial infarction.[23,72-83] Heparin regimens were usually controlled by measuring the activated clotting time (ACT), with a common target value of ≥250 seconds. The most serious complications were cerebrovascular accidents (CVA) and transient ischemic attacks (TIA) with an incidence of 1.3%. Pericardial tamponade, likely due to pericardial hemorrhage, occurred in 1% of cases. Local hemorrhagic complications (large hematomas or arterial pseudoaneurysms) occurred in more than 2% of patients.

Anticoagulation for right ventricular mapping and ablation

Unless other risk factors are present, catheter ablation within the right ventricle does not require use of systemic heparin. Some centers may use heparin for the prevention of deep venous thrombosis and pulmonary embolism, especially if a prolonged procedure is anticipated. Similarly, patients with a prior history of deep venous thrombosis or pulmonary embolism, presence of a hypercoagulable state (e.g., factor V Leiden), or right-to-left cardiac shunt should undergo systemic anticoagulation. Anticoagulation is not needed following the procedure.

Anticoagulation for left ventricular mapping and ablation in the absence of structural heart disease

Systemic anticoagulation with intravenous heparin is recommended intraoperatively for all patients undergoing left ventricular catheter ablation. In case of extensive ablation, aspirin may be given postoperatively at a dose from 75 mg to 325 mg for 4 to 8 weeks. Some centers advocate postprocedural warfarin use in patients with additional risk factors for thromboembolism.

Anticoagulation for left ventricular mapping and ablation in the presence of structural heart disease

Preoperative screening for left ventricular thrombus is required in all patients. Mobile left ventricular thrombus is an absolute contraindication to catheter ablation. In contrast, left ventricular catheter ablation may be performed despite the presence of laminated thrombus, if the patient has been therapeutically anticoagulated with warfarin for at least 4 weeks prior to ablation. Intraoperative anticoagulation schemes differ between centers. Unfractionated heparin is administered to maintain a target ACT ≥250 seconds. Certain electrode arrays with high thrombogenicity may require an ACT ≥300 seconds. Pericardial access should be obtained prior to ventricular instrumentation and the subsequent need for intraprocedural anticoagulation.

Sedation and Analgesia

In order to provide safe sedation and analgesia during catheter ablation for VT, a careful preprocedural assessment of the patient is indicated. Consultation with an anesthesiologist should be considered in high-risk patients. Trained personnel familiar with monitoring of blood pressure, pulse, and oxygen saturation need to be present throughout the procedure as dictated by state and institutional policy.[84] Training requirements for the safe administration of intravenous sedation and analgesia should follow the recommendations of the American Society of Anesthesiologists.[85] Conscious sedation or general anesthesia is commonly used during catheter ablation of VT. The optimal strategy depends on the patient characteristics. *Conscious sedation* is the preferred strategy in patients with catecholamine-sensitive VT or if VT was not inducible during a prior electrophysiology study. During conscious sedation, different drugs may be added to acquire deeper levels of sedation to prevent patient movement during epicardial puncture. The level of sedation may subsequently be titrated to allow induction of VT. *General anesthesia* is favored in children and in patients with risk for airway obstruction. The advantages of general anesthesia include enhanced patient comfort and minimizing patient movement, thereby facilitating vascular and epicardial access as well as catheter manipulation and ablation. In addition, ventilator cycle length settings may be adjusted to minimize catheter

movement during ablation. Last, the use of paralytic agents during epicardial mapping and ablation may preclude accurate identification of the phrenic nerve using high output pacing.

Mapping Methods for VT Ablation

The mapping techniques employed to guide VT ablation depend on the likely mechanism of VT and the nature of its substrate. Focal origin VTs can be localized by *activation mapping* and/or *pace mapping*. VTs that are due to scar-related reentry often arise from large reentry circuits. Activation mapping and pace mapping alone can be misleading. *Entrainment mapping* can be useful, but is limited when VT is unstable. *Substrate mapping* is useful in these cases. Mapping procedures commonly combine these different mapping techniques to facilitate identification of desirable ablation sites.

Activation Mapping

Activation mapping is the method of choice for identifying a *hemodynamically stable, focal VT*. It may be performed by point-by-point mapping with a roving mapping catheter, with the use of multiple catheters or multielectrode arrays. Electrograms may be recorded with unipolar, bipolar, and/or combinations of both recording methods as each has different advantages and weaknesses. *Unipolar recordings* are typically obtained with minimal filtering (e.g., high-pass filter corner frequency set to 0.5 Hz or lower), in which case the morphology of the recordings provides potentially useful information.[86-88] A QS configuration is typically seen at the origin of focal arrhythmias. An rS or RS configuration indicates a wavefront moving toward the recording electrode, hence the recording site is not at the origin of a focal VT. These morphologic characteristics are not sufficient, however, to be the sole guide to a VT origin, as a qS complex may be recorded over a region adjacent to the focus. Unipolar recordings contain a substantial contribution from far-field signals due to depolarization of myocardium remote from the recording site. In areas of scar, the far-field signal can obscure low-amplitude signals of interest that arise from slow conduction regions. Therefore, bipolar recording is favored for catheter mapping of scar-related VT. In *bipolar recordings* much of the far-field signal is subtracted out, facilitating recognition of low-amplitude signals.[86,88,89] Local activation is usually taken as the first peak of the bipolar signal. In bipolar recordings, spatial resolution is reduced by the fact that a discrete potential of interest may be due to depolarization of tissue beneath either or both of the recording electrodes. When the signal of interest arises from tissue beneath the proximal electrode ablation at the distal electrode may fail. This situation can be potentially recognized by simultaneous recording of unipolar and bipolar electrograms and high pass filtering the unipolar electrogram to reduce the far-field contribution to the signal.

For most activation sequence mapping a clear point on the QRS complex provides a useful fiducial point for measurement. The relation of this point to the onset of the QRS is determined. Depolarization that precedes the QRS onset, typically by less than 30% of the VT cycle length, is referred to as presystolic. Electrograms that are depolarized between the QRS complexes, in "electrical diastole" are often referred to as *diastolic electrical activity*. For focal VTs, such as idiopathic outflow tract VT, activation at the focus precedes the onset of the QRS and is the earliest point of activation in the ventricle. Most scar-related VTs are due to macroreentry. There is no earliest or latest point of activation. *Presystolic activity* is recorded from reentry circuit exit regions. Depolarization of isthmuses (channels) proximal to the exit is expected to occur during electrical diastole, often indicated by isolated potentials. Definition of the entire reentry circuit by activation mapping traces a continuous path of activation covering the entire tachycardia cycle length. In scar-related macroreentry VT, there are several factors that limit creation of complete activation maps. Identification of true local activation time can be difficult in areas with fractionated and split potentials, some of which can be far-field activation. Portions of the reentry circuit can be intramural or epicardial and not sampled. Diastolic activity occurs in some bystander regions in scars that are not part of the reentry circuit. For macroreentrant VTs, a complete activation map can be achieved for some stable VTs. In scar-related VTs, activation mapping is not a reliable method. Activation mapping data are often combined with entrainment mapping to distinguish bystander sites from reentry circuit sites and with substrate mapping data.

Activation mapping is the basic mapping technique in targeting *idiopathic VT* or PVCs originating from the RVOT or PAP, albeit pace mapping can provide additional assistance.[55,90] It is also the primary mapping tool in the ablation of *His-Purkinje-related VTs*, which includes verapamil-sensitive fascicular left VT.[91-93] It is also the primary method for targeting *foci that are triggering recurrent episodes of VF or polymorphic VT* with or without structural heart diseases.[42,94-96] Successful target sites often have a sharp potential, consistent with a Purkinje potential, preceding the QRS onset of VT or PVCs by 20 to 160 ms. In some patients PVCs that arise from the infarct scar originate from the exit site of a reentrant VT, such that activation mapping of the PVCs can be used to target ablation of a macroreentrant VT.[97]

The spatial and temporal resolution of point-by-point activation mapping is limited by the number of contact electrodes and the time required. Systems that provide greater spatial sampling are available. Basket catheters that have splines with multiple electrodes can be deployed in the ventricle.[98] These catheters have been used successfully to guide ablation of idiopathic RVOT VT/PVCs, and are of particular interest in patients with infrequent arrhythmia that limits mapping.[98] Spatial sampling is limited by the interspline and interelectrode distances, and endocardial contact is often limited due to the complex geometry of the ventricles. These catheters are not commonly used. The noncontact multielectrode array mapping system records signals from a 64-electrode array and calculates 3,000 virtual unipolar electrograms over the endocardial surface that is defined by roving mapping catheter[99] The sequence of depolarization is displayed visually from single beats, making it potentially useful to define activation sequence during nonsustained and poorly tolerated arrhythmias. It is not accurate for points that are more than 4 cm from the multielectrode array, and must be used with caution in dilated ventricles.[100,101] Filter settings have a significant effect on the activation maps and unipolar virtual electrograms with a QS onset, consistent with a VT origin, must be confirmed by inspection to ensure that they are not due to artifact. Studies using the system to define areas of

scar for substrate mapping and intramural foci support feasibility.[101-103]

Pace Mapping

Pace mapping is pacing in the absence of tachycardia to assess the possible relation of the pacing site to a tachycardia focus or reentry circuit.[104,105] Unipolar pacing from the distal ablation electrode may be performed, but causes a large stimulus artifact in the surface ECG.[106] Bipolar pacing from the closely spaced distal electrodes of the mapping catheter is more commonly used. Although the possibility for capture at either the distal or proximal bipolar electrodes can reduce spatial accuracy, this does not appear to be a major limitation[107,108] Use of current strengths near threshold should improve accuracy by limiting the size of the virtual electrode in the tissue and preventing capture of myocardium distant from the pacing site. Pacing thresholds ≥5 to 10 mA typically indicate insufficient electrode-tissue contact or inexcitable scar areas. The morphology comparison should be based on the 12-lead ECG. At the VT origin or exit, the paced QRS resembles the VT QRS. For idiopathic VTs, an exact match with all amplitudes and notches in 12-lead ECGs is sought. Studies comparing detailed analysis of QRS morphologies during pace mapping for outflow tract VT have shown that the resemblance to VT progressively decreases at sites further from the VT focus, but good pace-map matches can be seen over areas of more than 1 cm and more than 2 cm from the successful ablation site in some patients.[105,109] Catheter ablation at sites with a "perfect" pace map are typically successful.[109,110] Pace mapping can also be useful for LVOT VT, but is less reliable for arrhythmias originating from the aortic sinus cusps.[111]

Thus, pace mapping is likely to be less accurate than activation mapping. In contrast to activation mapping, however, pace mapping can be utilized during sinus rhythm, in the absence of VT. Therefore, it is particularly useful for identifying an initial region of interest when VT is rapid or difficult to induce. The quality of the information obtained from pace mapping is critically dependent on the spatial resolution of the mapping procedure within the 3D chamber/area of interest. Therefore, the combination of pace mapping with 3D mapping systems may be helpful to achieve better spatial resolution than fluoroscopy alone.

Specific clinical applications of pace mapping are focal VT and scar-related VT.

Scar-related VT

Pace mapping may also be used to define likely exit regions and reentry circuit isthmuses for scar-related VT.[112-115] The QRS morphology of the VT in the 12-lead ECG is an indication of the location of the reentrant circuit exit site. Pace mapping at the presumed exit site region from the "central common pathway" or "isthmus" replicates the QRS morphology of the VT with a relatively short (<40 ms) stimulus-QRS interval. However, an exact exit site pace-map match typically can be achieved over a relatively large area. It is important to recognize that pace mapping at reentry circuit sites that are not near the exit may produce a QRS that is different from the VT, even though ablation may be effective at that site.[115] Pace mapping also can provide additional information relevant to the arrhythmia substrate. A long stimulus-QRS, exceeding 40 ms, indicates slow conduction away from the pacing site, which can be the substrate for reentrant VT.[115] Areas of electrically unexcitable scar have been defined as regions with a pacing threshold >10 mA.[106] These areas may indicate dense fibrosis that may form the border of a reentry circuit path.

Entrainment Mapping

In patients with scar-related VT, the anatomic complexities of reentry circuits and regions of slow conduction make it difficult to define adequately reentry paths with activation mapping alone. A schematic drawing of a hypothetical reentry circuit with an isthmus, loops, and bystander is shown in Figure 2. The reentry wavefront travels from the entrance of the isthmus to the center and then exit of the isthmus. It then propagates around the scar as an outer loop, or through the scar as an inner loop, to reach the entrance. Entrainment findings consistent with different sites in and remote from reentry circuits are summarized in Figure 2. Four observations during entrainment are analyzed to identify the relation of the pacing site to the reentry circuit. The *postpacing interval* (PPI), measured from the last stimulus that entrains or resets tachycardia to the next depolarization at the pacing site, represents the conduction time from the pacing site to the reentry circuit, through the circuit, then back to the pacing site. Thus, the *PPI-tachycardia cycle length (TCL) difference* indicates the conduction time between the pacing site and the circuit. The PPI-TCL difference is not influenced by QRS fusion during entrainment and can help identify loops in the reentry circuit as well as isthmuses where pacing entrains tachycardia with concealed fusion.[116] The PPI-TCL difference is based on the assumption that the recorded ECG represents depolarization of the pacing site. Inability to distinguish far-field potentials, which are due to depolarization of tissue, remote from the pacing site, from the local electrogram is a source of error.[117] Recordings from the pacing site are not always obtainable or interpretable due to electrical noise after the stimulus. However, because the beat following the last entrained QRS (QRS_{n+1}) is not influenced by QRS fusion during entrainment, the QRS_{n+1} can be used as a timing reference to assess the PPI-TCL difference.[118] The stimulus-QRS_{n+1} to local electrogram difference indicates the PPI-TCL difference allowing assessment when the PPI cannot be measured directly from the pacing site electrograms. When pacing is performed from the protected isthmus, the QRS is the same as the VT QRS and there is no evidence of QRS fusion (*concealed entrainment*). Clear fusion will be observed when pacing is performed from an outer loop region. If the pacing rate is substantially faster than the VT, fusion will also be seen when pacing at the entrance of the protected isthmus. At sites with concealed entrainment bystanders can be identified by comparing the stimulus to QRS and electrogram to QRS intervals. Bystander areas have a stimulus-QRS interval longer than ECG-QRS interval. In this situation, the interpretation of the PPI-TCL difference is not necessary. The stimulus-QRS indicates the conduction time from the pacing site to the reentry circuit exit. Longer stimulus-QRS intervals indicate likely inner loop sites. At outer loop sites entrainment occurs with QRS fusion but the PPI indicates that the site is in the reentry circuit. Successful interruption of VT by ablation is low.[119] Sites where ablation is most likely to interrupt reentry are those with features of an isthmus site with a stimulus-QRS less than 70% of the VT cycle length and

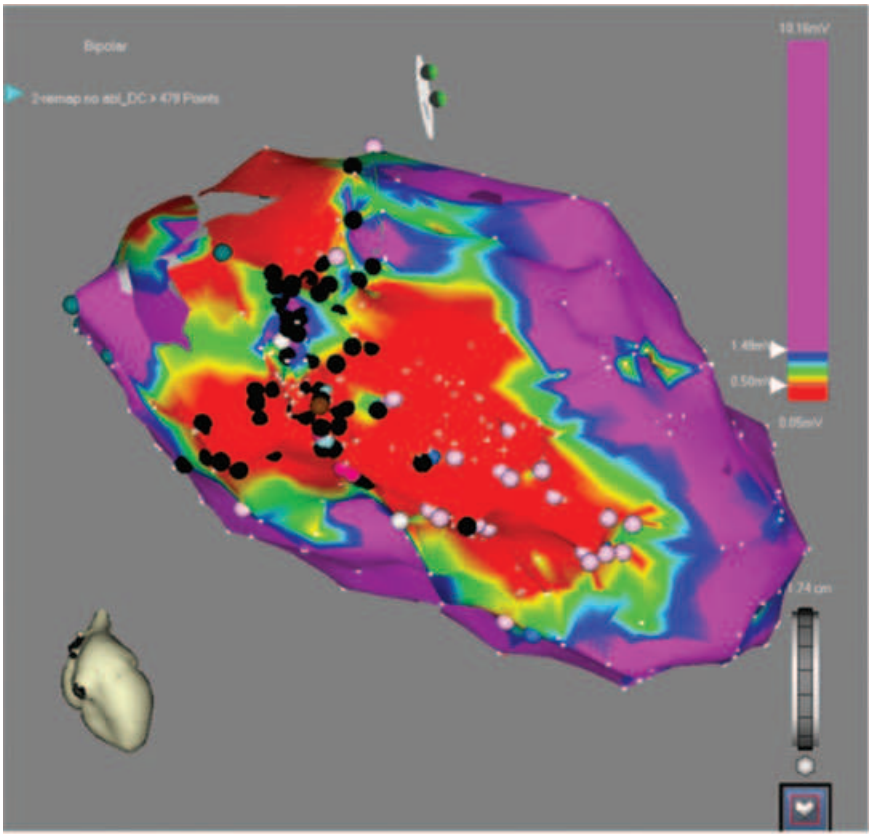

Figure 3. *Electroanatomic mapping for substrate ablation. A 3-dimensional left ventricular endocardial voltage map is shown in a patient with healed inferior myocardial infarction and VT. A voltage map constructed during sinus rhythm is designated by the color display: sites with bipolar voltage <0.5 mV are coded in red, sites with voltages >1.5 mV in purple, and the border zone of intervening voltages with the intervening colors. In this example, the location of late (black dots) and fractionated (pink dots) electrograms are also displayed.*

an isolated potential.[119-121] Pacing for entrainment mapping occasionally produces VT termination without global capture.[122] This finding is likely to indicate that the pacing site is in a reentry circuit isthmus that is a desirable target for ablation. Capture of the stimulus may occur with block of the orthodromic wavefront between the stimulus site and the exit and collision of the stimulation wavefront traveling in the antidromic direction in the circuit. Similarly, mechanical termination of VT can also be an indication that the catheter is at a reentry circuit site.[123]

There are many limitations of entrainment mapping. A stable tachycardia is required. Pacing that terminates or alters tachycardia complicates mapping and renders the entrainment mapping findings uninterpretable. It is difficult to apply for unstable VTs, although limited substrate mapping combined with limited entrainment mapping at selected sites followed by prompt tachycardia termination can be used to help locate a region for ablation during sinus or paced rhythm.[33]

Substrate Mapping

In a recent multicenter ablation study, 31% of patients had only unmappable VT and 38% had both mappable and unmappable VT morphologies targeted.[83] Substrate mapping is the approach of utilizing techniques that allow the majority of the *mapping and ablation to be performed in sinus rhythm*, and is required in many patients with VT in the setting of structural heart disease. It is often combined with limited activation and entrainment mapping. The concept of substrate mapping evolved from the success of surgical subendocardial resection for post-MI VT, which established the physical link between the VT circuit and the infarct scar.[124] Infarct regions are identified from *areas where electrograms have an amplitude of <1.5 mV* (bipolar electrograms recorded from catheters with a 4-mm tip electrode, 1 mm interelectrode spacing and filtered at 10–400 Hz)[113,125] (Fig. 3). This voltage threshold has also been applied to identify areas of scar in nonischemic cardiomyopathies, and ARVD.[126,127]

In patients with scar-related VT, the low voltage area is often large, such that complete ablation of the area or complete encircling ablation is often not feasible, nor necessarily desirable. There are several concepts that guide selection of ablation targets, all determined by different philosophies regarding the relationship of the VT circuit to the substrate. The first concept was pace mapping to identify exit regions in the border zone of the scar.[113] Linear ablation lesions were placed through each exit region, extending away from the border region into the denser scar due to the recognition that the critical isthmus may be deeper within the scar. A line of lesions may be placed parallel to the scar border within the low voltage area encompassing the exit region.[128] These strategies, although successful, are limited by their focus on individual VTs, requiring induction of VT to assess QRS morphologies for guidance during pace mapping, making it difficult to conceive of substrate ablation of undetected morphologies. Several investigators have targeted all isolated late potentials present during sinus rhythm or ventricular pacing, which are often present at reentry circuit isthmus sites identified for mappable VTs.[129] In some patients, areas of unexcitable scar that may be border forming for reentry circuits have been defined to attempt to identify isthmuses for ablation.[106] Alternatively, a "channel" may be identified as a region of relatively larger voltage bordered by low voltage within the scar.[130,131] These different substrate ablation

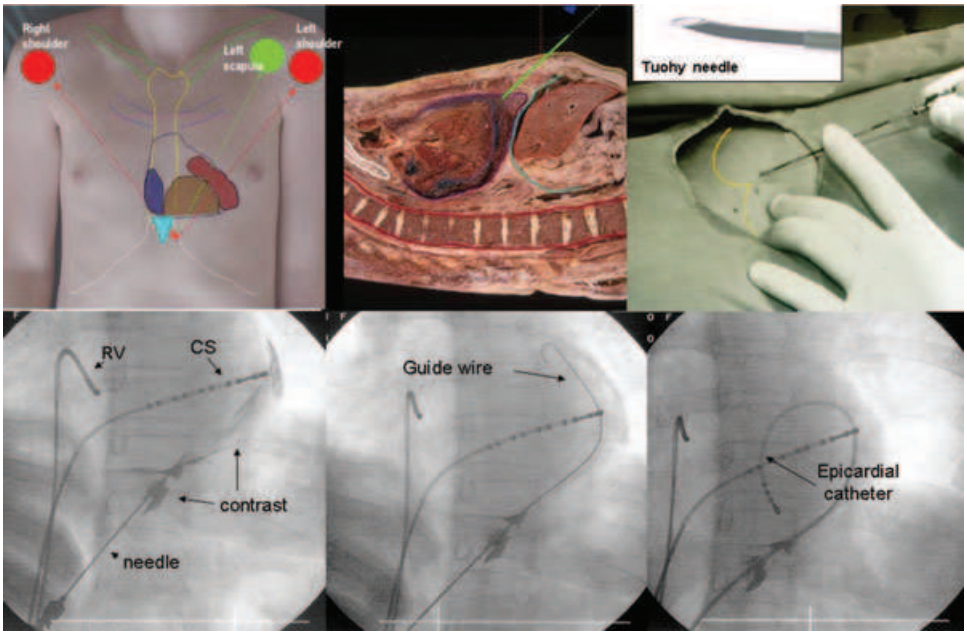

Figure 4. *A Tuohy needle (right superior corner) and anatomy relevant to epicardial access is shown. The sagittal anatomic image indicates the path of the needle for pericardial access (green line). Fluoroscopic images show contrast, a guide wire, and catheter in the pericardial space.*

strategies have not been directly compared and differences in outcomes are not apparent in the literature. Variations in anatomy may also influence the effectiveness of the different methods. Although ablation guided by substrate mapping avoids the hemodynamic consequences of prolonged mapping during VT, the lack of a precise reentry circuit target is compensated by extensive ablation lesion sets, which increases the potential for complications. In a recent multicenter study, major complications including worsening heart failure were observed in 7.3% of patients, and 3.0% died within 7 days of ablation.[83]

In general, substrate-guided ablation achieves a marked reduction in VT episodes (usually measured by a reduction of ICD shocks) in patients with scar-related VT.[33,83,113,114,129,130] It is a reasonable approach for patients with unmappable VT and may be combined with other mapping approaches in patients with mappable VTs.

Transthoracic Epicardial Mapping and Ablation

Recently introduced in 1995, transthoracic epicardial mapping and ablation has recently become an important adjunctive or even a preferable strategy to eliminate a diverse range of cardiac arrhythmias.[132–136] Briefly, a regular Tuohy-17G needle designed for epidural anesthesia is introduced at the subxiphoid region at a 45° angle and gently advanced under fluoroscopy until close to the cardiac silhouette. The precise site of the needle tip is determined by injection of 1 mL of contrast media. When the needle enters the pericardial space, contrast medium can be seen surrounding the cardiac silhouette (Fig. 4). A wire and introducer sheath is inserted, allowing a mapping catheter to be inserted into the pericardial space, where it can be manipulated to explore the entire surface of the right and left ventricles. Electrogram recording and interpretation for epicardial mapping are essentially the same as for endocardial mapping, including the use of activation mapping, pace mapping, and entrainment mapping. Epicardial mapping is facilitated by the smooth epicardial surface, without the limitation of papillary muscles, trabeculae, and chordae, as well as absence of catheter-induced ventricular extrasystoles that are encountered during endocardial mapping.

Standard RF ablation can be used during epicardial catheter ablation, but the lack of circulating blood for convective cooling of the ablation electrode limits power delivery in the pericardial space, potentially limiting lesion creation and efficacy of standard RF ablation.[137] *Irrigated RF ablation* allows greater power delivery and increased lesion size that can be effective even when the epicardial target is covered by fat.[137,138] External irrigation requires intermittent drainage of the pericardial space to prevent tamponade. Alternatively, use of an introducer that is larger than the mapping catheter allows aspiration around the ablation catheter. The amount of fluid infused can also be limited.

Risks of epicardial mapping and ablation

The potential for *coronary artery injury* is a major concern. There are 3 potential means by which damage could occur to the coronary arteries during transthoracic epicardial mapping and/or ablation. The needle can perforate a coronary artery during access; the ablation catheter or sheath could lacerate an epicardial vessel, which is unlikely because the coronary vessels are covered by the visceral pericardium, and the major concern is the risk of RF ablation on a coronary artery. Experimental data suggest that coronary artery occlusion depends on the vessel caliber.[137,139] It is recommended that proximity to the coronary arteries be defined by a coronary angiogram if the ablation site is suspected of being within 12 mm of a coronary vessel. On the other hand, there are centers that do not perform routine angiograms without any occurrence of acute and chronic coronary events.[46,140]

Imaging Tools, Energy Sources, and Catheters for VT/VF Ablation

Imaging Tools

Although imaging techniques at the present time play only a minor role in the field of catheter ablation of VT, as compared with A Fib, they do serve an important function both in preprocedural planning and in postprocedural follow-up. In addition, identification of the underlying heart disease and visualization of a potential arrhythmogenic substrate may facilitate selection of appropriate mapping and ablation strategies during catheter ablation of VT[141] and will likely increase the role of pre- and periprocedural imaging techniques.

Echocardiography

Transthoracic echocardiography serves as a reliable tool to rule out ventricular thrombi before left ventricular procedures. Additionally, it helps to identify relatively infrequent cardiomyopathies associated with VT, for example, ARVC and HCM, and is used for postprocedural detection of pericardial effusions and cardiac tamponade, respectively. *Transesophageal echocardiography* may be used in patients with atrial fibrillation or flutter to detect thrombi within the left atrium and the left atrial appendage, respectively, to prevent thromboembolic events when a transseptal access to the left ventricle or cardioversion are required. Severe atheroma in the aorta detected on transesophageal echo may encourage the operator to avoid the retrograde approach to the left ventricle. *ICE* applied from the right atrium and the right ventricle has been used for real-time imaging during VT ablation procedures.[142] It allows for visualization of scarred tissue and thus may help to identify the target area of ablation. ICE may guide ablation of RVOT and LVOT VT by visualizing the relationship between semilunar valves and coronary artery ostia, respectively, and the sites of VT origin.[143] In a small cohort of patients with VT originating from PAP, ICE helped to establish the site of origin and to guide successfully RF ablation.[55]

Cardiac CT and MRI

Both cardiac CT and MRI are valuable tools for assessing cardiac anatomy and function and for identifying structural abnormalities serving as *arrhythmia substrate*. Delayed contrast-enhanced MRI delineates regions of *scar tissue* potentially forming part of the arrhythmia substrate in patients with ischemic and nonischemic cardiomyopathies.[144,145] Additionally, this imaging technique allows for determining a specific etiology of nonischemic cardiomyopathies predisposing for a higher susceptibility for VT, such as myocarditis, sarcoid, and ARVC. Feasibility of catheter navigation and ablation in the left ventricle guided by registration of preacquired MRI with real-time electroanatomic mapping was demonstrated in a porcine infarct model.[146] Ablation catheters were successfully positioned to intracardiac target sites under direct visualization by MRI fluoroscopy. Visualization of ventricular anatomy and obstacles of procedural success, for example, epicardial fat in case of epicardial mapping approaches, and the possibility of navigation and ablation in the ventricular chambers has the potential to reduce procedure time, decrease the rate of complications, and increase success rate.[74,147] One potential disadvantage remains the concerns of the *safety of MRI* in patients with implanted devices. Increasing data suggest that MRI at 1.5 T is possible when appropriate precautions are taken,[148] and reports of MRI at 3 T have been published for patients with implantable defibrillators.[149] Industry is also working to improve the MRI compatibility of devices.

Other imaging tools

Cardiac catherization provides valuable information about the coronary arteries, LV function, and ventricular thrombi, representing a relative contraindication to catheter manipulation. Angiographic evidence of akinetic or dyskinetic bulgings within the right ventricle is highly specific to ARVC.[150] In patients with scar-related VT, PET CT may be beneficial, as it provides additional tissue characterization by displaying metabolic and morphologic information.[147,151,152]

Energy Sources and Catheter Technologies for VT Ablation

The principal problem facing catheter technology when applied to VT ablation is to deliver a controlled lesion to abolish the arrhythmia substrate but not so big as to damage nonarrhythmogenic tissue. Induction of very limited tissue damage may be desired during catheter ablation of focal idiopathic VT. However, many patients with VT have a large arrhythmia substrate involving endocardial, intramural, as well as epicardial structures. In these patients, more extensive tissue lesions may be required. Thus, from a biophysical perspective catheter ablation of VT is a true challenge.

Energy Sources

RF ablation

Since its first description in 1978, RF energy has become the most commonly, if not exclusively used energy source for catheter ablation of all VT entities.[153-157] *RF alternating current* is usually administered with a continuous sinusoidal unmodulated waveform of 300–1,000 kHz and allows the generation of *well-circumscribed myocardial lesions*. The most important mechanism of myocardial necrosis induction is based on the conversion of electrical energy into *heat* within the myocardial tissue.[158] (Fig. 5) The extent of the tissue damage depends on the duration of RF energy application[158-160] and the temperature in the resistive heating zone with higher RF power delivery invigorating an increase in lesion size.[161] However, at a certain energy level *electrode overheating* may occur leading to *coagulum formation and charring* on the tip electrode accompanied by a *rapid increase in electrical impedance* that in turn leads to a loss in effective myocardial heating.[162] To prevent overheating at the electrode-tissue interface, temperature-controlled energy application systems have been developed. A thermistor or thermocouple embedded in the tip of the ablation catheter allows temperature monitoring at the electrode-tissue interface during energy application. Maximal RF energy (usually 50 W) is delivered until the preselected target temperature has been reached and thereafter automatically titrated down to maintain the target temperature. The extent of lesion formation not only depends on RF duration and power but also on nonmeasurable variables like electrode-tissue contact and

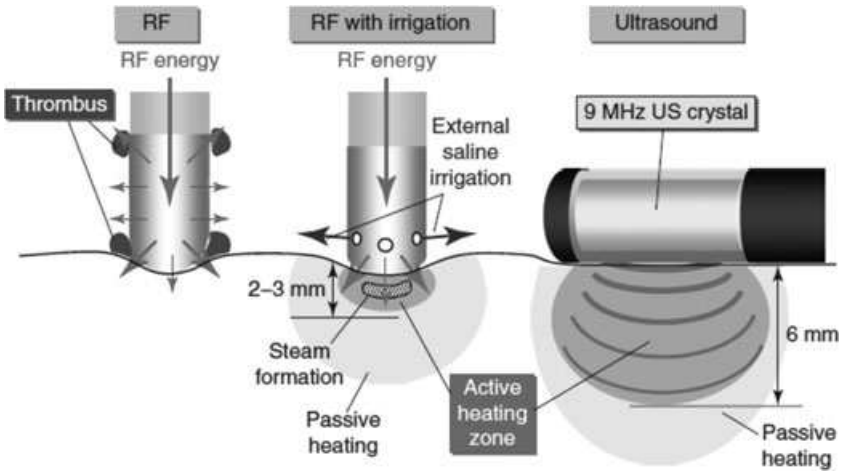

Figure 5. *Comparison of radiofrequency (RF) energy for lesion formation and risk of steam pop and thrombus. Left panel: RF ablation using a nonirrigated electrode results in thrombus formation when the interface temperature between the electrode and the tissue or the electrode and blood reaches 75–80°C. Center panel: RF ablation using a saline-irrigated electrode prevents thrombus. However, a higher RF power application produces a focal hot spot 2–3 mm below the surface, resulting in steam formation within the tissue and a steam pop. Right panel: Ultrasound energy at 9 MHz penetrates myocardial tissue to a depth of 5–6 mm and produces a homogeneous active tissue heating, resulting in a deeper lesion with a lower risk of steam pop and thrombus.*

orientation (perpendicular vs parallel to the tissue) and external cooling by the circulating blood flow.

Irrigated RF ablation

Despite a lack of randomized trials comparing different approaches for VT ablation, there is general agreement that irrigated electrodes provide advantages over standard RF ablation in the setting of scar-related VT. Active cooling of the ablation electrode, either by circulating fluid within the electrode (*closed loop*) or by flushing saline through pores in the electrode (*open irrigation*),[176] allows greater energy delivery before a critical temperature rise at the electrode-tissue interface occurs, and larger lesion formation.[158,163-166] Although currently no clinical studies are available directly comparing closed loop irrigation with external irrigation, it seems that the latter technique may have distinct advantages. External saline irrigation resulted in a lower interface temperature and decreased the risk of thrombus formation and severe tissue damage as compared with closed loop irrigation at similar levels of impedance, lesion depth, and tissue temperature in an experimental preparation.[167] However, administration of relatively large amounts of saline using external irrigation, which may exceed 2,000 mL, may cause hemodynamic or respiratory compromise especially in patients with severely impaired left ventricular function, which necessitates continuous monitoring of fluid balance. Saline irrigation cools the electrode itself and thus impedes electrode temperature feedback resulting in an increased risk of unnoticeable tissue overheating. If the intramyocardial temperature exceeds approximately 100°C, gas bubble formation may occur leading to an explosion of steam that may in turn cause myocardial perforation and cardiac tamponade. These "*steam pops*" are audible in the electrophysiological laboratory but usually without consequences when energy is applied to the left ventricle. However, perforation of the right ventricle after "popping" has been reported.

Three large studies showed the feasibility of both internal and external irrigation in ablation of VTs in the presence of structural heart disease.[77,83,168]

Pulsed RF ablation versus continuous RF ablation

In addition to the abovementioned techniques, energy delivery to the myocardium can be influenced by the mode of RF application. RF energy can be applied either continuously over a certain period of time or repetitively with the single periods (duty cycle) lasting a few milliseconds. The latter approach, referred to as "pulsed RF ablation," allows the application of higher energy levels to the myocardium at comparable electrode temperatures[169] As compared with continuous RF current delivery, the pulsed mode is associated with higher intramyocardial temperatures and larger lesion depths in vitro and in vivo.[169,170]

Alcohol ablation

Chemical ablation for VT is based on cytotoxic and irreversible tissue-damaging effects of ethanol and other agents leading to myocardial necrosis and coronary vessel occlusion with resultant ischemic injury. Before ethanol application is performed, it is crucial to identify the *target coronary artery* that supplies blood to the arrhythmogenic area. One means of target vessel identification is by selective injection of cooled saline, radiographic contrast medium, or antiarrhythmic drugs into different coronary branches.[171-173] VT termination identifies the branch supplying the arrhythmogenic substrate. Alternatively, mapping of diastolic potentials as well as entrainment and pace mapping may be performed from inside the coronary artery to locate the critical reentry circuit isthmus as for standard VT approaches.[174] After an appropriate target branch has been identified, ethanol is applied in a manner similar to the approach used for septal alcohol ablation in patients with obstructive HCM. Ethanol ablation has moderate success rate and bears potential of serious complications including permanent complete atrioventricular block, pericarditis,[171,173] reflux of ethanol into adjacent vessels leading to infarction of unintended myocardium, and a worsening of heart failure due to a significant loss of myocardium. Consequently, ethanol ablation should be considered only in selected patients suffering from highly symptomatic drug-refractory VT who failed previous endocardial and/or epicardial RF ablation.

Cryoablation

For more than 2 decades, cryoenergy has been successfully used for ablation of ventricular myocardium during surgical ablations of VT.[172,175,176] Cryoablation produces more circumscribed and generally smaller lesions as compared with RF current. It possibly involves less damage to adjacent coronary arteries in the setting of epicardial ablation as compared with RF ablation.[177,178] Currently, no data from

controlled clinical studies exist concerning the use of cryoenergy for catheter ablation of VT.

Other energy sources

Other energy sources that have been investigated for catheter ablation of ventricular tachycardias include high-intensity-focused ultrasound, laser energy as well as radiation energy applied transcutaneously. No clinical studies exploring these energy sources have been performed so far.

Ablation Catheters and Electrode Design

Electrode catheters used for ablation of VT usually have a size of 7.5 French and unidirectional or bidirectional steering capabilities. RF energy is usually delivered via the distal tip of the electrode catheter. Currently, platinum-iridium is the most commonly used catheter tip material. One advantage of RF ablation is the simple design of the energy delivery system, that is, a wire connects a generator to the tip electrode. In principle, larger electrodes allow the application of higher energy levels to the tissue due to greater exposure to the circulating blood resulting in more effective electrode cooling.[179] For conventional nonirrigated ablation procedures, the length of the ablation electrode measures 4, 5, 8, and 10 mm. Ablation electrodes used for external irrigation ablation have a 3.5 mm tip. The tip has 6 to 9 irrigation holes that are used to homogeneously distribute the saline over the ablation electrode during energy application.

Mode of Energy Application, Selection of Ablation Catheters, and Energy Settings

The selection of the mode of RF energy application, that is, nonirrigated versus irrigated ablation, the ablation catheter, and the energy application setting depends on the type of VT targeted by ablation.

Idiopathic outflow tract VT

These arrhythmias are focal in nature and the target tissue consists of structurally nondiseased myocardium. Thus, extensive tissue injury is usually not necessary for successful ablation. Steerable catheters with 4- or 5-mm tip electrodes and conventional nonirrigated energy application are generally used. The target temperature and output power should be limited to a maximum of 60°C and 30–40 W, respectively. Duration of energy application should not exceed 30–60 seconds. Because of the close anatomical relationship between energy application sites and the ostia of the coronary arteries, special caution is necessary for ablation of outflow tract VT arising from the coronary cusps. Lower energy and temperature levels may be adequate in this situation. Some investigators recommend the use of lower target temperatures and irrigated electrodes for left-sided idiopathic focal VT assuming a higher risk of coagulum formation and thromboembolic complications *compared with ablation in the right ventricle*.

Idiopathic fascicular VT and bundle branch reentrant VT

Due to the discrete nature of the arrhythmia substrate, the same settings as for idiopathic outflow tract VT are recommended.

VT originating from structurally diseased myocardium, scar-related VTs

Catheter ablation of scar-related VT usually requires induction of more extensive tissue injury to abolish the arrhythmia substrate. Therefore, larger or irrigated electrodes are preferred. Currently, there are no randomized studies available comparing the efficacy and complications of this approach with standard approach. Using 8 mm electrodes, a maximum output power of up to 70 W with a target temperature of 70°C or an impedance fall of 10 Ohms is reasonable in the left ventricular myocardium. When irrigated ablation is used output power is usually limited to 50 W, delivered during a saline irrigation rate of 20–30 mL per minute, whereas maximum catheter tip temperature should not exceed 50°C. Application duration of up to 90–120 seconds may be chosen.

Epicardial ablation

Ablation of epicardial idiopathic focal VT may be performed with standard 4-mm electrode catheters at power settings between 25 and 40 W. Although the coronary arteries are usually protected from severe injury induced by RF energy by the high flow rate in the vessel (leading to significant convection of heat), caution is recommended. Coronary angiography may be performed before energy delivery and energy setting may be adjusted to the individual situation. For patients with structural heart disease undergoing epicardial ablation, use of irrigated catheters may have significant advantages compared with conventional ablation; usually larger lesion are desired that can be more reliably induced with irrigated ablation. In addition, energy delivery during conventional RF application may be limited by the fact that application of relatively low power results in rapid heating of the ablation electrode thereby preventing the generation of large lesion due to the absence of cooling of the electrode by the circulating blood. External irrigation leads to saline accumulation in the pericardium during epicardial mapping and ablation. Thus, periodic aspiration is necessary to prevent hemodynamic compromise.

Ablation of VT/VF in Patients with Structural Heart Disease: Techniques and Results

It is estimated that only 10–30% of patients with structural heart disease have VT suitable for ablation guided only by activation and entrainment mapping during the arrhythmia.[113,180-182] In all the other patients, substrate-based mapping and ablation is required.

VT Ablation in the Setting of Ischemic Heart Disease and Prior Myocardial Infarction

It has been demonstrated that the underlying mechanism for VT in this setting is scar-related reentry.[183-186] Although an epicardial approach to catheter ablation may be needed in some refractory patients, most of these VTs are amenable to endocardial ablation.

Approach to catheter ablation of VT

It is important to obtain ECG recordings of all clinical VT when available. Similarly, electrogram analysis from the

device interrogation can be helpful in determining the cycle length of the VT.

With the electrophysiologic procedure and ablation attempts, an effort should be made to induce all potential morphologically distinct VTs. Bundle branch VT, although less commonly identified in prior myocardial infarction, should be excluded. In patients without inducible sustained VT and those with unstable VT, a *substrate-based ablation* is used. Preferential channels of conduction in the scar can also be identified by titrating the color range of the bipolar voltage map from the typical setting of 1.5 to 0.5 mV to values down to 0.2 mV to 0.1 mV. Pace mapping can be performed along the dense scar border (0.5 mV) based on an assessment of the 12-lead ECG morphology of all spontaneous and induced VT. During pace mapping not only the similarity of the QRS morphology to the pace map but also the time to the QRS is assessed with intervals greater than 40 ms suggesting areas of slow conduction that may approximate VT isthmus sites. Sites of inexcitability defined by failure to capture at 10 mA and 2 ms pulse width are also identified. These sites may also serve as anatomic boundaries for VT circuits and help further define channels of preferential conduction. Once bipolar scar voltage mapping has been performed and pace mapping identifies areas of interest, ablation lines are created. Lines are drawn to cross through sites of good pace maps and defined channels. Lines have been effectively deployed extending parallel to the scar edge in the border zone of the scar. When lines are deployed parallel to the scar they should be within the zone defined by a color range of 0.5 to 1.0 mV to avoid damaging normal myocardium under subendocardial scar. Lines perpendicular to the scar border and connecting the scar to anatomic boundaries have also been successful in eliminating VT. Many operators will draw lines in both directions. In one study, critical isthmus was identified in 25 (63%) of the 40 patients and linear lesions, averaging 4.3 cm, abolished all inducible VTs.[33,187] When targeting late potentials, lesions are frequently applied in clusters to eliminate the potentials. The *endpoint for VT ablation* tends to be hierarchal in nature and is currently based primarily on VT inducibility. The highest priority goes to trying to eliminate VT that has been documented to occur clinically, easily inducible VT with a slow rate and then finally all inducible VTs. Because *noninducibility* is currently used as the gold standard for the ablation procedure, it is recommended that a standardized protocol of single, double, and triple extrastimuli be used from at least 2 sites to define success. Poorly tolerated VTs and the ongoing use of antiarrhythmic agents warrant a more aggressive substrate-based ablation approach, if reproducible VT triggers have not been identified.

Outcome of VT ablation

Successful acute termination of the targeted VT, when it is stable and can be localized using activation and entrainment mapping, can be achieved in 70% to 95% of patients with limited RF application.[121] However, following ablation, VT can recur in up to 35% of patients.[78,120,187] Outcome appears to be improved with irrigated ablation techniques.[158] Substrate-based ablation results have produced comparable outcome results in single-center reports. Recurrence rates during intermediate-term follow-up has varied from 17% to 36%, but patients with recurrences have demonstrated a reduced frequency of VT episodes.[33,113,125,129,130,189,190,191] Several multicenter prospective trials have assessed the efficacy of VT ablation in the post-MI patient.[77,83,168,182] In the first reported multicenter trial of 146 patients with mappable VT and ablation performed with an internally irrigated catheter, 82% of the patients had coronary artery disease. During an average follow-up of 8 months, 54% were free of VT.[77] Eighty-one percent of patients followed up for more than 2 months had a greater than 75% reduction in VT episodes. Procedure-related mortality was 2.7%. Other complications included tamponade and stroke, each in 2.7% and myocardial infarction in 0.7%. The Multicenter Thermocool Ventricular Tachycardia Ablation Trial also enrolled 231 patients with recurrent VT in the setting of prior MI.[83] VT ablation used an open irrigation RF catheter guided by an electroanatomic mapping using both entrainment mapping and/or substrate mapping to guide ablation.[83] Unmappable VT was present in 69% of patients. During the 6-month follow-up period, 51% had recurrent VT. The frequency of VT was reduced with a >75% reduction in VT recurrence in 67% of patients. Procedure mortality was 3% with 6 of 7 deaths related to uncontrollable VT, and one due to tamponade with myocardial infarction. There were no strokes or thromboembolic events. Nonfatal complications occurred in 7% of patients, including heart failure and vascular access complications. Finally, the Substrate Mapping and Ablation in Sinus Rhythm to Halt Ventricular Tachycardia (SMASH-VT) multicenter study enrolled 128 patients with prior MI.[182] All patients were receiving an initial ICD for VF, unstable VT, or syncope with inducible VT.[182] Patients were randomized to substrate-based ablation versus a control group handled in a routine fashion. There was no procedure mortality. During an average follow-up of 23 months 33% of the control group and only 12% of the ablation group received appropriate ICD therapy for VT or VF.

VT Ablation in the Setting of Nonischemic Cardiomyopathy

Approach to catheter ablation of VT

The substrate for VT typically surrounds the aortic and mitral valve region and then extends apically.[193] Frequently, the substrate may be solely or predominantly intramural or epicardial.[35,194-196] Because of the frequent presence of an epicardial substrate, some experienced operators use a simultaneous endocardial and epicardial mapping approach.[71,197] Epicardially, the presence of a wide (>80 ms) split, and late electrograms are required to identify an arrhythmogenic substrate.[196]

Outcome of VT ablation

There are only a few single-center reports on acute outcome of VT ablation with short-to-intermediate-term follow-up in a relatively small numbers of patients in the setting of nonischemic cardiomyopathy.[35,126,198] Acute success in eliminating inducible VT has varied from 56% to 74% with VT recurrence of 42% to 75% with endocardial ablation. Outcome appears to be somewhat improved with epicardial ablation, but long-term follow-up in a large cohort of patients has been lacking.[35,196]

VT Ablation in the Setting of ARVC

It is critical to distinguish benign "idiopathic" focal VT originating from the outflow tract or peritricuspid valve regions of the right ventricle from VT associated with ARVC. The diagnosis of ARVC is dependent on meeting Task Force criteria.[199,200] However, *voltage mapping* should also be used to help establish the presence of a significant substrate abnormality consistent with the disease process.[37,201] Mapping of the right ventricular free wall especially in the perivalvular region may be technically challenging. Confirmation of contact by demonstrating capture at low pacing output and identification of signals that are not only small in amplitude but frequently split or late can allow one to eliminate small signals due to poor contact or intracavitary points and help identify important targets for subsequent mapping and ablation[201] Of note, LV involvement is probably more frequent than previously recognized.[202] Moreover, data from both pathological studies and recent reports on detailed substrate mapping suggest that epicardial involvement is more common than endocardial involvement with the disease progression.[203-205]

Approach to catheter ablation

Because most VTs occur in the setting of a significant substrate abnormality and are reentrant in mechanism, standard activation and entrainment mapping techniques can be applied to identify a critical isthmus to target for ablation for hemodynamically tolerated VT.[23,31,116,206,207] Substrate-based ablation techniques can be used for poorly tolerated, unmappable VT.[113] With irrigated catheters power titrated to achieve an impedance drop of 10–15 ohms with a maximum temperature of 42 to 45°C appears to allow for safe lesion formation without steam pops. The endpoint of ablation remains the noninducibility of monomorphic VT with programmed stimulation through triple extrastimuli.

Outcome of VT ablation

No large prospective multicenter studies have been performed to assess the value of endocardial ablative therapy in reducing VT recurrences in this patient population. Single center studies reporting on the outcome of 11 to 32 patients have in general been fairly consistent in their acute and follow-up outcome results.[36,42,201,208-214] The ability to eliminate all inducible VT appears to range from 72% to 88%. Most patients have remained arrhythmia free during long-term outcome with recurrence rates of 11–50% in part related to duration of follow-up. To date only one study has reported a very poor acute (46% noninducible) and then long-term outcome (83% recurrence rate). This study included a series of patients who did not undergo irrigated catheter ablation and/or substrate-based ablation.[212] The use of 3D mapping systems was also limited in this report. Nevertheless, recurrence of VT after endocardial ablation does occur and the requirement of antiarrhythmic drug therapy has been commonly reported by some investigators.[36]

VT Ablation in the Setting of HCM

In HCM, 2 main factors may predispose to ventricular arrhythmias: the myocardial disarray and the increase in left ventricular mass. The most common ventricular arrhythmias observed with programmed electrical stimulation include polymorphic VT and VF.[215] On the other hand, clinical sustained monomorphic VT in patients with HCM seems uncommon but may be underestimated because of early degeneration into VF.[216] Patients with HCM and left ventricular apical aneurysm represent an underrecognized but important subgroup.

Approach to catheter ablation and outcome of VT ablation

The ablation strategy applied to a monomorphic VT in patients with HCM is the same as in the setting of an old myocardial infarction. It is important to mention that placement of ablation catheter into the narrow neck of an apical aneurysm can be technically challenging because the narrow neck frequently obliterates during systole. Before maneuvering the ablation catheter, it is advisable to perform an angiography or other detailed echocardiographic or CT imaging of the aneurysm and its neck. Such imaging may facilitate the entrance into the aneurysm and may identify the presence of a left ventricular thrombus that may cause the procedure to be aborted.

Only a few cases have been reported in the literature on the ablation of VT in HCM and essentially regard patients with apical aneurysms treated with success.[217]

VT Ablation in the Setting of Congenital Heart Diseases

The occurrence of arrhythmia disturbances and, in particular, VT in the setting of congenital heart disease varies according to the underlying anatomic defect and method of surgical repair. Usually, the congenital malformations are severe in 30% to 50% of cases, requiring surgical procedures during early childhood. In the majority of cases, VT is a consequence of prior corrective surgery, which can create the ideal substrate for reentrant tachycardias due to the action of patches and sutures in conjunction with hypertrophy and fibrosis that create the necessary block and slow conduction to promote reentry. Catheter ablation has become an indispensable treatment option for this group of patients. The majority of data are centered on repaired tetralogy of Fallot that has a prevalence of VT between 3% and 14%[218-222] and is associated with a risk of SD of 2% per decade of follow-up.[218] The pathophysiologic mechanism of VT is a macroreentrant circuit in most cases, often involving narrow conduction corridors defined of regions of surgical scars with natural conduction barriers, such as the edge of a valve annulus.[223,224] In patients with operated tetralogy of Fallot and VT, the macroreentry involves the RVOT, either at the site of right anterior ventriculotomy or at the site of ventricular septal defect patch.

Approach to catheter ablation

In the occurrence of sustained, hemodynamically tolerated VT, the principal electrophysiologic diagnostic maneuver is the entrainment mapping. In patients with very fast, poorly tolerated VT, the use of electroanatomical mapping systems with voltage maps can be quite useful for detecting areas of scars in the RV. In patients with repaired tetralogy of Fallot, it could be important to create bidirectional block of conduction between the tricuspidal annulus and the RVOT patch. Creating a bidirectional block may allow ablation in sinus rhythm without the need to map or ablate during VT.[225] Indeed, the isthmus between the anterior wall of RVOT scar/patch and tricuspidal annulus is involved in

roughly 75% of VT cases in patients with repaired tetralogy of Fallot.[226] In the literature, it is reported a success rate of 60% using electroanatomical mapping and/or conventional techniques[227,228] and of 50% using the noncontact mapping in patients with VT after surgical repair of CHD.[40]

Outcome of VT ablation

Several case reports have been described in the last few years, but unfortunately the follow-up is not uniform. In 2 small series,[133] a total of 30 patients have been assembled, including tetralogy of Fallot (17 cases), ventricular septal defect (8 cases), and miscellaneous CHD (5 cases). Based on these results, catheter ablation was acutely successful in 25 out 28 procedures (89%) and later VT recurrence was documented in 5 cases (20%). Some of the recurrences could have been related to the difficulty with RF current to create a sufficient lesion in the often thick-walled chamber, like the right ventricle in the tetralogy of Fallot.

VT Ablation in Other Clinical Settings

Chagas' disease

VT in Chagas' disease can have heterogeneous presentations but occurs predominantly due to a reentrant mechanism,[229,230] sometimes clustered in electrical storms.[231,232] Myocardial damage can occur in various areas of both ventricles, but the inferolateral segment of the LV is the most commonly involved site, with frequently observed wall motion abnormalities; apical aneurysmal formation and mitral isthmus circuits are also common.[193,233-236] In this areas, endocardial mapping frequently depict fragmented late potentials in sinus rhythm as well as continuous or diastolic activity during VT. Histological analysis of those segments has shown focal and diffuse fibrosis that is predominantly subepicardial with nonuniform anisotropy of the surviving fibers.

In a recent report on 138 patients,[237] successful ablation (defined as termination and noninducibility) was possible in 52% of patients. Importantly, only 2 major complications were described (one abdominal cavity bleeding due to an injured diaphragmatic vessel that required laparotomy and another with coronary artery occlusion of a marginal branch that caused non-Q-wave MI). Minor complications were represented by precordial distress, present in 29% and drainable hemopericardium, present in 4.5% of cases.

Sarcoidosis

VTs in cardiac sarcoidosis are usually multiple reentrant monomorphic VTs (scar-related), with either left or right bundle branch morphology; low-amplitude and fragmented potentials are recorded both in the endocardial and epicardial regions of both ventricles.[38,238] Two patterns of regional wall motion abnormalities are frequently observed, involving the basal free wall and the anteroapical septum.[193] Catheter ablation for VT is indicated in patients with frequent episodes refractory to medical treatment. The reported success rates ranges from 25%[38] to 70%[238] in a recently reported registry and depends on the location of the reentrant circuit. The most frequent circuit was found in the peritricuspid area.

Idiopathic LV aneurysms

Idiopathic left ventricular aneurysms are defined as aneurysms of unknown etiology in the presence of normal coronary arteries and absence of angina or history of myocardial infarction; it is a rare condition frequently associated with reentrant VTs.[239,240] The LV aneurysms are smaller in size and more often located at the posterior and/or inferior wall, as opposed to postinfarction aneurysms that are often located at the anterior wall.[241,242]

The inducibility of VT on EP study is high and the majority has right bundle branch morphology. One of the largest reported series of cases[242] described an approach using irrigated endocardial and epicardial catheter ablation of VT from a left ventricular aneurysm in 4 patients. In that report, 75% were VT free during 31 months of follow-up using an aggressive ablation approach. Other reports have shown that RF catheter ablation could be performed around the neck as well as inside the aneurysms.[174-176]

VT after cardiac surgery

Coronary artery bypass surgery usually has an antiarrhythmic function in patients with VT or VF and an ischemic substrate; there is, however, a selected group of patients who either develop or aggravate ventricular arrhythmias after surgery. These may present as de novo VT occurring as a consequence of surgery. One of the largest published series reported on 3,820 patients undergoing CABG in a single center;[243] 12 patients (3%) developed de novo-sustained VT a mean of 4.1 days after surgery. In most cases (92%), no postoperative complication could explain the occurrence of VT. De novo-sustained VT may also develop after corrective valve surgery. A recent report by Eckart *et al.* demonstrated that most of these VT appear to be scar-based and to have a reentrant mechanism although bundle branch reentry must be excluded.[192] The scar is predominantly located around the periaortic and mitral valve regions.

Mapping strategies as described for VT in the setting of prior infarction can be used successfully to eliminate VT.

Ablation of VF

VF is usually initiated by a PVC during the vulnerable period of cardiac repolarization. Ablation therapy for VF has been recently described and increasingly reported. Most cases of VF appear to originate from the His-Purkinje system, although some cases have initiating events that are distinct from the cardiac conduction system.[244-249] Catheter ablation of VF has been attempted in the following clinical settings: postinfarction, LQTS, Brugada syndrome, infiltrative cardiac amyloidosis, postcardiac surgery, and normal heart (idiopathic VF).[94,95,244-246,250-258]

Approach to ablation

As mentioned before, the His-Purkinje system is the most frequent site of initiation of VF. This adds some complexity to the mapping process. Recording of the 12-lead ECG of the triggering event can prove valuable in regionalizing the origin of VT for more detailed mapping and an effort to record such a trigger should be routine. During activation mapping of the PVC, special attention must be paid to preceding sharp *Purkinje-like signals*. These may precede the local ventricular activation during the PVC by tens of

milliseconds. Mapping should be focused on the earliest activation of this potential. One may see earliest Purkinje-like potential activation in one spot and later activation of the potential proximal and distal to that spot. With multipolar catheters placed in the His position and down the left ventricular septum, one can see the progression of the signal through the conduction system with the His potential activating last. Sometimes, the potential may be seen with block to the myocardium and not producing a PVC. Determining the *earliest potential* is the key to successful ablation. Pace mapping of the area of interest also requires special care. The pacing amplitude output should be adjusted to attempt to capture the His-Purkinje system alone; otherwise, the pace mapping will appear dissimilar.

The Purkinje network is present on the superficial endocardium and tends to respond to ablation quickly and without the need for prolonged ablation times or high power. In cases that a PVC is not spontaneous or inducible, ablation may be performed along the distal LV septum with Purkinje-like potentials in sinus rhythm, assuming the PVC has this morphologic type. In patients with myocardial scar from previous myocardial infarction, a high-density scar map should be performed with careful attention to the border of the scar and normal tissue, since the PVC may originate from this border. Along the border, one may see Purkinje-like potentials. Further ablation may be performed in the area of arborized Purkinje-like potentials and around the scar border. In patients with normal hearts and PVC that appear to be from areas other than the His-Purkinje system, standard ablation techniques of activation mapping of the earliest local electrogram and pace mapping are typically employed.

Outcome of VF ablation

In general, patients who undergo ablation of VF are critically ill with storms of lethal arrhythmias, not responding to medical therapy, and very likely to die without further intervention. Patients with ICDs or in ICU settings have received over 50 shocks in a 24-hour time period.[94] Discussions of ending life-sustaining measures are frequently initiated before ablation is offered, and many physicians do not realize that ablation is a potential therapy. Understanding this, ablation is frequently associated with success rates greater than 90%. Of course, this is a very select population of people that survive to undergo ablation in the electrophysiology laboratory. Further study is needed to define the role of ablation in cases that are not medically refractory.

Ablation of VT/VF in Patients without Structural Heart Disease: Techniques and Results

Outflow Tract VT

Outflow tract VTs are not easily inducible at baseline electrophysiologic testing and may require rapid burst pacing and/or stimulation by isoproterenol. VT may become incessant under stress or with isoproterenol, and cannot be terminated by programmed electrical stimulation.[259-262] VT can be abolished with discrete RF lesions, demonstrating that the cells responsible for the arrhythmias are contained in a very small area.[263] Catheter ablation represents a viable alternate to medical therapy, especially in those patients who do not respond or are intolerant to pharmacologic treatment. In the absence of inducible tachycardia, pace mapping is used to localize the discrete site of origin of focal idiopathic VT. Comparable efficacy between pace mapping and activation mapping has been demonstrated.[264] Subtle variations in QRS morphology of ventricular arrhythmia can be observed, which may represent a wider endocardial "breakthrough" with the arrhythmia focus located deeper in the myocardium or in the epicardial layer.[108,265] RF energy delivery, however, is associated with a high long-term success rate (90–95%).[266-269] In cases where the target VT or PVCs are infrequently induced, the use of multielectrode or basket catheters can be of value.[268,270] In patients who had previously failed ablations, the use of electroanatomic mapping systems, either nonfluoroscopic or noncontact systems, may provide potential benefits in facilitating the procedure and attaining a high acute success rate.[98,109,270-271]

Other variants of outflow tract VT include ventricular arrhythmias arising from the aortic cusps, pulmonary artery, and epicardial foci remote from the sinus of Valsalva. Limited electropharmacologic data are available for these arrhythmias. The potential for acute coronary artery occlusion is a major risk consideration with catheter manipulation within the *aortic cusps*. Coronary angiography or intracardiac ultrasound imaging has been used to define the anatomy (Fig. 6). RF energy can be safely delivered in the aortic cusp and is associated with a long-term efficacy (~90%) in eliminating aortic cusp VTs.[44,272,273] The presence of double, delayed potentials during sinus rhythm may be predictive of the site of successful ablation.[15]

The idiopathic *epicardial VTs* commonly have an LBBB pattern because the arrhythmia foci are located along the interventricular veins near the septum, although right bundle branch block QRS morphology can be observed.[46,140] The ventricular activation is usually slow with a slurred QRS onset that resembles a delta wave. The interval from the onset of the QRS to the earliest maximal deflection in the precordial leads is also prolonged, consistent with a delayed access of the activation wave front to the endocardial Purkinje system.[46,58] Epicardial mapping and ablation via the epicardial vein with coronary sinus cannulation, or direct access with percutaneous pericardial catheterization can be successfully performed.[274]

The *pulmonary artery VTs* appear to arise from remnants of muscular sleeves that extend into the pulmonary arterial trunk.[58,274] This is supported by the presence of a sharp local potential that precedes the onset of ventricular activation during VT at the site of successful ablation.[12,275,276] During sinus rhythm, an atrial potential is frequently recorded (>58%) along with a diminished, low-amplitude local ventricular potential at the successful ablation site.

Despite careful mapping and use of sophisticated techniques, identifying the precise location of arrhythmias in outflow tract VT may be difficult because of the complex anatomic relationship and the proximity of various structures from the venous and arterial circulations. In addition to electroanatomic mapping, the use of intracardiac or transesophageal ultrasound to identify anatomic landmarks and catheter contact may facilitate ablation of idiopathic outflow tract VT.[277]

A stepwise systematic approach, from endocardial mapping and then epicardial mapping up to 6 anatomic accesses (RVOT, LVOT, coronary sinus, aortic cusp, pulmonary artery, and LV epicardium) can lead to successful RF catheter ablation.[278]

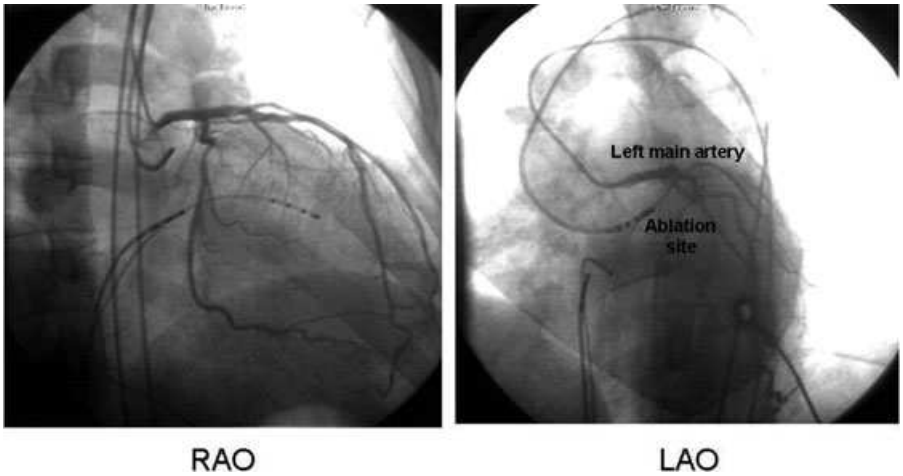

Figure 6. *Mapping and ablation of idiopathic ventricular tachycardia originating from the left aortic cusp. Fluoroscopic images of the ablation catheter located at the aortic cusp in right anterior oblique and left anterior oblique views. Simultaneous coronary angiography is performed to visualize the left main artery to assess its distance from the ablation site.*

Annular VT

Idiopathic ventricular arrhythmias can also arise in proximity to the valvular annuli. Focal VT from the *mitral annulus* accounted for 5% of the idiopathic VT in one series.[279] The arrhythmia typically has a right bundle branch block morphology and may originate from different portions of the mitral annulus (anterolateral, posterior, posteroseptal), resulting in different QRS axis.[52] Idiopathic ventricular arrhythmias originating from *tricuspid annulus* have also been described recently.[51] The predominant (74%) site of origin is located at the septal portion of the tricuspid annulus with the remaining arrhythmias arising from the annular-free wall. The detailed origin can be determined by ECG analysis. Repetitive monomorphic right VT originating *near the His bundle* may be recognized as a specific entity with distinctive ECG characteristics.[280] Recognition of this arrhythmia is important because of its unique location and the potential risk associated with catheter ablation. Knowledge of the characteristic QRS morphology will facilitate catheter mapping and successful ablation. The use of a supporting sheath to assure catheter stability, careful RF energy power/temperature titration, and cryoablation may improve the outcome and minimize complication.[280,281]

Verapamil-Sensitive Fascicular VT

This form of VT has a right bundle branch block with left axis deviation, can be induced with atrial pacing, occurs in patients without structural heart disease and is verapamil sensitive.[281–283] The mechanism is reentry within the Purkinje fibers of the left ventricular septum, most often arising from the *left posterior fascicle*.[92,93,262,284] Less often, the reentry is located in fibers distal to the *anterior fascicle* or may arise from fascicular locations high in the septum and has a relatively narrow right bundle branch block pattern and right inferior axis deviation[285] Fascicular tachycardia usually presents in patients between 15 and 40 years of age. Although ILVT can occur at rest, it is sensitive to catecholamines and often occurs during exercise, postexercise, or emotional distress. RF catheter ablation can be performed successfully (>80%) from the VT exit site (at the site of earliest ventricular activation), or the zone of slow conduction where a *Purkinje potential* was recorded in diastole during VT.[286] Critical sites of the reentrant circuit can also be identified by the earliest retrograde Purkinje network activation during sinus rhythm.[93] For patients with noninducible or nonsustained fascicular VT, a linear ablation strategy (mean 1.7 cm) perpendicular to the long axis of the ventricle, targeting the midinferior septum marked by the presence of Purkinje potentials in sinus rhythm and the best pace-map match of the VT, has been shown to be safe and effective for VT control.[286]

Idiopathic VF

Recent work has demonstrated that the *Purkinje network* is critical in the triggering and maintenance of VF in animal experiments and patients.[244,287,288] Catheter ablation targeting the PVC or Purkinje potentials responsible for triggering VF or both has been shown to be both possible and efficacious in a number of conditions, ranging from the Brugada syndrome, ischemic VF, to idiopathic VF. In order to map and then ablate VF, it is essential that there is accurate documentation of the triggering PVC with a 12-lead ECG. Due to the unpredictable nature of triggering beats, the optimal time for ablation is often in occasion of an electrical storm when the PVC tends to be frequent. The source of triggers is localized by the *earliest electrogram* relative to the onset of the ectopic QRS complex. An *initial sharp potential* (<10 ms in duration) preceding the ventricular electrogram during sinus rhythm as well as during PVC indicates the latter originates from the Purkinje system, whereas its absence at the site of earliest activation indicates an origin from ventricular muscle. Great care should be taken to avoid mechanical bumping of the right bundle branch while mapping as this would mask ipsilateral Purkinje activation during sinus rhythm.

Myocardial ectopics triggering VF

RVOT is the most common site of origin of myocardial ectopics triggering malignant monomorphic or polymorphic VT that rapidly degenerates into VF in structurally normal hearts.[289] The type of ablation is essentially no different to ablation of idiopathic RVOT ectopy or VT with a discrete and usually solitary focus located in a well-defined anatomic region. The coupling interval is significantly longer for ectopics of an RVOT origin compared with short-coupled Purkinje origin (mean coupling interval of 300 ms). Furthermore, the number of ectopics to guide mapping is usually very high in contrast to the capricious occurrence of ectopics in other patients with idiopathic VF.

Purkinje-triggered idiopathic VF

Anatomically, the Purkinje system is a small fraction of the myocardial mass, consisting of specialized fibers insulated from the underlying ventricular myocardium until their peripheral arborization into muscle. Narrow PVCs are certainly strong ECG markers that can be used to noninvasively identify Purkinje origin. PVC with a positive morphology in V1 indicates left ventricular origin and PVC with negative morphology in V1 indicates right ventricular origin.

Endocardial mapping and ablation

The use of polygraph system at high sampling rate (>2 kHz) and high gain amplification (commonly 1 mm = 0.1 mV) is optimal in order to clearly identify Purkinje potentials. The Purkinje sources are localized to a limited part of the anterior right ventricle or in a wider region of the lower half of the septum in the left ventricle[244] Recording of stable Purkinje activity is more difficult in the right ventricle. During PVC, the earliest Purkinje potential precedes the local muscle activation by a conduction interval of 38 ± 28 ms, with a greater precocity in the left than in the right ventricle (46 ± 29 vs 19 ± 10 ms).[244] At the same site, differing conduction times are associated with varying morphologies suggesting either changes in ventricular activation route or origin from another part of Purkinje system. During sinus rhythm, however, the Purkinje potential closely precedes the ventricular muscle activity by 11 ± 5 ms indicating distal arborization.[244] Ablation of Purkinje beats frequently produces temporary exacerbation of arrhythmia (including VF) followed by a disappearance of PVC. Different morphologies are progressively eliminated by ablation at multiple sites with early Purkinje potential, using a mean of 9 ± 5 (range 2 to 19) RF applications.[244] Local electrograms show the abolition of the local Purkinje potential and slight delay in the occurrence of the local ventricular electrogram.

There have been a multicenter study and a number of case reports of successful VF ablation for patients with idiopathic VF.[244,246,247,249,290,291]

Acute and Periprocedural Complications

In idiopathic VT, serious complications range from 0% to 4%.[11,176,263,280,292-294] Death was reported in one case as following right ventricular perforation.[267] In patients with VT associated with structural heart disease, catheter ablation appears associated with a greater risk of complications. In 2 large multicenter studies, major procedural complications ranged from 3.8% to 8%.[77,188] Death was reported in 2.7% of cases.[77]

Thromboembolic Events

The rate of thromboembolic events is 2.8% for the ablation of ventricular arrhythmias.[188,295,296] The higher incidence of thromboembolic events in the VT patients, compared with patients with supraventricular arrhythmias, might be related to the site of ablation (frequently the left ventricle), longer procedure time, multiple RF current applications, preexisting atherosclerotic aortic disease, and the possibility of preexisting thrombus that was not detected by transthoracic echocardiography. To minimize the occurrence of thromboembolic complications, aspirin is prescribed (81 mg to 325 mg) just before the procedure and an optimal dose of heparin infused for systemic *anticoagulation* (see above, pre- and intraablation patient management). For patients with VT of epicardial origin, heparin is started after pericardial puncture. After ablation, prolonged anticoagulation may be required in some patients, as thromboembolic complications can occur even 3 months after ablation.[297,298] Second, it is important to monitor the *change in the impedance* of the ablation catheter during delivery of RF energy. A sudden increase in the impedance of more than 20 ohms is associated with coagulum formation. Transthoracic *echocardiography* and transesophageal echocardiography should be used for routine screening of mural thrombus in the cardiac chamber, especially for ischemic VT with left ventricular dysfunction. For patients with severe atherosclerotic aortic disease, catheter access via *transseptal approach* should be considered to avoid thromboembolic complications. To make large transmural lesions without unfavorable heating injury and thromboembolic complications, a *cooled RF ablation catheter* is preferable.

Perforation and Tamponade

Incidence of cardiac tamponade or hemopericardium requiring immediate drainage is 0.4–2.7%[77,83] in catheter ablation for VT. The complication can develop during transseptal puncture, catheter manipulation, or ablation. Perforation of the left ventricle by the ablation catheter is uncommon because the left ventricle is thicker; however, the thin-walled right ventricle (particularly near the apex) may be more vulnerable to perforation by an ablation or pacing catheter. For prevention of right ventricle perforation, a *power setting* not exceeding 40 W and careful *monitoring of the impedance* are required. While percutaneous drainage of the hemorrhagic effusion is usually sufficient, spontaneous closure of the perforation may not occur, and subsequent surgical intervention may be required. During urgent pericardiocentesis, retransfusion of aspirated blood has the risk of systemic inflammatory response.

Valvular Complications

The incidence of valvular injury is reported to be 1.9% and is often minor.[299] Damage to the *mitral valve* can result from inadvertent manipulation across the valve or from an injury to the papillary muscles or chorda tendinae during or after ablation of VT. In patients with VT originated from aortic cusp, damage to the *aortic valve* could occur. To avoid these valvular complications, it is important to make sure there is *no entrapment* of the ablation catheter in these structures and to watch the *change in impedance* during RF delivery.

Condution System Complications

The rate of AV block or newly developed bundle branch block after VT ablation is known to be less than 1–2%.[77,300] For patients with preexisting LBBB and bundle branch reentry tachycardia, ablation of right bundle may cause complete AV block (0% to 30%);[301-304] however, a compensating conduction may occur through the left bundle, suggesting that right bundle ablation may be safe in the majority of patients with baseline LBBB. Ablation of the left bundle has been proposed as ideal, but this technique is difficult to perform and usually requires application of multiple lesions. For ablation of left posterior fascicular VT, ablation of the apical

third of the inferior septum is preferred to avoid producing an LBBB or AV block.

Worsened Heart Failure or Left Ventricular Function

In patients with significant heart disease, ablation of VT can involve multiple applications and long lines of RF lesions in already deteriorated left ventricular function. Unfortunately, few data are available to this regard. In a small series, Marchlinski *et al*. reported that none of their 6 patients in whom left ventricular EF was measured before (mean 24 ± 6%) and after (mean 23 ± 9%) ablation suffered deterioration greater than 5%.[113] In another series of 62 patients, Khan *et al*. reported that multiple RF ablation lesions confined to infarct regions did not measurably affect LV function.[305]

Coronary Artery Injury and Complications

Thermal injury to the coronary arteries has been described during the ablation of VT.[306] Coronary artery stenosis has been found to be a late consequence (12–24 months) of vessel trauma or vasospasm. As the use of catheter ablation is increasing, especially in children and young adults, a detailed understanding of coronary artery anatomy is critical for safe ablation. Coronary angiography or *ICE* may be considered when ablation sites are in the high-septal aspect of the RVOT[177] or in the aortic cusps. When the distance between the coronary arteries and the ablation sites is found to be less than 5 mm, *cryoablation* or *4-mm tip catheters* may be considered, in order to avoid short- and long-term damage to the coronary arteries. The safety and efficacy of epicardial RF ablation, especially in the vicinity of the coronary artery, remain unclear. In order to avoid coronary artery injury, *coronary angiography* is usually performed to visualize the relationship between RF target sites. This approach, however, requires frequent coronary contrast injections in different projections. Recently, some authors have suggested a different approach based on the fusion of CT and endocardial and epicardial electroanatomical mapping data to improve visualization of the catheter tip in relation to the epicardial coronary arteries.[307]

Vascular Access Complications

Aortic atheroembolism

The formation of multiple *cholesterol emboli* is a rare but serious complication. It is caused by cholesterol crystals that embolize and block small arteries. No specific treatment is available, and morbidity and mortality are high. It tends to be associated with difficulty in manipulation of catheters within a severely diseased aorta. A common feature is leg pain with livido reticularis despite palpable pulses. Confusion, renal failure, and death ultimately ensue.[308] In patients with severe aorta disease, it might be reasonable to use a *long vascular sheath* to advance the ablation catheter directly into the left ventricle. Alternatively, a *transseptal approach* could be considered.

Pseudoaneurysm, local hematoma, and arterovenous fistula

All interventional procedures carry a risk of local vascular complications, such as pseudoaneurysm, hematoma, and arterovenous fistula. The incidence of these complications is particularly related to the type of procedure performed (right- or left-side catheterization). In the Multicentre European Radiofrequency Survey (MERFS), the incidence of *major bleeding* at the puncture site ranged between 0.23% and 0.63%.[296] Van Hare *et al*. reported a 4% incidence of *hematoma*.[309] Kelm *et al*. found that almost 1% suffered femoral *arterovenous fistula*.[310] One-third of iatrogenic arterovenous fistula closes spontaneously within 1 year. Cardiac volume overload and limb damage are highly unlikely with arterovenous fistula persistence. Thus, conservative management for at least 1 year seems to be justified.[310] *Femoral pseudoaneurysm* is a common complication, and occurs in up to 6% of diagnostic or therapeutic catheterization procedures. Spontaneous closure is the rule for small pseudoaneurysms. Large and complex pseudoaneurysms need treatment to prevent complications, such as embolization.[311] Manual compression repair, with or without ultrasound guidance, remains first-line treatment. A surgical approach is indicated in selected cases. New therapies have recently emerged that are noninvasive and suitable for most patients, even those who are critically ill. Nonsurgical treatment options in addition to compression therapy include endoprosthesis placement, coil embolization, and percutaneous collagen and thrombin injection. The prophylactic use of anticoagulation therapy after the ablation procedure could increase the risk of developing vascular complications. Another important risk factor for this complication is the size of the sheaths used to introduce the catheters into the vessel.

Complications Associated with Epicardial Mapping/Ablation

Access

Compared with endocardial approach, epicardial ablation has some additional risks. Some degree of *pericardial bleeding* is recognized in approximately 30% of cases,[312] mostly due to the unintentional right ventricular puncture or lesion of pericardial vessels. Bleeding usually resolves with repeated aspiration of the pericardial space,[313] and rarely requires surgical intervention.[133] To prevent the laceration, the sheath should never be left without a catheter inside. Puncture of a subdiaphragmatic vessel causing intraabdominal bleeding has been reported and can potentially require surgery.[237,312] Anterior access may have less risk of intraabdominal bleeding, including liver puncture, compared with the inferior access.

Mapping/ablation

RF *injury to coronary arteries* can cause acute thrombosis.[237] In addition, severe coronary artery spasm has been reported during epicardial mapping.[139] The long-term consequences (beyond 1–3 months) of ablation near the coronary arteries are unknown. *Injury of the left phrenic nerve* has been reported.[314] Proximity to the nerve can be detected by pacing with high stimulus strength.[35] To prevent the phrenic nerve damage, moving the nerve away from the myocardium by injection of air into the pericardium, or placement of a balloon catheter between the ablation site and nerve has been reported.[315,316]

Postprocedure

Symptoms of *pericarditis* can be observed in about 30% of cases after the procedure.[237] Pericardial instillation of a

glucocorticoid following the procedure has been shown to reduce inflammation,[317] and is performed routinely in some centers.

Post-VT Ablation Follow-Up Management

Follow-up and postablation management of patients after catheter ablation for VT is largely determined by the type of VT being ablated. For patients with structurally normal hearts and idiopathic VT, follow-up can be straightforward and similar to the follow-up after an ablation procedure for a supraventricular tachycardia. However, in patients with structural heart disease, follow-up management can be complex and depends on the nature of the underlying disease. In addition to proper surveillance for procedural complications and outcome, management also includes the possibility of ongoing antiarrhythmic drug therapy and optimization of medical therapy to control the underlying heart disease. At present, there are no guidelines or a widely accepted consensus statement for the postablation management of VT patients. Follow-up management should focus on: (1) understanding and improving long-term prognosis and (2) medical therapy and ongoing monitoring.

Prognosis Post-VT Ablation

Knowledge of the prognosis post-VT ablation is important to understand the postablation management priorities for these patients. In case of idiopathic VT without detectable structural heart disease, such as VT arising from the RVOT, aortic cusp, or left ventricular fascicles, the long-term prognosis is in general excellent, with or without arrhythmia elimination.[269] Catheter ablation is primarily performed to limit symptoms and to improve quality of life, with low long-term morbidity or mortality risk. In patients with structural heart disease, long-term prognosis is often worse compared with the patients without detectable structural heart disease. Because of the progressive nature of most cardiomyopathies, recurrence of (non) ablated VT and/or death from nonarrhythmic cardiac causes (such as pump failure) become more prevalent over time. After VT ablation in patients with structural heart disease, the arrhythmic outcome over 1–5 years follow-up seems to be directly correlated to the degree of *acute procedural success*.[74,77-83,191] Acute outcomes may be defined as "total," or "partial success," or "failure." Unfortunately, the literature has used varying definitions of "clinical VT" (especially when 12-lead documentation was not available) and varying stimulation protocols (3–5 extrastimuli), stressing the necessity to standardize definitions of success.[318] However, regardless the definitions used, studies have reported the best results in "total" success patients with *VT recurrence* rates as low as 4–16% over 1–2 years' follow-up. "Partial" success patients have an intermediate recurrence rate of 40–65%, while "failures" have recurrence rates in excess of 90–99%.[79,83,191] The *mortality* rate in VT patients with structural heart disease is also substantial with reported 1-year mortality rates to be 16–18% with 70–75% of those deaths attributable to a cardiac cause.[83,191] Importantly, 53–65% of these cardiac deaths are due to a nonarrhythmic cause, indicating the importance of optimizing management of the underlying heart disease. Interestingly, the rate of death from nonarrhythmic cause is also directly related to acute procedural success, with the highest mortality rates in patients where VT could not be successfully or totally eliminated.[83] Finally, the occurrence of an electrical storm (one of the most common reasons for VT ablation) is a strong predictor of increased long-term mortality (about 25–30% over 2 years).[319]

Medical Therapy Post-VT Ablation

For patients with *idiopathic VT* and no detectable structural heart disease, medical management is similar to that for reentrant supraventricular tachycardia. Since elimination of all medication is often the goal of ablative therapy in this population, immediate discontinuation of drugs postablation is the best strategy to allow for monitoring of recurrence. In patients with a VT recurrence, the decision to pursue repeat ablation, or restart medication will be an individualized decision. Antiplatelet therapy with aspirin 80–325 mg/day for 4–6 weeks postablation can be considered for idiopathic VT patients who have had left-sided ablations or extensive ablation lesions to minimize the risk of thrombus, although there is little evidence that is a clinically relevant problem or that such therapy would prevent it. In VT ablation *patients with structural heart disease*, medical therapy can be subdivided into 4 major headings: antiarrhythmics, anticoagulation, beta-blockade, and heart failure management.

Antiarrhythmics

Antiarrhythmic drug therapy is often continued in most patients' post-VT ablation. In 2 recent reports, 70–90% of patients were maintained on their preablation antiarrhythmic drug therapy, with only about 25–30% of these patients having their doses reduced.[79,82,83,191] In contrast to the atrial fibrillation population, freedom from antiarrhythmic drugs may not be a reasonable goal given the complexity and progressive nature of the VT substrate. Even after apparently successful procedures, recurrence rates within 2 years are as high as 10–15%.[74,83,191] Furthermore, many of these patients are taking on antiarrhythmics for concomitant reasons (such as AF) and, thus, total elimination may not be feasible. Dose reduction may be an important goal, particularly for amiodarone for which the incidence of side effects is closely related to daily dose.[320] In various trials, dose reduction of amiodarone is reported and doses may be reduced in a progressive manner starting within the first 3–6 months postablation.[191] There are, of course, some patients where ablation is pursued as an alternative to antiarrhythmics, particularly where drugs may be causing unacceptable side effects. In these patients, drugs may be discontinued postablation, probably after a minimum of 3 months follow-up to assess clinical outcome.

Anticoagulation

Within the first 3 months postablation, particularly on the left side, there may be a risk of systemic thromboembolism, particularly if extensive ablation lesions were applied. However, there is no absolute proof of this, since only 2 TIAs were reported out of 390 patients (0.5%) accumulated from 3 recent, large-scale reports[83,182,191] using antiplatelet or no anticoagulant therapy only. Furthermore, most VT patients with structural heart disease are already receiving some form of antithrombotic or anticoagulant therapy, such as antiplatelet therapy in the coronary disease patients, or warfarin for patients with DCM and/or atrial fibrillation. Based on consensus opinion, and on postablation procedures from

published data, it is recommended that a minimum of *aspirin* 80–325 mg/day be used for 3 months postablation in patients who have had left-sided or extensive ablations. *Warfarin* may be used for higher risk patients (documented thrombus, previous stroke/TIA, atrial fibrillation, severe left ventricular dysfunction, etc.). Surveillance with echocardiography for thrombus is discussed later.

Beta-blockade

Beta-blockers should be maximized in most patients post-VT ablation with structural heart disease. Effective beta-blockade has been shown to reduce both arrhythmic and nonarrhythmic death in patients with left ventricular dysfunction.[321] Furthermore, concomitant use of beta-blockers with other antiarrhythmic agents is superior to the use of either agent in isolation, as shown by the OPTIC trial.[322] Even in patients receiving low-dose sotalol, there is not much beta-blocker effect in doses of 80 mg BID or less. Thus, addition of a traditional beta-blocker in combination with low-dose sotalol may be useful.

Other heart failure therapy

Many VT ablation patients have coexisting cardiomyopathy and, given the high rate of death from heart failure over the first 1–5 years postablation (see above), appropriate long-term heart function management must be optimized. Keep in mind that therapy shown to reduce mortality in HF patients, including statins and fish oil,[323-326] should be used whenever possible. Acutely, attention must be paid to volume status, particularly since patients are lying flat for prolonged periods, and often, an open-irrigated tip ablation catheter is used that can add 1–2 L of volume acutely to the patient. Significant volume overload requiring prolonged admission can occur in as many as 1–2% of patients post-VT ablation. Thus, *diuretic* doses may need to be increased in the days postablation to achieve a baseline fluid status. *Electrolytes* should also be closely monitored and corrected in the first few days.

Monitoring Post-VT Ablation

For patients with *idiopathic VT* and no structural heart disease, ablation is usually undertaken for symptomatic arrhythmias. Following a successful ablation procedure, patients should be seen at the outpatient clinic at regular intervals up to 1 year following the initial procedure. Follow-up should include 24–48-hour *Holter monitoring* at regular intervals. For patients with little or no symptoms or patients with infrequent arrhythmia episodes prior to ablation, prolonged monitoring with *loop recorders,* or *transtelephonic monitoring* should be considered. *Exercise stress testing* may be useful for patients with a history of exercise-induced VT's. *Echo monitoring* at regular intervals to assess LV/RV function should be considered in postablation patients with a history of suspected PVC-induced cardiomyopathy. After an unsuccessful ablation procedure it is advised to wait at least 3 months before scheduling a repeat ablation procedure in order to assess the burden of recurrent arrhythmias. In VT ablation *patients with structural heart disease*, monitoring recommendations may be grouped as follows:

ICD

Most patients with structural heart disease and VT undergoing ablation either already have an ICD or will get an ICD implanted after the procedure. If an ICD is present, *ICD functions* should be checked immediately and 3 months after ablation to detect any device-lead malfunctions, such as lead dislodgement/damage, change in sensing or pacing thresholds, or device infection. Thereafter ICDs should be checked every 3–6 months. Given the monitoring capabilities of ICDs, they are ideal to *monitor arrhythmia recurrences*. However, documentation of every PVC or nonsustained VT episode may not be clinically useful or relevant. The suggestion from the United States Food and Drug Administration (FDA) in 1999 was to document only those VTs requiring therapy (antitachycardia pacing or shock) or nonsustained VT episodes lasting >20 seconds as clinically relevant.[327] The FDA guidelines suggested a minimum of 6 months follow-up post-VT ablation for clinical trials, but a minimum of 1 year seems reasonable. Postablation *programming* should be performed as per emerging guidelines to minimize ICD shock delivery, such as using higher cutoff rates for VT and VF zones, extending detection limits, and aggressive use of antitachycardia pacing even for faster VTs. Monitor zones at lower rates may be programmed to look for slower VTs that may have been targeted during ablation, but do not necessarily warrant shock therapy.

Other rhythm monitoring

For ICD patients, other forms of rhythm monitoring are probably not warranted beyond standard ECGs acquired at each clinical visit. For patients without ICDs, *intermittent ECG* and 24–48-hour *Holter monitoring* should supplement symptom monitoring, with each clinical visit at 3 and 6 months and every 6 months thereafter. Loop recorders and/or transtelephonic monitoring may increase the yield of asymptomatic VT detection, as suggested by the atrial fibrillation literature, but whether such VT would be clinically relevant or not in this population is not well known.

Echoardiography

At a minimum, echo should be performed within 24–48 hours preablation and within 1-week postablation to look for thrombus or deterioration in ventricular function. Repeat echo should be considered at 3 months postablation for those patients who have documented thrombus and have been given warfarin to study if the thrombus has resolved. The 3-month echo is also useful to document changes in ventricular function postablation. For some patients, such as those with PVC-induced cardiomyopathy, it may take at least 3 months to detect improvement in left ventricular function. Conversely, in severe cardiomyopathy patients, left ventricular function may deteriorate if extensive ablation is performed in viable tissue.

Repeat Ablation

The decision and timing of performing a repeat VT ablation will be dependent on the context and urgency of the clinical situation. If possible, in line with the FDA guidelines one should wait for at least 1 week following ablation to assess possible procedure-related complications and to study the recurrence rate.[327] However, in case of *frequent recurrences* or even an electrical storm the repeat procedure should be scheduled as soon as possible. Other indications for repeat ablation would include failure of the first procedure, ongoing delivery of ICD therapy, ongoing high burden

of ventricular arrhythmias, or inability to stop antiarrhythmic medication that is causing side effects.

Surgical Ablation

The rationale of surgery for VT is based on either ablation or exclusion of the arrhythmogenic substrate responsible for the arrhythmia.[328] Therapeutic targets of the procedure are the earliest activation site during VT and the areas of low and/or delayed and/or fractionated potentials during diastole.[329-331]

Although very effective, surgical ablation of VT is associated with significant mortality and morbidity.[332] Therefore, at present it should be considered only in selected patients, when other less invasive therapeutic interventions have failed.

Surgical Indications and Procedure

Surgery can be considered under the following conditions: (1) low-risk patient, with a discrete scar, preserved left ventricular function, and persistence of problematic monomorphic sustained VT after failed catheter ablation; (2) life-threatening electric storm after failed catheter ablation, as a life-saving procedure, but only after careful consideration of the patient's left ventricular anatomy and function and the severity of comorbidity; and (3) after attempted catheter ablation, when there is good evidence that the arrhythmogenic targets are epicardial and there is contraindication or difficulty to the transthoracic percutaneous access.

Patient should have an extensive preoperative work-up with, in particular, an electrophysiologic study to document the number, site of origin of various VT morphologies, low-amplitude mapping to delineate the area of scar tissue with special attention to areas outside the main endocardial scar, as well as attempts of an RF catheter ablation. The surgical team must comprise a well-experienced group of experts in surgery and electrophysiology ready to demonstrate an excellent teamwork. Intraoperative electrophysiologic study should include all sophisticated mapping, catheter and surgical techniques. Before entering the left ventricular aneurysm, comprehensive epicardial mapping should be performed to identify early epicardial breakthroughs during tachycardia. Ablation should be guided by electrophysiological mapping during sinus rhythm and VT, as well as by cardiac pathology. All areas of endocardial fibrosis should be ablated or excluded. The surgery can be performed on the arrested heart or beating heart. Closure of the LV can use LV remodeling techniques, with which the surgeon is comfortable.

Indications to VT/VF Ablation and Hybrid Therapy

The indications for catheter ablation in general, and for VT/VF ablation in particular, have evolved rapidly since the first application in humans with ongoing improvement of technology and increase in experience. However, as with other technology-based approaches, progress is rapid, which, among other reasons, has prevented the performance of large randomized multicenter clinical trials with long recruitment periods during which technology usually will have changed. Therefore, almost all indications even when considered as strong (class I and II a) have a low level of evidence.

Indications for Ablation of Idiopathic Right Venticle/Left Ventricle VT/VF

RVOT/LVOT VT

These arrhythmias are typically benign and rarely cause SD. The success rate for ablating RVOT/LVOT VT is high, from greater than 80% to 95%.[278,280,289,333,334] However, long-term late recurrences have been reported to be relatively common.[294] Of note, with more recent sophisticated mapping and ablation approaches, the serious complication of cardiac perforation and tamponade during ablation in this area has been reported to be $<1\%$.

VT originating from the aortic sinus of Valsalva

The origin of these unusual forms of VT is most frequently from the left coronary cusp but can also be found in the right coronary cusp and the noncoronary cusp.[272,335] Ablation success rates from very experienced laboratories have been high, greater than 80%, with minimal complications. However, a dire consequence can be acute occlusion of the coronary artery, which has been reported.

Fascicular left VT

Verapamil-sensitive idiopathic left VT occurs primarily due to reentry involving the fascicles of the left bundle branch.[42,103,336] RF ablation is highly effective ($>80\%$) and should be considered in patients in whom medical therapy is unsuccessful or poorly tolerated.

Other idiopathic VT

Ablation has been attempted with success also in other forms of idiopathic VT, such as mitral and tricuspidal annular VT, VT originating from pulmonary artery or PAP, and epicardial VT.[46,51,52,274,275,278,279,337] However, the ablation in these particular sites may bring a higher risk of complications.

Idiopathic VF

Catheter ablation has been also proposed in selected patients with idiopathic VF, whose arrhythmia is consistently triggered by PVC originating from Purkinje fibers.[338,339] However, long-term results from larger clinical trials are required before this indication becomes routine recommendation in clinical practice.

Recommendations

The indications of ablation for idiopathic right ventricle/left ventricle VT/VF are summarized in Table 3.

Indications for Ablation of Nonischemic VT/VF

In general, VT and VF complicating nonischemic structural heart disease are treated with ICD. Catheter ablation is considered *adjunctive or palliative* therapy most of the time. Catheter ablation is recommended for patients with an ICD who are receiving multiple shocks as a result of sustained VT/VF that is not manageable by reprogramming or optimization of drug therapy. In patients with bundle branch reentry VT, catheter ablation may be considered as standard therapy. In patients at low risk of SD and sustained monomorphic VT, catheter ablation is also recommended when drug therapy is not effective, not tolerated, or not preferred. In

TABLE 3

Indications of Ablation for Idiopathic Right Ventricle/Left Ventricle VT

Class I:
1. Symptomatic VT/PVC of right ventricular origin unresponsive to medical therapy with beta-blockers and calcium channel-blockers
2. Symptomatic VT/PVC of left ventricular fascicular or endocardial origin remote from aortic sinus of Valsalva, unresponsive to medical therapy with beta-blockers and calcium channel-blockers
3. Symptomatic or asymptomatic VT/PVC of right ventricular or left ventricular origin thought to be causing cardiomyopathy and unresponsive to medical therapy

Class II a:
1. Asymptomatic sustained VT of right ventricular origin unresponsive to medical therapy

Class II b:
1. Symptomatic VT/PVC originating from uncommon left ventricular sites (aortic sinus of Valsalva, epicardium) that are unresponsive to medical therapy including class I/III agents
2. Asymptomatic sustained VT of left ventricular origin unresponsive to medical therapy

Class III:
1. Asymptomatic PVC of right or left ventricular origin not thought to be causing cardiomyopathy

PVC = premature ventricular contractions; VT = ventricular tachycardia.

TABLE 4

Indications of Ablation for Nonischemic VT and VF

Class I:
1. Sustained monomorphic VT in patients at low risk of sudden death when drug therapy is not effective, not tolerated, or not preferred (level of evidence C)
2. Bundle branch reentrant VT (level of evidence C)
3. Adjunctive treatment for VT storm in patients with an ICD (level of evidence C)
4. Accessory pathway ablation in VF caused by preexcited AF in WPW syndrome (level of evidence B)

Class II a:
1. Symptomatic nonsustained VT in patients at low risk of sudden death when drug therapy is not effective, not tolerated, or not preferred (level of evidence C)
2. Frequent symptomatic PVC in patients at low risk of sudden death when drug therapy is not effective, not tolerated, or not preferred (level of evidence C)
3. Ablation of accessory pathway to prevent VF in symptomatic patients with WPW syndrome in whom the refractory period of the accessory pathway is less than 240 ms (level of evidence B)

Class II b:
1. Ablation of Purkinje fiber potentials in VT/VF storm consistently triggered by ectopics of a similar morphology (level of evidence C)
2. Ablation of asymptomatic PVC to avoid or treat tachycardia-induced cardiomyopathy (level of evidence C)

Class III:
1. Ablation of asymptomatic and infrequent PVC is not indicated (level of evidence C)

AF = atrial fibrillation; PVC = premature ventricular contractions; VF = ventricular fibrillation; VT = ventricular tachycardia; WPW = Wolff-Parkinson-White.

patients at low risk of SD and symptomatic nonsustained monomorphic VT, catheter ablation may be useful as an alternate to medical treatment. The role of prophylactic ablation of VT/VF for prevention of ICD therapy in nonischemic VT/VF has not been assessed yet.

Considerations regarding the different etiologies responsible for nonischemic VT/VF

In idiopathic DCM and Chagas' disease, the origin of the arrhythmia is often epicardial (in more than 25–30% of cases);[35,193] this may complicate the procedure, since an epicardial approach is frequently required with all the risks that it brings. In patients with ARVC, the role of catheter ablation is questionable as primary treatment strategy, in view of the diffuse and progressive character of the disease.[212] This appears to be also the case in Chagas' disease. In cardiac sarcoidosis, catheter ablation is likely to improve prognosis only in patients with still-preserved left ventricular function.[38,238] In HCM, the role of catheter ablation is usually limited, with the only exception of patients with an apical aneurysm.[339] In patients with Wolff-Parkinson-White syndrome, catheter ablation of the accessory pathway is clearly indicated in cases of atrial fibrillation with rapid preexcited ventricular response causing VF, or in cases with very short (<240 ms) refractory period of the accessory pathway with preexcited atrial fibrillation. Catheter ablation has been also used with success in selected patients with or without structural heart disease and with VF triggered by ventricular ectopics or Purkinje potentials.[94,95,244,249,251,255,256,258,340]

Recommendations

The indications of ablation in nonischemic VT and VF as recommended by ACC/AHA/ESC are summarized in Table 4.[21]

Indications for Ablation of Ischemic VT/VF

Catheter ablation of ischemic VT/VF is not recommended as primary or sole treatment. It is generally indicated as an *adjunctive therapy* in postinfarction patients with ICD who experience frequent recurrences of ventricular arrhythmias or electrical storm, without any apparent correctable cause and despite adequate medical treatment. This is not a rare event in clinical practice. Of patients who receive an ICD for secondary prevention of SD, 40–60% experience recurrent episodes of VT/VF.[341] Electrical storm occurs in up to 20% of cases.[342] In addition, of patients who receive an ICD for primary prevention of SD, 20% experience at least 1 VT episode within 3–5 years after ICD implantation.[343] Catheter ablation is able to abolish VT and has a high acute success rate in eliminating the dominant type of VT. Accumulated evidence suggests that acute suppression of clinical VT in electrical storm can be achieved in approximately 90% of patients.[191] However, arrhythmic recurrences are frequent during follow-up. Other indications to ablation of VT/VF in postinfarction patients are listed in Table 5. Recently, it has been reported that triggering foci originating from the Purkinje system may be the cause of VF occurring early or late after myocardial infarction. The ablation of these foci has been proposed as life-saving procedure in subjects with electrical storm due to VF clearly caused by PVC.[96,250]

Recommendations

The indications of ablation for ischemic VT, in accordance with the ACC/AHA/ESC 2006 guidelines for management of patients with ventricular arrhythmias and the prevention of SD[7] are summarized in Table 5.

TABLE 5
Indications of Ablation for Ischemic VT

Class I:
1. Patients after myocardial infarction with an ICD who present with repetitive monomorphic VT that leads to multiple shocks or who present with drug-refractory incessant VT or "electrical storms" that cannot be avoided despite adequate reprogramming of the antitachycardia pacing mode and that cannot be prevented by beta-blocker and/or antiarrhythmic drug therapy or when patients are intolerant of these drugs (level C)
2. Patients after myocardial infarction with an ICD who present with repetitive sustained VT, which made mandatory the therapy with antiarrhythmic drugs that decreased the rate of VT below an acceptable intervention rate into the range of exercise-induced sinus rhythm despite concomitant beta-blocker therapy (level C)
3. Patients with bundle branch reentry after myocardial infarction (level C)

Class II a:
1. Patients after myocardial infarction with an ICD who present with infrequent monomorphic VT that have been terminated successfully by more than one electrical shock that most probably cannot be avoided in the long-term future despite adequate reprogramming of the antitachycardia pacing mode and where it is difficult to predict whether future events can be avoided by beta-blocker and/or antiarrhythmic drug therapy or when patients are not willing to take long-term drugs the efficacy of which cannot be predicted beforehand (level C)

Class II b:
1. As the sole procedure, that is, without an ICD, in patients after myocardial infarction who have relatively well-preserved LV function (above 35% to 40%) and in whom VT is monomorphic, relatively slow and well tolerated, who are considered to have a good long-term prognosis, and who are either drug resistant, do not tolerate an antiarrhythmic drug, or do not accept long-term therapy (level C)
2. Patients after myocardial infarction who present with frequent self-terminating monomorphic VT that may cause shock intervention by the ICD that potentially cannot be avoided by changing the intervention rate of the ICD (level C).
3. Patients with markedly reduced longevity and comorbidities (e.g., heart failure, reduced renal function) where VT can either not be prevented by antiarrhythmic drug therapy or drugs have not been tolerated and where an ICD would not be indicated due to the overall conditions of the patient
4. Patients with more than one intervention of the ICD by a shock that is causing severe anxiety and psychological distress

ICD = implantable cardioverter defibrillator; LV = left ventricular; VT = ventricular tachycardia.

Hybrid Therapy: Ablation and ICD

In SMASH-VT, catheter ablation reduced the incidence of ICD therapy (shocks or antitachycardia pacing) from 33% (ICD alone) to 12% (ablation plus ICD) ($P = 0.007$). Mortality was not increased in the group assigned to ablation as compared with the control group (9% vs 17%, $P = 0.29$). Therefore, ablation of VT/VF may be useful to prevent arrhythmic recurrences and device intervention in patients implanted with ICD for secondary prevention of SD.

Recommendations

Indications of a hybrid therapy consisting of ablation and ICD at present are:

Class II a

To reduce the burden of VT recurrences in patients receiving an ICD for secondary indication, catheter ablation may be considered (level C).

Future Tools and Treatment Options for Catheter Ablation of VT/VF

Image-Integration-Based Mapping

Future progress in mapping and ablation of VT/VF will require the extension of currently available tools and technologies and the development of new approaches. It is anticipated that *scar delineation* will be one of these increasingly applied techniques.[113] Classically, this has been based upon voltage mapping, but it has received renewed emphasis with the application of *electroanatomic mapping*. Obtaining an accurate 3D reconstruction of the ventricles with a precise demarcation of the scar zones is, however, time-consuming and technically difficult.

Cardiac MRI with delayed contrast enhancement analysis has emerged as the noninvasive, gold standard, diagnostic tool to analyze the topography and transmural extent of myocardial infarction.[344-346] Retention of gadolinium contrast in scar zones results in increased signal intensity on T1-weighted images relative to that of the normal myocardium. It is important, however, to recognize that delayed myocardial enhancement is not specific to myocardial infarction and can occur in a variety of other disorders, such as inflammatory or infectious diseases of the myocardium, cardiomyopathy, cardiac neoplasms, and congenital or genetic cardiac pathologic conditions. There are, however, differences in terms of scar location as well as transmural scar extent according to the underlying heart disease.[347] As a consequence, delayed contrast enhancement MRI may ultimately aid diagnosis. Finally, scar/fibrosis data on MRI have been shown to be associated with ventricular arrhythmogenicity in different cardiac pathologic conditions.[348,349]

Integration of 3D CT scan or MRI cardiac images into a 3D mapping system would be of great interest for guiding VT ablation, as already shown for supraventricular tachycardias. As compared with MRI scar definition, a recent study[350] showed that 3D electroanatomic mapping only provides a rough delineation of infarct areas. A clear mismatch in scar delineation was observed on the Carto map in one-third of the scars. Merging a preacquired MRI data set into the mapping system could also provide a precise anatomical context and may help identifying postinfarct VT circuits.

Future systems in general will not only facilitate the understanding of the underlying tachycardia substrate, but will also enhance the ability to assess lesion formation during the energy delivery in order to make the ablation itself more efficient. This will be particularly true in the much thicker ventricular myocardium, where assessment of the formation of lesions during the actual ablation will be valuable. The implementation of *remote navigation systems*[351] will require integration of mapping, recording, and imaging systems.

Future Tools and Treatment Options for Epicardial VT Ablation

Safe access of the pericardial space

Accessing the pericardial space allows that extensive areas of epicardial ventricles can be explored using standard catheters.[132,134] However, there is still concern about the safety of percutaneous pericardial puncture due to pericardial bleeding and or ventricular perforation.[132] Thus, technical development is still needed to access the pericardial space.

A specific device has been constructed aiming to aspirate the parietal pericardium in order to facilitate the introduction of a needle and a guidewire in the pericardial space.[352] Mahapatra *et al*.[353] also recently constructed a device capable of measuring the pressure-frequency components observed at the needle tip during introduction. Intracardiac approaches to accessing the pericardial space have also been proposed. Verrier *et al.* first described a percutaneous approach via the right atrial appendage.[354] Since this approach was proposed, no attempts for epicardial mapping and ablation have been performed as regular sheaths and electrophysiologic catheters are larger than used in such preliminary studies. However, developing a system that could close and stitch the right appendage after sheath withdrawal would add even more safety and confidence while performing such pericardial access.

Catheter ablation on the epicardial surface of the ventricles

Additional epicardial ablation development will take advantage of coronary artery or vein access. The coronary vessels are natural barriers for epicardial ablation. RF pulses delivered near an artery may result in intima hyperplasia and thrombosis.[139] On the other hand, ablation near large vessels, with increased arterial and venous flow, might preclude myocardial lesion development underneath the vessels that could be involved in the reentrant circuit.[355] Therefore, accessing the coronary venous system should be a good alternate in case of a perivascular VT substrate.[46,356] Direct visualization of the epicardial surface through a customized pericardial endoscope might also facilitate a safer epicardial RF delivery.[357] The epicardial fat thickness is also an important barrier to RF epicardial ablation. Cooled-tip catheters[138] and ultrasound energy create larger lesions despite the presence of fat interposed between the catheter tip and the epicardium, although there may persist the risk that a coronary artery could be occluded. Thus, more investigations are needed to safely ablate in that area. There is also an intrinsic risk for collateral tissue injury involving the phrenic nerve, parietal pericardium, pleural membrane, and lungs. Intrapericardial balloons or injection of fluid and air[315,316,358] have been used to prevent phrenic nerve injury;[315] however, a specific device should be developed to facilitate access to divergent areas of the pericardial space. Another way to prevent neighboring structure injury is through an epicardial customized thermally shielded catheter. Fenelon *et al*. compared lesion sizes obtained via regular irrigation-tip electrodes and thermally shielded electrodes in dogs. The latter thermally shielded approach promoted the same creation of similar lesion size as regular catheters, but prevented injury to the contiguous tissue.[359] In summary, many new strategies and tools are under evaluation, giving expectation that epicardial and endocardial VT mapping and ablation might be performed in combination with more reliable pericardial access, under direct visualization, and with specific catheters and sources of energy in the future.

Ultrasound and Laser Energy for Endocardial and Epicardial Catheter Ablation of VT/VF

Future tools for ablating the ventricular myocardium will undoubtedly leverage alternate energy sources. Deeper lesions are desirable for catheter ablation of VT, especially VT associated with prior myocardial infarction or ARVC. Ultrasound and laser energy may have several advantages over RF energy for endocardial and/or epicardial catheter ablation of VT.

Ultrasound energy

Ultrasound energy is only minimally absorbed by blood. Therefore, there is little or no direct heating of blood during endocardial ablation, resulting in a lower risk of thrombus than for RF energy.[361-363] Ultrasound energy decays as the inverse of distance from the source. In contrast, RF energy decays as the inverse of the square of the distance. The reduced decay allows ultrasound energy to produce a more homogeneous pattern of tissue heating with less focal hot spots in the tissue, a lower risk of steam pop, and deeper lesions (Fig. 5). Ultrasound penetration into the myocardium is dependent on frequency (higher the frequency, less the depth of penetration). Ablation using ultrasound at 20, 9, and 1 MHz would be expected to have a depth of active heating of 1–2 mm, 5–6 mm, and 25–30 mm, respectively. In a preliminary study, ablation using a 9 MHz ultrasound catheter created long (>14 mm) and deep (>8 mm) lesions without thrombus or steam pop in a canine thigh muscle preparation.[362] The advantage of ultrasound energy for percutaneous epicardial ablation is the ability to penetrate epicardial fat and no requirement for additional external cooling. The limitations for epicardial ablation are: (1) acoustic insulation may be required to prevent collateral damage to a coronary artery and phrenic nerve and (2) injection of saline into the pericardial space may be required to ensure an air-free interface between the catheter and the epicardium.

Laser energy

A major advantage of laser energy for ablation of VT is the ability to use an endoscopic fiber to allow direct visualization of the ablation target. Because the laser energy is absorbed by blood, lasing into blood may produce thrombus. This can be avoided by using a balloon filled with clear fluid, generally D_2O (heavy water), and visualizing the ablation filed through the endoscopic fiber.[363] Another advantage of endoscopic visualization is that scar and scar border can be easily seen for scar localization. Laser energy may not be well absorbed by fibrous tissue. This may result in refraction of the laser light until reaching myocardial cells for improved ablation of surviving myocardial bundles (arrhythmogenic channels) within the scar. The advantages of laser energy for percutaneous epicardial ablation are: (1) penetration of epicardial fat; (2) the ability to penetrate through air in the pericardial space; and (3) directional focus to prevent collateral damage to a coronary artery and phrenic nerve. Future ablation using new tools, such as ultrasound and laser energy sources, combined with new localization techniques, such as direct visualization using endoscopy, may improve the ease, efficacy, and safety for endocardial and epicardial catheter ablation of VT/VF.

Virtual Electrode and Cellular Ablation

A substantial amount of progress in the development of new energy technologies has been made over the past 10 years. This has enabled the creation of larger lesions that may be more effective in penetrating through underlying tissue abnormalities, such as infarct scar. Large and irrigation-tip electrodes allow tissue cooling through internal flow or

convective means, thereby fostering the delivery of higher powers with less chance of an impedance pop or scar formation. Nevertheless, these approaches remain limited in reaching circuits embedded in thick scar. As a result, *needle tip electrodes* have been developed for the delivery of both energy and higher ionic strength solutions, such as normal saline into the tissue.[364,365] The combination of this delivery results in a synergistic effect to create a larger "virtual electrode." Recent studies[364,365] have demonstrated the utility of such a system for creating large linear lesions in infarcted myocardium. In studies abating normal and abnormal infarcted myocardium, these investigators demonstrated that up to 90% of embedded tissue strands relevant for reentrant circuit in an infarct were effectively eliminated. Additional studies demonstrated the creation of contiguous linear lesions extending through the entire myocardium. Sapp *et al.*[365] have also demonstrated higher delivery of power to within tissue, providing more full thickness energy delivery than possible with standard irrigation-tip catheters. While these data provide new insight into the generation of larger lesions, additional efforts will be required to produce controllable lesions of narrower width. To date, the safety of these approaches has also been understudied. Nevertheless, in normal myocardium, recent preliminary studies show little effect on chamber volumes or left ventricular function as measured in the EF. Undoubtedly, the application of this technology would require careful targeting of infarcted areas rather than residual healthy myocardium.

Cell Therapies

Another avenue for investigation of novel treatment modalities is that of cell therapy for arrhythmias. Extensive studies detail the utility of delivery of either stem cells or bone marrow progenator cells to the enhancement of myocardial contractility.[366] The issue of whether or not these approaches serve an antiarrhythmic purpose has been less completely explored. Recently, Bunch *et al.*[367] demonstrated that autologous fibroblasts cultured from the dermis of canines could be injected into peri-AV nodal tissue to modulate conduction during atrial fibrillation in an intact canine model. While the effect was pronounced with cells alone, fibroblasts incubated with TGF Beta 1 grew to a much larger extent, resulting in greater prolongation in AV nodal conduction time, also reducing the ventricular response rate during atrial fibrillation. Others have shown similar findings in porcine models.[368] These data suggest that cell injection might critically alter conduction to reduce AV nodal transit in the setting of this arrhythmia. It has also been hypothesized that similar cellular injections would more homogenize the periphery of infarcts, perhaps leading to a decrease in infarct-related ventricular arrhythmias.[369]

Whether or not cellular injection might have a beneficial effect on impulse formation or propagation is at present unknown. A variety of studies have now demonstrated the possibility of the creation of automatic tissue capable of generating sinus node-type impulses.[370] The use for enhancing conduction elsewhere in the myocardium has not been examined, but should serve as an important area of subsequent research. While each of these areas are exciting, much additional work will be required to bring these to a level permitting full application in the clinical arena.

References

1. Hartzler GO: Electrode catheter ablation of refractory focal ventricular tachycardia. J Am Coll Cardiol 1983;2:1107-1113.
2. Investigators. TC. Randomized antiarrhythmic drug therapy in survivors of cardiac arrest (the CASCADE Study). Am J Cardiol 1993;72:280-287.
3. Kuck KH, Cappato R, Siebels J, Ruppel R: Randomized comparison of antiarrhythmic drug therapy with implantable defibrillators in patients resuscitated from cardiac arrest: The cardiac arrest study Hamburg (CASH). Circulation 2000;102:748-754.
4. Anonymous: A comparison of antiarrhythmic-drug therapy with implantable defibrillators in patients resuscitated from near-fatal ventricular arrhythmias. The antiarrhythmics versus implantable defibrillators (AVID) Investigators. N Engl J Med 1997;337:1576-1583.
5. Connolly SJ, Gent M, Roberts RS, Dorian P, Roy D, Sheldon RS, Mitchell LB, Green MS, Klein GJ, O'Brien B: Canadian implantable defibrillator study (CIDS): A randomized trial of the implantable cardioverter defibrillator against amiodarone. Circulation 2000;101:1297-1302.
6. Anderson JL, Hallstrom AP, Epstein AE, Pinski SL, Rosenberg Y, Nora MO, Chilson D, Cannom DS, Moore R: Design and results of the antiarrhythmics vs implantable defibrillators (AVID) registry. Circulation 1999;99:1692-1699.
7. Zipes DP, Camm AJ, Borggrefe M, Buxton AE, Chaitman B, Fromer M, Gregoratos G, Klein G, Moss AJ, Myerburg RJ, Priori SG, Quinones MA, Roden DM, Silka MJ, Tracy C: ACC/AHA/ESC 2006 Guidelines for management of patients with ventricular arrhythmias and the prevention of sudden cardiac death. Circulation 2006;114:1088-1132.
8. McAlpine WA: *Heart and Coronary Arteries*. Berlin, Springer-Verlag, 1975, pp. 9-26.
9. McAlpine WA: *Heart and Coronary Arteries*. Berlin, Springer-Verlag, 1975, pp. 135-135.
10. Muriago M, Sheppard MN, Ho SY, Anderson RH: Location of the coronary arterial orifices in the normal heart. Clin Anat 1997;10:297-302.
11. Vaseghi M, Cesario DA, Mahajan A, Wiener I, Boyle NG, Fishbein MC, Horowitz BN, Shivkumar K: Catheter ablation of right ventricular outflow tract tachycardia: Value of defining coronary anatomy. J Cardiovasc Electrophysiol 2006;17:632-637.
12. Stamm C, Anderson RH, Ho SY: Clinical anatomy of the normal pulmonary root compared with that in isolated pulmonary valvar stenosis. J Am Coll Cardiol 1998;31:1420-1425.
13. Mehta D, Curwin J, Gomes A, Fuster V: Sudden death in coronary artery disease: Acute ischemia versus myocardial substrate. Circulation 1997;96:3215-3223.
14. Ishihara T, Ferrans VJ, Jones M, Boyce SW, Kawanami O, Roberts WC: Histologic and ultrastructural features of normal human pericardium. Am J Cardiol 1980;46:744-753.
15. Spodick DH: The normal and diseased pericardium: Current concepts of pericardial physiology, diseases and treatment. J Am Coll Cardiol 1983;1:240-251.
16. Lowe MD, Peterson LA, Monahan KH, Asivatham SJ, Packer DL: Electroanatomical mapping to assess phrenic nerve proximity to superior vena cava and pulmonary vein ostia. Heart 2004;90:24.
17. Sánchez-Quintana D, Cabrera JA, Climent V, Farré J, Weiglein A, Ho SY: How close are the phrenic nerves to cardiac structures? Implications for cardiac interventionalists. J Cardiovasc Electrophysiol 2005;16:309-313.
18. Wit AL, Janse MJJ: *The Ventricular Arrhythmias of Ischemia and Infarction (Chapter 1)*. Mt Kisco, NY: Futura Publishing, 1993.
19. Cranefield PF, Aronson RS: *Cardiac Arrhythmias: The Role of Triggered Activity and Other Mechanisms*. Mt Kisco, NY: Futura Publishing, 1988.
20. Roden, DM: Drug-induced prolongation of the QT interval. N Engl J Med 2004;350:1013-1022.
21. Samie FH, Berenfeld O, Anumonwo J, Mironov SF, Udassi S, Beaumont J, Taffet S, Pertsov AM, Jalife J: Rectification of the background potassium current: A determinant of rotor dynamics in ventricular fibrillation. Circ Res 2001;89:1216-1223.
22. Witkowski FX, Leon LJ, Penkoske PA, Giles WR, Spano ML, Ditto WL, Winfree AT: Spatio temporal evolution of ventricular fibrillation. Nature 1998;392:78-82.
23. Stevenson WG, Khan H, Sager P, Saxon LA, Middlekauff HR, Natterson PD, Wiener I: Identification of reentry circuit sites during catheter

mapping and radiofrequency ablation of ventricular tachycardia late after myocardial infarction. Circulation 1993;88:1647-1670.
24. Nogami A, Kubota S, Adachi M, Igawa O: Electrophysiologic and histopathologic findings of the ablation sites for ventricular fibrillation in a patient with ischemic cardiomyopathy. J Interv Card Electrophysiol 2009;24:133-137.
25. Moss AJ, Hall WJ, Cannom DS, Daubert JP, Higgins SL, Klein H, Levine JH, Saksena S, Waldo AL, Wilber D, Brown MW, Heo M: Improved survival with an implanted defibrillator in patients with coronary disease at high risk for ventricular arrhythmia. Multicenter Automatic Defibrillator Implantation Trial Investigators. N Engl J Med 1996;335:1933-1940.
26. Consensus Statement of the Joint Committees of the Unexplained Cardiac Arrest Registry of Europe and of the Idiopathic Ventricular Fibrillation Registry in the Unites States. Survivors of out-of-hospital cardiac arrest with apparently normal heart: Need for definition and standardized clinical evaluation. Circulation 1996;95:265-272.
27. Priori SG, Schwartz PJ, Napolitano C, Bloise R, Ronchetti E, Grillo M, Vicentini A, Spazzolini C, Nastoli J, Bottelli G, Folli R, Cappelletti D: Risk stratification in the long QT syndrome. N Engl J Med 2003;348:1866-1874.
28. Priori SG, Napolitano C, Gasparini M, Pappone C, Della Bella P, Giordano U, Bloise R, Giustetto C, De Nardis R, Grillo M, Ronchetti E, Faggiano G, Nastoli J: Natural history of Brugada syndrome: Insights for risk stratification and management. Circulation 2002;105:1342-1347.
29. Antzelevitch C: Drug-induced spatial dispersion of repolarisation. Cardiol J 2008;15:100-121.
30. Thiene G, Basso C, Corrado D: Pathophysiology and cardiovascular causes of sudden death. In: Silver MD, Gotlieb AI, Schoen FJ, eds. *Cardiovascular Pathology*. Philadelphia: Churchill Livingstone, 2001, pp. 326-374.
31. Stevenson WJ, Soejima K: Catheter ablation of ventricular tachycardia. Circulation 2007;115:2750-2760.
32. de Bakker JM, van Capelle FJ, Janse MJ, Tasseron S, Vermeulen JT, de Jonge N, Lahpor JR: Slow conduction in the infarcted human heart: 'Zigzag' course of activation. Circulation 1993;88:915-926.
33. Soejima K, Suzuki M, Maisel WH, Brunckhorst CB, Delacretaz E, Blier L, Tung S, Khan H, Stevenson WG: Catheter ablation in patients with multiple and unstable ventricular tachycardias after myocardial infarction: Short ablation lines guided by reentry circuit isthmuses and sinus rhythm mapping. Circulation 2001;104:664-669.
34. Fananapazir L, Tracy CM, Leon MB, Winkler JB, Cannon RO 3rd, Bonow RO, Maron BJ, Epstein SE: Electrophysiologic abnormalities in patients with hypertrophic cardiomyopathy. A consecutive analysis in 155 patients. Circulation 1989;80:1259-1268.
35. Soejima K, Stevenson WG, Sapp JL, Selwyn AP, Couper G, Epstein LM: Endocardial and epicardial radiofrequency ablation of ventricular tachycardia associated with dilated cardiomyopathy: The importance of low-voltage scars. J Am Coll Cardiol 2004;43:1834-1842.
36. Verma A, Kilicaslan F, Schweikert RA, Tomassoni G, Rossillo A, Marrouche NF, Ozduran V, Wazni OM, Elayi SC, Saenz LC, Minor S, Cummings JE, Burkhardt JD, Hao S, Beheiry S, Tchou PJ, Natale A: Short- and long-term success of substrate-based mapping and ablation of ventricular tachycardia in arrhythmogenic right ventricular dysplasia. Circulation 2005;111:3209-3216.
37. Corrado D, Basso C, Leoni L, Tokajuk B, Turrini P, Bauce B, Migliore F, Pavei A, Tarantini G, Napodano M, Ramondo A, Buja G, Iliceto S, Thiene G: Three-dimensional electroanatomical voltage mapping and histologic evaluation of myocardial substrate in right ventricular outflow tract tachycardia. J Am Coll Cardiol 2008;51:731-739.
38. Koplan BA, Soejima K, Baughman K, Epstein LM, Stevenson WG: Refractory ventricular tachycardia secondary to cardiac sarcoid: Electrophysiologic characteristics, mapping, and ablation. Heart Rhythm 2006;3:924-929.
39. Ladyjanskaia GA, Basso C, Hobbelink MGG, Kirkels JH, Lahpor JR, Cramer MJ, Thiene G, Hauer RNW, V Oosterhout MFM: Sarcoid myocarditis with ventricular tachycardia mimicking ARVD/C. J Cardiovasc Electrophysiol 2010;21:94-98.
40. Morwood JG, Triedman JK, Berul CI, Khairy P, Alexander ME, Cecchin F, Walsh EP: Radiofrequency catheter ablation of ventricular tachycardia in children and young adults with congenital heart disease. Heart Rhythm 2004;1:301-308.
41. Maruyama M, Tadera T, Miyamoto S, Ino T: Demonstration of the reentry circuit of verapamil-sensitive idiopathic left ventricular tachycardia: Direct evidence for macroreentry as the underlying mechanism. J Cardiovasc Electrophysiol 2001;12:968-972.
42. Nogami A, Naito S, Tada H, Taniguchi K, Okamoto Y, Nishimura S, Yamauchi Y, Aonuma K, Goya M, Iesaka Y, Hiroe M: Demonstration of diastolic and presystolic Purkinje potentials as critical potentials in a macroreentry circuit of verapamil-sensitive idiopathic left ventricular tachycardia. J Am Coll Cardiol 2000;36:811-823.
43. Lerman BB, Stein K, Engelstein ED, Battleman DS, Lippman N, Bei D, Catanzaro D: Mechanism of repetitive monomorphic ventricular tachycardia. Circulation 1995;92:421-429.
44. Ouyang F, Fotuhi P, Ho SY, Hebe J, Volkmer M, Goya M, Burns M, Antz M, Ernst S, Cappato R, Kuck KH: Repetitive monomorphic ventricular tachycardia originating from the aortic sinus cusp: Electrocardiographic characterization for guiding catheter ablation. J Am Coll Cardiol 2002;39:500-508.
45. Abouezzeddine O, Suleiman M, Buescher T, Kapa S, Friedman PA, Jahangir A, Mears JA, Ladewig DJ, Munger TM, Hammill SC, Packer DL, Asirvatham SJ: Relevance of endocavitary structures in ablation procedures for ventricular tachycardia. J Cardiovasc Electrophysiol 2010;21:245-254.
46. Daniels DV, Lu YY, Morton JB, Santucci PA, Akar JG, Green A, Wilber DJ: Idiopathic epicardial left ventricular tachycardia originating remote from the sinus of Valsalva: Electrophysiological characteristics, catheter ablation, and identification from 12-lead electrogram. Circulation 2006;113:1659-1666.
47. Dixit S, Gerstenfeld EP, Callans DJ, Marchlinski FE: Electrocardiographic patterns of superior right ventricular outflow tract tachycardias: Distinguishing septal and free wall sites of origin. J Cardiovasc Electrophysiol 2003;13:1-7.
48. Callans DJ: Catheter ablation of idiopathic ventricular tachycardia arising from the aortic root. J Cardiovasc Electrophysiol 2009;20:969-972.
49. Alasady M, Singleton CB, McGavigan AD: Left ventricular outflow tract ventricular tachycardia originating from the noncoronary cusp electrocardiographic and electrophysiological characterization and radiofrequency ablation. J Cardiovasc Electrophysiol 2009;20:1287-1290.
50. Yamada T, McElderry HT, Okada T, Murakami Y, Doppalapudi H, Yoshida N, Yoshida Y, Inden Y, Murohara T, Epstein AE, Plumb VJ, Kay GN: Idiopathic left ventricular arrhythmias originating adjacent to the left aortic sinus of Valsalva: Electrophysiological rationale for the surface electrocardiogram. J Cardiovasc Electrophysiol 2010;21:170-176.
51. Tada H, Tadokoro K, Ito S, Naito S, Hashimoto T, Kaseno K, Miyaji K, Sugiyasu A, Tsuchiya T, Kutsumi Y, Nogami A, Oshima S, Taniguchi K: Idiopathic ventricular arrhythmias originating from the tricuspid annulus: Prevalence, electrocardiographic characteristics, and results of radiofrequency catheter ablation. Heart Rhythm 2007;4:7-16.
52. Dixit S, Gerstenfeld EP, Lin D, Callans DJ, Hsia HH, Nayak HM, Zado E, Marchlinski FE: Identification of distinct electrocardiographic patterns from the basal left ventricle: Distinguising medial and lateral sites of origin in patients with idiopathic ventricular tachycardia. Heart Rhythm 2005;2:485-491.
53. Haqqani HM, Morton JB, Kalman JM. Using the 12-lead ECG to localize the origin of atrial and ventricular tachycardias: Part 2–ventricular tachycardia. J Cardiovasc Electrophysiol. 2009;20:825-832.
54. Bogun F, Desjardins B, Crawford T, Good E, Jongnarangsin K, Oral H, Chugh A, Pelosi F, Morady F: Post-infarction ventricular arrhythmias originating in papillary muscles. J Am Coll Cardiol 2008;51:1794-1802.
55. Good E, Desjardins B, Jongnarangsin K, Oral H, Chugh A, Ebinger M, Pelosi F, Morady F, Bogun F: Ventricular arrhythmias originating from a papillary muscle in patients without prior infarction: A comparison with fascicular arrhythmias. Heart Rhythm 2008;5:1530-1537.
56. Fontaine G, Fontaliran F, Frank R: Arrhythmogenic right ventricular cardiomyopathies. Clinical forms and main differential diagnoses. Circulation 1997;97:1532-1535.
57. Niroomand F, Carbucicchio C, Tondo C, Riva S, Fassini G, Apostolo A, Trevisi N, Bella PD: Electrophysiological characteristics and outcome in patients with idiopathic right ventricular arrhythmia compared with arrythmogenic right ventricular dysplasie. Heart 2002;87:41-47.
58. Kazmierczak J, De Sutter J, Tavernier R, Cuvelier C, Dimmer C, Jordaens L: Electrocardiographic and morphometric features in patients with ventricular tachycardia of right ventricular origin. Heart 1998;79:388-393.

59. Josephson ME, Horowitz LN, Waxman HL, Cain ME, Spielman SR, Greenspan AM, Marchlinski FE, Ezri MD: Sustained ventricular tachycardia: Role of the 12-lead electrocardiogram in localizing site of origin. Circulation 1981;64:257-272.
60. Waxman HL, Josephson ME: Ventricular activation during ventricular endocardial pacing: I. Electrocardiographic patterns related to the site of pacing. Am J Cardiol 1982;50:1-10.
61. Miller JM, Marchlinski FE, Buxton AE, Josephson ME: Relationship between the 12-lead electrocardiogram during ventricular tachycardia and endocardial site of origin in patients with coronary artery disease. Circulation 1988;77:759-766.
62. Josephson ME, Simson MB, Harken AH, Horowitz LN, Falcone RA: The incidence and clinical significance of epicardial late potentials in patients with recurrent sustained ventricular tachycardia and coronary artery disease. Circulation 1982;66:1199-1204.
63. Josephson ME, Callans DJ: Using the twelve-lead electrocardiogram to localize the site of origin of ventricular tachycardia. Heart Rhythm 2005;2:443-446.
64. Berruezo A, Mont L, Nava S, Chueca E, Bartholomay E, Brugada J: Electrocardiographic recognition of the epicardial origin of ventricular tachycardias. Circulation 2004;109:1842-1847.
65. Bazan V, Gerstenfeld EP, Garcia FC, Bala R, Rivas N, Dixit S, Zado E, Callans DJ, Marchlinski FE: Site-specific twelve-lead ECG features to identify an epicardial origin for left ventricular tachycardia in the absence of myocardial infarction. Heart Rhythm 2007;4:1403-1410.
66. Paul M, Schäfers M, Grude M, Reinke F, Juergens KU, Fischbach R, Schober O, Breithardt G, Wichter T: Idiopathic left ventricular aneurysm and sudden cardiac death in young adults. Europace 2006;8:607-612.
67. Kobza R, Jenni R, Erne P, Oechslin E, Duru F: Implantable cardioverter-defibrillators in patients with left ventricular noncompaction. Pacing Clin Electrophysiol 2008;31:461-467.
68. Chimenti C, Calabrese F, Thiene G, Pieroni M, Maseri A, Frustaci A: Inflammatory left ventricular microaneurysms as a cause of apparently idiopathic ventricular tachyarrhythmias. Circulation 2001;104:168-173.
69. Doppalapudi H, Yamada T, H. McElderry T, Plumb VJ, Epstein AE, Kay GN: Ventricular tachycardia originating from the posterior papillary muscle in the left ventricle: A distinct clinical syndrome. Circ Arrhythmia Electrophysiol 2008;1:23-29.
70. Okumura Y, Henz BD, Johnson SB, Jared Bunch J, O'Brien CJ, Hodge DO, Altman A, Govari A, Packer DL: Three-dimensional ultrasound for image-guided mapping and intervention: Methods, quantitative validation, and clinical feasibility of a novel multimodality image mapping system. Circ Arrhythmia Electrophysiol 2008;1:110-119.
71. Abbara S, Desai JC, Cury RC, Butler J, Nieman K, Reddy V: Mapping epicardial fat with multi-detector computed tomography to facilitate percutaneous transepicardial arrhythmia ablation. Eur J Radiol 2006;57:417-422.
72. Morady F, Harvey M, Kalbfleisch SJ, El-Atassi R, Calkins H, Langberg JJ: Radiofrequency catheter ablation of ventricular tachycardia in patients with coronary artery disease. Circulation 1993;87:363-372.
73. Kim YH, Sosa-Suarez G, Trouton TG, O'Nunain SS, Osswald S, McGovern BA, Ruskin JN, Garan H: Treatment of ventricular tachycardia by transcatheter radiofrequency ablation in patients with ischemic heart disease. Circulation 1994;89:1094-1102.
74. Rothman SA, Hsia HH, Cossú SF, Chmielewski IL, Buxton AE, Miller JM: Radiofrequency catheter ablation of postinfarction ventricular tachycardia: Long-term success and the significance of inducible nonclinical arrhythmias. Circulation 1997;96:3499-3508.
75. Callans DJ, Zado E, Sarter BH, Schwartzman D, Gottlieb CD, Marchlinski FE: Efficacy of radiofrequency catheter ablation for ventricular tachycardia in healed myocardial infarction. Am J Cardiol 1998;82:429-432.
76. Ortiz M, Almendral J, Villacastín J, Arenal A, Martínez-Sande JL, Pérez-Castellano N, González S, Delcán JL: Radiofrequency ablation of ventricular tachycardia in patients with ischemic cardiopathy. Rev Esp Cardiol 1999;52:159-168.
77. Calkins H, Epstein A, Packer D, Arria AM, Hummel J, Gilligan DM, Trusso J, Carlson M, Luceri R, Kopelman H, Wilber D, Wharton JM, Stevenson W: Catheter ablation of ventricular tachycardia in patients with structural heart disease using cooled radiofrequency energy: Results of a prospective multicenter study. Cooled RF multi center Investigators Group. J Am Coll Cardiol 2000;35:1905-1914.
78. O'Callaghan PA, Poloniecki J, Sosa-Suarez G, Ruskin JN, McGovern BA, Garan H: Long-term clinical outcome of patients with prior myocardial infarction after palliative radiofrequency catheter ablation for frequent ventricular tachycardia. Am J Cardiol 2001;87:975-979.
79. Van Der Burg AEB, de Groot NMS, van Erven L, Bootsma M, Van Der Wall EE, Schalij MJ: Long-term follow-up after radiofrequency catheter ablation of ventricular tachycardia: A successful approach? J Cardiovasc Electrophysiol 2002;13:417-423.
80. Della Bella P, De Ponti R, Uriarte JA, Tondo C, Klersy C, Carbucicchio C, Storti C, Riva S, Longobardi M: Catheter ablation and antiarrhythmic drugs for haemodynamically tolerated post-infarction ventricular tachycardia; long-term outcome in relation to acute electrophysiological findings. Eur Heart J 2002;23:414-424.
81. O'Donnell D, Bourke JP, Anilkumar R, Simeonidou E, Furniss SS: Radiofrequency ablation for post infarction ventricular tachycardia. Report of a single centre experience of 112 cases. Eur Heart J 2002;23:1699-1705.
82. Segal OR, Chow AW, Markides V, Schilling RJ, Peters NS, Davies DW: Long-term results after ablation of infarct-related ventricular tachycardia. Heart Rhythm 2005;2:474-482.
83. Stevenson WG, Wilber DJ, Natale A, Jackman WM, Marchlinski FE, Talbert T, Gonzalez MD, Worley SJ, Daoud EG, Hwang C, Schuger C, Bump TE, Jazayeri M, Tomassoni GF, Kopelman HA, Soejima K, Nakagawa H, Multicenter Thermocool VT Ablation Trial Investigators: Irrigated radiofrequency catheter ablation guided by electroanatomic mapping for recurrent ventricular tachycardia after myocardial infarction: The multicenter thermocool VT ablation trial. Circulation 2008;118:2773-2782.
84. Bubien RS, Fisher JD, Gentzel JA, Murphy EK, Irwin ME, Shea JB, Dick M 2nd, Ching E, Wilkoff BL, Benditt DG: NASPE expert consensus document: Use of i.v. (conscious) sedation/analgesia by nonanesthesia personnel in patients undergoing arrhythmia specific diagnostic, therapeutic, and surgical procedures. Pacing Clin Electrophysiol 1998;21:375-385.
85. Statement on Granting Privileges for Administration of Moderate Sedation to Practitioners who are not Anesthesia Professionals. Approved by House of Delegates on October 25, 2005, and amended on October 18, 2006, ASA Standarts, Guidelines & Statements, October 2006. pp. 43-48.
86. Delacretaz E, Soejima K, Gottipaty VK, Brunckhorst CB, Friedman PL, Stevenson WG: Single catheter determination of local electrogram prematurity using simultaneous unipolar and bipolar recordings to replace the surface ECG as a timing reference. Pacing Clin Electrophysiol 2001;24:441-449.
87. Man KC, Daoud EG, Knight BP, Bahu M, Weiss R, Zivin A, Souza SJ, Goyal R, Strickberger SA, Morady F: Accuracy of the unipolar electrogram for identification of the site of origin of ventricular activation. J Cardiovasc Electrophysiol 1997;8:974-979.
88. de Bakker JMT, Hauer RNW, Simmers TA: Activation mapping: Unipolar versus bipolar recording. In: Zipes DP, Jalife J, eds. *Cardiac Electrophysiology. From Cell to Bedside*. 2nd edition. Philadelphia: W.B. Saunders, 1995, p. 68.
89. Stevenson WG, Soejima K: Recording techniques for clinical electrophysiology. J Cardiovasc Electrophysiol 2005;16:1017-1022.
90. Joshi S, Wilber DJ: Ablation of idiopathic right ventricular outflow tract tachycardia: Current perspectives. J Cardiovasc Electrophysiol 2005;16(Suppl 1):S52-S58.
91. Lopera G, Stevenson WG, Soejima K, Maisel WH, Koplan B, Sapp JL, Satti SD, Epstein LM: Identification and ablation of three types of ventricular tachycardia involving the His-Purkinje system in patients with heart disease. J Cardiovasc Electrophysio 2004;15:52-58.
92. Nakagawa H, Beckman KJ, McClelland JH, Wang X, Arruda M, Santoro I, Hazlitt HA, Abdalla I, Singh A, Gossinger H: Radiofrequency catheter ablation of idiopathic left ventricular tachycardia guided by a Purkinje potential. Circulation 1993;88:2607-2017.
93. Ouyang F, Cappato R, Ernst S, Goya M, Volkmer M, Hebe J, Antz M, Vogtmann T, Schaumann A, Fotuhi P, Hoffmann-Riem M, Kuck KH: Electroanatomic substrate of idiopathic left ventricular tachycardia: Unidirectional block and macroreentry within the Purkinje network. Circulation 2002;105:462-469.
94. Marrouche NF, Verma A, Wazni O, Schweikert R, Martin DO, Saliba W, Kilicaslan F, Cummings J, Burkhardt JD, Bhargava M, Bash D, Brachmann J, Guenther J, Hao S, Beheiry S, Rossillo A, Raviele A, Themistoclakis S, Natale A: Mode of initiation and ablation of ventricular fibrillation storms in patients with ischemic cardiomyopathy. J Am Coll Cardiol 2004;43:1715-1720.
95. Haïssaguerre M, Extramiana F, Hocini M, Cauchemez B, Jaïs P, Cabrera JA, Farré J, Leenhardt A, Sanders P, Scavée C, Hsu LF,

Weerasooriya R, Shah DC, Frank R, Maury P, Delay M, Garrigue S, Clémenty J: Mapping and ablation of ventricular fibrillation associated with long-QT and Brugada syndromes. Circulation 2003;108:925-928.
96. Szumowski L, Sanders P, Walczak F, Hocini M, Jaïs P, Kepski R, Szufladowicz E, Urbanek P, Derejko P, Bodalski R, Haïssaguerre M: Mapping and ablation of polymorphic ventricular tachycardia after myocardial infarction. J Am Coll Cardiol 2004;44:1700-1706.
97. Bogun F, Good E, Reich S, Elmouchi D, Igic P, Tschopp D, Dey S, Wimmer A, Jongnarangsin K, Oral H, Chugh A, Pelosi F, Morady F: Role of Purkinje fibers in post-infarction ventricular tachycardia. J Am Coll Cardiol 2006;48:2500-2507.
98. Aiba T, Shimizu W, Taguchi A, Suyama K, Kurita T, Aihara N, Kamakura S: Clinical usefulness of a multielectrode basket catheter for idiopathic ventricular tachycardia originating from right ventricular outflow tract. J Cardiovasc Electrophysiol 2001;12:511-517.
99. Schilling RJ, Peters NS, Davies DW: Simultaneous endocardial mapping in the human left ventricle using a noncontact catheter: Comparison of contact and reconstructed electrograms during sinus rhythm. Circulation 1998;98:887-898.
100. Sivagangabalan G, Pouliopoulos J, Huang K, Lu J, Barry MA, Thiagalingam A, Ross DL, Thomas SP, Kovoor P: Comparison of electroanatomic contact and noncontact mapping of ventricular scar in a postinfarct ovine model with intramural needle electrode recording and histological validation. Circ Arrhythmia Electrophysiol 2008;1:363-369.
101. Thiagalingam A, Wallace EM, Campbell CR, Boyd AC, Eipper VE, Byth K, Ross DL, Kovoor P: Value of noncontact mapping for identifying left ventricular scar in an ovine model. Circulation 2004;110:3175-3180.
102. Jacobson JT, Afonso VX, Eisenman G, Schultz JR, Lazar S, Michele JJ, Josephson ME, Callans DJ: Characterization of the infarct substrate and ventricular tachycardia circuits with noncontact unipolar mapping in a porcine model of myocardial infarction. Heart Rhythm 2006;3:189-197.
103. Voss F, Bauer A, Witte S, Katus HA, Becker R: Can noncontact mapping distinguish between endo- and epicardial foci? Clin Res Cardiol 2008;97:734-741.
104. Josephson ME, Waxman HL, Cain ME, Gardner MJ, Buxton AE: Ventricular activation during ventricular endocardial pacing. II. Role of pace-mapping to localize origin of ventricular tachycardia. Am J Cardiol 1982;50:11-22.
105. Bogun F, Taj M, Ting M, Kim HM, Reich S, Good E, Jongnarangsin K, Chugh A, Pelosi F, Oral H, Morady F: Spatial resolution of pace mapping of idiopathic ventricular tachycardia/ectopy originating in the right ventricular outflow tract. Heart Rhythm 2008;5:339-344.
106. Soejima K, Stevenson WG, Maisel WH, Sapp JL, Epstein LM: Electrically unexcitable scar mapping based on pacing threshold for identification of the reentry circuit isthmus: Feasibility for guiding ventricular tachycardia ablation. Circulation 2002;106:1678-1683.
107. Kadish AH, Childs K, Schmaltz S, Morady F: Differences in QRS configuration during unipolar pacing from adjacent sites: Implications for the spatial resolution of pace-mapping. J Am Coll Cardiol 1991;17:143-151.
108. Kadish AH, Schmaltz S, Morady F: A comparison of QRS complexes resulting from unipolar and bipolar pacing: Implications for pace-mapping. Pacing Clin Electrophysiol 1991;14:823-832.
109. Azegami K, Wilber DJ, Arruda M, Lin AC, Denman RA: Spatial resolution of pacemapping and activation mapping in patients with idiopathic right ventricular outflow tract tachycardia. J Cardiovasc Electrophysiol 2005;16:823-829.
110. Gerstenfeld EP, Dixit S, Callans DJ, Rajawat Y, Rho R, Marchlinski FE: Quantitative comparison of spontaneous and paced 12-lead electrocardiogram during right ventricular outflow tract ventricular tachycardia. J Am Coll Cardiol 2003;41:2046-2053.
111. Yamada T, Murakami Y, Yoshida N, Okada T, Shimizu T, Toyama J, Yoshida Y, Tsuboi N, Muto M, Inden Y, Hirai M, Murohara T, McElderry HT, Epstein AE, Plumb VJ, Kay GN: Preferential conduction across the ventricular outflow septum in ventricular arrhythmias originating from the aortic sinus cusp. J Am Coll Cardiol 2007;50:884-891.
112. Klemm HU, Ventura R, Steven D, Johnsen C, Rostock T, Lutomsky B, Risius T, Meinertz T, Willems S: Catheter ablation of multiple ventricular tachycardias after myocardial infarction guided by combined contact and noncontact mapping. Circulation 2007;115:2697-2704.
113. Marchlinski FE, Callans DJ, Gottlieb CD, Zado E: Linear ablation lesions for control of unmappable ventricular tachycardia in patients with ischemic and nonischemic cardiomyopathy. Circulation 2000;101:1288-1296.
114. Kottkamp H, Wetzel U, Schirdewahn P, Dorszewski A, Gerds-Li JH, Carbucicchio C, Kobza R, Hindricks G: Catheter ablation of ventricular tachycardia in remote myocardial infarction: Substrate description guiding placement of individual linear lesions targeting noninducibility. J Cardiovasc Electrophysiol 2003;14:675-681.
115. Brunckhorst CB, Delacretaz E, Soejima K, Maisel WH, Friedman PL, Stevenson WG: Identification of the ventricular tachycardia isthmus after infarction by pace mapping. Circulation 2004;110:652-659.
116. Stevenson WG, Khan H, Sager P, Saxon LA, Middlekauff HR, Natterson PD, Wiener I: Identification of reentry circuit sites during catheter mapping and radiofrequency ablation of ventricular tachycardia late after myocardial infarction. Circulation 1993;88:1647-1670.
117. Tung S, Soejima K, Maisel WH, Suzuki M, Epstein L, Stevenson WG: Recognition of far-field electrograms during entrainment mapping of ventricular tachycardia. J Am Coll Cardiol 2003;42:110-115.
118. Soejima K, Stevenson WG, Maisel WH, Delacretaz E, Brunckhorst CB, Ellison KE, Friedman PL: The N + 1 difference: A new measure for entrainment mapping. J Am Coll Cardiol 2001;37:1386-1394.
119. Delacretaz E, Stevenson WG: Catheter ablation of ventricular tachycardia in patients with coronary heart disease: Part I: Mapping. Pacing Clin Electrophysiol 2001;24:1261-1277.
120. Bogun F, Kim HM, Han J, Tamirissa K, Tschopp D, Reich S, Elmouchi D, Igic P, Lemola K, Good E, Oral H, Chugh A, Pelosi F, Morady F: Comparison of mapping criteria for hemodynamically tolerated, postinfarction ventricular tachycardia. Heart Rhythm 2006;3:20-26.
121. El-Shalakany A, Hadjis T, Papageorgiou P, Monahan K, Epstein L, Josephson ME: Entrainment/mapping criteria for the prediction of termination of ventricular tachycardia by single radiofrequency lesion in patients with coronary artery disease. Circulation 1999;99:2283-2289.
122. Bogun F, Krishnan SC, Marine JE, Hohnloser SH, Schuger C, Oral H, Pelosi F, Chugh A, Morady F: Catheter ablation guided by termination of postinfarction ventricular tachycardia by pacing with nonglobal capture. Heart Rhythm 2004;1:422-426.
123. Bogun F, Good E, Han J, Tamirisa K, Reich S, Elmouchi D, Igic P, Lemola K, Oral H, Chugh A, Pelosi F, Morady F: Mechanical interruption of postinfarction ventricular tachycardia as a guide for catheter ablation. Heart Rhythm 2005;2:687-691.
124. Miller JM, Kienzle MG, Harken AH, Josephson ME: Subendocardial resection for ventricular tachycardia: Predictors of surgical success. Circulation 1984;70:624-631.
125. Reddy VY, Neuzil P, Taborsky M, Ruskin JN: Short-term results of substrate mapping and radiofrequency ablation of ischemic ventricular tachycardia using a saline-irrigated catheter. J Am Coll Cardiol 2003;41:2228-2236.
126. Hsia HH, Callans DJ, Marchlinski FE: Characterization of endocardial electrophysiological substrate in patients with nonischemic cardiomyopathy and monomorphic ventricular tachycardia. Circulation 2003;108:704-710.
127. Corrado D, Basso C, Leoni L, Tokajuk B, Bauce B, Frigo G, Tarantini G, Napodano M, Turrini P, Ramondo A, Daliento L, Nava A, Buja G, Iliceto S, Thiene G: Three-dimensional electroanatomic voltage mapping increases accuracy of diagnosing arrhythmogenic right ventricular cardiomyopathy/dysplasia. Circulation 2005;111:3042-3050.
128. Oza S, Wilber DJ: Substrate-based endocardial ablation of postinfarction ventricular tachycardia. Heart Rhythm 2006;3:607-609.
129. Arenal A, Glez-Torrecilla E, Ortiz M, Villacastín J, Fdez-Portales J, Sousa E, del Castillo S, Perez de Isla L, Jimenez J, Almendral J: Ablation of electrograms with an isolated, delayed component as treatment of unmappable monomorphic ventricular tachycardias in patients with structural heart disease. J Am Coll Cardiol 2003;41:81-92.
130. Arenal A, del Castillo S, Gonzalez-Torrecilla E, Atienza F, Ortiz M, Jimenez J, Puchol A, García J, Almendral J: Tachycardia-related channel in the scar tissue in patients with sustained monomorphic ventricular tachycardias: Influence of the voltage scar definition. Circulation 2004;110:2568-2574.
131. Hsia HH, Lin D, Sauer WH, Callans DJ, Marchlinski FE: Anatomic characterization of endocardial substrate for hemodynamically stable reentrant ventricular tachycardia: Identification of endocardial conducting channels. Heart Rhythm 2006;3:503-512.

132. Sosa E, Scanavacca M, D'Avila A, Oliveira F, Ramires JA: Nonsurgical transthoracic epicardial catheter ablation to treat recurrent ventricular tachycardia occurring late after myocardial infarction. J Am Coll Cardiol 2000;35:1442-1449.
133. Sosa E, Scanavacca M, D'Avila A, Piccioni J, Sanchez O, Velarde JL, Silva M, Reolão B: Endocardial and epicardial ablation guided by nonsurgical transthoracic epicardial mapping to treat recurrent ventricular tachycardia. J Cardiovasc Electrophysiol 1998;9:229-239.
134. Sosa E, Scanavacca M, D'Avila A, Pilleggi F: A new technique to perform epicardial mapping in the electrophysiology laboratory. J Cardiovasc Electrophysiol 1996;7:531-535.
135. Grimard C, Lacotte J, Hidden-Lucet F, Duthoit G, Gallais Y, Frank R: Percutaneous epicardial radiofrequency ablation of ventricular arrhythmias after failure of endocardial approach: A 9-year experience. J Cardiovasc Electrophysiol 2010;21:56-61.
136. Tedrow U, Stevenson WG: Strategies for epicardial mapping and ablation of ventricular tachycardia. J Cardiovasc Electrophysiol 2009;20:710-713.
137. D'Avila A, Scanavacca M, Sosa E: Transthoracic epicardial catheter ablation of ventricular tachycardia. Heart Rhythm 2006;3:1110-1111.
138. D'Avila A, Houghtaling C, Gutierrez P, Vragovic O, Ruskin JN, Josephson ME, Reddy VY: Catheter ablation of ventricular epicardial tissue: A comparison of standard and cooled-tip radiofrequency energy. Circulation 2004;109:2363-2369.
139. D'Avila A, Gutierrez P, Scanavacca M, Reddy V, Lustgarten DL, Sosa E, Ramires JA: Effects of radiofrequency pulses delivered in the vicinity of the coronary arteries: Implications for nonsurgical transthoracic epicardial catheter ablation to treat ventricular tachycardia. Pacing Clin Electrophysiol 2002;25:1488-1495.
140. Schweikert RA, Saliba WI, Tomassoni G, Marrouche NF, Cole CR, Dresing TJ, Tchou PJ, Bash D, Beheiry S, Lam C, Kanagaratnam L, Natale A: Percutaneous pericardial instrumentation for endo-epicardial mapping of previously failed ablations. Circulation 2003;108:1329-1335.
141. Bogun F, Morady F: Ablation of ventricular tachycardia in patients with nonischemic cardiomyopathy. J Cardiovasc Electrophysiol 2008;19:1227-1230.
142. Asirvatham SJ, Bruce CJ, Friedman PA: Advances in imaging for cardiac electrophysiology. Coron Artery Dis 2003;14:3-13.
143. Khaykin Y, Skanes A, Whaley B, Hill C, Beardsall M, Seabrook C, Wulffhart Z, Oosthuizen R, Gula L, Verma A: Real-time integration of 2D intracardiac echocardiography and 3D electroanatomical mapping to guide ventricular tachycardia ablation. Heart Rhythm 2008;5:1396-1402.
144. Judd RM, Wagner A, Rehwald WG, Albert T, Kim RJ: Technology insight: Assessment of myocardial viability by delayed-enhancement magnetic resonance imaging. Nat Clin Pract Cardiovasc Med 2005;2:150-158.
145. Mahrholdt H, Wagner A, Judd RM, Sechtem U, Kim RJ: Delayed enhancement cardiovascular magnetic resonance assessment of non-ischaemic cardiomyopathies. Eur Heart J 2005;26:1461-1474.
146. Reddy VY, Malchano ZJ, Holmvang G, Schmidt EJ, d'Avila A, Houghtaling C, Chan RC, Ruskin JN: Integration of cardiac magnetic resonance imaging with three-dimensional electroanatomic mapping to guide left ventricular catheter manipulation: Feasibility in a porcine model of healed myocardial infarction. J Am Coll Cardiol 2004;44:2202-2213.
147. Dickfeld T, Lei P, Dilsizian V, Jeudy J, Dong J, Voudouris A, Peters R, Saba M, Shekhar R, Shorofsky S: Integration of three-dimensional scar maps for ventricular tachycardia ablation with positron emission tomography-computed tomography. J Am Coll Cardiol Img 2008;1:73-82.
148. Nazarian S, Roguin A, Zviman MM, Lardo AC, Dickfeld TL, Calkins H, Weiss RG, Berger RD, Bluemke DA, Halperin HR: Clinical utility and safety of a protocol for noncardiac and cardiac magnetic resonance imaging of patients with permanent pacemakers and implantable-cardioverter defibrillators at 1.5 tesla. Circulation 2006;114:1277-1284.
149. Gimbel JR: Magnetic resonance imaging of implantable cardiac rhythm devices at 3.0 Tesla. Pacing Clin Electrophysiol 2008;31:795-801.
150. Corrado D, Basso C, Nava A, Thiene G: Arrhythmogenic right ventricular cardiomyopathy: Current diagnostic and management strategies. Cardiol Rev 2001;9:259-265.
151. Fahmy TS, Wazni OM, Jaber WA, Walimbe V, Di Biase L, Elayi CS, DiFilippo FP, Young RB, Patel D, Riedlbauchova L, Corrado A, Burkhardt JD, Schweikert RA, Arruda M, Natale A: Integration of positron emission tomography/computed tomography with electroanatomical mapping: A novel approach for ablation of scar-related ventricular tachycardia. Heart Rhythm 2008;5:1538-1545.
152. Tian J, Smith MF, Chinnadurai P, Dilsizian V, Turgeman A, Abbo A, Gajera K, Xu C, Plotnick D, Peters R, Saba M, Shorofsky S, Dickfeld T: Clinical application of PET/CT fusion imaging for three-dimensional myocardial scar and left ventricular anatomy during ventricular tachycardia ablation. J Cardiovasc Electrophysiol 2009;20:597-604.
153. Evans GT Jr, Scheinman MM, Zipes DP, Benditt D, Camm AJ, el-Sherif N, Fisher J, Fontaine G, German L, Hartzler G. Catheter ablation for control of ventricular tachycardia: A report of the percutaneous cardiac mapping and ablation registry. Pacing Clin Electrophysiol 1986;9:1391-1395.
154. Franklin JO, Langberg JJ, Oeff M, Finkbeiner WE, Herre JM, Griffin JC, Scheinman MM: Catheter ablation of canine myocardium with radiofrequency energy. Pacing Clin Electrophysiol 1989;12:170-176.
155. Eick OJ: Temperature controlled radiofrequency ablation. Indian Pacing Electrophysiol J 2002;2:66-73.
156. Mitsui T, Ijima H, Okamura K, Hori M: Transvenous electrocautery of the atrioventricular connection guided by the His electrogram. Jpn Circ J 1978;42:313-318.
157. Nath S, DiMarco JP, Haines DE: Basic aspects of radiofrequency catheter ablation. J Cardiovasc Electrophysiol 1994;5:863-876.
158. Soejima K, Delacretaz E, Suzuki M, Brunckhorst CB, Maisel WH, Friedman PL, Stevenson WG: Saline-cooled versus standard radiofrequency catheter ablation for infarct-related ventricular tachycardias. Circulation 2001;103:1858-1862.
159. Wittkampf FH: Temperature response in radiofrequency catheter ablation. Circulation 1992;86:1648-1650.
160. Wittkampf FH, Nakagawa H, Yamanashi WS, Imai S, Jackman WM: Thermal latency in radiofrequency ablation. Circulation 1996;93:1083-1086.
161. Wittkampf FH, Hauer RN, Robles de Medina EO: Control of radiofrequency lesion size by power regulation. Circulation 1989;80:962-968
162. Wittkampf FH, Nakagawa H: RF catheter ablation: Lessons on lesions. Pacing Clin Electrophysiol 2006;29:1285-1297.
163. Delacretaz E, Stevenson WG, Winters GL, Mitchell RN, Stewart S, Lynch K, Friedman PL: Ablation of ventricular tachycardia with a saline-cooled radiofrequency catheter: Anatomic and histologic characteristics of the lesions in humans. J Cardiovasc Electrophysiol 1999;10:860-865.
164. Nakagawa H, Yamanashi WS, Pitha JV, Arruda M, Wang X, Ohtomo K, Beckman KJ, McClelland JH, Lazzara R, Jackman WM: Comparison of in vivo tissue temperature profile and lesion geometry for radiofrequency ablation with a saline-irrigated electrode versus temperature control in a canine thigh muscle preparation. Circulation 1995;91:2264-2273.
165. Ruffy R, Imran MA, Santel DJ, Wharton JM: Radiofrequency delivery through a cooled catheter tip allows the creation of larger endomyocardial lesions in the ovine heart. J Cardiovasc Electrophysiol 1995;6:1089-1096.
166. Skrumeda LL, Mehra R: Comparison of standard and irrigated radiofrequency ablation in the canine ventricle. J Cardiovasc Electrophysiol 1998;9:1196-1205.
167. Yokoyama K, Nakagawa H, Wittkampf FH, Pitha JV, Lazzara R, Jackman WM: Comparison of electrode cooling between internal and open irrigation in radiofrequency ablation lesion depth and incidence of thrombus and steam pop. Circulation 2006;113:11-19.
168. Tanner H, Hindricks G, Volkmer M, Furniss S, Kühlkamp V, Lacroix D, De Chillou C, Almendral J, Caponi D, Kuck KH, Kottkamp H: Catheter ablation of recurrent scar-related ventricular tachycardia using electroanatomical mapping and irrigated ablation technology: Results of the prospective multicenter euro-VT-study. J Cardiovasc Electrophysiol 2010;21:47-53.
169. Grumbrecht S, Neuzner J, Pitschner HF: Interrelation of tissue temperature versus flow velocity in two different kinds of temperature controlled catheter radiofrequency energy applications. J Interv Card Electrophysiol 1998;2:211-219.
170. Erdogan A, Grumbrecht S, Carlsson J, Roederich H, Schulte B, Sperzel J, Berkowitsch A, Neuzner J, Pitschner HF: Homogeneity and diameter of linear lesions induced with multipolar ablation catheters: In vitro and in vivo comparison of pulsed versus continuous radiofrequency energy delivery. J Interv Card Electrophysiol 2000;4:655-661.

171. Brugada P, de Swart H, Smeets JL, Wellens HJ: Transcoronary chemical ablation of ventricular tachycardia. Circulation 1989;79:475-482.
172. Friedman PL, Dubuc M, Green MS, Jackman WM, Keane DT, Marinchak RA, Nazari J, Packer DL, Skanes A, Steinberg JS, Stevenson WG, Tchou PJ, Wilber DJ, Worley SJ: Catheter cryoablation of supraventricular tachycardia: Results of the multicenter prospective "frosty" trial. Heart Rhythm 2004;1:129-138.
173. Kay GN, Epstein AE, Bubien RS, Anderson PG, Dailey SM, Plumb VJ: Intracoronary ethanol ablation for the treatment of recurrent sustained ventricular tachycardia. J Am Coll Cardiol 1992;19:159-168.
174. Segal OR, Wong T, Chow AW, Jarman JW, Schilling RJ, Markides V, Peters NS, Wyn Davies D: Intra-coronary guidewire mapping-a novel technique to guide ablation of human ventricular tachycardia. J Interv Card Electrophysiol 2007;18:143-154.
175. Carlson MD: Transvenous cryoablation of supraventricular tachycardias: It works but is it better? J Cardiovasc Electrophysiol 2002;13:1090-1091.
176. Kurzidim K, Schneider HJ, Kuniss M, Sperzel J, Greiss H, Berkowitsch A, Pitschner HF: Cryocatheter ablation of right ventricular outflow tract tachycardia. J Cardiovasc Electrophysiol 2005;16:366-369.
177. Lustgarten DL, Bell S, Hardin N, Calame J, Spector PS: Safety and efficacy of epicardial cryoablation in a canine model. Heart Rhythm 2005;2:82-90.
178. Moniotte S, Triedman JK, Cecchin F: Successful cryoablation of ventricular tachycardia arising from the proximal right bundle branch in a child. Heart Rhythm 2008;5:142-144.
179. Matsudaira K, Nakagawa H, Wittkampf FH, Yamanashi WS, Imai S, Pitha JV, Lazzara R, Jackman WM: High incidence of thrombus formation without impedance rise during radiofrequency ablation using electrode temperature control. Pacing Clin Electrophysiol 2003;26:1227-1237.
180. Zeppenfeld K, Stevenson WG: Ablation of ventricular tachycardia in patients with structural heart disease. Pacing Clin Electrophysiol 2008;31:358-374.
181. Morady F: Radiofrequency ablation as treatment for cardiac arrhythmias. N Engl J Med 1999;340:534-544.
182. Reddy VY, Reynolds MR, Neuzil P, Richardson AW, Taborsky M, Jongnarangsin K, Kralovec S, Sediva L, Ruskin JN, Josephson ME: Prophylactic catheter ablation for prevention of defibrillator therapy. N Engl J Med 2007;357:2657-2665.
183. de Bakker JM, van Capelle FJ, Janse MJ, Wilde AA, Coronel R, Becker AE, Dingemans KP, van Hemel NM, Hauer RN: Reentry as a cause of ventricular tachycardia in patients with chronic ischemic heart disease: Electrophysiologic and anatomic correlation. Circulation 1988;77:589-606.
184. Stevenson WG, Nademanee K, Weiss JN, Wiener I, Baron K, Yeatman LA, Sherman CT: Programmed electrical stimulation at potential ventricular reentry circuit sites. Comparison of observations in humans with predictions from computer simulations. Circulation 1989;80:793-806.
185. Akhtar M: Clinical spectrum of ventricular tachycardia. Circulation 1990;82:1561-1573.
186. Kindwall KE, Brown J, Josephson ME: Electrocardiographic criteria for ventricular tachycardia in wide complex left bundle branch block morphology tachycardias. Am J Cardiol 1988;61:1279-1283.
187. Della Bella P, Pappalardo A, Riva S, Tondo C, Fassini G, Trevisi N: Non-contact mapping to guide catheter ablation of untolerated ventricular tachycardia. Eur Heart J 2002;23:742-752.
188. Scheinman MM, Huang S: The 1998 NASPE prospective catheter ablation registry. Pacing Clin Electrophysiol 2000;23:1020-1028.
189. Sra J, Bhatia A, Dhala A, Blanck Z, Deshpande S, Cooley R, Akhtar M: Electroanatomically guided catheter ablation of ventricular tachycardias causing multiple defibrillator shocks. Pacing Clin Electrophysiol 2001;24:1645-1652.
190. Marchlinski F, Garcia F, Siadatan A, Sauer W, Beldner S, Zado E, Hsia H, Lin D, Cooper J, Verdino R, Gerstenfeld E, Dixit S, Russo A, Callans D: Ventricular tachycardia/ventricular fibrillation ablation in the setting of ischemic heart disease. J Cardiovasc Electrophysiol 2005;16:S59-S70.
191. Carbucicchio C, Santamaria M, Trevisi N, Maccabelli G, Giraldi F, Fassini G, Riva S, Moltrasio M, Cireddu M, Veglia F, Della Bella P: Catheter ablation for the treatment of electrical storm in patients with implantable cardioverter-defibrillators: Short- and long-term outcomes in a prospective single-center study. Circulation 2008;117:462-469.
192. Eckart RE, Hruczkowski TW, Tedrow UB, Koplan BA, Epstein LM, Stevenson WG: Sustained ventricular tachycardia associated with corrective valve surgery. Circulation 2007;116:2005-2011.
193. Hsia HH, Marchlinski FE: Characterization of the electroanatomic substrate for monomorphic ventricular tachycardia in patients with nonischemic cardiomyopathy. Pacing Clin Electrophysiol 2002;25:1114-1127.
194. Nazarian S, Bluemke DA, Lardo AC, Zviman MM, Watkins SP, Dickfeld TL, Meininger GR, Roguin A, Calkins H, Tomaselli GF, Weiss RG, Berger RD, Lima JA, Halperin HR: Magnetic resonance assessment of the substrate for inducible ventricular tachycardia in nonischemic cardiomyopathy. Circulation 2005;112:2821-2825.
195. Saba MM, Porter M, Mitchell M, Brysiewicz N, Santucci P, Akar J: Role of the epicardium in ventricular tachycardia associated with non-ischemic cardiomyopathy. Heart Rhythm 2007;4:S331.
196. Cano O, Fan R, Hutchinson MD, Bala R, Garcia FC, Riley MP: Epicardial and endocardial electroanatomic substrate in patients with nonischemic cardiomyopathy and ventricular tachycardia. Heart Rhythm 2008;5:S27.
197. Dixit S, Narula N, Callans DJ, Marchlinski FE: Electroanatomic mapping of human heart: Epicardial fat can mimic scar. J Cardiovasc Electrophysiol 2003;14:1128.
198. Kottkamp H, Hindricks G, Chen X, Brunn J, Willems S, Haverkamp W, Block M, Breithardt G, Borggrefe M: Radiofrequency catheter ablation of sustained ventricular tachycardia in idiopathic dilated cardiomyopathy. Circulation 1995;92:1159-1168.
199. McKenna WJ, Thiene G, Nava A, Fontaliran F, Blomstrom-Lundqvist C, Fontaine G, Camerini F: Diagnosis of arrhythmogenic right ventricular dyslasia/cardiomyopathy. Task Force of the working group for myocardial and pericardial disease of the European Society of Cardiology and of the Scientific Council on Cardiomyopathies of the International Society and Federation of Cardiology. Br Heart J 1994;71:215-218.
200. Sen-Chowdhry S, Prasad SK, Syrris P, Wage R, Ward D, Merrifield R, Smith GC, Firmin DN, Pennell DJ, McKenna WJ: Cardiovascular magnetic resonance in arrhythmogenic right ventricular cardiomyopathy revisited: Comparison with task force criteria and genotype. J Am Coll Cardiol 2006;48:2132-2140.
201. Marchlinski FE, Zado E, Dixit S, Gerstenfeld E, Callans DJ, Hsia H, Lin D, Nayak H, Russo A, Pulliam W: Electroanatomic substrate and outcome of catheter ablative therapy for ventricular tachycardia in the setting of right ventricular cardiomypathy. Circulation 2004;110:2293-2298.
202. Sen-Chowdhry S, Syrris P, Prasad SK, Hughes SE, Merrifield R, Ward D, Pennell DJ, McKenna WJ: Left-dominant arrhythmogenic cardiomyopathy: An under-recognized clinical entity. J Am Coll Cardiol 2008;52:2175-2187.
203. Lobo FV, Heggtveit HA, Butany J, Silver MD, Edwards JE: Right ventricular dysplasia: Morphological findings in 13 cases. Can J Cardiol 1992;8:261-268.
204. Tabib A, Loire R, Chalabreysse L, Meyronnet D, Miras A, Malicier D, Thivolet F, Chevalier P, Bouvagnet P: Circumstances of death and gross and microscopic observations in a series of 200 cases of sudden death associated with arrhythmogenic right ventricular cardiomyopathy and/or dysplasia. Circulation 2003;108:3000-3005.
205. Garcia FC, Bazan V, Hutchinson MD, Riley MP, Bala R, Zado ES, Gerstenfeld E, Marchlinski FE: Comparison of endocardial and epicardial substrate and outcome of epicardial ventricular tachycardia ablation in patients with right ventricular cardiomyopathy/dysplasia. Heart Rhythm 2008;5:S123.
206. Stevenson WG, Friedman PL, Sager PT, Saxon LA, Kocovic D, Harada T, Wiener I, Khan H: Exploring postinfarction reentrant ventricular tachycardia with entrainment mapping. J Am Coll Cardiol 1997;29:1180-1189.
207. Stevenson WG, Kocovic D, Friedman PL: Ablation of ventricular tachycardia late after myocardial infarction: Techniques for localizing target sites. In: Huang SKS, Wilber DJ, eds., *Radiofrequency Catheter Ablation of Cardiac Arrhythmias: Basic Concept and Clinical Applications*. Armonk, NY: Futura publishing, 2000, pp. 669-700.
208. O'Donnell D, Cox D, Bourke J, Mitchell L, Furniss S: Clinical and electrophysiological differences between patients with arrhythmogenic right ventricular dysplasia and right ventricular outflow tract tachycardia. Eur Heart J 2003;24:801-810.
209. Miljoen H, State S, de Chillou C, Magnin-Poull I, Dotto P, Andronache M, Abdelaal A, Aliot E: Electroanatomic mapping characteristics of ventricular tachycardia in patients with arrhythmogenic right ventricular cardiomyopathy/dysplasia. Europace 2005;7:516-524.

210. Satomi K, Kurita T, Suyama K, Noda T, Okamura H, Otomo K, Shimizu W, Aihara N, Kamakura S: Catheter ablation of stable and unstable ventricular tachycardias in patients with arrhythmogenic right ventricular dysplasia. J Cardiovasc Electrophysiol 2006;17:469-476.
211. Yao Y, Zhang S, He DS, Zhang K, Hua W, Chu J, Pu J, Chen K, Wang F, Chen X: Radiofrequency ablation of the ventricular tachycardia with arrhythmogenic right ventricular cardiomyopathy using non-contact mapping. Pacing Clin Electrophysiol 2007;30:526-533.
212. Dalal D, Jain R, Tandri H, Dong J, Eid SM, Prakasa K, Tichnell C, James C, Abraham T, Russell SD, Sinha S, Judge DP, Bluemke DA, Marine JE, Calkins H: Long-term efficacy of catheter ablation of ventricular tachycardia in patients with arrhythmogenic right ventricular dysplasia/cardiomyopathy. J Am Coll Cardiol 2007;50:432-440.
213. Wijnmaalen AP, SchaliJ MJ, Bootsma M, Kies P, De Roos A, Putter H, Bax JJ, Zeppenfeld K: Patients with scar-related right ventricular tachycardia: Determinants of long-term outcome. J Cardiovasc Electrophysiol 2009;20:1119-1127.
214. Nogami A, Sugiyasu A, Tada H, Kurosaki K, Sakamaki M, Kowase S, Oginosawa Y, Kubota S, Usui T, Naito S: Changes in the isolated delayed component as an endpoint of catheter ablation in arrhythmogenic right ventricular cardiomyopathy: Predictor for long-term success. J Cardiovasc Electrophysiol 2008;19:681-688.
215. Fananapazir L, Chang AC, Epstein SE, McAreavey D: Prognostic determinants in hypertrophic cardiomyopathy. Prospective evaluation of a therapeutic strategy based on clinical, Holter, hemodyamic, and electrophysiological findings. Circulation 1992;86:730-740.
216. Gilligan DM, Missouris CG, Boyd MJ, Oakley CM: Sudden death due to ventricular tachycardia during amiodarone therapy in familial hypertrophic cardiomyopathy. Am J Cardiol 1991;68:971-973.
217. Rodriguez LM, Smeets JLRM, Timmermans C, Blommaert D, van Dantzig JM, Wellens HJJ: Radiofrequency catheter ablation of sustained ventricular tachycardia in hypertrophic cardiomyopathy. J Cardiovasc Electrophysiol 1997;8:803-806.
218. Murphy JG, Gersh BJ, Mair DD, Fuster V, McGoon MD, Ilstrup DM, McGoon DC, Kirklin JW, Danielson GK: Long-term outcome in patients undergoing surgical repair of tetralogy of Fallot. N Engl J Med 1993;329:593-599.
219. Roos-Hesselink J, Pelroth MG, McGhie J, Spitaels S: Atrial arrhythmias in adults after repair of tetralogy of Fallot: Correlations with clinical, exercise, and electrophysiologic findings. Circulation 1995;91:2214-2219.
220. Harrison DA, Harris L, Siu SC, MacLoghlin CJ, Connelly MS, Webb GD, Downar E, McLaughlin PR, Williams WG: Sustained ventricular tachycardia in adult patients late after repair of tetralogy of Fallot. J Am Coll Cardiol 1997;30:1368-1373.
221. Gatzoulis MA, Till JA, Sommerville J, Redington AN: Mechanoelectrical interaction in tetralogy of Fallot: QRS prolongation relates to right ventricular size and predicts malignant ventricular arrhythmias and sudden death. Circulation 1995;92:231-237.
222. Berul CI, Hill SL, Geggel RL, Hijazi ZM, Marx GR, Rhodes J, Walsh KA, Fulton DR: Electrocardiographic markers of late sudden death risk in postoperative tetralogy of Fallot children. J Cardiovasc Electrophysiol 1997;8:1349-1356.
223. Horowitz LN, Vetter VL, Harken AH, Josephson ME: Electrophysiologic characteristics of sustained ventricular tachycardia occurring after repair of tetralogy of Fallot. Am J Cardiol 1980;46:446-452.
224. Downar E, Harris L, Kimber S, Mickleborough L, Williams W, Sevaptsidis E, Masse S, Chen TC, Chan A, Genga A: Ventricular tachycardia after surgical repair of tetralogy of Fallot: Results of intraoperative mapping studies. J Am Coll Cardiol 1992;20:648-655.
225. Horton RP, Canby RC, Kessler DJ, Joglar JA, Hume A, Jessen ME, Scott WP, Page RL: Ablation of ventricular tachycardia associated with tetralogy of Fallot: Demonstration of bidirectional block. J Cardiovasc Electrophysiol 1997;8:432-435.
226. Zeppenfeld K, Schalij MJ, Bartelings MM, Tedrow UB, Koplan BA, Soejima K, Stevenson WG: Catheter ablation of ventricular tachycardia after repair of congenital heart disease. Electroanatomic identification of the critical right ventricular isthmus. Circulation 2007;116:2241-2252.
227. Hebe J, Hansen P, Ouyang F, Volkner M, Kuck KH: Radiofrequency catheter ablation of tachycardia in patients with congenital heart disease. Pediatr Cardiol 2000;21:557-575.
228. Gonska BD, Cao K, Raab J, Eigster G, Kreuzer H: Radiofrequency catheter ablation of right ventricular tachycardia late after repair of congenital heart defects. Circulation 1996;94:1902-1908.
229. Mendoza I, Camardo J, Moleiro F, Castellanos A, Medina V, Gomez J, Acquatella H, Casal H, Tortoledo F, Puigbo J: Sustained ventricular tachycardia in chronic chagasic myocarditis: Electrophysiologic and pharmacologic characteristics. Am J Cardiol 1986;57:423-427.
230. de Paola AA, Horowitz LN, Miyamoto MH, Pinheiro R, Ferreira DF, Terzian AB, Cirenza C, Guiguer N Jr, Portugal OP: Angiographic and electrophysiologic substrates of ventricular tachycardia in chronic Chagasic myocarditis. Am J Cardiol 1990;65:360-363.
231. Rassi A Jr, Rassi SG, Rassi A: Sudden death in Chagas' disease. Arq Bras Cardiol 2001;76:75-96.
232. Abello M, Gonzalez-Zuelgaray J, Lopez C, Labadet C: Initiation modes of spontaneous monomorphic ventricular tachycardia in patients with Chagas heart disease. Rev Esp Cardiol 2008;61:487-493.
233. d'Avila A, Splinter R, Svenson RH, Scanavacca M, Pruitt E, Kasell J, Sosa E: New perspectives on catheter-based ablation of ventricular tachycardia complicating Chagas' disease: Experimental evidence of the efficacy of near infrared lasers for catheter ablation of Chagas' VT. J Interv Card Electrophysiol 2002;7:23-38.
234. Sosa E, Scanavacca M, D'Avila A, Bellotti G, Pilleggi F: Radiofrequency catheter ablation of ventricular tachycardia guided by nonsurgical epicardial mapping in chronic Chagasic heart disease. Pacing Clin Electrophysiol 1999;22:128-130.
235. Acquatella H: Echocardiography in Chagas heart disease. Circulation 2007;115:1124-1131.
236. Scanavacca M, Sosa E, d'Avila A, De Lourdes Higuchi M: Radiofrequency ablation of sustained ventricular tachycardia related to the mitral isthmus in Chagas' disease. Pacing Clin Electrophysiol 2002;25:368-371.
237. Sosa E, Scanavacca M: Epicardial mapping and ablation techniques to control ventricular tachycardia. J Cardiovasc Electrophysiol 2005;16:449-452.
238. Jefic D, Joel B, Good E, Morady F, Rosman H, Knight B, Bogun F: Role of radiofrequency catheter ablation of ventricular tachycardia in cardiac sarcoidosis: Report from a multicenter registry. Heart Rhythm 2009;6:189-195.
239. Maloy WC, Arrants JE, Sowell BF, Hendrix GH: Left ventricular aneurysm of uncertain etiology with recurrent ventricular arrhythmias. N Engl J Med 1971;285:662-663.
240. Mestroni L, Morgera T, Miani D, Pinamonti B, Sinagra G, Tanganelli P, Silvestri F, Camerini F: Idiopathic left ventricular aneurysm: A clinical and pathological study of a new entity in the spectrum of cardiomyopathies. Postgrad Med J 1994;70(Suppl 1):S13-S20.
241. Tada H, Kurita T, Ohe T, Shimizu W, Suyama K, Aihara N, Shimomura K, Kamakura S: Clinical and electrophysiologic features of idiopathic left ventricular aneurysm with sustained ventricular tachycardia. Int J Cardiol 1998;67:27-38.
242. Ouyang F, Antz M, Deger FT, Bänsch D, Schaumann A, Ernst S, Kuck KH: An underrecognized subepicardial reentrant ventricular tachycardia attributable to left ventricular aneurysm in patients with normal coronary arteriograms. Circulation 2003;107:2702-2709.
243. Steinberg JS, Gaur A, Sciacca R, Tan E: New-onset sustained ventricular tachycardia after cardiac surgery. Circulation 1999;99:903-908.
244. Haïssaguerre M, Shoda M, Jaïs P, Nogami A, Shah DC, Kautzner J, Arentz T, Kalushe D, Lamaison D, Griffith M, Cruz F, de Paola A, Gaïta F, Hocini M, Garrigue S, Macle L, Weerasooriya R, Clémenty J: Mapping and ablation of idiopathic ventricular fibrillation. Circulation 2002;106:962-967.
245. Yu CC, Tsai CT, Lai LP, Lin JL: Successful radiofrequency catheter ablation of idiopathic ventricular fibrillation presented as recurrent syncope and diagnosed by an implanted loop recorder. Int J Cardiol 2006;110:112-113.
246. Kohsaka S, Razavi M, Massumi A: Idiopathic ventricular fibrillation successfully terminated by radiofrequency ablation of the distal Purkinje fibers. Pacing Clin Electrophysiol 2007;30:701-704.
247. Saliba W, Abul Karim A, Tchou P, Natale A: Ventricular fibrillation: Ablation of a trigger? J Cardiovasc Electrophysiol 2002;13:1296-1299.
248. Takatsuki S, Mitamura H, Ogawa S: Catheter ablation of a monofocal premature ventricular complex triggering idiopathic ventricular fibrillation. Heart 2001;86:E3.
249. Betts TR, Yue A, Roberts PR, Morgan JM: Radiofrequency ablation of idiopathic ventricular fibrillation guided by noncontact mapping. J Cardiovasc Electrophysiol 2004;15:957-959.
250. Bänsch D, Oyang F, Antz M, Arentz T, Weber R, Val-Mejias JE, Ernst S, Kuck KH: Successful catheter ablation of electrical storm after myocardial infarction. Circulation 2003;108:3011-3016.

251. Enjoji Y, Mizobuchi M, Shibata K, Yokouchi I, Funatsu A, Kanbayashi D, Kobayashi T, Nakamura S: Catheter ablation for an incessant form of antiarrhythmic drug-resistant ventricular fibrillation after acute coronary syndrome. Pacing Clin Electrophysiol 2006;29:102-105.
252. Takahashi Y, Takahashi A, Isobe M: Ventricular fibrillation initiated by premature beats from the ventricular myocardium not associated with the Purkinje system after myocardial infarction. Heart Rhythm 2008;5:1458-1460.
253. Srivathsan K, Gami AS, Ackerman MJ, Asirvatham SJ: Treatment of ventricular fibrillation in a patient with prior diagnosis of long QT syndrome: Importance of precise electrophysiologic diagnosis to successfully ablate the trigger. Heart Rhythm 2007;4:1090-1093.
254. Darmon JP, Bettouche S, Deswardt P, Tiger F, Ricard P, Bernasconi F, Saoudi N: Radiofrequency ablation of ventricular fibrillation and multiple right and left atrial tachycardia in a patient with Brugada syndrome. J Interv Card Electrophysiol 2004;11:205-209.
255. Nakagawa E, Takagi M, Tatsumi H, Yoshiyama M: Successful radiofrequency catheter ablation for electrical storm of ventricular fibrillation in a patient with Brugada syndrome. Circ J 2008;72:1025-1029.
256. Mlcochova H, Saliba WI, Burkhardt DJ, Rodriguez RE, Cummings JE, Lakkireddy D, Patel D, Natale A: Catheter ablation of ventricular fibrillation storm in patients with infiltrative amyloidosis of the heart. J Cardiovasc Electrophysiol 2006;17:426-430.
257. Sanders P, Hsu LF, Hocini M, Jaïs P, Takahashi Y, Rotter M, Sacher F, Pasquié JL, Arentz T, Scavée C, Garrigue S, Clémenty J, Haïssaguerre M: Mapping and ablation of ventricular fibrillation. Minerva Cardioangiol 2004;52:171-181.
258. Li YG, Grönefeld G, Israel C, Hohnloser SH: Catheter ablation of frequently recurring ventricular fibrillation in a patient after aortic valve repair. J Cardiovasc Electrophysiol 2004;15:90-93.
259. Kamakura S, Shimizu W, Matsuo K, Taguchi A, Suyama K, Kurita T, Aihara N, Ohe T, Shimomura K: Localization of optimal ablation site of idiopathic ventricular tachycardia from right and left ventricular outflow tract by body surface ECG. Circulation 1998;98:1525-1533.
260. Kim RJ, Iwai S, Markowitz SM, Shah BK, Stein KM, Lerman BB: Clinical and electrophysiological spectrum of idiopathic ventricular outflow tract arrhythmias. J Am Coll Cardiol 2007;49:2035-2043.
261. Lerman BB, Belardinelli L, West GA, Berne RM, DiMarco JP: Adenosine-sensitive ventricular tachycardia: Evidence suggesting cyclic AMP-mediated triggered activity. Circulation 1986;74:270-280.
262. Sung RJ, Keung EC, Nguyen NX, Huycke EC: Effects of beta-adrenergic blockade on verapamil-responsive and verapamil-irresponsive sustained ventricular tachycardias. J Clin Invest 1988;81:688-699.
263. Morady F, Kadish AH, DiCarlo L, Kou WH, Winston S, deBuitlier M, Calkins H, Rosenheck S, Sousa J: Long-term results of catheter ablation of idiopathic right ventricular tachycardia. Circulation 1990;82:2093-2099.
264. Jadonath R, Schwartzman D, Preminger M, Gottlieb C, Marchlinski F: Utility of the 12-lead electrocardiogram in localizing the origin of right ventricular outflow tract tachycardia. Am Heart J 1995;130:1107-1113.
265. Chinushi M, Aizawa Y, Takahashi K, Kitazawa H, Shibata A: Radiofrequency catheter ablation for idiopathic right ventricular tachycardia with special reference to morphological variation and long-term outcome. Heart 1997;78:255-261.
266. Wilber D, Baerman J, Olshansky B, Kall J, Kopp D: Adenosine-sensitive ventricular tachycardia: Clinical characteristics and response to catheter ablation. Circulation 1993;87:126-134.
267. Coggins DL, Lee RJ, Sweeney J, Chein WW, Van Hare G, Epstein L, Gonzalez R, Griffin JC, Lesh MD, Scheinman MM: Radiofrequency catheter ablation as a cure for idiopathic tachycardia of both left and right ventricular origin. J Am Coll Cardiol 1994;23:1333-1341.
268. Cole C, Marrouche N, Natale A: Evaluation and management of ventricular outflow tract tachycardias. Cardiac Electrophysiol Rev 2002;6:442-447.
269. Badhwar N, Scheinman M: Idiopathic ventricular tachycardia: Diagnosis and management. Curr Probl Cardiol 2007;32:7-43.
270. Saleem MA, Burkett S, Passman R, Dibs S, Engelstein ED, Kadish AH, Goldberger JJ: New simplified technique for 3D mapping and ablation of right ventricular outflow tract tachycardia. Pacing Clin Electrophysiol 2005;28:397-403.
271. Ribbing M, Wasmer K, Mönnig G, Kirchhof P, Loh P, Breithardt G, Haverkamp W, Eckardt L: Endocardial mapping of right ventricular outflow tract tachycardia using noncontact activation mapping. J Cardiovasc Electrophysiol 2003;14:602-608.
272. Kanagaratnam L, Tomassoni G, Schweikert R, Pavia S, Bash D, Beheiry S, Neibauer M, Saliba W, Chung M, Tchou P, Natale A: Ventricular tachycardias arising from the aortic sinus of Valsalva: An under-recognized variant of left outflow tract ventricular tachycardia. J Am Coll Cardiol 2001;37:1408-1414.
273. Tada H, Oral H, Sticherling C, Chough SP, Baker RL, Wasmer K, Pelosi F Jr, Knight BP, Strickberger SA, Morady F: Double potentials along the ablation line as a guide to radiofrequency ablation of typical atrial flutter. J Am Coll Cardiol 2001;38:750-755.
274. Meininger G, Berger R: Idiopathic ventricular tachycardia originating in the great cardiac vein. Heart Rhythm 2006;3:464-466.
275. Timmermans C, Rodriguez L, Crijns H, Moorman A, Wellens H: Idiopathic left bundle-branch block-shaped ventricular tachycardia may originate above the pulmonary valve. Circulation 2003;108:1960-1967.
276. Sekiguchi Y, Aonuma K, Takahashi A, Yamauchi Y, Hachiya H, Yokoyama Y, Iesaka Y, Isobe M: Electrocardiographic and electrophysiologic characteristics of ventricular tachycardia originating within the pulmonary artery. J Am Coll Cardiol 2005;45:887-895.
277. Lamberti F, Calo' L, Pandozi C, Castro A, Loricchio ML, Boggi A, Toscano S, Ricci R, Drago F, Santini M: Radiofrequency catheter ablation of idiopathic left ventricular outflow tract tachycardia: Utility of intracardiac echocardiography. J Cardiovasc Electrophysiol 2001;12:529-535.
278. Tanner H, Hindricks G, Schirdewahn P, Kobza R, Dorszewski A, Piorkowski C, Gerds-Li JH, Kottkamp H: Outflow tract tachycardia with R/S transition in lead V3: Six different anatomic approaches for successful ablation. J Am Coll Cardiol 2005;45:418-423.
279. Tada H, Ito S, Naito S, Kurosaki K, Kubota S, Sugiyasu A, Tsuchiya T, Miyaji K, Yamada M, Kutsumi Y, Oshima S, Nogami A, Taniguchi K: Idiopathic ventricular arrhythmia arising from the mitral annulus: A distinct subgroup of idiopathic ventricular arrhythmias. J Am Coll Cardiol 2005;45:877-886.
280. Yamauchi Y, Aonuma K, Takahashi A, Sekiguchi Y, Hachiya H, Yokoyama Y, Kumagai K, Nogami A, Iesaka Y, Isobe M: Electrocardiographic characteristics of repetitive monomorphic right ventricular tachycardia originating near the His-bundle. J Cardiovasc Electrophysiol 2005;16:1041-1048.
281. Atienza F, Arenal A, Torrecilla EG, García-Alberola A, Jiménez J, Ortiz M, Puchol A, Almendral J: Acute and long-term outcome of transvenous cryoablation of midseptal and parahissian accessory pathways in patients at high risk of atrioventricular block during radiofrequency ablation. Am J Cardiol 2004;93:1302-1130.
282. Zipes DP, Foster PR, Troup PJ, Pedersen DH: Atrial induction of ventricular tachycardia: Reentry versus triggered automaticity. Am J Cardiol 1979;44:1-8.
283. Belhassen B, Rotmensch HH, Laniado S: Response of recurrent sustained ventricular tachycardia to verapamil. Br Heart J 1981;46:679-682.
284. Kottkamp H, Chen X, Hindricks G, Willems S, Haverkamp W, Wichter T, Breithardt G, Borggrefe M: Idiopathic left ventricular tachycardia: New insights into electrophysiological characteristics and radiofrequency catheter ablation. Pacing Clin Electrophysiol 1995;18:1285-1297.
285. Rodriguez LM, Smeets JL, Timmermans C, Trappe HJ, Wellens HJ: Radiofrequency catheter ablation of idiopathic ventricular tachycardia originating in the anterior fascicle of the left bundle branch. J Cardiovasc Electrophysiol 1996;7:1211-1216.
286. Nogami A, Naito S, Tada H, Oshima S, Taniguchi K, Aonuma K, Iesaka Y: Verapamil-sensitive left anterior fascicular ventricular tachycardia: Results of radiofrequency ablation in six patients. J Cardiovasc Electrophysiol 1998;9:1269-1278.
287. Berenfeld O, Jalife J: Purkinje-muscle reentry as a mechanism of polymorphic ventricular arrhythmias in a 3-dimensional model of the ventricles. Circ Res 1998;82:1063-1077.
288. Tabereaux PB, Walcott GP, Rogers JM, Kim J, Dosdall DJ, Robertson PG, Killingsworth CR, Smith WM, Ideker RE: Activation patterns of Purkinje fibers during long-duration ventricular fibrillation in an isolated canine heart model. Circulation 2007;116:1113-1119.
289. Noda T, Shimizu W, Taguchi A, Aiba T, Satomi K, Suyama K, Kurita T, Aihara N, Kamakura S: Malignant entity of idiopathic ventricular fibrillation and polymorphic ventricular tachycardia initiated by premature extra systoles originating from the right ventricular outflow tract. J Am Coll Cardiol 2005;46:1288-1294.

290. Akihiko N, Aiko S, Shoichi K, Kenichi K: Mapping and ablation of idiopathic ventricular fibrillation from the Purkinje system. Heart rhythm 2005;2:646-649.
291. Kataoka M, Takatsuki S, Tanimoto K, Akaishi M, Ogawa S, Mitamura H: A case of vagally mediated idiopathic ventricular fibrillation. Nat Clin Pract Cardiovasc Med 2008;5:111-115.
292. Lerman BB, Stein KM, Markowitz SM: Idiopathic right ventricular outflow tract tachycardia: A clinical approach. Pacing Clin Electrophysiol 1996;19:2120-2137.
293. Friedman PA, Asirvatham SJ, Grice S, Glikson M, Munger TM, Rea RF, Shen WK, Jahanghir A, Packer DL, Hammill SC: Noncontact mapping to guide ablation of right ventricular outflow tract tachycardia. J Am Coll Cardiol 2002;39:1808-1812.
294. Ventura R, Steven D, Klemm HU, Lutomsky B, Müllerleile K, Rostock T, Servatius H, Risius T, Meinertz T, Kuck KH, Willems S: Decennial follow-up in patients with recurrent tachycardia originating from the right ventricular outflow tract: Electrophysiologic characteristics and response to treatment. Eur Heart J 2007;28:2338-2345.
295. Hindricks G: The multicentre european radiofrequency survey (MERFS): Complications of radiofrequency catheter ablation of arrhythmias. The Multicentre European Radiofrequency Survey (MERFS) Investigators of the Working Group on arrhythmias of the European Society of Cardiology. Eur Heart J 1993;14:1644-1653.
296. Delacretaz E, Stevenson WG: Catheter ablation of ventricular tachycardia in patients with coronary heart disease. Part II: Clinical aspects, limitations, and recent developments. Pacing Clin Electrophysiol 2001;24:1403-1411.
297. Epstein MR, Knapp LD, Martindill M, Lulu JA, Triedman JK, Calkins H, Huang SK, Walsh EP, Saul JP: Embolic complications associated with radiofrequency catheter ablation. ATAKR Investigator Group. Am J Cardiol 1996;77:655-658.
298. Thakur RK, Klein GJ, Yee R, Zardini M: Embolic complications after radiofrequency catheter ablation. Am J Cardiol 1994;74:278-279.
299. Olsson A, Darpo B, Bergfeldt L, Rosenqvist M: Frequency and long term follow up of valvar insufficiency caused by retrograde aortic radiofrequency catheter ablation procedures. Heart 1999;81:292-296.
300. O'Donnell D, Bourke JP, Anilkumar R, Simeonidou E, Furniss SS: Radiofrequency ablation for post infarction ventricular tachycardia. Report of a single centre experience of 112 cases. Eur Heart J 2002;23:1699-1705.
301. Cohen TJ, Chien WW, Lurie KG, Young C, Goldberg HR, Wang YS, Langberg JJ, Lesh MD, Lee MA, Griffin JC: Radiofrequency catheter ablation for treatment of bundle branch reentrant ventricular tachycardia: Results and long-term follow-up. J Am Coll Cardiol 1991;18:1767-1773.
302. Blanck Z, Dhala A, Deshpande S, Sra J, Jazayeri M, Akhtar M: Bundle branch reentrant ventricular tachycardia: Cumulative experience in 48 patients. J Cardiovasc Electrophysiol 1993;4:253-262.
303. Mehdirad AA, Keim S, Rist K, Tchou P: Long-term clinical outcome of right bundle branch radiofrequency catheter ablation for treatment of bundle branch reentrant ventricular tachycardia. Pacing Clin Electrophysiol 1995;18:2135-2143.
304. Narasimhan C, Jazayeri MR, Sra J, Dhala A, Deshpande S, Biehl M, Akhtar M, Blanck Z: Ventricular tachycardia in valvular heart disease: Facilitation of sustained bundle-branch reentry by valve surgery. Circulation 1997;96:4307-4313.
305. Khan HH, Maisel WH, Ho C, Suzuki M, Soejima K, Solomon S, Stevenson WG: Effect of radiofrequency catheter ablation of ventricular tachycardia on left ventricular function in patients with prior myocardial infarction. J Interv Card Electrophysiol 2002;7:243-247.
306. Pons M, Beck L, Leclercq F, Ferriere M, Albat B, Davy JM: Chronic left main coronary artery occlusion: A complication of radiofrequency ablation of idiopathic left ventricular tachycardia. Pacing Clin Electrophysiol 1997;20:1874-1876.
307. Zeppenfeld K, Tops LF, Bax JJ, Schalij MJ: Images in cardiovascular medicine. Epicardial radiofrequency catheter ablation of ventricular tachycardia in the vicinity of coronary arteries is facilitated by fusion of 3-dimensional electroanatomical mapping with multislice computed tomography. Circulation 2006;114:e51-e52.
308. Gaines PA, Cumberland DC, Kennedy A, Welsh CL, Moorhead P, Rutley MS: Cholesterol embolisation: A lethal complication of vascular catheterisation. Lancet 1988;1:168-170.
309. Van Hare GF, Witherell CL, Lesh MD: Follow-up of radiofrequency catheter ablation in children: Results in 100 consecutive patients. J Am Coll Cardiol 1994;23:1651-1659.
310. Kelm M, Perings SM, Jax T, Lauer T, Schoebel FC, Heintzen MP, Perings C, Strauer BE: Incidence and clinical outcome of iatrogenic femoral arteriovenous fistulas: Implications for risk stratification and treatment. J Am Coll Cardiol 2002;40:291-297.
311. Waigand J, Uhlich F, Gross CM, Thalhammer C, Dietz R: Percutaneous treatment of pseudoaneurysms and arteriovenous fistulas after invasive vascular procedures. Catheter Cardiovasc Interv 1999;47:157-164.
312. D'Avila A: Epicardial catheter ablation of ventricular tachycardia. Heart Rhythm 2008;5(Suppl):S73-S75.
313. Aryana A, D'Avila A, Heist EK, Mela T, Singh JP, Ruskin JN, Reddy VY: Remote magnetic navigation to guide endocardial and epicardial catheter mapping of scar-related ventricular tachycardia. Circulation 2007;115:1191-1200.
314. Bai R, Patel D, Di Biase L, Fahmy TS, Kozeluhova M, Prasad S, Schweikert R, Cummings J, Saliba W, Andrews-Williams M, Themistoclakis S, Bonso A, Rossillo A, Raviele A, Schmitt C, Karch M, Uriarte JA, Tchou P, Arruda M, Natale A: Phrenic nerve injury after catheter ablation: Should we worry about this complication? J Cardiovasc Electrophysiol 2006;17:944-948.
315. Buch E, Vaseghi M, Cesario DA, Shivkumar K: A novel method for preventing phrenic nerve injury during catheter ablation. Heart Rhythm 2007;4:95-98.
316. Matsuo S, Jaïs P, Knecht S, Lim KT, Hocini M, Derval N, Wright M, Sacher F, Haïssaguerre M: Images in cardiovascular medicine. Novel technique to prevent left phrenic nerve injury during epicardial catheter ablation. Circulation 2008;117:e471.
317. D'Avila A, Neuzil P, Thiagalingam A, Gutierrez P, Aleong R, Ruskin JN, Reddy VY: Experimental efficacy of pericardial instillation of anti-inflammatory agents during percutaneous epicardial catheter ablation to prevent postprocedure pericarditis. J Cardiovasc Electrophysiol 2007;18:1178-1183.
318. O'Donnell D, Bourke JP, Furniss SS: Standardized stimulation protocol to predict the long-term success of radiofrequency ablation of postinfarction ventricular tachycardia. Pacing Clin Electrophysiol 2003;26:348-351.
319. Verma A, Kilicaslan F, Marrouche NF, Minor S, Khan M, Wazni O, Burkhardt JD, Belden WA, Cummings JE, Abdul-Karim A, Saliba W, Schweikert RA, Tchou PJ, Martin DO, Natale A: Prevalence, predictors, and mortality significance of the causative arrhythmia in patients with electrical storm. J Cardiovasc Electrophysiol 2004;15:1265-1270.
320. Chun SH, Sager PT, Stevenson WG, Nademanee K, Middlekauff HR, Singh BN: Long-term efficacy of amiodarone for the maintenance of normal sinus rhythm in patients with refractory atrial fibrillation or flutter. Am J Cardiol 1995;76:47-50.
321. Hunt SA: ACC/AHA 2005 guideline update for the diagnosis and management of chronic heart failure in the adult: A report of the American College of Cardiology/American Heart Association Task Force on Practice Guidelines (Writing Committee to Update the 2001 Guidelines for the Evaluation and Management of Heart Failure). J Am Coll Cardiol 2005;46:e1-e82.
322. Connolly SJ, Dorian P, Roberts RS, Gent M, Bailin S, Fain ES, Thorpe K, Champagne J, Talajic M, Coutu B, Gronefeld GC, Hohnloser SH, Optimal Pharmacological Therapy in Cardioverter Defibrillator Patients (OPTIC) Investigators: Comparison of beta-blockers, amiodarone plus beta-blockers, or sotalol for prevention of shocks from implantable cardioverter defibrillators: The OPTIC Study: A randomized trial. JAMA 2006;295:165-171.
323. Coleman CI, Kluger J, Bhavnani S, Clyne C, Yarlagadda R, Guertin D, White CM: Association between statin use and mortality in patients with implantable cardioverter-defibrillators and left ventricular systolic dysfunction. Heart Rhythm 2008;5:507-510.
324. Metcalf RG, Sanders P, James MJ, Cleland LG, Young GD: Effect of dietary n-3 polyunsaturated fatty acids on the inducibility of ventricular tachycardia in patients with ischemic cardiomyopathy. Am J Cardiol 2008;101:758-761.
325. Gissi-HF I: Effect of rosuvastatin in patients with chronic heart failure (the GISSI-HF trial): A randomised, double-blind, placebo-controlled trial. Lancet 2008;372:1231-1239.
326. Brouwer IA, Zock PL, Camm AJ, Böcker D, Hauer RN, Wever EF, Dullemeijer C, Ronden JE, Katan MB, Lubinski A, Buschler H, Schouten EG, SOFA Study Group: Effect of fish oil on ventricular tachyarrhythmia and death in patients with implantable cardioverter defibrillators: The study on omega-3 fatty acids and ventricular arrhythmia (SOFA) randomized trial. JAMA 2006;295:2613-2619.

327. United States Food and Drug Administration Center for Devices and Radiological Health. Recommended clinical study design for ventricular tachycardia ablation. http://www.fda.gov/cdrh/ode/tachyabl.pdf. 1999:1-14.
328. Guiraudon GM, Fontaine G, Frank R, Cabrol C, Grosgogeat Y: Encircling endocardial ventriculotomy in the treatment of recurrent ventricular tachycardia after myocardial infarction. Arch Mal Coeur Vaiss 1982;75:1013-1021.
329. Horowitz LN, Harken AH, Kastor JA, Josephson ME: Ventricular resection guided by epicardial and endocardial mapping for treatment of recurrent ventricular tachycardia. N Engl J Med 1980;302:589-593.
330. Josephson ME, Harken AH, Horowitz LN: Endocardial excision: A new surgical technique for the treatment of recurrent ventricular tachycardia. Circulation 1979;60:1430-1439.
331. Josephson ME, Harken AH, Horowitz LN: Long-term results of endocardial resection for sustained ventricular tachycardia in coronary disease patients. Am Heart J 1982;104:51-57.
332. Guiraudon GM. Surgery without interventions? Pacing Clin Electrophysiol 1998;21:2160-2165.
333. Lee SH, Tai CT, Chiang CE, Huang JL, Chiou CW, Ding YA, Chang MS, Chen SA: Determinants of successful ablation of idiopathic ventricular tachycardias with left bundle branch block morphology from the right ventricular outflow tract. Pacing Clin Electrophysiol 2002;25:1346-1351.
334. Tada H, Tadokoro K, Miyaji K, Ito S, Kurosaki K, Kaseno K, Naito S, Nogami A, Oshima S, Taniguchi K: Idiopathic ventricular arrhythmias arising from the pulmonary artery: Prevalence, characteristics, and topography of the arrhythmia origin. Heart Rhythm 2008;5:419-426.
335. Hachiya H, Aonuma K, Yamauchi Y, Igawa M, Nogami A, Iesaka Y: How to diagnose, locate, and ablate coronary cusp ventricular tachycardia. J Cardiovasc Electrophysiol 2002;13:551-556.
336. Lin D, Hsia HH, Gerstenfeld EP, Dixit S, Callans DJ, Nayak H, Russo A, Marchlinski FE: Idiopathic fascicular left ventricular tachycardia: Linear ablation lesion strategy for non-inducible or non-sustained tachycardia. Heart Rhythm 2005;2:934-939.
337. Kumagai K, Fukuda K, Wakayama Y, Sugai Y, Hirose M, Yamaguchi N, Takase K, Yamauchi Y, Takahashi A, Aonuma K, Shimokawa H: Electrocardiographic characteristics of the variants of idiopathic left ventricular outflow tract ventricular tachyarrhythmias. J Cardiovasc Electrophysiol 2008;19:495-501.
338. Haïssaguerre M, Shah DC, Jaïs P, Shoda M, Kautzner J, Arentz T, Kalushe D, Kadish A, Griffith M, Gaïta F, Yamane T, Garrigue S, Hocini M, Clémenty J: Role of Purkinje conduction system in triggering of idiopathic ventricular fibrillation. Lancet 2002;359:677-678.
339. Lim KK, Maron BJ, Knight BP: Successful catheter ablation of hemodynamically unstable monomorphic ventricular tachycardia in a patient with hypertrophic cardiomyopathy and apical aneurysm. J Cardiovasc Electrophysiol 2009;20:445-447.
340. Wright M, Sacher F, Haissaguerre M: Catheter ablation for patients with ventricular fibrillation. Curr Opin Cardiol 2008;24:56-60.
341. Klein RC, Raitt MH, Wilkoff BL, Beckman KJ, Coromilas J, Wyse DG, Friedman PL, Martins JB, Epstein AE, Hallstrom AP, Ledingham RB, Belco KM, Greene HL, AVID Investigators: Analysis of implantable defribillator therapy in the antiarrhythmics versus implantable defibrillators (AVID) trial. J Cardiovasc Electrophysiol 2003;14:940-948.
342. Exner DV, Pinski SL, Wyse DG, Renfroe EG, Follmann D, Gold M, Beckman KJ, Coromilas J, Lancaster S, Hallstrom AP, AVID Investigators. Antiarrhythmics versus implantable defibrillators: Electrical storm presages nonsudden death. The antiarrhythmics versus implantable defibrillators (AVID) trial. Circulation 2001;103:2066-2071.
343. Moss AJ, Greenberg H, Case RB, Zareba W, Hall WJ, Brown MW, Daubert JP, McNitt S, Andrews ML, Elkin AD, Multicenter automatic defibrillator implantation trial-II (MADIT-II) Research Group: Long-term clinical course of patients after termination of ventricular tachyarrhythmia by an implanted defibrillator. Circulation 2004;110:3760-3765.
344. Kim RJ, Wu E, Rafael A, Chen EL, Parker MA, Simonetti O, Klocke FJ, Bonow RO, Judd RM: The use of contrast-enhanced magnetic resonance imaging to identify reversible myocardial dysfunction. N Engl J Med 2000;343:1445-1453.
345. Wu E, Judd RM, Vargas JD, Klocke FJ, Bonow RO, Kim RJ: Visualisation of presence, location, and transmural extent of healed Q-wave and non-Q-wave myocardial infarction. Lancet 2001;357:21-28.
346. Wagner A, Mahrholdt H, Holly TA, Elliott MD, Regenfus M, Parker M, Klocke FJ, Bonow RO, Kim RJ, Judd RM: Contrast-enhanced MRI and routine single photon emission computed tomography (SPECT) perfusion imaging for detection of subendocardial myocardial infarcts: An imaging study. Lancet 2003;361:374-379.
347. McCrohon JA, Moon JC, Prasad SK, McKenna WJ, Lorenz CH, Coats AJ, Pennell DJ: Differentiation of heart failure related to dilated cardiomyopathy and coronary artery disease using gadolinium-enhanced cardiovascular magnetic resonance. Circulation 2003;108:54-59.
348. Assomull RG, Prasad SK, Lyne J, Smith G, Burman ED Khan M, Sheppard MN, Poole-Wilson PA, Pennell DJ: Cardiovascular magnetic resonance, fibrosis, and prognosis in dilated cardiomyopathy. J Am Coll Cardiol 2006;48:1977-1985.
349. Schmidt A, Azevedo CF, Cheng A, Gupta SN, Bluemke DA, Foo TK, Gerstenblith G, Weiss RG, Marbán E, Tomaselli GF, Lima JA, Wu KC: Infarct tissue heterogeneity by magnetic resonance imaging identifies enhanced cardiac arrhythmia susceptibility in patients with left ventricular dysfunction. Circulation 2007;115:2006-2014.
350. Codreanu A, Odille F, Aliot E, Marie PY, Magnin-Poull I, Andronache M, Mandry D, Djaballah W, Régent D, Felblinger J, de Chillou C: Electroanatomic characterization of post-infarct scars comparison with 3-dimensional myocardial scar reconstruction based on magnetic resonance imaging. J Am Coll Cardiol 2008;52:839-842.
351. Haghjoo M, HindrickS G, Bode K, Piorkowski C, Bollmann A, Arya A: Initial clinical experience with the new irrigated tip magnetic catheter for ablation of scar-related sustained ventricular tachycardia: A small case series. J Cardiovasc Electrophysiol 2009;20:935-939.
352. Seferovic PM, Ristic AD, Maksimovic R, Petrovic P, Ostojic M, Simeunovic S, Zamaklar D, Simeunovic D, Spodick DH: Initial clinical experience with PerDUCER device: Promising new tool in the diagnosis and treatment of pericardial disease. Clin Cardiol 1999;22:I30-I35.
353. Tucker-Schwartz JM, Gelias GT, Scanavacca M, Sosa E, Mahapatra S. Pressure-frequency sensing subxiphoid access system for use in the percutaneous cardiac electrophysiology: Prototype design and pilot study results. IEEE Trans Biomed Eng 2009;56:1160–1168.
354. Verrier RL, Waxman S, Lovett EG, Moreno R: Transatrial access to the normal pericardial space: A novel approach for diagnostic sampling, pericardiocentesis, and therapeutic interventions. Circulation 1998;98:2331-2333.
355. Kawamura M, Kobayashi Y, Ito H, Onuki T, Miyoshi F, Matsuyama TA, Watanabe N, Ryu S, Asano T, Miyata A, Tanno K, Katagiri T: Epicardial ablation with cooled tip catheter close to the coronary arteries is effective and safe in the porcine heart if the ventricular potential is being monitored in the epicardium and endocardium. Circ J 2006;70:926-932.
356. de Paola AA, Melo WD, Tavora MZ, Martinez EE: Angiographic and electrophysiological substrates for ventricular tachycardia mapping through the coronary veins. Heart 1998;79:59-63.
357. Zenati MA, Shalaby A, Eisenman G, Nosbisch J, McGarvey J, Ota T: Epicardial left ventricular mapping using subxiphoid video pericardioscopy. Ann Thorac Surg 2007;84:2106-2107.
358. Di Biase L, Burkhardt JD, Pelargonio G, Dello Russo A, Casella M, Santarelli P, Horton R, Sanchez J, Gallinghouse JG, Al-Ahmad A, Wang P, Cummings JE, Schweikert RA, Natale A: Prevention of phrenic nerve injury during epicardial ablation: Comparison of methods for separating the phrenic nerve from the epicardial surface. Heart Rhythm 2009;6:957-961.
359. Fenelon G, Pereira KP, de Paola AA: Epicardial radiofrequency ablation of ventricular myocardium: Factors affecting lesion formation and damage to adjacent structures. J Interv Card Electrophysiol 2006;15:57-63.
360. Yokoyama K, Nakagawa H, Shah DC, Lambert H, Leo G, Aeby N, Ikeda N, Pitha JV, Sharma T, Lazzara R, Jackman WM: Novel contact force sensor incorporated in irrigated radiofrequency ablation catheter predicts lesion size and incidence of steam pop and thrombus. Circ Arrhythmia Electrophysiol 2008;1:354-362.
361. Nakagawa H, Antz M, Wong T, Schmidt B, Ernst S, Ouyang F, Vogtmann T, Wu R, Yokoyama K, Lockwood D, Po SS, Beckman KJ, Davies DW, Kuck KH, Jackman WM: Initial experience using a forward directed, high-intensity focused ultrasound balloon catheter for pulmonary vein antrum isolation in patients with atrial fibrillation. J Cardiovas Electrophysiol 2007;18:136-144.
362. Ikeda A, Nakagawa H, Yokoyama K, Jung E, Merino J, Zou Y, Pitha JV, Jackman WM: Novel ultrasound catheter produces deep lesions without thrombus or pop. Heart Rhythm 2008;15:S68. Abstract.

363. Nakagawa H, Yokoyama K, Aoyama H, Foresti S, Pith JV, Lazzara R, Natale A, Jackman WM: Novel balloon catheter technologies for pulmonary vein/antrum isolation. In: Natale A, ed. *Atrial Fibrillation: From Bench to Bedside*, Humana Press, 2008, 363-383.
364. Thiagalingam A, Pouliopoulos J, Barry MA, Boyd AC, Eipper V, Yung T, Ross DL, Kovoor P: Cooled needle catheter ablation creates deeper and wider lesions than irrigated tip catheter ablation. J Cardiovasc Electrophysiol 2005;16:508-515.
365. Sapp JL, Cooper JM, Zei P, Stevenson WG: Large radiofrequency ablation lesions can be created with a retractable infusion-needle catheter. J Cardiovasc Electrophysiol 2006;17:657-661.
366. Christman KL, Fok HH, Sievers RE, Fang Q, Kim AJ, Lee RJ: Myoblasts delivered in an injectable fibrin scaffold improve cardiac function and preserve left ventricular geometry in a chronic myocardial infarction model. Circulation 2003;108:IV-246.
367. Bunch TJ, Mahapatra S, Bruce GK, Johnson SB, Miller DV, Horne BD, Wang XL, Lee HC, Caplice NM, Packer DL: Impact of transforming growth factor-beta 1 on atrioventricular node conduction modification by injected autologous fibroblasts in the canine heart. Circulation 2006;113:2485-2494.
368. Tondato F, Robinson K, Cui J, Sanzo J, Goodchild T, Fowlkes M, Lee R, Maciejevski M, Chronos N, Peters N: Autologous fibroblast transplantation into myocardial infarcts in pigs: Effects on arrhythmogenesis and arrhythmic threshold. J Am Coll Cardiol 2004;43:129A.
369. Tondato F, Robinson K, Maciejewski M, Chronos N, Cui J, Kopelman H, Peters NS: Epicardial fibroblast injection modifies electrical conduction in atrial myocardium. Heart Rhythm 2004;1:S30.
370. Rosen MR, Brink PR, Cohen IS, Robinson RB: Genes, stem cells and biological pacemakers. Cardiovasc Res 2004;64:12-23.
371. D'Avila A, Nellens P, Andries E, Brugada P: Catheter ablation of ventricular tachycardia occurring late after myocardial infarction: A point-of-view. Pacing Clin Electrophysiol 1994;17:532-541.

Appendix

Venice Chart Task Force Composition

Venice Chart Task Force Cochairmen

Andrea Natale, MD, FACC, FHRS, Texas Cardiac Arrhythmia Institute at St. David's Medical Center, Austin, Texas, USA; Division of Cardiology, Stanford University, California, USA; Case Western Reserve University, Cleveland, Ohio, USA; EP Services, California Pacific Medical Center, San Francisco, CA, USA; Antonio Raviele, MD, FESC, Cardiovascular Department, Arrhythmia Center and Center for Atrial Fibrillation, Ospedale dell'Angelo, Venice-Mestre, Italy.

Venice Chart Task Force Working Groups

Epidemiology, classification, and clinical impact of VT/VF

John Camm, MD—*Working Group Chairman*, Cardiac and Vascular Sciences, St. George's Hospital Medical School, London, UK; Amin Al-Ahmad, MD—*Working Group Liaison Member*, Cardiac Arrhythmia Service, Stanford University Medical School, Stanford, USA; David S. Cannom, MD, Good Samaritan Hospital, Los Angeles, USA; Jeronimo Farré, MD, Department of Cardiology, Fundación Jiménez Díaz, Madrid, Spain; Mark E. Josephson, MD, Cardiovascular Division, Department of Cardiology, Beth Israel Deaconess Medical Center, Boston, USA; Hein J.J. Wellens, MD, Cardiovascular Research Institute, Maastricht, The Netherlands.

Anatomy of right/left ventricles and surrounding structures in health and disease

Hugh Calkins, MD—*Working Group Chairman,* Department of Cardiology, The Johns Hopkins Hospital, Baltimore, USA; Siew Yen Ho, MD—*Working Group Liaison Member,* Cardiac Morphology Unit, Royal Brompton Hospital, London, and Imperial College, London, UK; Cristina Basso, MD, Department of Medico-Diagnostic Sciences, Pathological Anatomy, University of Padua Medical School, Padua, Italy; Damian Sánchez-Quintana, MD, Department of Anatomy and Cell Biology, Faculty of Medicine, Badajoz, Spain; Allard C. Van der Wal, MD, Academic Medical Center, Amsterdam, The Netherlands.

Pathophysiology and mechanisms of VT/VF

Etienne Aliot, MD—*Working Group Chairman,* Department of Cardio-Vascular Diseases, CHU de Nancy, Hôpital de Brabois, Vandoeuvre-lès-Nancy, France; Jesus Almendral, MD—*Working Group Liaison Member,* Division of Cardiology, Hospital General Gregorio Maranon, Madrid, Spain; Aldo Bonso, MD, Cardiovascular Department, Ospedale dell'Angelo, Venice-Mestre, Italy; Peng-Sheng Chen, MD, Division of Cardiology, Krannert Institute of Cardiology, Indianapolis, USA; Domenico Corrado, MD, Department of Cardiac, Thoracic and Vascular Sciences, University of Padua, Padua, Italy; Yoshito Iesaka, MD, Tsuchiura Kyodo Hospital, Tsuchiura City, Japan; Andrew Wit, MD, College of Physicians & Surgeons, Columbia University, New York, USA.

ECG features of VT/VF as expression of the underlying mechanisms and site of origin

Josep Brugada, MD—*Working Group Chairman,* Thorax Institute – Cardiology, Clinic of Barcelona, Barcelona, Spain; Paolo Della Bella, MD—*Working Group Liaison Member,* Cardiology Division, Centro Cardiologico Monzino, Milan, Italy; Antonio Berruezo, MD, Cardiology Department, Clinic of Barcelona, Barcelona, Spain; Frank Bogun, MD, Division of Cardiology, University of Michigan, Ann Arbor, USA; Melvin M. Scheinman, MD, Cardiac Electrophysiology, UCSF, San Francisco, USA; Christian Wolpert, MD, Medizinische Klinik, Universitätsklinikum Mannheim, Mannheim, Germany.

Pre- and intraprocedural management

Karl H. Kuck, MD—*Working Group Chairman,* Department of Cardiology, Asklepios Klinik St. Georg, Hamburg, Germany; Kalyanam Shivkumar, MD—*Working Group Liaison Member,* Cardiac Arrhythmia Center, David Geffen School of Medicine at UCLA, Los Angeles, USA; Chi K. Ching, MD, Department of Cardiology, National Heart Centre, Singapore, Singapore; Andrea Corrado, MD, Cardiovascular Department, Ospedale dell'Angelo, Venice-Mestre, Italy; Wyn D. Davies, MD, Cardiology Department, St. Mary's Hospital, London, UK.

Mapping methods for VT/VF ablation

William G. Stevenson, MD—*Working Group Chairman,* Cardiovascular Division, Brigham and Women's Hospital, Boston, USA; David Callans, MD—*Working Group Liaison Member,* Department of Medicine, Section of Cardiovascular Disease, Hospital of the University of Pennsylvania, Philadelphia, USA; Andrea D'Avila, MD, Cardiac Arrhythmia Service, Mount Sinai School of Medicine, New York, USA; Hans Kottkamp, MD, Leitender Rhythmologie Hirslanden, Klinik Hirslanden, Zurich, Switzerland; Eduardo

Sosa, MD, Clinical Arrhythmias and Pacemaker Unit – Heart Institute, University of San Paulo Medical School, San Paulo, Brazil; Yan Yao, MD, Arrhythmia Service Center, Fuwai Heart Hospital, Beijing, China.

Imaging tools, energy sources, and catheters for VT/VF ablation

Vivek Y. Reddy, MD—*Working Group Chairman,* Cardiac Arrhythmia Service, Miller School of Medicine, University of Miami, Miami, USA; Gerhard Hindricks, MD—*Working Group Liaison Member,* University of Leipzig, Heart Center, Department of Cardiology, Leipzig, Germany; Warren M. Jackman, MD, Heart Rhythm Institute, Oklahoma City, USA; Javier E. Sánchez, MD, Texas Cardiac Arrhythmia Institute, St. David's Medical Center, Austin, USA; Richard J. Schilling, MD, St Bartholomew's Hospital, London, UK.

Ablation of VT/VF in patients with structural heart disease: techniques and results

Francis Marchlinski, MD—*Working Group Chairman,* Department of Medicine, Section of Cardiovascular Disease Hospital of the University of Pennsylvania, Philadelphia, USA; Sakis Themistoclakis, MD—*Working Group Liaison Member,* Cardiovascular Department, Ospedale dell'Angelo, Venice-Mestre, Italy; David J. Burkhardt, MD, Texas Cardiac Arrhythmia Institute, St. David's Medical Center, Austin, USA; Eduardo Saad, MD, Center for Atrial Fibrillation, Hospital Pro-Cardiaco, Rio de Janeiro, Brazil; Jaspir Sra, MD, Aurora St. Luke's Medical Centers, University of Wisconsin, Milwaukee, USA; Claudio Tondo, MD, Division of Cardiology, Cardiac Arrhythmia and Heart Failure Institute, San Camillo Forlanini – Università Cattolica, Rome, Italy.

Ablation of VT/VF in patients without structural heart disease: techniques and results

Michel Haïssaguerre, MD—*Working Group Chairman,* Hôpital Cardiologique du Haut Leveque, Bordeaux, France; Riccardo Cappato, MD—*Working Group Liaison Member,* Department of Electrophysiology, Policlinico S. Donato, San Donato Milanese, Italy; Pedro Brugada, MD, Cardiovascular Centre, Heart Rhythm Management Centre, Free University of Brussels, Brussels, Belgium; Etienne Delacrétaz, MD, Swiss Cardiovascular Center, University Hospital, Bern, Switzerland; Henri Hsia, MD, Cardiac Electrophysiology & Arrhythmia Service, Stanford University, Stanford, USA.

Acute and periprocedural complications

David Wilber, MD—*Working Group Chairman,* Department of Cardiology, Loyola University Medical Center, Chicago, USA; Kyoko Soejima, MD—*Working Group Liaison Member,* Cardiovascular Division, University of Miami Hospital, Miami, USA; Young H. Kim, MD, Cardiology and Electrophysiology, Korea University Medical Center, Seoul, South Korea; Antonio Rossillo, MD, Cardiovascular Department, Ospedale dell'Angelo, Venice-Mestre, Italy; Rodolfo Ventura, MD, Klinik und Poliklinik fur Kardiologie und Angiologie, Universitares Herzzentrum, Hamburg, Germany.

Post-VT ablation follow-up management

Jeremy N. Ruskin, MD—*Working Group Chairman,* Arrhythmia Service, Massachusetts General Hospital, Boston, USA; Atul Verma, MD—*Working Group Liaison Member,* Cardiology, Southlake Regional Health Center, Toronto, Canada; Martin Borggrefe, MD, 1st Department of Medicine-Cardiology, University Hospital Mannheim, Mannheim, Germany; Martin J. Schalij, MD, Department of Cardiology, Leiden Hospital, Leiden, The Netherlands; Robert A. Schweikert, MD, Cardiology Department, Akron General Medical Center, Akron, USA.

Surgical ablation

Ottavio Alfieri, MD—*Working Group Chairman,* Department of Cardiac Surgery, Ospedale San Raffaele, Milan, Italy; Gerard M. Guiraudon, MD—*Working Group Liaison Member,* Cardiac Surgery, University of Western Ontario, London, Canada; Roberto De Ponti, MD, Department of Heart Sciences, Fondazione Macchi, Università degli Studi dell'Insubria, Varese, Italy; James R. Edgerton, MD, The Heart Hospital, Dallas, USA; Domenico Mangino, MD, Cardiovascular Department, Ospedale dell'Angelo, Venice-Mestre, Italy.

Indications to VT/VF ablation and hybrid therapy

Eric N. Prystowsky, MD—*Working Group Chairman,* The Care Group, Indianapolis, USA; Gunter Breithardt, MD—*Working Group Liaison Member,* Department of Cardiology and Angiology, Hospital of the University of Münster, Münster, Germany; Stuart J. Connolly, MD, Division of Cardiology, McMaster University, Hamilton, Canada; Josef Kautzner, MD, Department of Cardiology, Ortopedicka Klinika deti a Dospelych 2, Prague, Czech Republic; Chu-Pak Lau, MD, Division of Cardiology, University of Hong Kong – Queen Mary Hospital, Hong Kong, China; Benzy Padanilam, MD, The Care Group, Indianapolis, USA.

Future tools and treatment options

Douglas L. Packer, MD—*Working Group Chairman,* Cardiac Translational Electrophysiology Laboratory, Saint Mary's Hospital Complex, Mayo Clinic and Foundation, Rochester, USA; Mauricio Scanavacca, MD—*Working Group Liaison Member,* Heart Institute, University of San Paulo Medical School, San Paulo, Brazil; Christian de Chillou, MD, Department of Cardiology, Brabois Hospital, Vandoeuvre-lès-Nancy, France; Sabine Ernst, MD, National Heart and Lung Institute, Royal Brompton and Harefield Hospital, Imperial College, London, UK; Hiroshi Nakagawa, MD, Cardiac Arrhythmia Research Institute, University of Oklahoma Health Sciences Center, Oklahoma City, USA.