

# Transperineal Ultrasound for Perianal Fistulas and Abscesses – A Systematic Review and Meta-Analysis

## Transperinealer Ultraschall bei perianalen Fisteln und Abszessen – Systematischer Überblick und Metaanalyse

### Authors

Giovanni Maconi<sup>1</sup>, Maria Teresa Greco<sup>2</sup>, Anil Kumar Asthana<sup>3</sup>

### Affiliations

- 1 Gastroenterology Unit, Department of Biomedical and Clinical Sciences, "L.Sacco" University Hospital, Milan, Italy
- 2 Epidemiological Unit, ATS of the Metropolitan City of Milan, Italy
- 3 Department of Gastroenterology, The Alfred Hospital, Melbourne, Australia

### Key Words

anus, fistula, abscess, perianal, ultrasound, meta-analysis

received 14.02.2016

accepted 16.01.2017

### Bibliography

DOI <http://dx.doi.org/10.1055/s-0043-103954>

Published online: April 11, 2017 | *Ultraschall in Med* 2017; 38: 265–272 © Georg Thieme Verlag KG Stuttgart · New York  
ISSN 0172-4614

### Correspondence

Prof. Giovanni Maconi

Gastroenterology Unit, Department of Biomedical and Clinical Sciences, "L. Sacco" University Hospital

Via GB Grassi, 74

20157 Milan

Italy

Tel.: +39/2/39 04 31 64

Fax: +39/2/39 04 22 32

[giovanni.maconi@unimi.it](mailto:giovanni.maconi@unimi.it)

### ABSTRACT

**Purpose** Transperineal ultrasound (TPUS) is a practical tool for assessing perianal inflammatory lesions. We systematically review its accuracy for detecting and classifying perianal fistulae and abscesses.

**Method** The National Library of Medicine and Embase were searched for articles on TPUS for the assessment of idiopathic and Crohn's perianal fistulae and abscesses. Two reviewers independently reviewed eligible studies and rated them for quality using the QUADAS tool. The primary outcome measure was the accuracy of TPUS as measured by its sensitivity and positive predictive value (PPV) in detecting and classifying perianal fistulae, internal openings and perianal abscesses.

**Results** We included 12 studies (565 patients). Overall, the methodological quality of the studies was suboptimal. 3 studies were retrospective and 4 showed significant risks of bias in the application of the reference standard. The sensitivity of TPUS in detecting perianal fistulae on a per-lesion basis was 98 % (95 % CI 96 – 100 %) and the PPV was 95 % (95 % CI 90 – 98 %). The detection of internal openings had a sensitivity of 91 % (95 % CI 84 – 97 %) with a PPV of 87 % (95 % CI 76 – 95 %). The classification of fistulae yielded a sensitivity of 92 % (95 % CI 85 – 97 %) and a PPV of 92 % (95 % CI 83 – 98 %). TPUS had a sensitivity of 86 % (95 % CI 67 – 99 %) and PPV of 90 % (95 % CI 76 – 99 %) in the detection of perianal abscesses. **Conclusion** The current literature on TPUS illustrates good overall accuracy in the assessment of perianal fistulae and abscesses. However, many studies had methodological flaws suggesting that further research is required.

### ZUSAMMENFASSUNG

**Ziel** Der transperineale Ultraschall (TPUS) ist eine Untersuchungsmethode zur Bewertung von entzündlichen perianalen Läsionen. Wir überprüfen systematisch dessen diagnostische Genauigkeit in Bezug auf Nachweis und Klassifizierung von Perianalfisteln und -abszessen.

**Methoden** Die „National Library of Medicine and Embase“ wurden auf Artikel über TPUS zur Beurteilung von perianalen Fisteln und Abszessen (idiopathisch und bei M. Crohn) untersucht. Zwei Gutachter überprüften unabhängig voneinander geeignete Studien und bewerteten deren Qualität dem QUADAS Werkzeug. Der primäre Endpunkt war die Genauigkeit des TPUS, ausgedrückt durch Sensitivität und positiver Vorhersagewert (PPV) in Bezug auf Nachweis und Klassifizierung von Perianalfisteln, inneren Öffnungen und perianalen Abszessen.

**Ergebnisse** Wir schlossen 12 Studien (565 Patienten) ein. Insgesamt gesehen war die methodische Qualität der Studien suboptimal; 3 waren retrospektiv und 4 hatten ein signifikantes Bias-Risiko bezüglich der Anwendung von Referenzstandards. Die Sensitivität des TPUS beim Nachweis perianaler Fisteln auf Läsionsbasis betrug 98 % (95 % CI: 96 – 100), der PPV war 95 % (95 % CI: 90 – 98). Bei der Erkennung innerer Öffnungen zeigte sich eine Sensitivität von 91 % (95 % CI: 84 – 97) und ein PPV von 87 % (95 % CI: 76 – 95); Die Klassifizierung von Fisteln ergab eine Sensitivität von 92 % (95 % CI: 85 – 97) und

einen PPV von 92 % (95 % CI: 83 – 98). Eine Sensitivität von 86 % (95 % CI: 67 – 99) und ein PPV von 90 % (95 % CI: 76 – 99) hatte TPUS beim Nachweis von Perianalabszessen.

**Schlussfolgerung** Die aktuelle TPUS-Literatur zeigt eine insgesamt gute Genauigkeit bei der Beurteilung von Perianalfis-

teln und -abszessen. Allerdings hatten viele Studien methodische Mängel, was darauf hindeutet, dass weitere Forschungsarbeiten erforderlich sind.

## Introduction

### Rationale

Inflammatory perianal lesions are debilitating conditions which include hidradenitis suppurativa, acne conglobata, pilonidal sinus and, in particular, perianal fistulae and abscesses. Their differentiation relies on a combination of a thorough medical history, physical examination and diagnostic imaging. The latter is frequently used in inconclusive cases, especially for characterizing perianal lesions and differentiating pilonidal sinuses from other superficial cutaneous or subcutaneous diseases such as perianal fistulae and abscesses. Perianal fistulae are the most common of these conditions and the majority of them arise from either the cryptoglandular category (90 %) or Crohn's disease [1]. Both of these lesions are chronic granulation tissue tracts connecting the anal canal and perianal skin, but may demonstrate different anatomical and pathogenetic features and consequently have different clinical outcomes. Perianal fistulae have a tendency to recur. This recurrence can occur due to initial misclassification, missed infections during surgery, especially for cryptoglandular fistulae, as well as due to an insufficient response to medical treatment in Crohn's disease where fistulae can occur in 40 – 70 % of patients [2, 3].

Therefore, the treatment of perianal inflammatory lesions varies according to their underlying nature. The etiology of perianal fistulae is dependent upon whether the underlying process is cryptogenic or Crohn's disease-related and upon its classification. This latter point takes into account several aspects, such as the anatomical site of internal openings, the course of fistulae in relation to anal sphincters and, in particular, the presence of extensions, branches and perianal abscesses.

The main diagnostic tools currently in use to classify perianal fistulae include transanal ultrasound, magnetic resonance imaging (MRI) and examination under anesthesia (EUA).

More recently, transperineal ultrasound (TPUS) has been proposed as a low-cost, easily available, noninvasive and accurate tool when these procedures are contraindicated or not available. First described for the examination of pregnant patients [4] and young children [5] to evaluate distal anorectal and perirectal abnormalities, it has been used for the detection and classification of perianal inflammatory lesions and in particular for perianal fistulae [6 – 8] (► Fig. 1 – 3s). However, despite the advantages of this procedure, it has not found a concrete role in the diagnostic work-up or follow-up of patients with perianal fistulae to date.

### Objective

Thus, the purpose of our study was to systematically review the accuracy of transperineal ultrasound in detecting perianal diseases, assessing the presence of perianal fistulae or abscesses and classifying these lesions using standard diagnostic tools such as MRI, endoscopic ultrasound or surgery as gold standards.

## Methods

### Search strategy and study eligibility

A computer-assisted search was performed using the MEDLINE and EMBASE databases to identify articles reporting the accuracy of TPUS in detecting and classifying perianal fistulae, perianal abscesses, hidradenitis suppurativa, acne conglobata and pilonidal sinus. In MEDLINE and EMBASE, we used the following terms "transperineal OR perineal OR perianal" combined with "ultrasound OR sonography" and "fistulae OR fistulas OR abscesses OR sepsis OR hidradenitis suppurativa OR acne conglobata OR pilonidal sinus" as search terms.

The search period was restricted to January 1990 through June 2016. No age limits were applied, but the literature was limited to the English language.

Titles and/or abstracts of all retrieved articles were checked by one observer (GM) to determine eligibility for inclusion. Reference lists of review articles and eligible studies were checked manually to identify other relevant papers. Irrelevant articles evident from the titles and abstracts were excluded. Only data that was presented as full-text articles were eligible for inclusion.

### Study selection

Two reviewers (AKA and GM) independently checked all retrieved articles to check whether they satisfied the following inclusion criteria:

1. To provide data on diagnostic accuracy and with sufficient data to develop a two-by-two table for sensitivity, specificity, PPV or NPV calculations of TPUS;
2. To assess patients with a clinical suspicion of perianal fistulae or abscesses as primary endpoints;
3. To compare TPUS findings with those obtained at MRI, endoscopic ultrasound and/or intraoperative findings (exam under anesthesia); these were considered as the reference standard to assess perianal fistulae and abscess, considering their comparable accuracy, and in particular for their high sensitivity in detecting these lesions [9, 10].



We therefore excluded case studies, studies with insufficient data to develop sensitivity, specificity, PPV or NPV calculations, those focused on methodological techniques or on ultrasonographic signs, those focused on treatment options and studies that were not designed for primary research.

### Study quality assessment

To assess the study quality characteristics, the QUADAS (quality assessment for studies of diagnostic accuracy) guidelines were used. The QUADAS is an 11-item tool, developed and recommended by the Cochrane Collaboration Methods group to evaluate the quality of studies, especially for diagnostic accuracy [11]. In particular, the following characteristics were assessed:

1. Whether the spectrum of patients was representative of those who would receive TPUS in clinical practice (patient spectrum);
2. If the selection criteria were clearly described (selection criteria);
3. If the reference standard was likely to detect and classify the target condition correctly (reference standard);
4. Whether the time period between TPUS and the reference standard was short enough to reasonably ensure that the condition did not change between these two tests (time period);
5. Whether all patients or a sample of patients received verification using a reference standard (partial verification);
6. Whether patients received the same reference standard regardless of the index test result (different verification);
7. If the reference standard was independent of the index test (incorporation bias);
8. Whether the execution of the TPUS was described in sufficient detail to permit its replication (index test execution);
9. Whether the execution of the reference standard was described in sufficient detail to permit its replication accuracy (reference standard execution);
10. Whether the TPUS results were interpreted without knowledge of the results of the reference standard (blind interpretation: index test);
11. Whether the reference standard results were interpreted without knowledge of the results of the index test (blind interpretation: reference standard);
12. Whether the same clinical data was available when the results were interpreted as would be available in clinical practice (clinical information);
13. Whether uninterpretable/intermediate test results were reported (uninterpretable/ intermediate results);
14. Whether withdrawals from the study were explained (withdrawals);

When there was disagreement between the reviewers regarding aspects of the QUADAS answers, consensus was reached via discussion. Studies were considered of a high-quality level if the QUADAS score was  $\geq 8$ .

### Study characteristics

Both reviewers independently assessed characteristics of the included studies and extracted relevant data, as described in detail below.

The following patient characteristics were recorded: number of patients; sex ratio distribution; mean age (range); patient spectrum and selection criteria (e.g., Crohn's disease related or not), gold standard used; type of study design (prospective or retrospective).

Moreover the outcomes were reported as follows:

- accuracy in the detection of fistulae (sensitivity, specificity, positive predictive value or negative predictive value) on a per-lesion basis.
- accuracy in the classification of fistulae according to the Parks criteria (and reported as overall sensitivity, specificity, positive predictive value or negative predictive value)
- accuracy in the detection of internal openings.
- accuracy in the detection of abscesses on a per-patient basis (namely sensitivity, specificity, positive predictive value or negative predictive value in discriminating patients with perianal abscesses).

### Statistical analysis

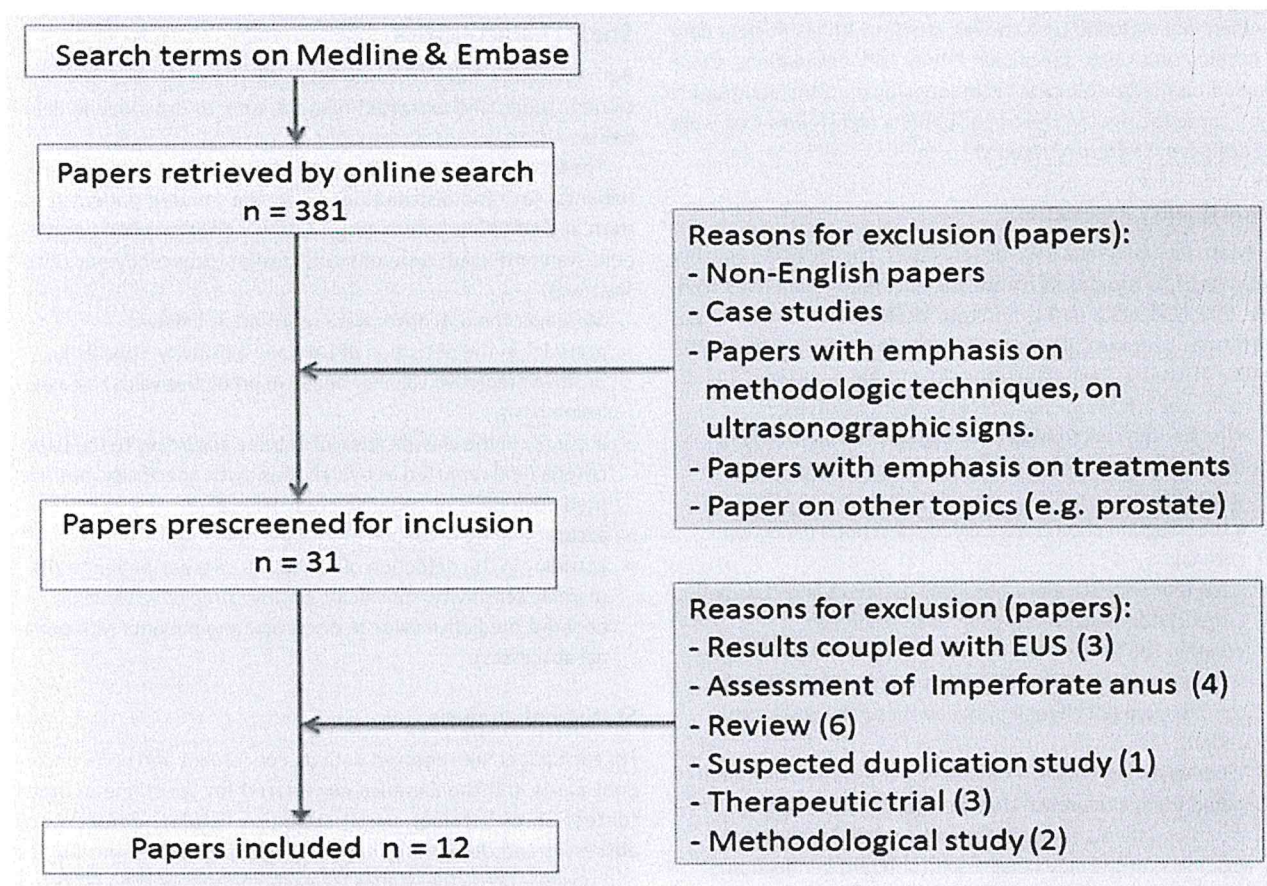
For each paper, we reported data on concordant and non-concordant cases and the samples considered for specific outcomes (detection of fistulae, classification of fistulae, detection of abscesses and detection of internal openings). The sensitivities and positive predictive values for each study were then reported and the pooled sensitivity was estimated using a specific meta-analysis of binomial data as previously reported [12]. In particular, we estimated the pooled sensitivity and its 95% confidence intervals using a random-effects model [13]. To investigate whether the variation in prevalence rates between studies was more than could be attributed to chance alone, the I-square test and  $\chi^2$  test for homogeneity were calculated. We conducted subgroup analyses according to the variables: gold standard, categorized as MRI, EUA or TRUS, and presence of Crohn's disease. We assessed publication bias with a funnel plot and Egger test and no publication bias was determined. All analyses were performed using the program Stata 11, a new program to perform meta-analyses of binomial data (2009, StataCorp LP, College Station, TX) [12]. It allows computation of 95% confidence intervals using the score statistic and the exact binomial method as well as incorporating the Freeman-Tukey double arcsine transformation of proportions. The program also allows the within-study variability to be modeled using binomial distribution. In order to include studies with 0% or 100% sensitivity in the meta-analysis, the continuity correction option has been used.

## Results

### Search strategy and study population

The search strategy resulted in 381 articles. 31 were eligible and retrieved as full texts for further analysis. 12 papers ultimately





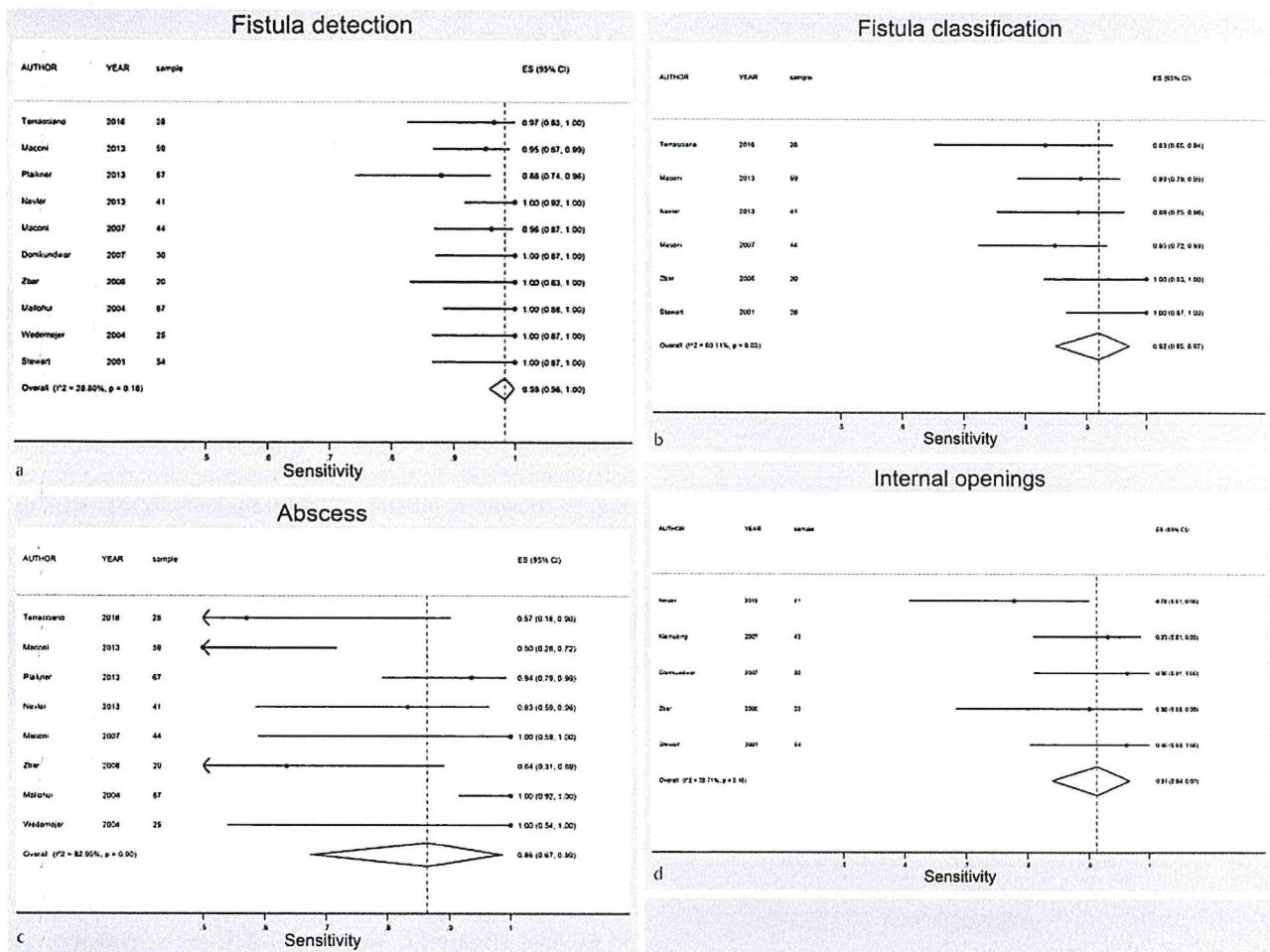
► Fig. 1 Flow diagram for the selection of the studies included in this systematic review.

► Table 1 Characteristics and outcomes of studies.

author [ref]	design	gold standard	aims	fistula etiology (CD/other)	no. of pts	TPUS operator	sex (M/F)	mean age (range or SD)
Terracciano 2016 [22]	P	MRI	FD, FC, AD	28/0	28	Gas	17/11	37.6 (16.0)
Maconi 2013 [21]	P	MRI	FD, FC, AD	59/0	59	Gas	27/32	39 (19–72)
Plaikner 2013 [20]	R	MRI-EUA	FD, FC, AD	N.R.	67	Rad	40/27	44 (14.7)
Nevler 2013 [19]	R	EUA	FD, FC, IO, AD	14/27	41	Gas	28/13	34.5 (4–75)
Iverson 2012 [18]	P	NONE	AD	N.R.	67	N.R.	25/42	6 (0.5–18)
Kleinubing 2007 [17]	P	EUA	IO	0/43	43	Sur	32/11	39 (19–76)
Maconi 2007 [16]	P	TRUS	FD, FC, AD, AC	44/0	44	Gas	21/23	37 (16–72)
Domkundwar 2007 [15]	R	FUP-EUA	FD, AD, IO	0/30	30	N.R.	26/4	37 (24–56)
Zbar 2006 [8]	P	EUA	FD, AD, IO	0/20	20	Sur	15/5	45.5 (28–82)
Mallohui 2004 [14]	P	EUA/MRI/FUP	FD, AD	19/68	87	Rad	54/33	45 (16–90)
Wedemejer 2004 [7]	P	MRI	FD, FC, AD, AC	25/0	25	Gas	17/8	36.2 (2.5)
Stewart 2001 [6]	P	EUA/FUP	FD, FC, IO, AD	28/26	54	Rad	28/26	N.R. (23–69)

P: prospective; R: retrospective; CD: Crohn's disease; N.R.: not reported; SD: standard deviation; MRI: magnetic resonance imaging; EUA: exam under anesthesia; TRUS: transrectal ultrasound; FUP: follow-up; FD: fistula detection; FC: fistula classification; AD: abscess detection; IO: internal opening; Gas: gastroenterologist; Rad: radiologist; Surg: surgeon.





► Fig. 2 a Sensitivity for perianal fistula detection. b Sensitivity for perianal fistula classification. c Sensitivity for perianal abscess detection. d Sensitivity for internal opening detection.

fulfilled all inclusion criteria and were used for data extraction and data analysis (► Fig. 1) [6–8, 14–22].

The studies included 565 patients (330 males; mean age of 36.4 years), 217 (38.4%) of whom had perianal Crohn's disease (► Table 1). Overall, the methodological quality of the studies was suboptimal, with 6 having a QUADAS score  $\geq 8$  (► Table 1s). 3 studies were retrospective and among the remaining prospective ones, 4 showed significant risks of bias in the application of the reference standard. With respect to this point, the reference standard varied significantly among the studies. Most used EUA (7 studies) or MRI (5 studies) but only 5 provided an accurate description and in 4 studies the reference standard results were interpreted without knowledge of the TPUS results. Moreover, the time period between the reference standard and TPUS was short enough (<2 weeks) to be reasonably certain that the condition would not have changed over time in only 5 studies.

TPUS sonographers in these studies were gastroenterologists, radiologists or surgeons.

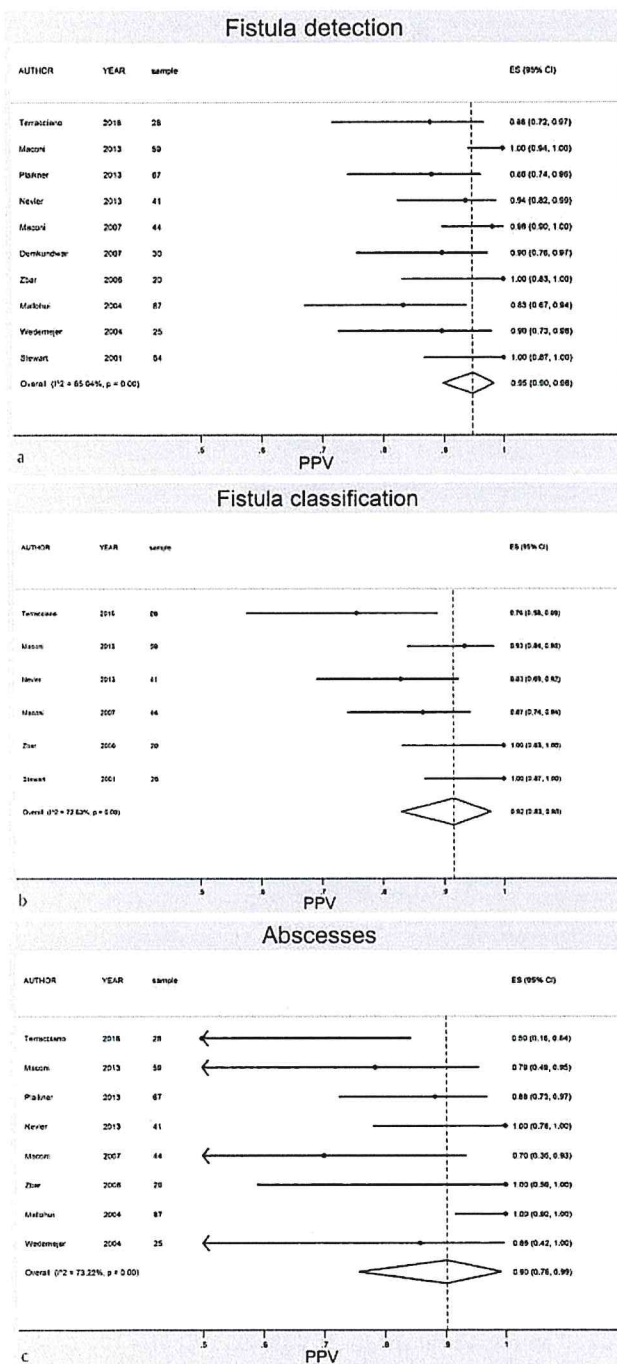
All studies provided an accurate description of TPUS (► Table 1).

## Detection of fistulae

10 studies [6–8, 14–22] assessed the accuracy of TPUS in the detection of perianal fistulae and all of these provided sensitivity values compared with a reference standard (► Fig. 2). The sensitivity of TPUS in detecting perianal fistula on a per-lesion basis ranged from 88.1% to 100% with positive predictive values ranging from 83.3% to 100% (► Fig. 3). Pooled results of these studies showed an overall sensitivity of 98% (95% CI 96–100%) and positive predictive value of 95% (95% CI 90–98%) (► Fig. 2, 3, ► Table 2s).

6 studies [6, 7, 16, 19, 21, 22], which provided data on TPUS fistulae detection in Crohn's disease patients, showed a mean sensitivity value of 99.0% (95% CI 96–100%) (► Table 2).

The sensitivity for fistulae detection by TPUS was also high (>96%) and not significantly different according to the diagnostic tool used as the gold standard (► Table 2), with a not significant heterogeneity amongst these studies.



► Fig. 3 a Positive predictive value for perianal fistula detection. b Positive predictive value for perianal fistula classification. c Positive predictive value for perianal abscess detection.

### Detection of internal openings

5 studies [6, 8, 14, 15, 17, 19] investigated the accuracy of TPUS in assessing internal openings (► Fig. 2) giving a pooled sensitivity of 91 % (95 % CI 84 – 97 %) (► Fig. 2). Only two studies provided data suitable for the PPV analysis and the mean was 87 % (95 % CI 76 – 95 %) (► Table 2s). With respect to the assessment of internal

openings in Crohn's disease, the estimated pooled sensitivity was 87 % (95 % CI 77 – 94 %), (► Table 2).

### Classification of fistulae

6 studies [6, 8, 16, 19, 21, 22] assessed the accuracy of TPUS in the classification of fistulae showing a sensitivity range from 83 % to 100 % (► Fig. 2) and a positive predictive value range from 76 % to 100 % (► Fig. 3). Pooled results of these studies show a sensitivity of 92 % (95 % CI 85 – 97 %) and a positive predictive value of 92 % (95 % CI 83 – 98 %) (► Table 2s).

6 studies provided data about TPUS in the classification of fistulae in Crohn's disease patients [6, 7, 16, 19, 21, 22], and showed an average sensitivity of 90 % (95 % CI 83 – 95 %). The sensitivity for the classification of fistulae was higher when the comparator was exam under anesthesia (98 %) than transrectal ultrasound or MRI (87 %) (► Table 2). However, all of these assessments showed a substantial heterogeneity across studies ( $I^2 > 60\%$ ).

### Detection of abscesses

The presence of abscesses was detected and found in 11 studies. However, only 8 studies provided data suitable for the sensitivity analysis (where 190 out of 490 patients showed perianal abscesses). These studies showed a wide variability in the prevalence of this complication ranging from 16 % to 72.3 % (mean: 40.7 %). The accuracy of TPUS in the detection of perianal abscesses was assessed in 9 studies [7, 8, 14, 16, 18 – 22]. Pooled results of these studies showed a sensitivity of 86 % (95 % CI 67 – 99 %) and a positive predictive value of 90 % (95 % CI 76 – 99 %).

Considering the 5 studies that assessed this complication in Crohn's disease [7, 16, 19, 21, 22], the sensitivity was 88 %. As compared to the gold standard used, the sensitivity in patients assessed by MRI seemed to be lower (80%; IC 95 % 47 – 100 %) than that assessed by EUA (88%; IC 95 % 56 – 100 %) (► Table 2, 3s). However, all of these assessments showed significant heterogeneity across studies ( $I^2 > 73\%$ ).

## Discussion

### Summary of evidence

Perianal disease is a disabling condition and can be caused by different etiologies, including inflammatory bowel disease, hidradenitis suppurativa and acne conglobata. Imaging is an essential part of the management, in particular for primary diagnosis.

TPUS is a useful option in this case but its role in clinical care has not been optimally established. There has been no previous systematic review published on this subject and therefore we systematically reviewed the existing medical literature evaluating the utility of TPUS in patients with perianal pathologies. This study was conducted to critically appraise the current literature in this area with the goal of identifying clinical situations in which TPUS can be recommended. Our systematic review showed that TPUS overall has a high degree of accuracy in diagnosing the presence of fistulae, ascertaining the classification of fistulae, locating the



▶ **Table 2** Pooled sensitivity by Crohn's disease and gold standard.

subgroup analysis	fistula detection		internal openings		fistula classification		abscesses	
	sensitivity (%; 95% CI)	test for heterogeneity (p-value)	sensitivity (%; 95% CI)	test for heterogeneity (p-value)	sensitivity (%; 95% CI)	test for heterogeneity (p-value)	sensitivity (%; 95% CI)	test for heterogeneity (p-value)
Crohn's disease								
yes	99, 96–100	0.52	87, 77–94	0.01	90, 83–95	0.08	88, 62–100	<0.001
no	98, 87–100	0.04	94, 87–98	0.71	100, 83–100	1	89, 76–97	<0.001
gold standard								
MRI	96, 90–99	0.18	NA		87, 80–94	<0.001	80, 47–100	<0.001
EUA	99, 98–100	0.99			98, 87–100	<0.001	88, 56–100	<0.001

NA = Studies including only in 1 category.  
<sup>1</sup> Only 1 study.

position of the fistulous internal opening and determining the presence of abscesses. The pooled sensitivity for the detection of perianal fistulae using TPUS was 98% (95% CI 96–100%) and the positive predictive value of 95% (95% CI 90–98%). Similarly, a high degree of accuracy for perianal fistulae classification has been found with a pooled sensitivity and PPV of 92% [6–8, 11–18]. Overall, the studies revealed lower sensitivities and PPVs for extrasphincteric fistulae [16, 19, 21]. On the contrary to fistulae detection, the results for abscess detection were heterogeneous with sensitivities ranging from 50–100% [6–8, 14–22] and PPVs ranging from 70–100% [6–8, 14–22]. Despite the results reflecting a high degree of accuracy for using TPUS in perianal fistulae and abscesses, the level of evidence on which to base its universal clinical utility remains suboptimal. The quality of many of the included studies was suboptimal with 6 out of 12 studies attaining a QUADAS score <8. 9 studies were prospective in nature, and 4 studies showed a significant incorporation bias, with the reference standard being dependent on the TPUS exam result [6, 14, 15, 18]. The gold standard for the correlation of ultrasonographic fistulae differed considerably among the studies: 6 studies used examination under anesthesia as the reference test [6, 8, 15, 17, 19, 20] while the remaining studies used either MRI scanning or EUS/endoanal ultrasound. This significantly affected the statistical heterogeneity of the results. In fact, we found a substantial heterogeneity among studies of the systematic review ( $I^2$  varied between 29% and 83%) also when these were grouped according to the gold standard used, MRI or EUA, or to the underlying disease (Crohn's disease or not). Given the high heterogeneity, it might have been inappropriate or unnecessary to do a meta-analysis. Moreover, the results should be viewed with caution for the same reason.

Another potential source of variability is that ultrasonography is operator-dependent and one significant limitation of most of the included studies is that they did not state the experience of the operator. This is important, on a practical note, because the more experienced the operator, the lower the chances of inter-operator variability and therefore the greater the reliability of the results. From the data, it can be seen that TPUS has an accurate correlation with MRI and other forms of imaging with regard to perianal fistula detection and classification. This is based on three prospective and methodologically sound studies [16, 21, 22]. TPUS has also demonstrated a high correlation in the detection of superficial (transsphincteric and intersphincteric) fistulae compared to deeper ones (extrasphincteric) [16, 19, 21, 22]. This would be expected, from a technical point of view, as the probe used for perianal examinations is a high-frequency one and sensitivity for detection of deeper abnormalities would be limited. Our data would also suggest that the accuracy for the detection of perianal pathologies does not appear to be dependent upon the underlying disease process [19]. This question needs to be further explored, however, with high-quality evidence. Based on the higher quality studies in our review, it can be said that TPUS is an accurate imaging modality, comparable to MRI for perianal fistulae detection and classification and abscess detection [7, 16, 21, 22]. This has significant clinical implications, i. e., the use of TPUS as a first-line investigation for perianal fistulae and abscesses provided the appropriate expertise is present. This would prob-



ably result in time and cost-savings due to the accessibility and cost-effectiveness of this ultrasound imaging method, in particular in Crohn's disease [23].

#### Limitation and conclusion

The limitations of this study include the fact that only English-language literature was evaluated, that the number of studies and patients is relatively small and that heterogeneity among studies was very high in terms of the reference standard used, kind of population examined and quality of the studies. All of these limitations might have had some impact on the significance of the results. On the other hand, one strength of our review is that the methods include the use of the QUADAS tool for quality assessment of the studies, which is a validated method. Another strength of this review was that our endpoint was not solely fistula detection, but it included fistula classification and internal opening and abscess detection rates.

TPUS fulfils the characteristics of an ideal diagnostic procedure – it is cheap, noninvasive, portable and rapid [16]. Both the European Crohn's and Colitis Organisation (ECCO) and the American Society of Colon and Rectal Surgeons have not endorsed the use of TPUS in patients with perianal disease [24, 25]. Other imaging modalities are advised, such as EAUS and MRI imaging. Our systematic review illustrates that TPUS is accurate and comparable to MRI scans with respect to perianal fistula detection and can thus be used as a first-line modality for perianal pathology. This is provided that the appropriate expertise is present on-site. On the same token, it is essential that the limitations of this diagnostic test are taken into consideration to ensure the right patient selection. The individual studies in this review that assessed the accuracy of TPUS in relation to surgical findings were of sub-optimal quality and this is thus an area for improvement in the future. It is recommended to conduct well-designed prospective studies to answer this question further. In conclusion, TPUS is an accurate imaging modality for perianal fistula detection, fistula classification and abscess detection and ought to be considered as a first-line imaging tool.

#### Conflict of Interest

The authors declare that they have no conflict of interest.

#### References

- [1] Sainio P. Fistula-in-ano in a defined population. Incidence and epidemiological aspects. *Ann Chir Gynaecol* 1984; 73: 219–224
- [2] Hellers G, Bergstrand O, Ewerth S et al. Occurrence and outcome after primary treatment of anal fistulae in Crohn's disease. *Gut* 1980; 21: 525–527
- [3] Schwartz DA, Loftus EV Jr, Tremaine WJ et al. The natural history of fistulizing Crohn's disease in Olmsted County, Minnesota. *Gastroenterology* 2002; 122: 875–880
- [4] Hertzberg BS, Bowie JD, Weber TM et al. Sonography of the cervix during the third trimester of pregnancy: value of the transperineal approach. *Am J Roentgenol* 1991; 157: 73–76
- [5] Teele RL, Share JC. Transperineal sonography in children. *Am J Roentgenol* 1997; 168: 1263–1267
- [6] Stewart LK, McGee J, Wilson SR. Transperineal and transvaginal sonography of perianal inflammatory disease. *Am J Roentgenol* 2001; 177: 627–632
- [7] Wedemeyer J, Kirchoff T, Sellge G et al. Transcutaneous perianal sonography: a sensitive method for the detection of perianal inflammatory lesions in Crohn's disease. *World J Gastroenterol* 2004; 10: 2859–2863
- [8] Zbar AP, Oyetunji RO, Gill R. Transperineal versus hydrogen peroxide-enhanced endoanal ultrasonography in never operated and recurrent cryptogenic fistula-in-ano: a pilot study. *Tech Coloproctol* 2006; 10: 297–302
- [9] Schwartz DA, Wiersema MJ, Dudiak KM et al. A comparison of endoscopic ultrasound, magnetic resonance imaging, and exam under anesthesia for evaluation of Crohn's perianal fistulas. *Gastroenterology* 2001; 121: 1064–1072
- [10] Siddiqui MR, Ashrafian H, Tozer P et al. A diagnostic accuracy meta-analysis of endoanal ultrasound and MRI for perianal fistula assessment. *Dis Colon Rectum* 2012; 55: 576–585
- [11] Whiting P, Rutjes AW, Dinnes J et al. Development and validation of methods for assessing the quality of diagnostic accuracy studies. *Health Technol Assess* 2004; 8: 1–234
- [12] Nyaga VN, Arbyn M, Aerts M. Metaprop: a Stata command to perform meta-analysis of binomial data. *Arch Public Health* 2014; 72: 39
- [13] DerSimonian R, Laird N. Meta-analysis in clinical trials. *Control Clin Trials* 1986; 7: 177–188
- [14] Mallouhi A, Bonatti H, Peer S et al. Detection and characterization of perianal inflammatory disease: accuracy of transperineal combined gray scale and color Doppler sonography. *J Ultrasound Med* 2004; 23: 19–27
- [15] Domkundwar SV, Shinagare AB. Role of transcutaneous perianal ultrasonography in evaluation of fistulas in ano. *J Ultrasound Med* 2007; 26: 29–36
- [16] Maconi G, Ardizzone S, Greco S et al. Transperineal ultrasound in the detection of perianal and rectovaginal fistulae in Crohn's disease. *Am J Gastroenterol* 2007; 102: 2214–2219
- [17] Kleinübung H Jr, Jannini JF, Campos AC et al. The role of transperineal ultrasonography in the assessment of the internal opening of cryptogenic anal fistula. *Tech Coloproctol* 2007; 11: 327–331
- [18] Iverson K, Haritos D, Thomas R et al. The effect of bedside ultrasound on diagnosis and management of soft tissue infections in a pediatric ED. *Am J Emerg Med* 2012; 30: 1347–1351
- [19] Nevler A, Beer-Gabel M, Lebedyev A et al. Transperineal ultrasonography in perianal Crohn's disease and recurrent cryptogenic fistula-in-ano. *Colorectal Dis* 2013; 15: 1011–1018
- [20] Plaikner M, Loizides A, Peer S et al. Transperineal ultrasonography as a complementary diagnostic tool in identifying acute perianal sepsis. *Tech Coloproctol* 2014; 18: 165–171
- [21] Maconi G, Tonolini M, Monteleone M et al. Transperineal perineal ultrasound versus magnetic resonance imaging in the assessment of perianal Crohn's disease. *Inflamm Bowel Dis* 2013; 19: 2737–2743
- [22] Terracciano F, Scalisi G, Bossa F et al. Transperineal ultrasonography: First level exam in IBD patients with perianal disease. *Dig Liver Dis* 2016; 48: 874–879
- [23] Botti F, Losco A, Viganò C et al. Imaging techniques and combined medical and surgical treatment of perianal Crohn's disease. *J Ultrasound* 2013; 18: 19–35
- [24] Van Assche G, Dignass A, Reinisch W et al. The second European evidence-based Consensus on the diagnosis and management of Crohn's disease: Special situations. *Journal of Crohn's & Colitis* 2010; 4: 63–101
- [25] Steele SR, Kumar R, Feingold DL et al. Practice parameters for the management of perianal abscess and fistula-in-ano. *Diseases of the Colon and Rectum* 2011; 54: 1465–1474