



# UNIVERSITÀ DEGLI STUDI DI MILANO

Corso di Dottorato in Scienze odontostomatologiche  
Ciclo XXIX

Dipartimento di Scienze biomediche, chirurgiche ed odontoiatriche

MED/28

## FROM BENCH TO CHAIRSIDE: EVALUATION OF BIOLOGICAL EFFECTS OF PLATELET CONCENTRATES THROUGH AN IN-VITRO STUDY AND A RANDOMIZED CLINICAL TRIAL

Alessandra Lolato  
Matricola n. R10641

Tutor:  
Chiar.mo Prof. Massimo Del Fabbro

Correlatore:  
Dott. Silvio L. M. Taschieri

Coordinatore del Corso di Dottorato:  
Chiar.mo Prof. Massimo Del Fabbro

A.A. 2015-2016

*Alla mia mamma Giuliana, al mio papà Roberto*

*e ai miei fratelli Federica, Edoardo e Filippo*

*Per aspera ad astra*

# TABLE OF CONTENTS

|  |           |
|--|-----------|
| <b>ABSTRACT</b>  | <b>5</b>  |
| <b>CHAPTER I: INTRODUCTION</b>   | <b>8</b>  |
| <b>1.1 Autologous platelet concentrates</b>  | <b>9</b>  |
| <i>1.1.1 General aspects</i>   | <b>9</b>  |
| <i>1.1.2 History of the medical use of platelet concentrates</i>   | <b>10</b> |
| 1.1.2.1 <i>Fibrin adhesives</i>  | <b>10</b> |
| 1.1.2.2 <i>Platelet-Rich Plasma</i>  | <b>11</b> |
| 1.1.2.3 <i>Platelet-Rich Fibrin</i>  | <b>12</b> |
| 1.1.2.4 <i>Platelet-Rich in Growth Factors</i>   | <b>13</b> |
| <i>1.1.3 Technical differences between PRGF, PRP and PRF</i>   | <b>14</b> |
| <i>1.1.4 Current classifications of autologous platelet concentrates</i>   | <b>15</b> |
| 1.1.4.1 <i>Dohan Ehrenfest classification</i>  | <b>15</b> |
| 1.1.4.2 <i>Mishra classification</i>   | <b>16</b> |
| 1.1.4.3 <i>PAW classification</i>  | <b>17</b> |
| <b>1.2 Clinical evidence of the efficacy of autologous platelet concentrates in oral regenerative procedures</b> | <b>18</b> |
| <i>1.2.1 General aspects</i>   | <b>18</b> |
| <i>1.2.2 Alveolar post-extraction healing</i>  | <b>18</b> |
| <i>1.2.3 Periodontal defects</i>   | <b>19</b> |
| <i>1.2.4 Endodontics</i>   | <b>19</b> |
| <i>1.2.5 Sinus lift augmentation</i>   | <b>20</b> |
| <i>1.2.6 Implantology</i>  | <b>20</b> |

|   |           |
|---|-----------|
| <b>1.3 Management of reduced residual crestal height. Long implants in augmented sinus or short implant without augmentation?</b> | <b>22</b> |
| <b>1.4 Rationale of the thesis</b>  | <b>24</b> |
| <i>1.4.1 Pre-clinical findings on P-PRP</i>   | 24        |
| <i>1.4.2 Clinical findings on P-PRP</i>   | 24        |
| <b>1.5 Aims of thesis</b>   | <b>25</b> |
| <b>CHAPTER II: MATERIALS AND METHODS</b>  | <b>27</b> |
| <b>2.1 In-vitro study</b>   | <b>28</b> |
| <i>2.1.1 Preparation of Pure-Platelet Rich Plasma (P-PRP)</i>   | 28        |
| <i>2.1.2 Cell cultures</i>  | 28        |
| <i>2.1.3 Cell proliferation and viability</i>   | 29        |
| <i>2.1.4 Osteogenic differentiation</i>   | 30        |
| <i>2.1.5 Statistical analysis</i>   | 30        |
| <b>2.2 Randomized clinical study</b>  | <b>31</b> |
| <i>2.2.1 Patients inclusion criteria</i>  | 31        |
| <i>2.2.2 Patients exclusion criteria</i>  | 31        |
| <i>2.2.3 Study design</i>   | 32        |
| <i>2.2.4 Sinus surgery</i>  | 32        |
| <i>2.2.5 Implant surgery</i>  | 33        |
| <i>2.2.5.1 Preparation of P-PRP</i>   | 33        |
| <i>2.2.5.2 Surgical procedure</i>   | 33        |
| <i>2.2.6 Prosthetic phase</i>   | 34        |
| <i>2.2.7 Radiographic examination</i>   | 34        |
| <i>2.2.8 Primary and secondary outcomes</i>   | 35        |
| <i>2.2.9 Statistical analysis</i>   | 35        |

|  |           |
|--|-----------|
| <b>CHAPTER III: RESULTS</b>                                      | <b>36</b> |
| <b>3.1 In-vitro study</b>  | <b>37</b> |
| <i>3.1.1 Platelet concentration of Pure-Platelet Rich Plasma</i> | 37        |
| <i>3.1.2 Cell proliferation of hObs and hDFs</i>                 | 37        |
| <i>3.1.3 Cell viability of hObs and hDFs</i>                     | 39        |
| <i>3.1.4 Osteogenic differentiation of hObs</i>                  | 39        |
| <b>3.2 Randomized clinical study</b>                             | <b>41</b> |
| <i>3.2.1 Patient population and intervention characteristics</i> | 41        |
| <i>3.2.2 Implant and prosthesis survival</i>                     | 44        |
| <i>3.2.3 Peri-implant marginal bone level changes</i>            | 45        |
| <i>3.2.4 Evaluation of clinical parameters</i>                   | 46        |
| <b>CHAPTER IV: DISCUSSION</b>                                    | <b>47</b> |
| <b>CHAPTER V: CONCLUSIONS</b>                                    | <b>52</b> |
| <b>CHAPTER VI: REFERENCES</b>                                    | <b>54</b> |
| <b>CHAPTER VII: ACKNOWLEDGMENTS</b>                              | <b>67</b> |

---

# **Abstract**

Autologous platelet concentrates are widely used in a variety of medical application with the aim of enhancing the regeneration of hard and soft tissue. The rationale of this clinical use lies in their enriched content of growth factors and other key molecules involved in promoting tissue healing.

This thesis is composed of two different studies having as a common objective the evaluation of the biological properties of a platelet concentrate, Pure-Platelet Rich Plasma.

The first part of the thesis was a pre-clinical *in vitro* study focused on evaluating the stimulating activity of P-PRP on human osteoblasts (hObs) and human dermal fibroblasts (hDFs).

hObs and hDFs were grown in a serum-free medium supplemented by P-PRP obtained from three different donors. hObs and hDFs proliferation was assessed by cell counting and vitality through MTT assays up to 12 days of incubation. hObs osteo-differentiation was tested after 7- and 14- days of incubation by alkaline phosphatase assay.

Results showed that cells maintained in the presence of P-PRP display an increased proliferation rate at 12 days of culture, compared to the standard condition. The increased vitality of hObs, induced by P-PRP, noticed after 12 days of culture, was comparable of that of control. In contrast, an increased vitality of hDFs, in comparison to the control, was observed at 12 days of culture. The addition of P-PRP did not further stimulate the enzyme activity either at day 7 and 14.

The second part of the thesis was a randomized clinical trial that focused on clinical and radiographic evaluation of the adjunct of P-PRP in the management of edentulous posterior maxillae with a reduced height needing an implant rehabilitation. Clinical and radiographic outcomes of two different approaches were compared up to 3 years after loading: fixed prosthesis supported by 5 to 8.5 mm-long implants which were humidified with P-PRP versus fixed prosthesis supported by 10-mm or longer implants bioactivated with P-PRP and placed following maxillary sinus augmentation with deproteinized bovine bone mixed with P-PRP.

Results showed that both procedures were safe and successful, with comparable outcomes. The use of P-PRP did not shift the balance toward one technique over the other one, but it may have contributed to make these procedures similar in term of clinical and radiographic outcomes.

Since similar outcomes were reported for both approaches, the most cost-effective treatment appears the appropriate and should be advocated. Therefore, when there is an alternative for restoring the lost dentition, avoidance of a demanding surgical procedure like maxillary sinus augmentation should be considered and recommended. In conclusion, results coming from the *in vitro* study and the randomized clinical trial may support the clinical use of P-PRP. It may be beneficial in those situations requiring a successful bone and soft tissue regeneration at the site of surgery.



# **Chapter I:**

---

# **Introduction**

## **1.1 Autologous platelet concentrates**

### ***1.1.1 General aspects***

Autologous platelet concentrates (APCs) have been widely used in many different clinical situations that require a rapid tissue healing and regeneration as it is especially the case in oral and maxillofacial surgery, orthopaedics, sports medicine, ophthalmology and in the treatment of skin ulcers. APCs are hemocomponents, obtained through centrifugation of patient's own blood, in order to collect the most active blood components: platelets, fibrin and in certain cases also leukocytes. The final product has a platelet concentration higher than the basal level, consequently has an increased number of platelet-derived growth factors [1]. The rationale of the clinical use of such platelet-rich preparations is based upon the concept of exploiting their contents enriched of numerous mitogenic platelet-derived growth factors (including platelet-derived growth factor, [PDGF] transforming growth factor- $\beta$  [TGF- $\beta$ ], endothelial growth factor [EGF], vascular endothelial growth factor [VEGF], insulin-like growth factor-1 [IGF-1], basic fibroblast growth factor [FGF], hepatocyte growth factor [HGF]) as well as other key molecules in promoting tissue healing (as adhesive proteins, pro-coagulant factors, cytokines, chemokines and anti-microbial proteins [2-5] to stimulate many biological functions such as chemotaxis, angiogenesis, proliferation, differentiation (Table 1) in order to enhance hard and soft tissue healing.

**Table 1. Platelet  $\alpha$ -granule contents and their functional categories**

| Category                                     | Term   | Biological activities  |
|--|--|--|
| Adhesive proteins                            | VWF + pro-peptide, Fg, Fn, Vn, TSP-1, laminin-8  | Cell contact interactions, clotting, extracellular matrix composition  |
| Clotting factors and associated proteins     | F V/Va, F XI, Gas6, protein S, HMWK, AT, TFPI  | Thrombin production and regulation, angiogenesis   |
| Fibrinolytic factors and associated proteins | Pgn, PAI-I, u-PAm, OSN, $\alpha$ 2-AP, HRGP, TAFI, $\alpha$ 2-M  | Plasmin production and vascular modelling  |
| Proteases and anti-proteases                 | TIMP-4, MMP-4, inhibitor of FIX, PN-II, C1-INH, A1AT   | Angiogenesis, vascular modelling, regulation of coagulation, regulation of cellular behaviour                                  |
| Growth factors, cytokines, chemokines        | PDGF, TGF $\beta$ -1 and -2, EGF, IGF-1, VEGF, bFGF, FGF-2, HGF, CCL5, IL-8, MIP-1 $\alpha$ , CXCL5, MCP-3, ANG-1, IL-1 $\beta$ , neutrophil chemoactive protein | Chemotaxis, cell proliferation and differentiation, angiogenesis   |
| Basic proteins and others                    | PF4, $\beta$ -TG, PBP, CTAP III, NAP-2, ES   | Regulation of angiogenesis, vascular modelling, cellular interactions  |
| Anti-microbial proteins                      | TC   | Bactericidal and fungicidal properties   |
| Others                                       | CS-4, AB, Ig   | Diverse  |
| Membrane glycoproteins                       | $\alpha$ IIb $\beta$ 3, $\alpha$ v $\beta$ 3, GPIb, PECAM-1, most plasma membrane constituents, receptors for primary agonists, CD40L, TF, P-selectin            | Platelet aggregation and adhesion, endocytosis of proteins, inflammation, thrombin generation, platelet-leukocyte interactions |

Extracted and readapted from Anitua et al. *Thromb Haemost* 2004;91:4-15 [2]

### 1.1.2 History of the medical use of platelet concentrates

#### 1.1.2.1 Fibrin adhesives

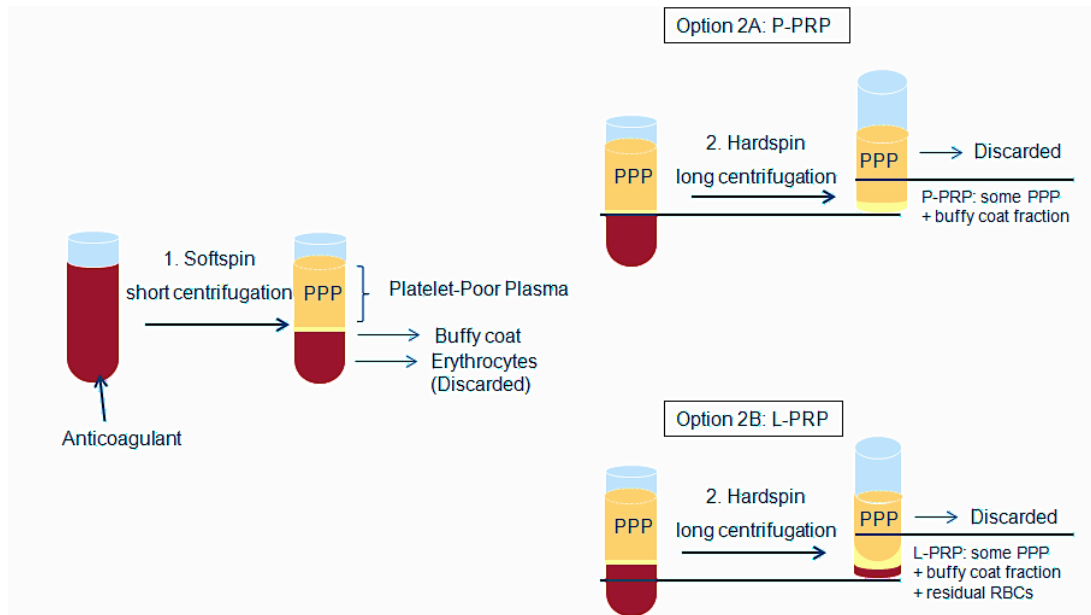
More than 40 years ago these technologies were originally used as sealant-adhesive agents in the treatment of haemorrhage with the aim of blocking the blood leakage [6]. Subsequently, other molecules involved in the coagulation process were combined to such fibrin preparations to improve their adhesive properties. These preparations were referred as "platelet-fibrinogen-thrombin mixtures" and were successfully used in ophthalmology [7,8], general surgery [9] and neurosurgery [10]. Other authors termed them as "gel foam" [11].

It is noteworthy that the application of these preparations was essentially related to their adhesive properties and the platelets served only to reinforce the fibrin matrix architecture. Only several years later, it was developed the concepts that these preparations could have healing and regenerative properties. In the late 80's, Knighton and coll. [12-14] used the autologous "Platelet-Derived Wound Healing Factors (PDWHF)", which was prepared through 2-step centrifugation process, in the treatment of chronic non-healing cutaneous ulcers. In 1997, Whitman et al. used platelet concentrate referred as "platelet gel" in oral and maxillofacial surgery [15].

#### *1.1.2.2 Platelet-Rich Plasma*

The term "Platelet-Rich Plasma" (PRP) was, for the first time, introduced by Kingsley *et al.* to describe a thrombocyte concentrate [16] used for the treatment of severe thrombopenia. However, the use of PRP term really started with Marx in 1998 [1] when he published a comparative clinical study in which the PRP regenerative potential was demonstrated during a mandibular reconstruction. Afterwards, the PRP product was then associated with the concept of platelet growth factors and their potential contribution to the enhancement of tissue healing.

According to the PRP protocol, the blood is collected in tubes containing anticoagulants and processed by two centrifugation steps. Figure 1 illustrates in details the specific protocol [17]. The final PRP product can be applied to the surgical site with a syringe or be activated by thrombin and/or calcium chloride to trigger platelet activation and to stimulate the fibrin polymerization.



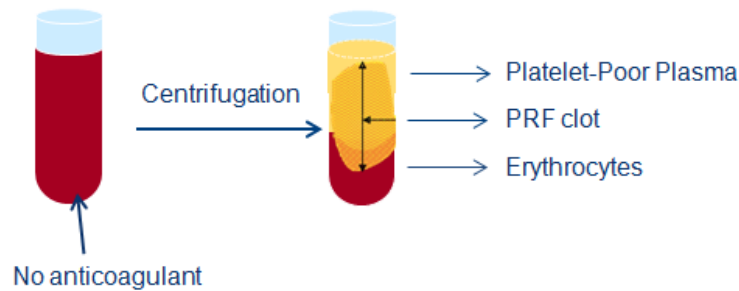
**Figure 1. Protocol for PRP production.**

After blood collection with anticoagulants, the first centrifugation at low forces (soft spin) allows the separation of blood into three distinct layers: red blood cells at the bottom, acellular plasma (PPP, Platelet-Poor Plasma) in the upper portion and a whitish layer called buffy coat located between them containing the highest concentration of platelets and leukocytes. For the production of Pure-PRP (P-PRP), PPP and the superficial buffy coat layer are transferred into another tube and centrifuged at high forces (hard spin) after which most of the PPP and leukocytes are discarded and the final P-PRP can be collected. For the production of PRP rich in leukocytes (L-PRP), PPP, the entire buffy coat layer and some residual red blood cells are collected and transferred in another tube to be hard spin centrifuged. To obtain the final L-PRP, PPP is discarded leading to a L-PRP that contains the buffy coat with most of the platelets and leukocytes, some residual red blood cells and PPP. Adapted from Dohan Ehrenfest et al. *Trends Biotechnol* 2009;27:158-67 [17].

### 1.1.2.3 Platelet-Rich Fibrin

Choukroun and coll. developed in 2011, concomitantly to the introduction of PRP, another form of platelet concentrate, named Platelet-Rich Fibrin (PRF) [18]. Here, the blood is collected in tubes in the absence of anticoagulant and centrifuged with

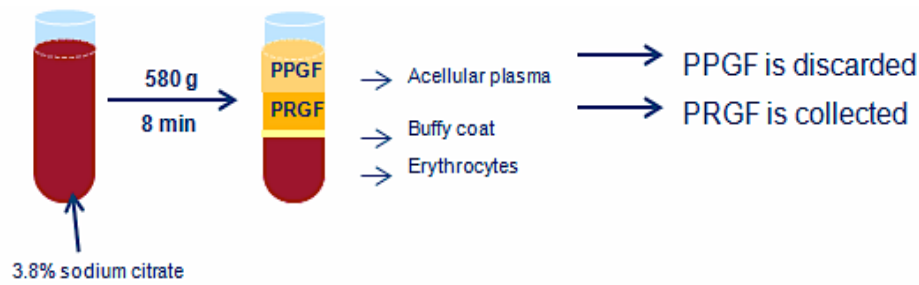
moderate forces for 12 minutes. Afterwards three layers are formed: red blood cells and acellular plasma are located, respectively, at the bottom and at the top of the tube, and the fibrin clot, positioned between them, is PRF (Figure 2). Since the formation of the PRF clot naturally occurs within the tube, it has a strong fibrin matrix in which most of the platelets and leukocytes are embedded [19].



**Figure 2. Protocol for PRF production.** Adapted from Dohan Ehrenfest et al. *J Periodontol* 2010;81:546-55 [19].

#### 1.1.2.4 Platelet-Rich in Growth Factors

In parallel to the introduction of PRP and PRF, Anitua in 1999 proposed another platelet concentrate protocol, denominated Plasma Rich in Growth Factors (PRGF) [20]. According to that, blood is collected in tubes containing 3.8% trisodium citrate as anticoagulant. After a centrifugation at 580g for 8 minutes, red blood cells and buffy coat layer are deposited at the bottom of the tube, and the plasmatic component above. The plasmatic component is then manually separated into two fractions. The lower portions of about 2 ml above the buffy coat, is the PRGF, while the upper portion is the Plasma Poor in Growth Factors (PPGF) (Figure 3). The final PRGF product may be applied as a liquid fraction to the target site or may be activated by adding 10% CaCl<sub>2</sub> milliliter to induce the clot formation [21].



**Figure 3. Process of PRGF production.** Details in the text. [Adapted from Anitua *Pract proced aesthet dentist* 2001;13:487-493 [21].

### ***1.1.3 Technical differences between PRGF, PRP and PRF***

PRGF differs from PRP for the following technical aspects:

- 1) blood volume drawn is minimal (5-40 ml)
- 2) requires a single centrifugation for the preparation
- 3) does not contain leukocytes
- 4) does not contain pro-inflammatory cytokines
- 5) platelet concentration is reduced (2-3 threefold the baseline)

In addition PRGF also differs from PRF for these features:

- 1) different products can be obtained (liquid, fibrin clot)
- 2) PRGF liquid can be combined with bone graft materials for bone regeneration procedure

Differences between PRP and PRF are listed below:

- 1) PRP preparation requires 2 centrifugations
- 2) different products can be obtained (liquid and fibrin clot)
- 3) PRP liquid can be mixed with bone graft materials for bone regeneration procedures.

#### ***1.1.4 Current classifications of autologous platelet concentrates***

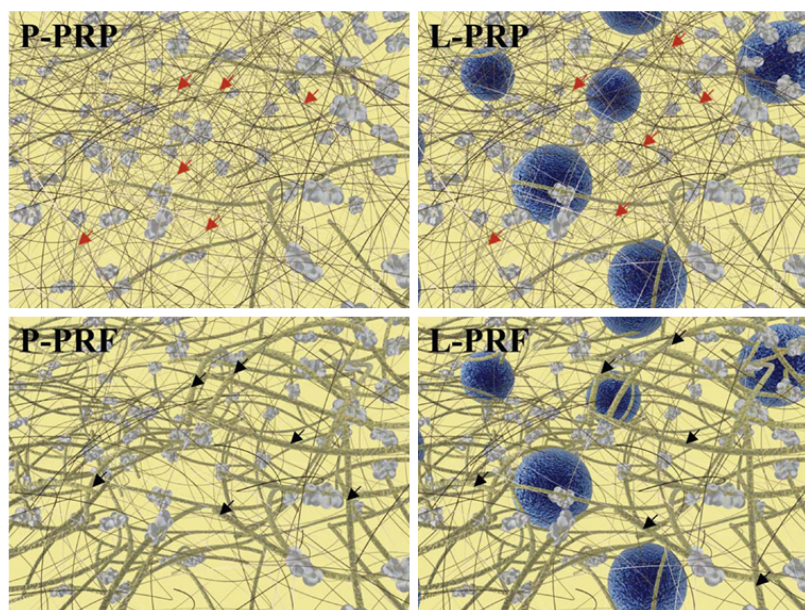
Over the last 20 years, autologous platelet concentrates have been extensively investigated both *in vitro* and *in vivo* in a wide variety of clinical applications. Concomitant to that, multiple systems for their preparation have been developed and several different commercial products, as PRP, PRF and PRGF were briefly described previously, have been introduced in the market. The direct consequence of such growing interest is that a huge number of preparation protocols, commercial kits and several different centrifuges are commercially available. Therefore, due to the different existing methods of preparation, various types of platelet concentrates differ in cellular composition, physical characteristics and presumably biological activity. For these reasons, three classifications have been proposed [17,22,23] to better define each product. A scientific terminology, instead of the commercial names, has been adopted in order to avoid an inaccurate use of these terms.

##### ***1.1.4.1 Dohan Ehrenfest classification***

According to the classification proposed by Dohan Ehrenfest and coll. [17], autologous platelet concentrates can be divided into 4 categories based upon cell contents, fibrin matrix architecture and density [Figure 4]:

- 1) Pure Platelet-Rich Plasma (P-PRP) – plasma rich in platelets without leukocytes with low-density fibrin network after activation;
- 2) Leukocyte- and Platelet-Rich Plasma (L-PRP) – plasma rich in platelets with leukocytes and a low- density fibrin network after activation;
- 3) Pure Platelet-Rich Fibrin (P-PRF) – high density fibrin matrix rich in platelets without leukocytes;
- 4) Leukocyte- and Platelet-Rich Fibrin (L-PRF) – high density fibrin matrix rich in platelets with leukocytes.





**Figure 4. Schematic view of the matrix and cellular composition of the four types of platelet concentrates according to Dohan Ehrenfest Classification.**

Leukocytes are represented as blue circles and fibrin as yellow fibres; platelet aggregates are the light-grey circles and are assembled on the fibrin fibres. [Images taken from Dohan Ehrenfest et al. *Trends Biotechnol.* 2009;27:158-67 [17].

#### 1.1.4.2 Mishra classification

Mishra *et al.* [22] proposed a classification used especially in the field of sport medicine in which platelet concentrates are divided into 4 groups on the basis of platelets and leukocytes concentration and whether or not the PRP activation is performed (further details are summarized in Table 2).

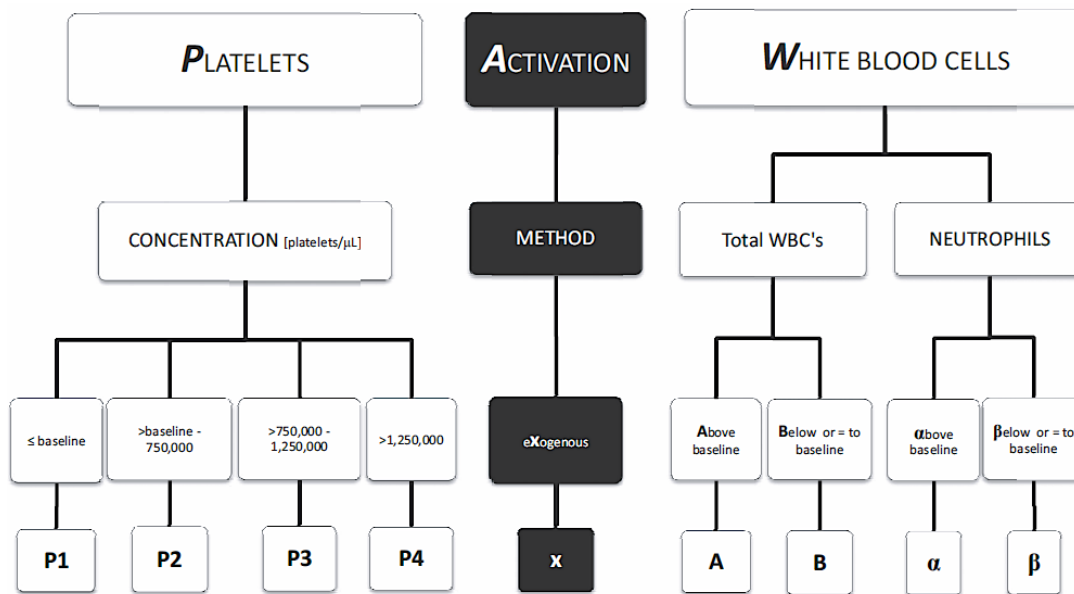
**Table 2. Mishra classification of Platelet Rich Plasma**

|        | White Blood Cells | Activation    | Platelet Concentration |           |
|--------|-------------------|---------------|------------------------|-----------|
| Type 1 | Increased         | No activation | A. $\geq 5x$           | B. $< 5x$ |
| Type 2 | Increased         | Activated     | A. $\geq 5x$           | B. $< 5x$ |
| Type 3 | Minimal or no WBC | No activation | A. $\geq 5x$           | B. $< 5x$ |
| Type 4 | Minimal or no WBC | Activated     | A. $\geq 5x$           | B. $< 5x$ |

Adapted from Mishra et al. *Curr Pharm Biotechnol* 2012;13:1185-95 [22]

### 1.1.4.3 PAW classification

The third proposed classification is called PAW (Platelets, Activation, White cells) [23] and is based on three parameters: the exact number of platelet quantity, platelet activation mode and presence of white blood cells (Figure 5).



**Figure 5.** PAW classification of PRP [Adapted from DeLong et al. *Arthroscopy* 2012;28:998-1009 [23].

## **1.2 Clinical evidence of the efficacy of autologous platelet concentrates in oral regenerative surgical procedures**

### ***1.2.1 General aspects***

In the last couple of decades, it has been observed a growing interest in the use of autologous platelet concentrates during oral regenerative surgical procedures as an adjunctive tool to enhance the hard and soft tissue healing. The following paragraph will summarize the recent evidence on the efficacy of autologous platelet concentrates in the dental field. Healing of post-extraction sockets, treatment of periodontal defects, treatment of immature necrotic teeth, sinus lift augmentation and implantology will be discussed.

### ***1.2.2 Alveolar post-extraction healing***

A recent systematic review evaluated the efficacy of autologous platelet concentrates in enhancing alveolar socket healing after tooth extraction. Beneficial effects were generally reported in terms of better soft tissue healing, better clinical and histological epithelialisation of wound margins and a faster wound closure, although the heterogeneity of the data could not allow a meta-analysis. Regarding the bone formation, the qualitative synthesis of the histological analyses reported a better bone quality in those biopsies retrieved from platelet concentrate treated sites. Furthermore, the meta-analysis of the histomorphometric evaluation of the bone formation (performed in only two of the included studies), revealed that sites treated with platelet concentrate showed a statistically significant greater proportion of new bone than the controls, at three months of follow-up. Even though the results of the meta-analysis are positive suggesting a beneficial effect of autologous platelet concentrates on bone formation, caution should be paid on interpreting such results since the available evidence are scarce and of limited quality [24].

### ***1.2.3 Periodontal defects***

Several systematic reviews and some meta-analysis evaluated the efficacy of autologous platelet concentrates in the treatment of periodontal defects including intrabony defects, gingival recessions and furcation defects [25-33]. Beneficial effects on clinical and radiographic outcomes in the treatment of infrabony defects were reported, although it emerged a high heterogeneity among the clinical studies in terms of outcomes evaluated and bioactive agents/procedures combined with autologous platelet concentrates [25,28,30-32]. Furthermore, two meta-analyses [28,30] concluded that PRP might exert positive adjunctive effects in the surgical treatment of such defects when combined with grafting materials, but no adjunctive effects in association with the guided tissue regeneration technique that may mask the PRP effect. Regarding the autologous platelet concentrates' effect on gingival recessions, very few systematic reviews have been conducted, presumably due to the limited data about it. PRP or PRF did not show any clinical improvements in the treatment of gingival recessions or furcation defects [28,33].

### ***1.2.4 Endodontics***

Platelet concentrates have been recently used in the clinical treatment of immature necrotic teeth, with the aim of regenerating the intracanal pulp and stimulating tooth development, as well as in the surgical treatment of teeth with apical periodontitis to enhance healing of periapical tissues. Clinical evidence on the benefits of the use of platelet concentrates in these pathologies exists but scarce. Our recent systematic review concluded that periapical healing and apical closure were improved in those immature necrotic teeth treated with PRP compared to the control group without PRP, even though not statistically significant, and a significant better thickening of dentinal walls and root lengthening were also reported [34]. However from the histological point of view, it seems that a true regeneration of necrotic pulp tissue of either mature or immature teeth were not achieved after using platelet concentrates. In fact, the

neofomed intracanal tissues were mainly cemento-like, bone-like and connective tissue. Root canals were repopulated with living tissue that only marginally resembled the original pulp. Despite this, the root maturation may be achieved and teeth function is not compromised [35].

### ***1.2.5 Sinus lift augmentation***

The use of platelet concentrates in association with grafting material during a maxillary sinus augmentation reported conflicting results in both preclinical and clinical studies [36-42]. A recent meta-analysis documented that PRP combined to graft materials, in this type of surgical procedure, had no adjunctive effect on bone formation, on implant survival and implant stability as well as it did not show any statistically significant differences on marginal bone loss or alveolar bone height, compared to the bone graft alone [43]. Similar conclusions were also reported in other systematic reviews [44,45]. However another meta-analysis reported opposite conclusions concerning the bone formation supporting the use of PRP for sinus bone graft [46]. Furthermore, beneficial effects on soft tissue healing as well as reduction of post-operative discomfort were often reported [44].

### ***1.2.6 Implantology***

As it is claimed that platelet concentrates may promote bone regeneration, several animal studies have been conducted to assess the PRP effect on the osseointegration process, through histological and histomorphometrical evaluation, but controversial results have been reported. In fact, some studies did not demonstrate any advantages of PRP over non-PRP control groups at stimulating faster bone formation or higher bone-implant contact [47-49]. By the contrast, histomorphometric analyses of the bone-implant interface in the early healing phase after implantation (6 or 8 weeks) revealed a significantly higher percentage of bone-implant contact in implants coated with liquid PRP formulation compared to those not PRP-bioactivated [50-52]. In addition to being

time dependent, PRP effect is also site dependent since its effect has been reported to decrease with increasing distance from the site of application [52]. Similarly, liquid-PRP showed a tendency to increase the bone apposition to roughened titanium implants during early healing phase [53,54].

Clinical studies reported a higher bone formation around the implants [55] and a good preservation of the alveolar crest around post-extraction implants [56,57] when APCs were used.

APCs have been also combined with several different types of grafting materials during regenerative procedures associated with implanto-prosthesis rehabilitations, showing satisfying results and positive patient-related outcomes [58-62]. A long-term clinical study (10-12 y) on short implant placement in association with PRGF, reported an implant survival rate of 98.9% and marginal bone loss inferior to 1 mm [63].

### **1.3 Management of reduced residual crestal height in the posterior maxillary region. Long implants in augmented sinus or short implants without augmentation?**

Implant placement is a treatment option for partially or totally edentulous jaws. Following tooth loss, physiological progressive resorption occurs in the alveolar bone, which in case of maxillary posterior regions, leads to an insufficient bone volume making unable the placement of dental implants of standard length ( $\geq 10$  mm). Such reduced bone height issue in posterior maxilla may be overcome by sinus lift procedure that aims at creating a thicker layer of bone at the basis of the sinus cavity; the augmentation of the sinus cavity is performed with autogenous bone or biomaterials or both [64]. Maxillary sinus augmentation is the most predictable of the surgical techniques used to re-establish the ridge height for the implant placement needed to supporting a fixed prosthesis [65]. Alternative techniques to the challenging procedure of sinus augmentation were proposed. Among these, placement of short implants of reduced length (4-8.5 mm) represents a less complex surgery, cheaper and faster option treatment with a reduced morbidity and a high implant survival rate [66,67].

Currently, there is no evidence of superiority of one technique over the other one. Evidence of moderate quality on the evaluation of the comparison between short implants vs. long implants in augmented sinus exists, but it was unable to conclude that sinus lift procedures, in bone with residual height of 4-9 mm, is more successful than placing short implants without sinus augmentation at reducing prosthesis or implant failure, up to one year after loading, as documented in a Cochrane review [64]. High implant and prosthesis survival rates for short implants and long implants in association with sinus lift were reported in several systematic reviews, although with no statistically significant differences [67-70]. In addition, no statistical differences were also observed for marginal bone loss [67-69]. However, due to the complexity of the technique, increased surgical time and cost [71], increased post-operative morbidity,

and also higher risks of complications were reported for sinus elevation procedure [64, 67, 70].



## **1.4 Rationale of the thesis**

In the last years, the interest of our research group has been focused on investigating the use of P-PRP in several oral surgical procedures. Several clinical- and *in-vitro* studies as well as systematic reviews have been conducted for assessing the efficacy of P-PRP in the dental field.

### ***1.4.1 Pre-clinical findings on P-PRP***

Some *in-vitro* studies and one systematic review on pre-clinical studies documented that autologous platelet concentrates may have an antimicrobial activity against some oral microorganisms. This antibacterial effect may contribute at reducing the incidence of post-operative infections [72-74].

In another *in-vitro* study, proliferative and differentiative capacities of human adipose-derived stem cells (hASCs) were tested after being cultured in the presence of P-PRP. Platelet-rich preparations promoted hASCs cell viability up to 12 days and differentiation toward the osteogenic lineage at early phase (day 7) [75].

### ***1.4.2 Clinical findings on P-PRP***

From the clinical point of view, some randomized clinical trials performed by our group showed a significant reduction in the post-operative pain and inflammation in association with the use of P-PRP in patients treated for periradicular surgery or maxillary sinus augmentation [76-78].

In particular, preliminary results of a randomized clinical study documented that the adjunctive use of P-PRP to the maxillary sinus augmentation had a noticeable beneficial effects in patient's quality of life in the first post-operative days after surgical procedure. In fact, a significant reduction in the perceived pain, tissue swelling, hematoma formation as well as functional activities was reported when P-PRP was mixed to the deproteinized bovine bone graft material and applied as a membrane covering the graft, compared to the standard maxillary sinus augmentation without P-

PRP [78]. Furthermore, a split-mouth histological and histomorphometric study investigating regenerated bone biopsies taken 6 months after bilateral maxillary sinus augmentation showed a higher newly formed bone volume in sites treated with deproteinized bovine bone plus P-PRP as compared to sites augmented with bovine bone alone ( $30.70\% \pm 7.89\%$  (range, 18.30%–39.99%) in the P-PRP group versus  $22.72\% \pm 9.21\%$  (range, 11.45%–33.30%) in the control group) [79].

## 1.5 Aims of the thesis

The first aim of the thesis was to proceed on testing further *in-vitro* inductive capacities of P-PRP. Therefore, it was evaluated the *in-vitro* ability of P-PRP to stimulate vitality and cell growth of terminally differentiated cells, as human osteoblasts (hObs) and human dermal fibroblasts, since these cellular processes are key-events in tissue healing and regeneration. Furthermore, hOb differentiation toward the osteogenic lineage was also tested.

Considering that (a) the adjunct of P-PRP in maxillary sinus augmentation has a beneficial effect due to the reported better patients' related outcomes, and (b) there is scarce evidence for a clear superiority of sinus augmentation over the use of short implants in case of limited bone volume in the posterior maxilla, it appeared interesting to study whether the adjunctive use of P-PRP during these two different surgical procedures might shift the balance toward one technique.

Therefore, the second aim of the thesis was to compare clinical and radiographic outcomes of these two approaches for the rehabilitation of edentulous posterior maxilla of reduced height: fixed prosthesis supported by 5-8.5 mm-long implants which were humidified with P-PRP versus fixed prosthesis supported by 10-mm or longer P-PRP bioactivated implants placed after maxillary sinus augmentation with deproteinized bovine bone mixed with P-PRP.

The null hypotheses were: (1) no differences between the two groups regarding prosthesis and implant survival and success rates; (2) no differences in marginal bone loss, complications, bleeding on probing, presence of inflammation and plaque

between the two groups. This thesis reports data of a randomized clinical study up to 3 years after loading.

## **Chapter II:**

---

# **Materials and Methods**

## **2.1 The *in-vitro* study**

### **2.1.1 Preparation of Pure-Platelet Rich Plasma (P-PRP)**

Blood from healthy donors was collected in 9-ml laboratory tubes (BTI blood collecting tubes®) with 3.8% sodium citrate (m/v) and processed according to Anitua's protocol [20] whose details were already reported in a previous paragraph (1.1.2.4 pag.12). Platelets count was performed using a hematology analyzer (Sysmex, XE-2100, Norderstedt, Germany). PRGF was activated using 50 µl of 10% CaCl<sub>2</sub> per milliliter [21] and immediately aliquoted and stored at -80°C until use. After being thawed at 37°C in a water bath for few minutes, it was incubated at 37°C for 30 minutes, triggering platelet activation and growth factors release and then used as supplement to the culture medium.

### **2.1.2 Cell cultures**

All cells used in this study derived from discarded tissues obtained from healthy donors after their written consent and Institutional Review Board approval (IRCCS Galeazzi Orthopaedic Institute PQ 7.5.125, version 3, 14.05.2012).

Human osteoblasts (hObs) were isolated from cortical bone of two male patients (age 43-57 years) undergoing osteotomy. Bone fragments were digested for 60 minutes with collagenase type II (0.003%) at 37°C and hObs were plated and maintained in basal medium supplemented with 10% fetal bovine serum (FBS), 50 U/ml penicillin, 50 mg/ml streptomycin and 2 mM L-glutamine. Plastic culture flasks-adherent hObs were selected during subsequent passages. The fibroblast-like morphology displayed by the isolated cells was checked by phase-contrast microscopy and the doubling time was calculated as  $\ln(N/N_0)/\ln 2$ , where N is the number of counted cells and N<sub>0</sub> represents the number of plated ones. Cell viability was tested by means of 3-[4,5-dimethylthiazol-2-yl]-2,5-diphenyltetrazolium bromide (MTT) test, while the colony-forming unit-fibroblast (CFU-F) frequency was established by counting individual colonies (of at least 20 cells) compared to the number of seeded cells. hObs were

characterized immunophenotypically by FACS Calibur flow cytometer (BD Biosciences Europe, Erembodegem, Belgium). Cells were CD14, CD45, CD73, CD90, CD105 and CD271 positive.

Human dermal fibroblasts were obtained from a 46-year-old female patient undergoing abdominoplastic surgery. Tissue was digested for 6 hours in DMEM and 0.1% collagenase I at 37°C and hDFs-1 were separated by centrifugation (1200 g for 10 minutes), filtered, and plated (100,000 cells/cm<sup>2</sup>) in complete medium. The fibroblast-like morphology displayed by the isolated cells was checked by phase-contrast microscopy and the doubling time was calculated as  $(t_2-t_1) \cdot \ln 2 / \ln (N/N_0)$ , where N is the number of counted cells and N<sub>0</sub> represents the number of plated ones. Cell viability was tested by means of 3-[4,5-dimethylthiazol-2-yl]-2,5-diphenyltetrazolium bromide (MTT) test. Human dermal fibroblasts were characterized in vitro and their multilineage differentiation potential into adipogenic, osteogenic, and chondrogenic lines was also confirmed (data not shown). All cells were maintained in a humidified atmosphere at 37°C with 5% CO<sub>2</sub> until confluence.

### ***2.1.3 Cell Proliferation and viability***

Cell count: From passage 1 to 3 in culture, cells were detached with 0.5% trypsin/0.2% EDTA and plated at a density of 8X10<sup>3</sup>cells/cm<sup>2</sup> in 6-well tissue-culture plates. Cells were starved for 24 hours, then culture medium was replaced by medium supplemented with either 5% of P-PRP or 10% FBS (CTRL). At days 4, 8, 12, cells were counted in a Burker chamber considering also trypan blue exclusion. MTT assay: hObs and hDFs, derived from the counting assays at day 4, were used for vitality evaluation. From passage 3 to 5 cells were plated at a density of 1.5X10<sup>4</sup> cells/cm<sup>2</sup> in 96-well tissue culture plates in the presence of either 5% P-PRP or 10% FBS. After 5 and 12 days in culture, 0.5 mg/mL MTT (3-[4,5-dimethylthiazol-2-yl]-2,5-diphenyltetrazolium bromide) was added and incubated for 4 hours at 37 °C. The formazan precipitate was solubilized with 100% dimethylsulphoxide and the absorbance read at 550nm with a

Celbio plate reader. For the proliferation and viability test, cell cultures were performed in duplicates.

#### ***2.1.4 Osteogenic differentiation***

From passage 1 to 3, hObs were plated in 24-well tissue-culture plates at a density of  $7.5 \times 10^3$  cells/cm<sup>2</sup> for 7 days and  $5 \times 10^3$  cells/cm<sup>2</sup> for 14 days and let adhere overnight in control medium. After being washed and cultured for 24 hours in serum-free medium, either 2.5% P-PRP or 10% FBS (CTRL) was added. Then hObs were osteo-induced to differentiate with 10 nM dexamethasone, 10 mM glycerol-2-phosphate, 150  $\mu$ M L-ascorbic acid-2-phosphate, 10 nM cholecalciferol (OSTEO) [80]. Cells were culture for 7 and 14 days before the biochemical analyses. ALP assay- enzymatic activity was measured at day 7 and 14, cells were lysed with 0.1% Triton X-100 and protein concentrations were determined by BCA protein assay (Pierce Biotechnology, Rockford, Ill., USA). 1 mM p-nitrophenylphosphate in alkaline buffer (100 mM diethanolamine and 0.5 mM MgCl<sub>2</sub>, pH 10.5) [81] was added to the cell lysate and incubated at 37°C. The reaction was stopped with 1N NaOH and absorbance read at 405nm with a Wallac Victor II plate reader. ALP activity was then normalized respect to each sample protein concentration. Reagents, when not otherwise indicated, were provided by Sigma-Aldrich, Milan, Italy.

#### ***2.1.5 Statistical analysis***

Data are expressed as means  $\pm$  SE and statistical analysis (unpaired Student's *t*-test) was performed by using GraphPad Prism 5.03 (GraphPad Software, San Diego, Calif., USA). Differences were considered significant at  $p < 0.05$ .

## **2.2 Randomized clinical study**

The present randomized clinical trial was approved by the ethical committee of the Lombardy region and conducted at the Dental Clinic of IRCCS Istituto Ortopedico Galeazzi, Milan, Italy. All patients were treated following the principles embodied in the World Medical Association Helsinki Declaration of 1975 for biomedical research involving human subjects, as revised in 2000 [82] and all surgeries were performed by one highly experienced clinician (Dott. Silvio Taschieri) with more than 10 years of activity in the implant dentistry field.

### ***2.2.1 Patients inclusion criteria***

- Patients older than 18 years, able to sign an informed consent form and in good health (classified as ASA 1-2 following the American Society of Anaesthesiologists classification)
- Patients with posterior edentulous maxilla who needed the augmentation of the maxillary sinus floor in order to be rehabilitated by means of fixed implant-supported prostheses
- Bone height in the posterior maxilla ranged from 4 to 7 mm as determined by preliminary CT evaluation

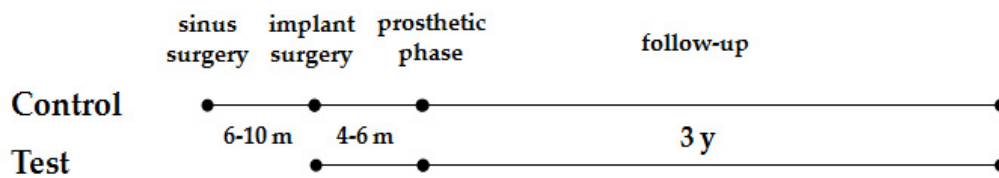
### ***2.2.2 Patients exclusion criteria***

- Presence of systemic conditions or pathologies representing contraindication to oral surgery and any disease affecting the bone metabolism
- Presence of active infection or inflammation in the area intended for sinus floor augmentation or implant placement such as any form of maxillary sinusitis
- Pregnant or nursing women
- Inadequate oral hygiene and poor motivation



### 2.2.3 Study design

Eligible participants were randomly allocated to receive one of the following treatments: test group received implants with a length inferior to 8.5 mm (BTI, Biotechnology Institute, Vitoria, Spain) in combination with P-PRP, and control group received sinus lift augmentation using deproteinized bovine bone as grafting material mixed with P-PRP (Bio-Oss®, Geistlich) and after 6-10 months (in case of a residual bone volume and density sufficient to provide optimal implant primary stability, implant placement was performed simultaneously to the sinus lift), implants longer than 8.5 mm were inserted in combination with P-PRP. Clinical and radiographic evaluations were scheduled at 6 and 12 months after prosthesis delivery and yearly thereafter up to three years of follow up. Diagram of the study design is illustrated in Fig. 6.



**Figure 6. Study design**

### 2.2.4 Sinus surgery (control group)

One hour before surgery, 2 g of amoxicillin and clavulanic acid (Augmentin, Roche, Milan, Italy) were given to patients as prophylactic regimen. After administration of local anesthesia with 4% articaine and adrenaline (1:100,000), a trapezoidal flap was elevated after one horizontal incision in the middle portion of the edentulous mucosa of the posterior maxilla and two vestibular vertical incisions extending apically to the muco-gingival junction were performed. If needed, a periosteal incision was also performed to reduce the tensile stresses to the flap. After creation of a lateral window

using a piezoelectric device, the Schneiderian membrane was initially detached, starting from the mesial wall and then from the distal one using specific membrane elevators. Afterwards, a P-PRP clot was placed above the membrane surface and continued until the membrane detachment [83]. The absence of membrane perforations was assessed. The cavity was then filled with deproteinized bovine bone matrix as grafting materials mixed with activated P-PRP. After that, flap was repositioned and sutured. Patients were instructed to avoid any activity that could change the sinus cavity pressure for 10 days after surgery, as for example sneezing with the mouth closed, blowing the nose. Besides, patients had to avoid eating hard and soft foods and smoking. Postoperative instructions were: gently rinse with 0,2% chlorexidine digluconate solution twice a day for 10 days to plaque control; assumption of pain relief medications in case of needed and antibiotic therapy with amoxicillin+ clavulanic acid 1 g twice a day for 1 week.

## ***2.2.5 Implant surgery (both groups)***

### *2.2.5.1 Preparation of P-PRP*

In patients allocated to both groups, P-PRP was prepared according to the Anitua's protocol as previously described in details in section 1.1.2.4, pag. 14. Prior to insertion, all implants were embedded in liquid P-PRP to bioactivate the implant surface [50].

### *2.2.5.2 Surgical procedure*

One hour before surgery, all patients received as prophylactic regimen 2g of amoxicillin and clavulanic acid (Augmentin®, Roche, Milan, Italy) and rinsed with 0,2% chlorhexidine mouthwash for 2 min. The procedure was carried out under local anaesthesia using with articaine (4%) + adrenaline (1:100,000).

After flap elevation, implant site preparation and insertion were performed according to the protocol provided by the manufacturer BTI Biotechnology Institute, Vitoria,

Alava, Spain). After being embedded with liquid P-PRP to bioactive the implant surface, short implants (length  $\leq$  8.5 mm) and implants longer than 10 mm were installed, in test and control group, respectively. In control group, implants were inserted after waiting 6-10 months from the sinus lift procedure to allow the healing of the graft material.

Flaps were then repositioned and secured with sutures. Implants were left to heal in a submerged way. Standard pharmacological protocol was prescribed: nimesulide 100mg twice daily for pain control if needed and chlorhexidine digluconate mouthwash 0.2% twice daily for 1 week for plaque control. A soft diet was recommended, avoiding contact of the surgically involved zone with food for a few days if possible.

### ***2.2.6 Prosthetic phase***

A surgical re-entry procedure was performed 4-6 months after implant insertion. Elevation of full thickness flaps was executed to have access to the marginal portion of the implant sites and to replace the healing caps with a healing abutment. Prosthetic procedures were performed.

### ***2.2.7 Radiographic examination***

A radiograph was taken at entry, immediately after surgery (baseline), at the prosthetic phase, and at each follow-up visit (after 6 and 12 months of prosthesis function and yearly thereafter). Radiographs of the prosthetic phases were taken using a long-cone paralleling technique and individual trays to ensure reproducibility. A specific image analysis software (ImageJ version 1.46, National Institutes of Health, Bethesda, MD, USA; <http://rsb.info.nih.gov/ij/>) was used to perform measurements of marginal bone level around implants at the mesial and distal aspects. The implant neck was the reference for each measurement. Implant length was used for calibration. All the radiographs were analysed by an independent evaluator (AL).

### ***2.2.8 Primary and secondary outcomes***

Primary outcomes assessed were implant and prosthesis survival defined as the implant and prosthesis were still in function, without mobility.

Secondary outcomes were:

- Occurrence of any biological or prosthetic complications
- Mesial and distal changes of marginal bone level, measured on periapical radiographs as described previously (radiographic examination in section 2.2.7)
- Assessment of the following clinical parameters: presence of plaque; presence of bleeding on probing; presence of inflammation; presence of peri-implant radiolucency; presence of prosthesis mobility

### ***2.2.9 Statistical analysis***

Descriptive statistical analysis was performed. Data were synthesized using the mean value and standard deviation for the quantitative variables. Life table analysis was used to calculate the cumulative survival rate on implant basis. Implant survival was evaluated according the following criteria: presence of the implant in the patient's mouth, absence of peri-implant radiolucency, no recurrence or persistent peri-implant infection, no complain of pain and of neuropathies or paraesthesia.

Unpaired Students' *t*-test was used to compare the means between two groups, while Fisher's exact test was used for nominal data and survival rates. A *p*-value below 0.05 was considered statistically significant.

# Chapter III:

---

# Results

### 3.1 In vitro study

#### 3.1.1 Platelet concentration of Pure-Platelet Rich Plasma

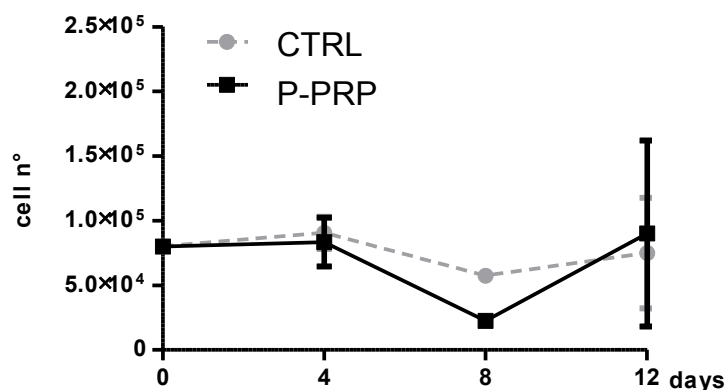
Mean baseline platelet concentration of three volunteer donors was  $259.40 \times 10^3$  platelets/ $\mu\text{l}$  (range  $225\text{-}291 \times 10^3$  platelets/ $\mu\text{l}$ ). After centrifugation, mean platelet concentration of P-PRP was  $485.40 \times 10^3$  platelets/ $\mu\text{l}$  (range  $384\text{-}584 \times 10^3$  platelets/ $\mu\text{l}$ ), with a mean increase of 1.9-fold (Table 3).

| Variable                                  | Number or Mean $\pm$ SD (range) |
|---|---------------------------------|
| Donors                                    | 3                               |
| Age (years)                               | $26.2 \pm 2.6$                  |
| Platelets of blood ( $10^3/\mu\text{l}$ ) | $259.40 \pm 29.98$ (225-291)    |
| Platelets of P-PRP ( $10^3/\mu\text{l}$ ) | $485.40 \pm 79.27$ (384-584)    |

P-PRP: Pure-Platelet Rich Plasma. Brini et al. *J Craniofac Surg* 2016;27:656-61 [84]

#### 3.1.2 Cell Proliferation of hObs and hDFs

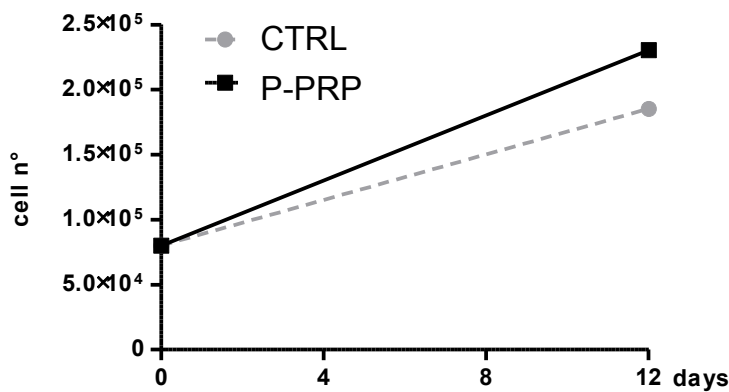
Human osteoblasts (hObs) maintained in the presence of 5% P-PRP and detached every 4 days had a similar proliferation rate of those grown in control culture condition (CTRL) at 4 and 12 days of cell culture, while at 8 days they showed a lower proliferation rate compared to the CTRL ones (Figure 7).



**Figure 7. The effect of P-PRP on hOb proliferation.**

Proliferation was assessed after cell detachment every 4 days. CTRL: Control; P-PRP: Pure-Platelet Rich Plasma

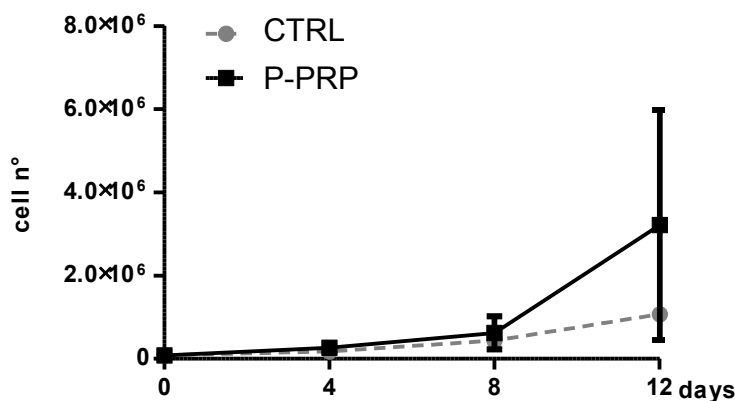
By contrast, when hObs were cultured in the presence of 5% P-PRP for 12 days without being detached, a 1.2-fold increase in their growth was observed compared to the CTRL (Fig. 8).



**Figure 8. The effect of P-PRP on hOb proliferation.**

Proliferation was assessed at 12 days without cell detachment. CTRL: Control; P-PRP: Pure-Platelet Rich Plasma

Human dermal fibroblasts (hDFs) cultured with 5% P-PRP behaved similarly to hObs. In fact, at early time points it was not observed any appreciable cell number increase of hDFs, while after 12 days of P-PRP, their mean proliferation rate increased 3-fold compared to the control medium (Figure 9) with a pronounced growth peak.



**Figure 9. The effect of P-PRP on hDF proliferation.**

Cell growth increase observed after 12 days of culture with P-PRP was not statistically significant for both cell types (hObs and hDFs) ( $P > 0.05$ ).

### 3.1.3 Cell viability of hObs and hDFs

P-PRP did not show any cytotoxic effects on both cell types. In fact, MTT analysis documented that hOb viability increased of 1.8-fold after 12 days of P-PRP culture, while in standard condition it was improved by 1.9-fold. (Fig. 10A) ( $P < 0.05$ ). hDFs grown for 12 days in the presence of P-PRP achieved a 7.8-fold cell viability increase compared with day 5, whereas in CTRL condition it just improved 2.4-fold (Fig. 10B).

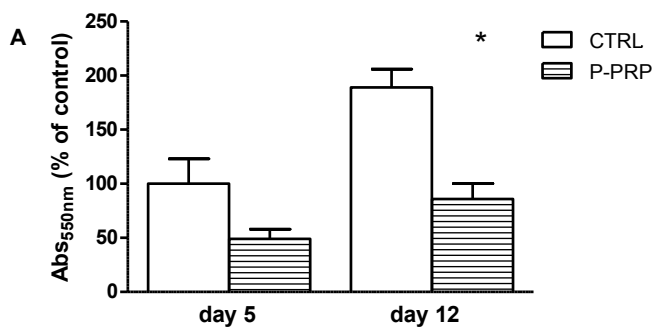


Figure 10A. The effect of P-PRP on hOb viability.

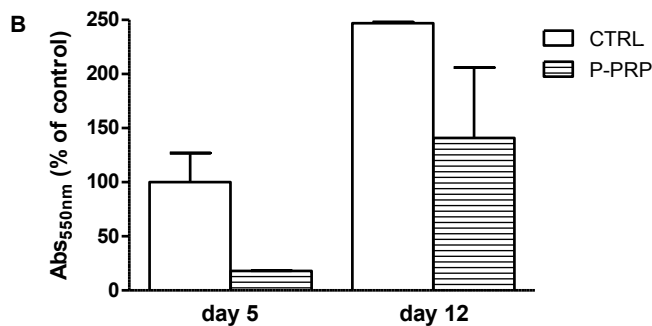


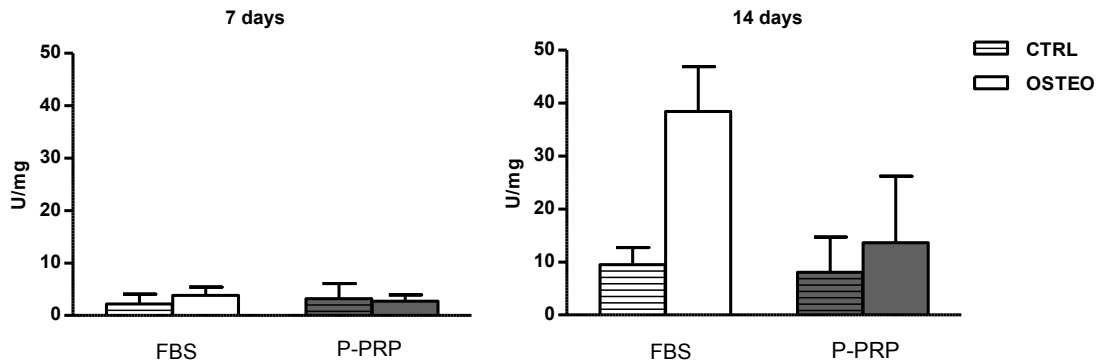
Figure 10B. The effect of P-PRP on hDF viability.

### 3.1.4 Osteogenic differentiation of hObs

Alkaline phosphatase activity (ALP) was assessed in hObs induced to osteo-differentiate for 7 and 14 days in the presence of 2.5% P-PRP. The decision of choosing P-PRP concentration of 2.5% was related to our previous findings documenting that culture medium supplemented with 2.5% P-PRP was sufficient to maintain cells as the standard condition [75].



hObs treated with differentiation (OSTEO) and P-PRP medium showed a similar behaviour at 7 days of culture with a minimal detection of ALP activity (Figure 11 left panel). ALP activity slowly increased in response to OSTEO and P-PRP medium, with the highest point at 14 days (approximately 4-fold increase compared to day 7). The additional presence of P-PRP in OSTEO medium did not further stimulate the enzyme activity either at day 7 and 14 compared to P-PRP control medium. By the contrast, hObs treated with OSTEO medium showed the greatest increase of ALP activity at day 14 (Figure 11, right panel).



**Figure 11. The effect of P-PRP on osteo-differentiation of hObs.** ALP activity was assessed at 7 and 14 days after 2.5% P-PRP incubation. Alkaline phosphatase activity is expressed as U/mg proteins.

## 3.2 Randomized clinical study

### 3.2.1 Patient population and intervention characteristics

Study population of this randomized clinical study included 45 patients (26 women, 19 men, mean age at the implant surgery 51.63 years, range 31-77 years) that were followed up to three years after prosthesis loading.

Baseline demographic details of patients are summarized in Table 4; mean age at implant surgery, gender, medical conditions, smoking status did not show any significant differences between groups.

Sinus lift group: 18 patients were allocated to the graft group (4 of which underwent simultaneous bilateral sinus augmentation whereas other 3 patients underwent bilateral augmentation with separate surgical procedures). The total number of augmented sinuses was 25 and received a total number of 58 implants (57 of which were equal or longer than 10 mm; 12 implants out of 58 were immediately inserted after the sinus augmentation).

Short implant group: 27 patients were allocated to the short implant group and received 65 implants, 42 of which were shorter than 8.5 mm.

Characteristics of interventions are reported in Table 5 whereas position and number of inserted implants in Figure 12. In Table 6 patient platelet counts, performed on baseline blood samples and on final P-PRP products, are shown.

**Table 4. Demographic details of the study population**

|                               | SLI<br>group             | SI<br>group             | Total   | <i>p-Value</i> |
|-------------------------------|--------------------------|-------------------------|---------|----------------|
| No. of implants               | 57(58)                   | 42(65)                  | 99(123) |                |
| 25 augmented sinus            |                          |                         |         |                |
| No. of patients               | 18*                      | 27                      | 45      |                |
| Age at implant surgery        |                          |                         |         |                |
| Mean SD (range)               | 51.05 ± 10.64<br>(36-68) | 52.21± 10.42<br>(31-77) |         | 0.69           |
| Gender                        |                          |                         |         |                |
| F                             | 10                       | 16                      | 26      | 1              |
| M                             | 8                        | 11                      | 19      |                |
| Smoking status                |                          |                         |         |                |
| Non smokers                   | 13                       | 20                      |         | 0.72           |
| Former smokers                | 2                        | 0                       |         |                |
| Smokers                       | 3                        | 7                       |         |                |
| Light smokers                 | 2                        | 2                       |         |                |
| Heavy smokers<br>(>10 al die) | 1                        | 5                       |         |                |
| ASA                           |                          |                         |         |                |
| I                             | 17                       | 24                      | 39      | 0.63           |
| II                            | 1                        | 3                       | 4       |                |

SLI: Standard Length Implants; SI: Short Implants.

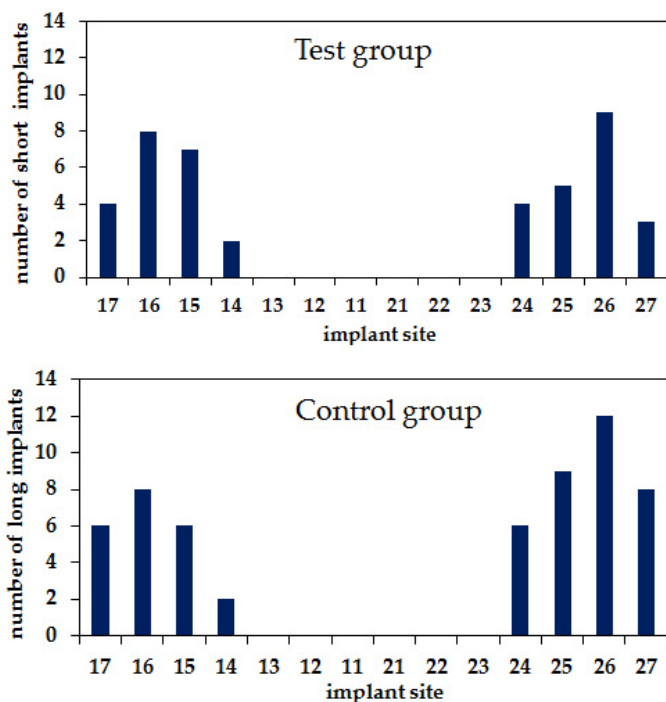
In brackets are reported the total number of implants inserted.

\*7out of 18 patients underwent a bilateral sinus lift augmentation procedure

**Table 5. Intervention characteristics**

|                                 | SLI group       | SI group       |
|---------------------------------|-----------------|----------------|
| Tot. n. of patients             | 18 (25 sinuses) | 27             |
| Tot. n. of prosthesis           | 26              | 29             |
| N. of inserted implants         | 58              | 65             |
| N. of Standard/ Short implants  | 57/1            | 23/42          |
| Average n. Tot/SLI/SI implants  | 3.22/3.17/0.05  | 2.41/0.85/1.56 |
| Mean length of placed implants  | 11.47 ± 0.63    | 8.05 ± 0.59    |
| N. of 3.75 mm-diameter implants | 10              | 9              |
| N. of 4 mm-diameter implants    | 38              | 28             |
| N. of 4.5 mm-diameter implants  | 9               | 5              |
| N. of single-tooth prosthesis   | 7               | 6              |
| N. of fixed-partial prosthesis  | 18              | 20             |
| N. of fixed-full prosthesis     | 1               | 3              |

SLI: Standard Length Implants; SI: Short Implants.



**Figure 12. Implant site distribution.**

In the upper panel is represented the short implant group whereas in the lower panel is represented the Standard Length implants group.

**Table 6. Patient platelet counts**

|   | Standard Length Implants group | Short Implants group |
|---|--------------------------------|----------------------|
| Mean baseline platelet concentration ( $10^3/\mu\text{l}$ ) | 240.83 $\pm$ 45.81             | 251.82 $\pm$ 55.80   |
| Mean P-PRP platelet concentration ( $10^3/\mu\text{l}$ )    | 303.70 $\pm$ 131.22            | 298 $\pm$ 155.01     |
| Mean increase of platelet concentration                     | 1.30 $\pm$ 0.59                | 1.17 $\pm$ 0.53      |

P-PRP: Pure-Platelet Rich Plasma

### 3.2.2 Implant and prosthesis survival rate

All the examined implants were osseointegrated and clinically stable during the study period of 3 years, leading thus to a 100% implant survival rate. Table 7 showed the life table analysis on implant basis. No prosthetic complications occurred during the study period rendering a prosthetic survival rate equal to 100%. No biological complications were registered intrasurgically and post-surgically.

**Table 7. Life table analysis on implant basis**

| Years                                 | N. of patients | N. of implants | Failed implants | Lost to f.u. | ISR % | CSR % |
|---------------------------------------|----------------|----------------|-----------------|--------------|-------|-------|
| <b>Standard Length Implants group</b> |                |                |                 |              |       |       |
| Insertion to 1                        | 18             | 57             | 0               | 0            | 100   | 100   |
| 1-2                                   | 17             | 55             | 0               | 2            | 100   | 100   |
| 2-3                                   | 12             | 38             | 0               | 17           | 100   | 100   |
| <b>Short Implants group</b>           |                |                |                 |              |       |       |
| Insertion to 1                        | 27             | 42             | 0               | 0            | 100   | 100   |
| 1-2                                   | 27             | 42             | 0               | 0            | 100   | 100   |
| 2-3                                   | 24             | 32             | 0               | 10           | 100   | 100   |

ISR Interval survival rate; CSR Cumulative survival rate

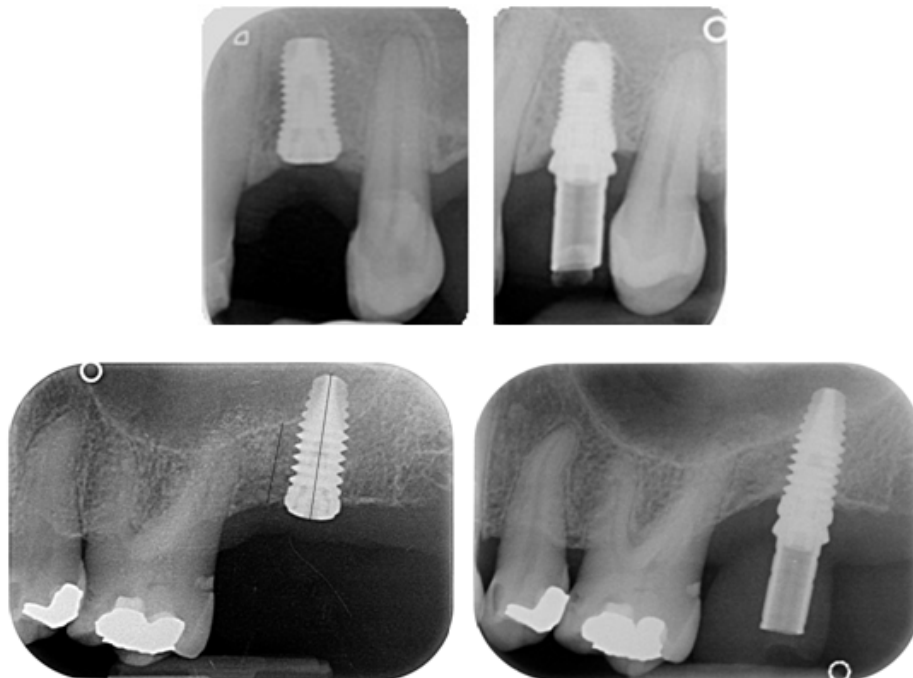
### 3.2.3 Peri-implant marginal bone level changes

Radiographic peri-implant bone level changes for both groups are reported in Table 8. No significant changes in marginal bone level at both mesial and distal implant aspect were observed between the two groups from implant insertion to 1 year of follow-up.

**Table 8. Differences in marginal bone level between implant placement and 1 year of follow-up**

| Short Implants group           |                        |
|--------------------------------|------------------------|
| Mean mesial value ± SD         | Mean distal value ± SD |
| -0.801 ± 1.52*                 | -0.836 ± 1.53*         |
| Standard Length Implants group |                        |
| Mean mesial value ± SD         | Mean distal value ± SD |
| -1.044 ± 0.46**                | -0.930 ± 0.65**        |
| <i>p</i> =0.73                 | <i>p</i> =0.89         |

Negative numbers indicate bone loss  
 \* These data are relative to short implants only  
 \*\* These data are relative to standard length implants only



**Figure 13. X-rays taken after implant insertion (left panel) and at the prosthesis delivery (right panel) of two representative cases. (Upper panel: short implant group, lower panel: standard length implant).**

### 3.2.4 Evaluation of clinical parameters

Clinical assessments are reported in Table 9. No significant differences neither intra-groups and inter-groups were reported. The only finding to point out is that the presence of bleeding on probing and inflammation were nearly to be statistically significant in standard length implants group when comparing the two time points considered.

**Table 9. Clinical outcomes on implant basis at 1 and 3 year after loading**

|                           | SI group  |           |                             | SLI group  |           |                             | <i>p-value</i>                       |     |
|---------------------------|-----------|-----------|-----------------------------|------------|-----------|-----------------------------|--------------------------------------|-----|
|                           | 1y        | 3y        | <i>p-value</i><br>1y vs. 3y | 1y         | 3y        | <i>p-value</i><br>1y vs. 3y | <i>p-value</i><br>SI vs. LI<br>1y 3y |     |
| Plaque                    | 1<br>(41) | 2<br>(30) | .27                         | 6*<br>(51) | 2<br>(51) | .27                         | .23                                  | .63 |
| BoP                       | 1<br>(41) | 1<br>(31) | 1                           | 5*<br>(52) | 0<br>(53) | .06                         | .24                                  | .38 |
| Inflammation              | 0<br>(42) | 1<br>(31) | .33                         | 5*<br>(52) | 0<br>(53) | .06                         | .07                                  | .38 |
| Peri-implant radiolucency | 0<br>(42) | 0<br>(32) | 1                           | 0<br>(57)  | 0<br>(53) | 1                           | 1                                    | 1   |
| Prosthesis mobility       | 0<br>(42) | 0<br>(32) | 1                           | 0<br>(57)  | 0<br>(53) | 1                           | 1                                    | 1   |

SI=Short Implants; SLI= Standard Length Implants; BoP= bleeding on probing

In brackets are reported the number of implants with absence of plaque, bleeding on probing, inflammation, peri-implant radiolucency and prosthesis mobility.

\*Same implants in one patient with full-arch prosthesis

No statistically significant differences within each group as well as no significant differences between two groups at both time periods were reported.

# **Chapter IV:**

---

# **Discussion**



The use of short implants has been proposed as a therapeutic alternative to bone augmentation techniques followed by insertion of standard-length implants, when the posterior region of maxillae has a reduced ridge height. There is no agreement on the definition of a short implant: some authors consider an implant as short when its length is inferior to 10 mm [85,86] whereas for others, implant length must be inferior or equal to 8 mm [67,68,70,87]. In the present randomized clinical study implants long between 8.5 and 6.5 mm were considered short and implants with a length superior or equal to 10 mm as standard.

The results of the clinical part of the study confirmed the predictability and efficacy of short implants in the treatment of atrophic maxillae in the medium/ long-term follow-up. The first null hypothesis was accepted since no differences were found in prosthesis and implant survival rates between short and standard implants, both inserted during surgeries performed with P-PRP. Furthermore, excellent prosthesis and implant survival rates (100%) were reported up to three years after loading in both groups. Same high implant survival rates were also documented in other RCTs with the same study design as the present study, but a shorter follow-up [71,88-90]. Findings coming from recent systematic reviews and meta-analyses were in line with our results describing a high prosthesis and implant survival rates for both procedures with no significant differences [67,69,70]. Analysis of pooled data of a systematic review conducted by Thoma and coll. for EAO working group [67], documented a 99.5% survival rate for standard implants in augmented sinus and 99.0% for short implants during for a follow-up of 16-18 months [71,89-92], while for shorter follow-up (8-9 months) a 100% survival rate for standard implants and 98.2% for short implants was documented [88,93,94].

Short implants were expected to have more failures than the standard ones because of their theoretical unfavourable mechanical properties [95]. One of the supposed reasons may be related to the fact that short implants, having less implant surface, have a smaller available contact area with bone tissue and this might compromise the achievement of an optimal stability during the osseointegration process, that is closely related to the implant success. In case of peri-implant bone resorption, short implants

may present a higher risk of mobility than standard length implants. Besides, short implants are mostly inserted in posterior regions of the jaws where the bone quality is poor, especially in the maxilla [85]. However, results of the present study did not demonstrate this negative association between short implants and survival rate, reporting a 100% of survival rate for short implants placed in conjunction with P-PRP. All implants used in this study, independently of the length, had a micro-rough acid-etched surface and were humidified with P-PRP, prior to insertion. It is claimed that liquid P-PRP, when applied to such type of implant, adsorbs to its surface and forms a layer rich of growth factors and other molecules that entirely cover it creating thus a dynamic surface coating with biological activity [50,96]. In this way, P-PRP represents the initial contact between the surrounding bone tissue and the implant. Consequently, due to its content rich of active molecules able to interact with cells in the surrounding tissues, P-PRP triggers recruitment, attachment, proliferation and differentiation of osteoprogenitor cells as well as osteoblasts.

*In-vitro* results of the first part of this thesis confirmed the ability of P-PRP to promote vitality and growth of human osteoblasts and human dermal fibroblasts, essential cells for bone and soft tissue healing [84]. Furthermore, our results demonstrated that P-PRP has a negligible role in osteoblasts differentiation. Other cell-based studies proved that PRP had stimulatory effects on migration, proliferation and osteo-differentiation of osteoblasts [97-99]. Several animal studies have been conducted to assess the effects of PRP on the implant osseointegration process, through histological and histomorphometrical evaluation, but controversial results have been reported. In fact, some studies could not demonstrate any advantages of PRP over control groups not using PRP regarding the promotion of a faster bone formation or a higher bone-implant contact [47-49]. By contrast, significantly higher percentage of bone-implant contact were reported in implants coated with liquid PRP compared to those not PRP-bioactivated through histomorphometric analysis after 6-8 weeks following implant insertion [50-52]. Furthermore, a layer of liquid-PRP sprayed onto the implant surface before insertion showed a tendency to increase the bone apposition to roughened titanium implants during early healing phase [53,54]. All of these findings may

therefore support the clinical use of PRP during oral bone regenerative procedures where it is required differentiation and proliferation of bone cells at the site of surgery. The second null hypothesis was also accepted since no differences in marginal bone loss, complications and clinical parameters (bleeding on probing, inflammation and plaque) were observed between the two treatment groups. Few other RCTs, with a similar study design, reported marginal bone level changes around short implants and standard implants placed in augmented sinus, concluding with a no statistically significant difference between the two groups [89,90,92]. In particular, in the present study, the observed mean marginal bone loss, at 12 months after loading, was -0.818 mm and -0.987 mm for short and standard implants, respectively. Pistilli and coll. reported a slightly higher marginal bone loss at 12 months of follow-up [89,92], whereas Guljé and coll. reported a mean loss of -0.1 mm for both groups at 18 months of follow-up [90].

In this study, no biological nor prosthetic complications occurred in both groups. However, a recent meta-analysis and a systematic review evidenced that short implants are associated with a lower risk of complications compared to standard implants inserted in augmented sinus [67,70]. This could be due for example to intrasurgical complications like the Schneiderian membrane perforation that may commonly occur during the procedure of sinus floor elevation procedure. However, in the present RCT no perforations occurred during the sinus surgeries performed. One possible explanation may be related to the systematic use of P-PRP clot during these procedures, as its mechanical and biological properties might have avoided that occurrence. P-PRP clot, being of elastic consistency and adhering tightly to the sinus membrane, may allow a gently detachment of the membrane in a non-traumatic way. In fact, P-PRP clot was positioned below the Schneiderian membrane and then compressed favouring the detachment due to its hydraulic pressure reducing thus the forces. After completing the lifting procedure, P-PRP clot remains attached to the sinus membrane continuing to protect and reinforce it [83]. Furthermore, there is evidence that P-PRP clot due to its above-mentioned cohesive properties may effectively be used for intrasurgical management of sinus membrane perforation, allowing safe

completion of the surgical procedure [83]. In this study, activated P-PRP was combined with bone substitute granules forming a compact mixture that facilitates graft manipulation ensuring therefore an easier and more precise graft application in the sinus cavity, without material dispersion. The latter property is particularly useful as, in case of a membrane perforation, it is avoided the escape of some bone graft granules into the sinus, making the graft application safer. Moreover, this solid mixture may reduce the risk of perforations caused by the sharpness of the granules.

From the biological point of view, combining P-PRP which has osteoinductive properties, on either differentiated osteoblasts and undifferentiated mesenchymal stem cells [75,97-102], with osteoconductive bone substitute, may act as an adjunctive stimulus that may speed up the graft maturation [1,103,104]. Marx [1] documented, through histologic and histomorphometric analysis, an increased bone maturation rate and greater bone density when PRP was mixed with bone graft compared with graft without PRP. Findings coming from some systematic reviews could not clearly demonstrate the beneficial effect of PRP on bone graft healing enhancement in maxillary sinus augmentation [43-45]. However, in another meta-analysis of eight controlled clinical studies, PRP yielded a significantly greater bone formation in those PRP-treated sinuses than control sinuses augmented without PRP [46]. As also highlighted in those reviews, much of the discrepancy in observed results can be attributed to the adoption of different techniques for the preparation of the platelet concentrate. Unless standardized techniques will be developed and used, a quote of variation due to the PRP preparation procedure must be taken into account in reviews comparing the effect of platelet concentrates as an adjunct to surgical applications.

# **Chapter V:**

---

# **Conclusions**

The present thesis has the characteristic of being composed of two different parts, a pre-clinical study and a randomized clinical one, that had as the main central theme the evaluation of the biological properties of a platelet concentrate, Pure-Platelet Rich Plasma.

The first part of the thesis focused on cellular biological stimulating properties of P-PRP. Findings coming from this part demonstrated the proliferative capacities of P-PRP on human osteoblasts and human dermal fibroblasts. However, further studies are needed to demonstrate the osteo-differentiation stimulus of P-PRP.

The second part of the thesis focused on clinical and radiographic evaluation of the use of P-PRP in the management of atrophic posterior maxillae needing an implant rehabilitation. Results of this part, showed that both procedures, namely short implants and standard length implants in association with maxillary sinus augmentation performed with the adjunct of P-PRP, were safe and successful, showing comparable outcomes in the rehabilitative treatment of edentulous posterior maxilla with a reduced height, during the observational period of 3 years after loading. The use of P-PRP did not shift the balance toward one technique over the other one, but it may have contributed to make these procedures similarly effective in term of clinical and radiographic outcomes. In both groups P-PRP was used to humidify the implant surface and in addition, in standard implant group, P-PRP was mixed with bone graft materials. Since similar outcomes were reported for both approaches, the most cost-effective treatment appears to be the appropriate and advocated. Therefore, restoring a dentition that avoids the surgical procedure of sinus augmentation should be considered and recommended since it is associated with an increased treatment and surgical time and post-operative morbidity [71]. Of course, it must always be kept in mind that the treatment choice must take into account not only the clinical evidence and the cost-effectiveness ratio, but also the patient's preferences and the clinician's skills, as recommended by the evidence-based medicine concept.

# **Chapter VI:**

---

# **References**

1. Marx RE, Carlson ER, Eichstaedt RM, Schimmele SR, Strauss JE, Georgeff KR. Platelet-rich plasma: Growth factor enhancement for bone grafts. *Oral Surg Oral Med Oral Pathol Oral Radiol Endod* 1998;85:638-46.
2. Anitua E, Andia I, Ardanza B, et al. Autologous platelets as a source of proteins for healing and tissue regeneration. *Thromb Haemost* 2004;91:4-15.
3. Alsousou J, Thompson M, Hulley P, et al. The biology of platelet-rich plasma and its application in trauma and orthopaedic surgery: a review of the literature. *J Bone Joint Surg Br* 2009;91:987-96.
4. Boswell SG, Cole BJ, Sundman EA, et al. Platelet-rich plasma: a milieu of bioactive factors. *Arthroscopy* 2012;28:429-39.
5. Pelletier MH, Malhotra A, Brighton T, et al. Platelet function and constituents of platelet rich plasma. *Int J Sports Med* 2013;34:74-80.
6. Matras H. Effect of various fibrin preparations on reimplantations in the rat skin. *Osterr Z Stomatol* 1970;67:338-59.
7. Rosenthal AR, Harbury C, Egbert PR, Rubenstein E. Use of a platelet-fibrinogen-thrombin mixture as a corneal adhesive: experiments with sutureless lamellar keratoplasty in the rabbit. *Invest Ophthalmol* 1975;14:872-5.
8. Rosenthal AR, Egbert PR, Harbury C, Hopkins JL, Rubenstein E. Use of platelet-fibrinogen-thrombin mixture to seal experimental penetrating corneal wounds. *Albrecht Von Graefes Arch Klin Exp Ophthalmol* 1978;207:111-5.
9. Pearl RM, Wustrack KO, Harbury C, Rubenstein E, Kaplan EN. Microvascular anastomosis using a blood product sealant-adhesive. *Surg Gynecol Obstet* 1977;144:227-31.
10. Silverberg GD, Harbury CB, Rubenstein E. A physiological sealant for cerebrospinal fluid leaks. *J Neurosurg* 1977;46:215-9.
11. Fischer H. A method of suture-free anastomosis of nerve transplantation is being reported, using facial nerve as the example (author's transl)]. *Laryngol Rhinol Otol (Stuttg)* 1979;58:154-6.



12. Knighton DR, Ciresi KF, Fiegel VD, Austin LL, Butler EL. Classification and treatment of chronic nonhealing wounds. Successful treatment with autologous platelet-derived wound healing factors (PDWHF). *Ann Surg* 1986;204:322-30.
13. Knighton DR, Doucette M, Fiegel VD, Ciresi K, Butler E, Austin L. The use of platelet derived wound healing formula in human clinical trials. *Prog Clin Biol Res* 1988;266:319-29.
14. Knighton DR, Ciresi K, Fiegel VD, Schumerth S, Butler E, Cerra F. Stimulation of repair in chronic, nonhealing, cutaneous ulcers using platelet-derived wound healing formula. *Surg Gynecol Obstet* 1990;170:56-60.
15. Whitman DH, Berry RL, Green DM. Platelet gel: an autologous alternative to fibrin glue with applications in oral and maxillofacial surgery. *J Oral Maxillofac Surg* 1997;55:1294-9.
16. Kingsley CS. Blood coagulation; evidence of an antagonist to factor VI in platelet-rich human plasma. *Nature* 1954;173:723-4.
17. Dohan Ehrenfest DM, Rasmusson L, Albrektsson T. Classification of platelet concentrates: from pure platelet-rich plasma (P-PRP) to leucocyte- and platelet-rich fibrin (L-PRF). *Trends Biotechnol* 2009;27:158-67.
18. Choukroun J, Adda F, Schoeffler C, Vervelle A. Une opportunité en parodontologie: Le PRF. *Implantodontie* 2001;42:55-62.
19. Dohan Ehrenfest DM, Del Corso M, Diss A, Mouhyi J, Charrier JB. Three-dimensional architecture and cell composition of a Choukroun's platelet-rich fibrin clot and membrane. *J Periodontol* 2010;81:546-55.
20. Anitua E. Plasma rich in growth factors: preliminary results of use in the preparation of sites for implants. *Int J Oral Maxillofac Implants* 1999;14:529-35.
21. Anitua E. The use of plasma-rich growth factors (PRGF) in oral surgery. *Pract proced aesthet dentistry* 2001;13:487-93.
22. Mishra A, Harmon K, Woodall J, Vieira A. Sports medicine applications of platelet rich plasma. *Curr Pharm Biotechnol* 2012;13:1185-95.
23. DeLong JM, Russell RP, Mazzocca AD. Platelet-rich plasma: the PAW classification system. *Arthroscopy* 2012;28:998-1009.

24. Del Fabbro M, Corbella S, Taschieri S, Francetti L, Weinstein R. Autologous platelet concentrate for post-extraction socket healing: a systematic review. *Eur J Oral Implantol* 2014;7:333-44.
25. Plachokova AS, Nikolidakis D, Mulder J, Jansen JA, Creugers NH. Effect of platelet-rich plasma on bone regeneration in dentistry: a systematic review. *Clin Oral Implants Res* 2008;19:539-45.
26. Martínez-Zapata MJ, Martí-Carvajal A, Solà I, Bolibar I, Angel Expósito J, RodríguezL, García J. Efficacy and safety of the use of autologous plasma rich in platelets for tissue regeneration: a systematic review. *Transfusion* 2009;49:44-56.
27. Kotsovilis S, Markou N, Pepelassi E, Nikolidakis D. The adjunctive use of platelet-rich plasma in the therapy of periodontal intraosseous defects: a systematic review. *J Periodontal Res* 2010;45:428-43.
28. Del Fabbro M, Bortolin M, Taschieri S, Weinstein R. Is platelet concentrate advantageous for the surgical treatment of periodontal diseases? A systematic review and meta-analysis. *J Periodontol* 2011;82:1100-11.
29. Del Fabbro M, Ceci C, Taschieri T. Systematic review on the effect of platelet concentrates for the surgical treatment of periodontal defects. *Dent Cadmos* 2013;81:138-45.
30. Panda S, Doraiswamy J, Malaiappan S, Varghese SS, Del Fabbro M. Additive effect of autologous platelet concentrates in treatment of intrabony defects: a systematic review and meta-analysis. *J Invest and Clin Dent* 2014;5:1-14.
31. Shah M, Deshpande N, Bharwani A, Nadig P, Doshi V, Dave D. Effectiveness of autologous platelet-rich fibrin in the treatment of intra-bony defects: A systematic review and meta-analysis. *J Indian Soc Periodontol* 2014;18:698-704.
32. Roselló-Camps À, Monje A, Lin GH, Khoshkam V, Chávez-Gatty M, Wang HL, Gargallo-Albiol J, Hernandez-Alfaro F. Platelet-rich plasma for periodontal regeneration in the treatment of intrabony defects: a meta-analysis on prospective clinical trials. *Oral Surg Oral Med Oral Pathol Oral Radiol* 2015;120:562-74.

33. Moraschini V, Barboza Edos S. Use of Platelet-Rich Fibrin Membrane in the Treatment of Gingival Recession: A Systematic Review and Meta-Analysis. *J Periodontol* 2016;87:281-90.
34. Lolato A, Bucchi C, Taschieri S, Kabbaney AE, Fabbro MD. Platelet concentrates for revitalization of immature necrotic teeth: a systematic review of the literature of the clinical studies. *Platelets* 2016;27:383-92.
35. Del Fabbro M, Lolato A, Bucchi C, Taschieri S, Weinstein RL. Autologous Platelet Concentrates for Pulp and Dentin Regeneration: A Literature Review of Animal Studies. *J Endod* 2016;42:250-7.
36. Fennis JP, Stoelinga PJ, Jansen JA. Mandibular reconstruction: a histological and histo-morphometric study on the use of autogenous scaffolds, particulate cortico-cancellous bone grafts and platelet rich plasma in goats. *Int J Oral Maxillofac Surg* 2004;33:48–55.
37. Magesh DP, Kumaravelu C, Maheshwari GU. Efficacy of PRP in the reconstruction of mandibular segmental defects using iliac bone grafts. *J Maxillofac Oral Surg* 2013;12:160–7.
38. Hakimi M, Grassmann JP, Betsch M, Schneppendahl J, Gehrman S, Hakimi AR, et al. The composite of bone marrow concentrate and PRP as an alternative to autologous bone grafting. *PLOS ONE* 2014;9:e100143.
39. Hatakeyama I, Marukawa E, Takahashi Y, Omura K. Effects of platelet-poor plasma, platelet-rich plasma, and platelet-rich fibrin on healing of extraction sockets with buccal dehiscence in dogs. *Tissue Eng Part A* 2014;20:874–82.
40. Badr M, Coulthard P, Alissa R, Oliver R. The efficacy of platelet-rich plasma in grafted maxillae. A randomised clinical trial. *Eur J Oral Implantol* 2010;3:233–44.
41. Choi BH, Im CJ, Huh JY, Suh JJ, Lee SH. Effect of platelet-rich plasma on bone regeneration in autogenous bone graft. *Int J Oral Maxillofac Surg* 2004;33:56–9.
42. Thor A, Franke-Stenport V, Johansson CB, Rasmusson L. Early bone formation in human bone grafts treated with platelet-rich plasma: preliminary histomorphometric results. *Int J Oral Maxillofac Surg* 2007;36: 1164–71.

43. Lemos CA, Mello CC, dos Santos DM, Verri FR, Goiato MC, Pellizzer EP. Effects of platelet-rich plasma in association with bone grafts in maxillary sinus augmentation: a systematic review and meta-analysis. *Int J Oral Maxillofac Surg* 2016;45:517-25.
44. Del Fabbro M, Bortolin M, Taschieri S, Weinstein RL. Effect of autologous growth factors in maxillary sinus augmentation: a systematic review. *Clin Implant Dent Relat Res* 2013;15:205-16.
45. Rickert D, Slater JJ, Meijer HJ, Vissink A, Raghoobar GM. Maxillary sinus lift with solely autogenous bone compared to a combination of autogenous bone and growth factors or (solely) bone substitutes. A systematic review. *Int J Oral Maxillofac Surg* 2012;41:160-7.
46. Bae JH, Kim YK, Myung SK. Effects of platelet-rich plasma on sinus bone graft: meta-analysis. *J Periodontol* 2011;82:660-7.
47. Streckbein P, Kleis W, Buch RS, Hansen T, Weibrich G. Bone healing with or without platelet-rich plasma around four different dental implant surfaces in beagle dogs. *Clin Implant Dent Relat Res* 2014;16:479-86.
48. Thor AL, Hong J, Kjeller G, Sennerby L, Rasmusson L. Correlation of platelet growth factor release in jawbone defect repair--a study in the dog mandible. *Clin Implant Dent Relat Res* 2013;15:759-68.
49. Weibrich G, Hansen T, Kleis W, Buch R, Hitzler WE. Effect of platelet concentration in platelet-rich plasma on peri-implant bone regeneration. *Bone* 2004;34:665-71.
50. Anitua EA. Enhancement of osseointegration by generating a dynamic implant surface. *J Oral Implantol* 2006;32:72-6.
51. Anitua E, Orive G, Pla R, Roman P, Serrano V, Andía I. The effects of PRGF on bone regeneration and on titanium implant osseointegration in goats: a histologic and histomorphometric study. *J Biomed Mater Res A* 2009;91:158-65.
52. Zechner W, Tangl S, Tepper G, Fürst G, Bernhart T, Haas R, Mailath G, Watzek G. Influence of platelet-rich plasma on osseous healing of dental implants: a

- histologic and histomorphometric study in minipigs. *Int J Oral Maxillofac Implants* 2003;18:15-22.
53. Nikolidakis D, van den Dolder J, Wolke JG, Stoelinga PJ, Jansen JA. The effect of platelet-rich plasma on the bone healing around calcium phosphate-coated and non-coated oral implants in trabecular bone. *Tissue Eng* 2006;12:2555-63.
54. Nikolidakis D, van den Dolder J, Wolke JG, Jansen JA. Effect of platelet-rich plasma on the early bone formation around Ca-P-coated and non-coated oral implants in cortical bone. *Clin Oral Implants Res* 2008;19:207-13.
55. Georgakopoulos I, Tsantis S, Georgakopoulos P, Korfiatis P, Fanti E, Martelli M, Costaridou L, Petsas T, Panayiotakis G, Martelli FS. The impact of Platelet Rich Plasma (PRP) in osseointegration of oral implants in dental panoramic radiography: texture based evaluation. *Clin Cases Miner Bone Metab* 2014;11:59-66.
56. Kutkut A, Andreana S, Monaco E Jr. Clinical and radiographic evaluation of single-tooth dental implants placed in grafted extraction sites: a one-year report. *J Int Acad Periodontol* 2013;15:113-24.
57. Rosano G, Taschieri S, Del Fabbro M. Immediate postextraction implant placement using plasma rich in growth factors technology in maxillary premolar region: a new strategy for soft tissue management. *J Oral Implantol* 2013;39:98-102.
58. Anitua E, Alkhrasat MH, Miguel-Sánchez A, Orive G. Surgical correction of horizontal bone defect using the lateral maxillary wall: outcomes of a retrospective study. *J Oral Maxillofac Surg* 2014;72:683-93.
59. Jeong SM, Lee CU, Son JS, Oh JH, Fang Y, Choi BH. Simultaneous sinus lift and implantation using platelet-rich fibrin as sole grafting material. *J Craniomaxillofac Surg* 2014;42:990-4.
60. Tajima N, Ohba S, Sawase T, Asahina I. Evaluation of sinus floor augmentation with simultaneous implant placement using platelet-rich fibrin as sole grafting material. *Int J Oral Maxillofac Implants* 2013;28:77-83.

61. Taschieri S, Corbella S, Del Fabbro M. Mini-invasive osteotome sinus floor elevation in partially edentulous atrophic maxilla using reduced length dental implants: interim results of a prospective study. *Clin Implant Dent Relat Res* 2014;16:185-93.
62. Del Fabbro M, Corbella S, Ceresoli V, Ceci C, Taschieri S. Plasma Rich in Growth Factors Improves Patients' Postoperative Quality of Life in Maxillary Sinus Floor Augmentation: Preliminary Results of a Randomized Clinical Study. *Clin Implant Dent Relat Res* 2015;17:708-16.
63. Anitua E, Piñas L, Begoña L, Orive G. Long-term retrospective evaluation of short implants in the posterior areas: clinical results after 10-12 years. *J Clin Periodontol* 2014;41:404-11.
64. Esposito M, Felice P, Worthington HV. Interventions for replacing missing teeth: augmentation procedures of the maxillary sinus. *Cochrane Database Syst Rev* 2014 Cd008397.
65. Aghaloo TL, Moy PK. Which hard tissue augmentation techniques are the most successful in furnishing bony support for implant placement? *Int J Oral Maxillofac Implants* 2007;22 Suppl:49-70.
66. Nisand D, Renouard F. Short implant in limited bone volume. *Periodontol 2000* 2014;66:72-96.
67. Thoma DS, Zeltner M, Hüsler J, Hämmerle CH, Jung RE. EAO Supplement Working Group 4 - EAO CC 2015 Short implants versus sinus lifting with longer implants to restore the posterior maxilla: a systematic review. *Clin Oral Implants Res* 2015;26 Suppl 11:154-69.
68. Lee SA, Lee CT, Fu MM, Elmisalati W, Chuang SK. Systematic review and meta-analysis of randomized controlled trials for the management of limited vertical height in the posterior region: short implants (5 to 8 mm) vs longer implants (> 8 mm) in vertically augmented sites. *Int J Oral Maxillofac Implants* 2014;29:1085-97.

69. Lemos CA, Ferro-Alves ML, Okamoto R, Mendonça MR, Pellizzer EP. Short dental implants versus standard dental implants placed in the posterior jaws: A systematic review and meta-analysis. *J Dent* 2016;47:8-17.
70. Fan T, Li Y, Deng WW, Wu T, Zhang W. Short Implants (5 to 8 mm) Versus Longer Implants (>8 mm) with Sinus Lifting in Atrophic Posterior Maxilla: A Meta-Analysis of RCTs. *Clin Implant Dent Relat Res* 2016. doi: 10.1111/cid.12432. [Epub ahead of print].
71. Thoma DS, Haas R, Tutak M, Garcia A, Schincaglia GP, Hämmerle CH. Randomized controlled multicentre study comparing short dental implants (6 mm) versus longer dental implants (11-15 mm) in combination with sinus floor elevation procedures. Part 1: demographics and patient-reported outcomes at 1 year of loading. *J Clin Periodontol* 2015;42:72-80.
72. Drago L, Bortolin M, Vassena C, Taschieri S, Del Fabbro M. Antimicrobial activity of pure platelet-rich plasma against microorganisms isolated from oral cavity. *BMC Microbiol* 2013;13:47.
73. Drago L, Bortolin M, Vassena C, Romanò CL, Taschieri S, Del Fabbro M. Plasma components and platelet activation are essential for the antimicrobial properties of autologous platelet-rich plasma: an in vitro study. *PloS one* 2014;9:e107813.
74. Del Fabbro M, Bortolin M, Taschieri S, Ceci C, Weinstein RL. Antimicrobial properties of platelet-rich preparations. A systematic review of the current pre-clinical evidence. *Platelets* 2016;27:276-85.
75. Ceci C, Niada S, Del Fabbro M, Lolato A, Taschieri S, Giannasi C, Brini AT. Does Freeze-Thawing Influence the Effects of Platelet Concentrates? An In Vitro Study on Human Adipose-Derived Stem Cells. *J Craniofac Surg* 2016;27:398-404.
76. Del Fabbro M, Ceresoli V, Lolato A, Taschieri S. Effect of platelet concentrate on quality of life after periradicular surgery: a randomized clinical study. *J Endod* 2012;38:733-9.
77. Taschieri S, Corbella S, Tsesis I, Del Fabbro M. Impact of the use of plasma rich in growth factors (PRGF) on the quality of life of patients treated with

- endodontic surgery when a perforation of sinus membrane occurred. A comparative study. *Oral Maxillofac Surg* 2014;18:43-52.
78. Del Fabbro M, Corbella S, Ceresoli V, Ceci C, Taschieri S. Plasma rich in growth factors improves patients' postoperative quality of life in maxillary sinus floor augmentation: preliminary results of a randomized clinical study. *Clin Impl Dent Rel Res* 2015;17:708-16.
79. Taschieri S, Testori T, Corbella S, Weinstein R, Francetti L, Di Giancamillo A, Del Fabbro M. Platelet-Rich Plasma and Deproteinized Bovine Bone Matrix in Maxillary Sinus Lift Surgery: A Split-Mouth Histomorphometric Evaluation. *Implant Dent* 2015;24:592-7.
80. de Girolamo L, Sartori MF, Arrigoni E et al. Human adipose-derived stem cells as future tools in tissue regeneration: Osteogenic differentiation and cell-scaffold interaction. *Int J Artif Organs* 2008;31:467-79.
81. Bodo M, Lilli C, Bellucci C et al. Basic fibroblast growth factor autocrine loop controls human osteosarcoma phenotyping and differentiation. *Mol Med* 2002;8:393-404.
82. World Medical Association Declaration of Helsinki: ethical principles for medical research involving human subjects *JAMA* 2000;284:3043-45.
83. Taschieri S, Corbella S, Del Fabbro M. Use of plasma rich in growth factor for schneiderian membrane management during maxillary sinus augmentation procedure. *J Oral Implantol* 2012;38:621-7.
84. Brini AT, Ceci C, Taschieri S, Niada S, Lolato A, Giannasi C, Mortellaro C, Del Fabbro M. Effect of an Activated Platelet Concentrate on Differentiated Cells Involved in Tissue Healing. *J Craniofac Surg* 2016;27:656-61.
85. Telleman G, Raghoobar GM, Vissink A, den Hartog L, Huddleston Slater JJ, Meijer HJ. A systematic review of the prognosis of short (<10 mm) dental implants placed in the partially edentulous patient. *J Clin Periodontol* 2011;38:667-76.



86. Mezzomo LA, Miller R, Triches D, Alonso F, Shinkai RS. Meta-analysis of single crowns supported by short (<10 mm) implants in the posterior region. *J Clin Periodontol* 2014;41:191-213.
87. Renouard F, Nisand D. Impact of implant length and diameter on survival rates. *Clin Oral Implants Res* 2006;17 Suppl 2:35-51.
88. Esposito M, Cannizzaro G, Soardi E, Pistilli R, Piattelli M, Corvino V, Felice P. Posterior atrophic jaws rehabilitated with prostheses supported by 6 mm-long, 4 mm-wide implants or by longer implants in augmented bone. Preliminary results from a pilot randomised controlled trial. *Eur J Oral Implantol* 2012;5:19–33.
89. Pistilli R, Felice P, Cannizzaro G, Piattelli M, Corvino V, Barausse C, Buti J, Soardi E, Esposito M. Posterior atrophic jaws rehabilitated with prostheses supported by 6 mm long 4 mm wide implants or by longer implants in augmented bone. One-year post-loading results from a pilot randomised controlled trial. *Eur J Oral Implantol* 2013;6:359–72 [a].
90. Gulje FL, Raghoobar GM, Vissink A, Meijer HJ. Single crowns in the resorbed posterior maxilla supported by either 6-mm implants or by 11-mm implants combined with sinus floor elevation surgery: a 1-year randomised controlled trial. *Eur J Oral Implantol* 2014;7:247–55.
91. Esposito M, Pellegrino G, Pistilli R, Felice P. Rehabilitation of posterior atrophic edentulous jaws: prostheses supported by 5 mm short implants or by longer implants in augmented bone? One-year results from a pilot randomised clinical trial. *Eur J Oral Implantol* 2011;4:21–30.
92. Pistilli R, Felice P, Piattelli M, Gessaroli M, Soardi E, Barausse C, Buti J, Corvino, V. Posterior atrophic jaws rehabilitated with prostheses supported by 5 x 5 mm implants with a novel nanostructured calcium-incorporated titanium surface or by longer implants in augmented bone. One-year results from a randomised controlled trial. *Eur J Oral Implantol* 2013;6:343–57 [b].
93. Felice P, Checchi V, Pistilli R, Scarano A, Pellegrino G, Esposito M. Bone augmentation versus 5-mm dental implants in posterior atrophic jaws. Four-

- month post-loading results from a randomised controlled clinical trial. *Eur J Oral Implantol* 2009;2:267–81.
94. Felice P, Pistilli R, Piattelli M, Soardi E, Corvino V, Esposito M. Posterior atrophic jaws rehabilitated with prostheses supported by 5 x 5 mm implants with a novel nanostructured calcium-incorporated titanium surface or by longer implants in augmented bone. Preliminary results from a randomised controlled trial. *Eur J Oral Implantol* 2012;5:149–61.
95. Lee JH, Frias V, Lee KW, Wright RF. Effect of implant size and shape on implant success rates: a literature review. *J Prosthet Dent* 2005;94:377-81.
96. Aparicio C, Gil FJ, Planell JA, Engel E. Human-osteoblast proliferation and differentiation on grit-blasted and bioactive titanium for dental applications. *J Mater Sci Mater Med* 2002;13:1105-11.
97. Kawase T, Okuda K, Saito Y, Amizuka N, Suzuki H, Yoshie H. Platelet-rich plasma provides nucleus for mineralization in cultures of partially differentiated periodontal ligament cells. *In Vitro Cell Dev Biol Anim* 2005;41:171–6.
98. Kanno T, Takahashi T, Tsujisawa T, Ariyoshi W, Nishihara T. Platelet-rich plasma enhances human osteoblast-like cell proliferation and differentiation. *J Oral Maxillofac Surg* 2005;63:362-9.
99. Creeper F, Lichanska AM, Marshall RI, Seymour GJ, Ivanovski S. The effect of platelet-rich plasma on osteoblast and periodontal ligament cell migration, proliferation and differentiation. *J Periodontal Res* 2009;44:258-65.
100. Clausen C, Hermund NU, Donatsky O, Nielsen H, Osther K. Homologous activated platelets stimulate differentiation and proliferation of primary human bone cells. *Cells Tissues Organs* 2006;184:68-75.
101. Goto H, Matsuyama T, Miyamoto M, Yonamine Y, Izumi Y. Platelet-rich plasma/osteoblasts complex induces bone formation via osteoblastic differentiation following subcutaneous transplantation. *J Periodontal Res* 2006;41:455-62.

102. He L, Lin Y, Hu X, Zhang Y, Wu H. A comparative study of platelet-rich fibrin (PRF) and platelet-rich plasma (PRP) on the effect of proliferation and differentiation of rat osteoblasts in vitro. *Oral Surg Oral Med Oral Pathol Oral Radiol Endod* 2009;108:707-13.
103. Cheah CW, Vaithilingam R, Siar, CH, Swaminathan D, Hornbuckle GC. Histologic, Histomorphometric, and Cone-Beam Computerized Tomography Analyses of Calcium Sulfate and Platelet-Rich Plasma in Socket Preservation: A Pilot Study. *Implant Dent* 2014;23:593–601
104. Durmuşlar MC, Alpaslan C, Alpaslan G, Çakır M. Clinical and radiographic evaluation of the efficacy of platelet-rich plasma combined with hydroxyapatite bone graft substitutes in the treatment of intra-bony defects in maxillofacial region. *Acta Odontol Scand* 2014;72:948-53.

# **Chapter VII:**

---

# **Acknowledgments**

*Vorrei innanzitutto ringraziare il Professore Roberto Weinstein per avermi accolto nel suo gruppo, aver creduto in me fin dall'inizio e avermi dato l'opportunità, in questi anni non limitati ai soli tre anni di dottorato, di lavorare con il suo gruppo di ricercatori, professori e clinici del reparto da lui diretto.*

*Ringrazio il Professore Massimo Del Fabbro per i suoi preziosi insegnamenti e per avermi dato la possibilità di lavorare con lui in tutti questi anni.*

*Ringrazio il Dott. Silvio Taschieri per il suo punto di vista clinico sempre fondamentale, per avermi accolto nella sua stanza e aver colorato le mie giornate al Galeazzi.*

*Un ringraziamento speciale a Linda, che per me è stata più che la segretaria del Direttore, è stata il mio appiglio, e la ringrazio per tutti i consigli, le chiacchierate, le risate, i pranzi passati insieme e anche per i momenti più difficili, lei c'è sempre stata e mi ha sempre svoltato la giornata.*

*Ringrazio le mie colleghe, Monica e Valentina, per essere state delle ottime compagne di questo viaggio e per avermi dato un supporto morale e consigli quando ne ho avuto bisogno, soprattutto in quest'ultimo anno e mezzo.*

*Ringrazio Stefano, per essere sempre stato disponibile ad ascoltare i miei lamenti e sfoghi e per avermi fatto ridere di gusto ogni volta che passava a trovarci.*

*Ringrazio infine la mia famiglia senza la quale questo non sarebbe mai potuto succedere.*

*Un grazie anche ai miei amici, poiché nonostante gli anni passati lontano da casa comincino ad essere davvero tanti, quando ci vediamo è come se ci fossimo visti il giorno prima.*