

Section Editors

Robert C. Griggs, MD
Rochester, New York

Jerry R. Mendell, MD
Columbus, Ohio

Robert G. Miller, MD
San Francisco, California

We describe clinical, pathological, and muscle imaging findings in a patient with an early adult-onset progressive muscular weakness in association with atrophy beginning in the legs and involving both gastrocnemi in particular. Muscle biopsy findings showed a severe dystrophic process with no vacuoles, consistent with Miyoshi's myopathy. Computerized tomography and magnetic resonance imaging scans were used to provide an ongoing permanent record of the various stages of the disease. © 1996 John Wiley & Sons, Inc.

Key words: distal myopathy • computerized tomography imaging • magnetic resonance imaging • Miyoshi's myopathy • muscular dystrophy

MUSCLE & NERVE 19:1476-1480 1996

COMPUTERIZED TOMOGRAPHY AND MAGNETIC RESONANCE MUSCLE IMAGING IN MIYOSHI'S MYOPATHY

GIOVANNI MEOLA, MD, VALERIA SANSONE, MD, GIUSEPPE ROTONDO, MD, and ANTOINE JABBOUR, MD

Patients with primarily distal weakness and histological evidence pointing to muscular dystrophy are rare. These disorders are characterized clinically by distal weakness and atrophy beginning in the muscles of the hands or feet, without abnormalities of the cranial innervated muscles, sensory loss, or signs indicating an involvement of the central nervous system. Some cases progress to involve the proximal muscles. The age of onset varies while heredity includes sporadic, autosomal recessive, and dominant forms. Muscle biopsy demonstrates progressive muscle degeneration, often associated with a vacuolar myopathy for which there is no known etiology. This report describes a patient with Miyoshi's myopathy whose clinical features were progressive muscular weakness and atrophy beginning in the legs associated with a dystrophic process in the skeletal muscles. We performed muscle computerized tomography and magnetic resonance imaging scans to confirm the predominant site of involvement (posterior compartment of the legs), to obtain morphological information about deep-seated muscles

that cannot be assessed clinically, and to provide objective information on muscles that can be stored in the form of images for review once the disease has reached a later stage. These muscle imaging techniques are also a potential tool for the study of the natural history of patients with Miyoshi's myopathy.

CASE REPORT

A.S. (IV-5) is a 39-year-old man, son of consanguineous healthy parents (III-1 and III-2) (Fig. 1), who was in good health until age 11 when he started experiencing difficulties in walking; he had difficulty in placing his feet, especially the left one, correctly on the ground, as if he suffered from pes planus. This difficulty in walking got gradually worse so that at age 12 he started wearing arch-support shoes with scarcely any advantage. By the age of 18 he had developed an increasing muscular atrophy affecting muscles of the anterolateral and posterior compartment of the legs with particular involvement of both gastrocnemi; he started suffering from pain in his feet and knees and sought medical advice. He was given antiflogistic drugs, which partially alleviated the pain. Since then, the distal weakness described has worsened and extended toward the proximal muscles of his lower limbs so that walking is still possible but only for short distances and there is a definite bilateral footdrop; he now displays a typical waddling gait and cannot climb stairs. Toe extension is still possible bilaterally (Fig. 2b). Family history is negative for neuromuscular diseases. The patient's daughters of 6 and 3 years of age (V-4 and V-5) have been tested for creatine kinase (CK) levels and these were normal.

From the Department of Neurology, Division of Neurology I, (Drs. Meola, Sansone, and Rotondo), and Department of CT and MRI (Dr. Jabbour), University of Milan, San Donato Hospital, Milan, Italy.

Address reprint requests to Prof. G. Meola, Director of Neurology I, University of Milan, San Donato Hospital, Via Morandi 30, 20097 San Donato Milanese, Milan, Italy.

Acknowledgments: This work was supported by MURST 60%. We are grateful to Alasdair McEwen for scrutinizing the English.

Accepted for publication April 22, 1996.

CCC 0148-639X/96/111476-05
© 1996 John Wiley & Sons, Inc.

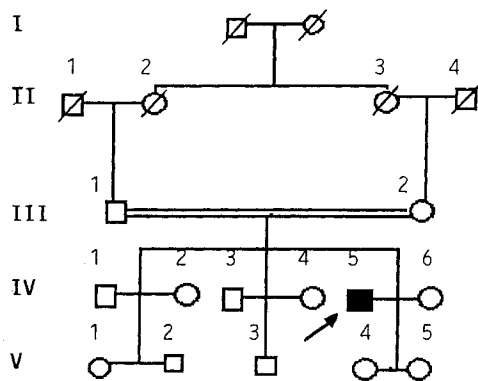


FIGURE 1. Family pedigree of patient with Miyoshi's myopathy. See text for detailed explanation.

Neurological Examination. No abnormalities of the cranial innervated muscles were found, while upper limb strength was unimpaired. In the lower extremities the patient had a severe distal atrophy especially evident in both gastrocnemii and there was definite back-kneeing (Fig. 2a) so that he was unable to hop on one leg and he could stand upright only with a hyperlordic posture and a broad base; he displayed severe distal muscle weakness (anterior and posterior tibialis grade 2 MRC grading) and a less prominent impairment of proximal muscles (quadriceps grade 4 MRC grading); knee extension was weaker than knee flexion. He had a clear bilateral footdrop and his gait was waddling. Deep tendon reflexes were abolished in all four limbs.

Laboratory Investigations and Diagnostic Procedures. Serum blood studies were normal except for CK levels between 3000 and 4000 U/L (increased by 15–20 times) and a twofold increase in alanine aminotransferase (ALT) and aspartate aminotransferase (AST). Electrocardiography, Echocardiography, and respiratory function were within the normal ranges.

Electromyography (EMG). EMG studies demonstrated that there were no voluntary motor unit potentials or involuntary fibrillation potentials or fasciculations in either gastrocnemius; in the other muscles investigated, short and long duration muscle potentials with reduced and increased amplitude were present. Polyphasic action potentials were also present.

Muscle Biopsy. The left quadriceps muscle showed a clear dystrophic process. There was a highly marked variation in fiber diameter, with some atrophic and hypertrophic fibers (up to 200 μ m), and an increase in central nuclei and fiber splitting with some necrotic fibers undergoing phagocytosis by

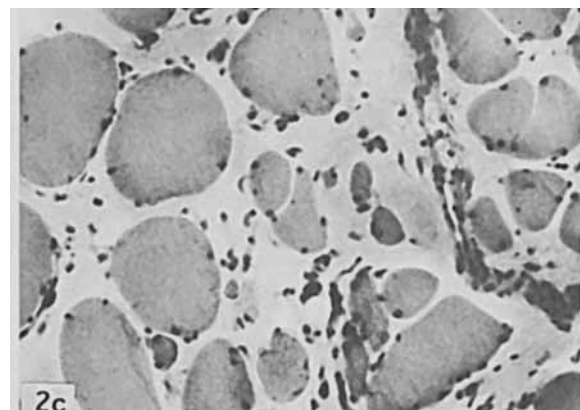
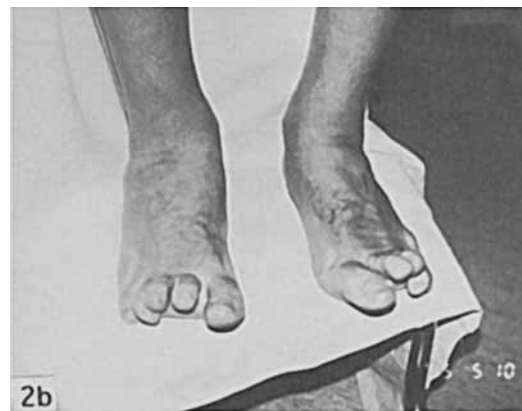
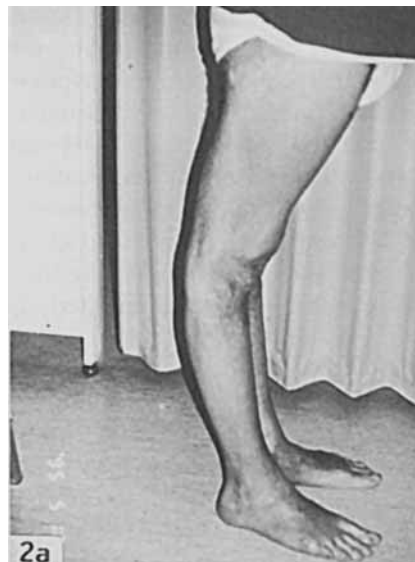
FIGURE 2. (a) Notice the prominent back-kneeing and severe distal atrophy compared to the relative hypertrophy of the quadriceps muscle; (b) toe extension is the only spared movement in distal muscles of the lower limbs; (c) note the increase in endomysial connective tissue; central nuclei, muscle variability, and some necrotic and regenerative fibers; no vacuoles are present. Hematoxylin and eosin, original magnification $\times 100$.

mononuclear inflammatory cells while there were signs of regeneration in others. No vacuoles were seen. A marked increase in endo- and perimysial connective tissue was noted (Fig. 2c). Adenosine triphosphatase (ATPase) staining showed a good distribution and differentiation of fiber types with some type IIC muscle fibers. An altered pattern of distribution of oxidative activity by NADH-staining was found in some fibers with a "moth-eaten" appearance. A slight increase in acid phosphatase was found. No abnormalities in lipid and glycogen content were observed. Immunocytochemical dystrophin staining using antibodies directed against the COOH-, NH₂-, and mid-rod domains showed normal distribution in all fibers.

Computerized Tomography (CT) and Magnetic Resonance Imaging (MRI) Scans. CT scans of muscles (Figs. 3 and 4) were carried out according to a standardized protocol, using a General Electric GE 9800 without intravenous contrast. Seven axial CT planes

were imaged from the groin to the ankle.^{4,9} We adjusted the contrast levels for optimum visualization of muscle and soft tissue. MRI scans were carried out with a General Electric Signa 1.5 Tesla using spin-echo sequences and T1-weighted images from the thigh and from the calves as in CT examination (Figs. 3 and 4). In CT imaging (Figs. 3a, 3c, 4a, 4b) the muscles involved were hypodense with a well-defined peripheral rim due to epimysial connective tissue. Figure 3a shows a relatively symmetrical fatty replacement of muscle tissue in the quadriceps muscle, in accordance with our biopsy findings, and in the biceps femoris. This is clearly distinguishable from the relatively hyperdense spared muscles (gracilis, sartorius, and semimembranosus) of the thighs. These features are best represented by MRI scans (Fig. 3b) where T1-weighted images of affected muscles show a hyperintense signal comparable to that of subcutaneous fat. Figure 3c confirms the predominant and symmetrical site of involvement of the posterior and medial compartment of the legs of the thighs. The

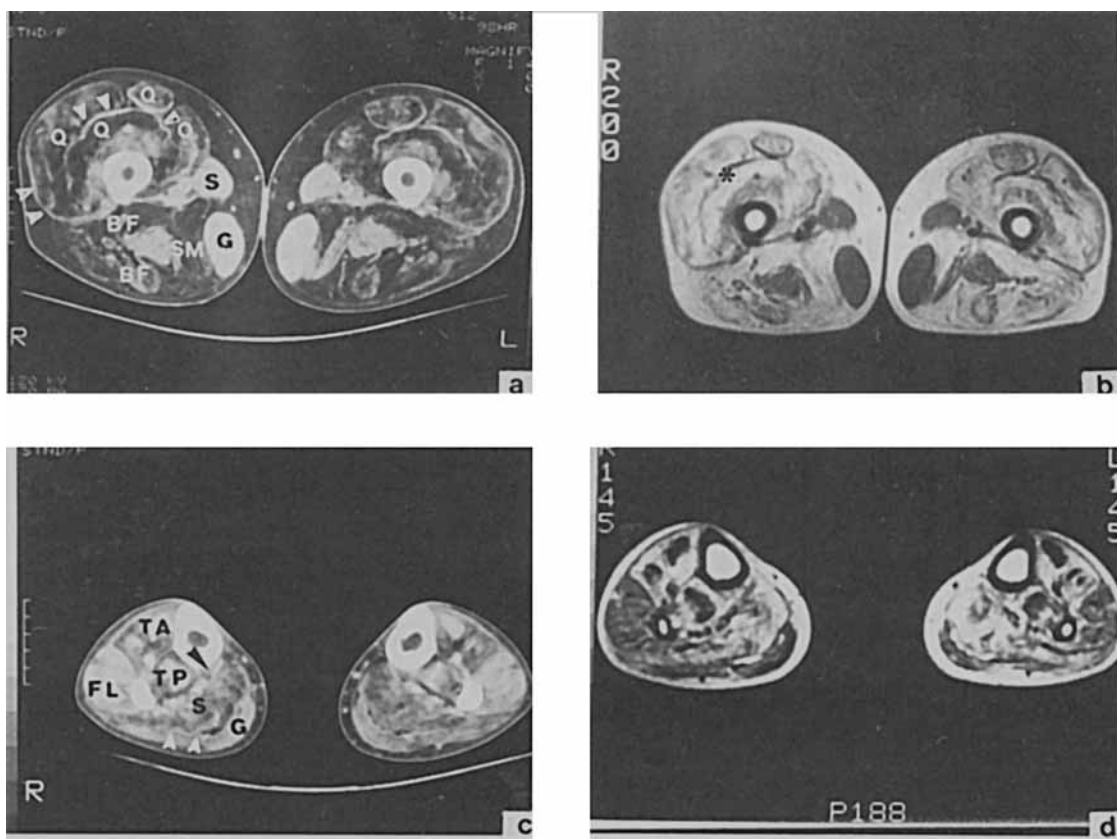


FIGURE 3. (a) Midthigh CT scans showing symmetrical and predominant involvement of both quadriceps (Q) and biceps femoris (BF) muscles with relative sparing of gracilis (G), sartorius (S), and semimembranosus (SM) muscles; (b) midthigh MRI scans showing affected muscles as relatively hyperintense with a signal comparable to that of subcutaneous fat (*); (c) note the predominant and symmetrical involvement of the posterior and medial compartment of the legs with affected soleus (S) and gastrocnemius (G) and spared tibialis anterior (TA), tibialis posterior (TP), and fibularis longus (FL). The peripheral rim due to epimysial connective tissue is indicated (arrow-heads) both in a and c; (d) MRI T1-weighted images show affected muscles as hyperintense.

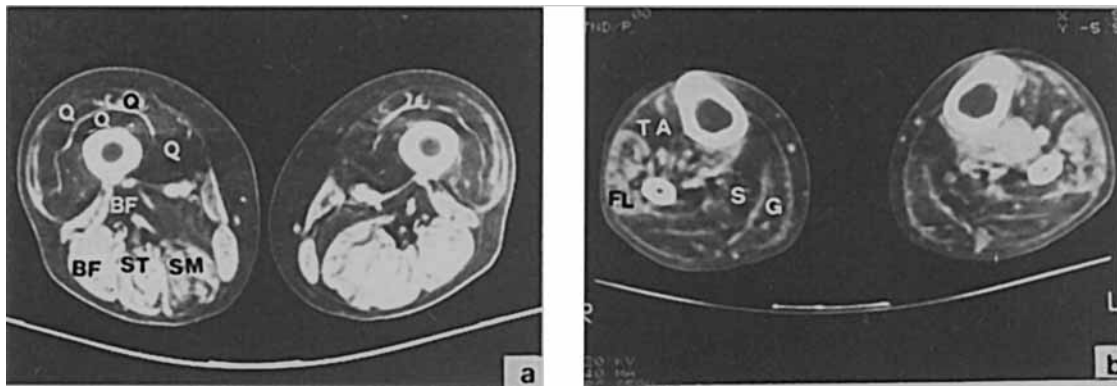


FIGURE 4. (a) Myotonic dystrophy midthigh CT scans showing an involvement of quadriceps (Q) with sparing of biceps femoris (BF), semitendinosus (ST), and semimembranosus (SM); (b) in the legs both anterior [tibialis anterior (TA)] and posterior compartments [gastrocnemius (G), soleus (S)] are affected, while peroneal muscles [fibularis longus (FL)] are spared.

peroneal, extensor digitalis, and tibialis anterior muscles have a normal or relatively normal density and morphology. T1-weighted sequences in MRI (Fig. 3d) offer the best representation of fatty infiltrated muscles compared to the relatively spared muscle groups. These findings of preferential involvement of the posterior compartment muscles of the lower limbs in Miyoshi's myopathy differ from the data obtained from another distal myopathy such as myotonic dystrophy. In this disease CT imaging of the thigh shows an involvement of the quadriceps while the biceps femoris, semitendinosus, and semimembranosus are spared (Fig. 4a), and in the leg both the tibialis anterior, soleus, and the gastrocnemii are affected, while peroneal muscles are spared (Fig. 4b).

DISCUSSION

The patient described above shows the characteristic clinical and laboratory features of the autosomal recessive adult-onset distal muscular dystrophy first reported by Miyoshi et al.⁷ and subsequently by others.^{1,2} The salient clinical features of this disorder are: (1) probable autosomal recessive inheritance, although sporadic cases have been described; (2) onset between 15 and 25 years of age; (3) early and predominant involvement of the gastrocnemii with relative sparing of the tibialis anterior; (4) CK values 15–20 times higher than normal; and (5) biopsy evidence of an active dystrophic process without vacuoles, especially evident in relatively spared muscle.^{1–3,5,6}

In our patient consanguinity is strongly suggestive of an autosomal recessive mode of inheritance; onset was at about 11 years old and was predominant in both gastrocnemii with relative sparing of the proximal lower limb muscles. No involvement of fa-

cial or upper limb muscles was noticed by the patient. CK levels were 20 times normal values. A distinctive feature of Miyoshi's myopathy compared to the other adult-onset distal myopathy (Nonaka's myopathy) is a less progressive course while the ability to stand and walk without assistance is maintained. As in Japanese and Western cases our patient shows a very slow progression. After a 30-year history and a 3-year follow-up, our patient is still ambulatory and the degree of muscle disability over a 3-year period suggests a relatively benign course; no signs of cardiomyopathy or multisystem involvement are present and the patient does not complain of any deterioration. Several points regarding the distribution of weakness and muscle biopsy findings in our patient deserve mention. Even though the quadriceps muscle and the biceps femoris were similarly affected on CT scans, in our patient knee extension (MRC 4) was weaker than knee flexion (MRC 5). The dystrophic changes noted in the quadriceps muscle biopsied are consistent with the progression of the dystrophic process in other muscle groups and show features comparable with those described previously with regard to the biceps femoris.¹ For this reason we suggest that the quadriceps muscle in these patients may also be the region of choice for diagnostic procedures. Nevertheless, in any given patient, there may be a considerable variation in the findings, depending on which muscle is biopsied; in our patient, as in other cases of Miyoshi's myopathy, vacuoles within muscle fibers have not been noted and frequent necrotic and regenerating fibers were found, in contrast with Nonaka's biopsy findings.⁸

To the best of our knowledge CT and MRI muscle imaging have never been used so far to assess the degree of neuromuscular involvement in cases of distal myopathies like the one described above. We

have assessed the information obtained by CT and by MRI imaging of distal and proximal lower limb muscles in relation to the conventional clinical assessment of patients with neuromuscular involvement to confirm the predominant site of muscle weakness and the degree of the dystrophic process in those muscle groups that have not been biopsied but prove to be affected by the dystrophic process. MRI also yielded better soft tissue resolution than CT and it was the most sensitive technique for detecting fatty infiltration. These techniques also permit the evaluation of individual muscles that can be clinically examined only as a group; marked imaging abnormalities in muscles where clinical testing had revealed only mild involvement (i.e., 4 MRC grading in the quadriceps) were found to be in striking contrast with normal imaging of clinically severely affected muscles (i.e., 2 MRC in the tibialis anterior). In conclusion, our study shows that CT and MRI imaging provide information that is not obtainable by clinical examination alone while the same techniques also make it possible to effect a potential quantitative evaluation of single muscle involvement, useful in the study of the natural history of Miyoshi's myopathy.^{4,9}

It is clear from this and from other reports that the distal myopathies are a heterogeneous group of disorders and that an increasing number of detailed studies of distal myopathies, including muscle imaging techniques, will permit a more precise classification of this syndrome. An important new scientific development is the linkage of Miyoshi's myopathy to

chromosome 2p12-14, as established by Bejaoui et al.³ in large informative families. More and more families with Miyoshi's myopathy will have to be studied in detail in order to diagnose symptomatic and presymptomatic patients. Such studies would also simplify prenatal and carrier diagnosis and ultimately help us to identify a gene responsible for this form of adult-onset distal myopathy.

REFERENCES

1. Barohn RJ, Miller RG, Griggs RC: Autosomal recessive distal dystrophy. *Neurology* 1991;41:1365-1370.
2. Barohn RJ: Distal myopathies and dystrophies. *Semin Neurol* 1993;13:247-255.
3. Bejaoui K, Hirabayashi K, Hentati F, Haines JL, Ben Hamida C, Belal S, Miller RG, McKenna-Yasek D, Weissenbach J, Rowland LP, Griggs RC, Munsat TL, Ben Hamida M, Arahata K, Brown RH: Linkage of Miyoshi myopathy (distal autosomal recessive muscular dystrophy) locus to chromosome 2p12-14. *Neurology* 1995;45:768-772.
4. Clague JE, Roberts N, Gibson H, Edwards RHT: Muscle imaging in health and disease. *Neuromusc Disord* 1995;5:171-178.
5. Griggs RC, Markesbery WR: Distal myopathies, in Engel AG, Franzini-Armstrong C (eds): *Myology*. New York, McGraw-Hill, 1994, vol 2, pp 1246-1257.
6. Markesbery WR, Griggs RC, Leach RP, Lapham LW: Late onset hereditary distal myopathy. *Neurology* 1974;23:127-134.
7. Miyoshi K, Kawai H, Iwasa M, Kusaka K, Nishino H: Autosomal recessive distal muscular dystrophy as a new type of progressive muscular dystrophy. *Brain* 1986;109:31-54.
8. Nonaka I, Sunohara N, Ishiura S, Satoyoshi E: Familial distal myopathy with rimmed vacuole and lamellar (myeloid) body formation. *J Neurol Sci* 1981;51:141-155.
9. Swash M, Brown MM, Thakkar C: CT muscle imaging and the clinical assessment of neuromuscular disease. *Muscle Nerve* 1995;18:708-714.