

# Research Letters

AIDS 2002, 16:2219–2227

## Thymic volume predicts long-term immune reconstitution in HIV-infected children treated with highly active antiretroviral therapy

Mario Clerici<sup>a</sup>, Marina Saresella<sup>c</sup>, Daria Trabattoni<sup>a</sup>, Pasquale Ferrante<sup>c</sup>, Angelo Vanzulli<sup>d</sup> and Alessandra Viganò<sup>b</sup>

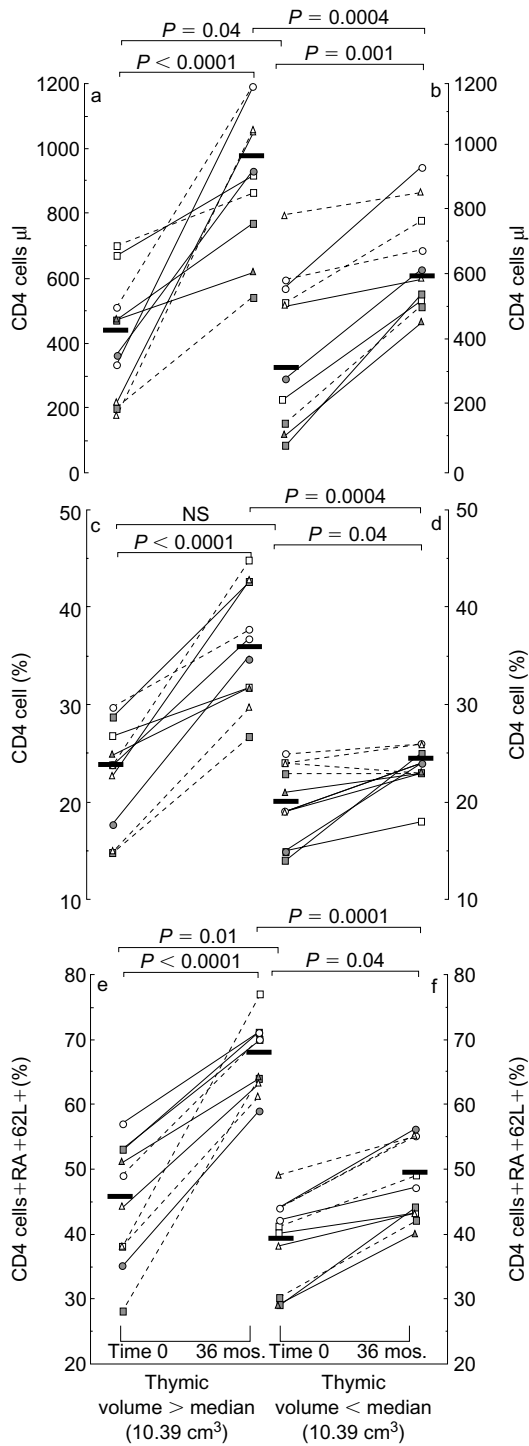
**Highly active antiretroviral therapy (HAART) suppresses viral replication and augments CD4 T cell counts. HAART-associated immune restoration is often difficult to predict. We verified whether increases in CD4 cells, and particularly in cells of the naive phenotype, would be associated in HAART-treated children with thymic volume. Long-term immune reconstitution is significantly better in children with bigger thymuses at the initiation of HAART. Thymic volume has a strong predictive value for the immunological effect of HAART.**

Highly active antiretroviral therapy (HAART) suppresses viral replication and augments CD4 T cells in HIV-infected individuals. The virological effect of HAART is highly reproducible; in contrast, the degree of immune restoration is variable among different patients and is difficult to predict [1,2]. CD4 T cells include both memory (CD4+CD45RO+) and naive (CD4+CD45RA+CD62L+) subpopulations. In HAART-treated adults, increases in CD4 T cells are for a long period of time supported by the redistribution of memory lymphocytes, whereas early increases in naive lymphocytes are seen in paediatric patients [2,3]. Because thymic maturation and selection lead to the generation of naive T cells, we verified whether the degree of HAART-associated immune reconstitution was associated with thymic volume. We report here that immune reconstitution after 3 years of therapy is significantly better in children with bigger thymuses at the initiation of HAART. Thymic volume thus has a strong predictive value for the immunological effect of HAART.

Thymus evaluation was performed using magnetic resonance imaging in 20 HIV vertically infected children. Using this technology, thymic tissue appears sharply hypointense in comparison with mediastinal fat, and is easily distinguishable from vessels. Sagittal and axial slices (5 mm) were performed with a 1.5 T magnet with fast spin echo and T1 and T2 weighted acquisitions. Thymic dimensions were calculated

according to the formula:  $3.14/6 \times D1 \times D2 \times D3$  using the transverse diameter of the gland (D1) on the axial images and the antero-posterior (D2) and cranio-caudal (D3) diameters obtained from sagittal sections. The median thymic volume at baseline was 10.39 cm<sup>3</sup>; this value was used to divide children into those with a thymus bigger or smaller than the median. The mean age (10.6 versus 9.8 years) was comparable between the two groups of patients, who all had moderate-to-advanced disease according to the 1994 revised Centers for Disease Control and Prevention HIV classification. Children had previously been treated with zidovudine alone (eight patients) or in association with didanosine (12 patients), and were subsequently switched to HAART [lamivudine (4 mg/kg per 12 h) plus stavudine (1 mg/kg per 12 h) plus indinavir (500 mg/m<sup>2</sup> per 8 h)]. At baseline, HIV plasma viraemia (21 570 versus 18 758 copies/ml) was comparable in children with thymic volumes above or below the median. Absolute CD4 cell counts and the percentage of naive CD4 T lymphocytes were moderately higher in children with bigger thymuses (Fig. 1), whereas the percentage of CD4 T cells was similar between the two groups of patients.

Immunological and virological parameters were re-evaluated after 36 months of therapy. HAART was associated with a dramatic reduction in plasma viraemia in both groups of children (plasma viraemia < 80 RNA copies/ml in 19/20 individuals), whereas the effect of antiviral therapy on immune parameters was more conspicuous in children with thymic volumes above the median at baseline. HAART-associated increases in both CD4 cell counts and CD4 cell percentages were significantly more impressive in these children (Fig. 1a and c) compared with those with smaller thymuses at baseline (Fig. 1b and d). As a consequence, the median CD4:CD8 cell ratio increased from 0.48 to 1.19 ( $p < 0.0001$ ) in children with bigger thymuses and only from 0.34 to 0.57 (not significant) in children with smaller thymuses. Naive CD4 T lymphocytes drastically increased in children with bigger thymuses (Fig. 1e), and were only marginally modified in patients with smaller thymuses (Fig. 1f). Finally, HAART resulted in an augmentation of the thymus, which, again, was more evident when children with bigger thymuses (median 12.41 versus 21.81 cm<sup>3</sup>;  $P = 0.0005$ ) were compared with those with thymuses below the median at baseline (median 8.21 versus 10.73 cm<sup>3</sup>;  $P = 0.03$ ).



**Fig. 1.** CD4 cell absolute numbers (a,b), CD4 cell percentages (c,d), and percentages of CD4+RA+62L+ (naive) lymphocytes (e,f) in 20 HIV-infected children studied before the beginning of highly active antiretroviral therapy (baseline) and after 36 months of therapy. Panels a, c and e show values observed in children whose thymic volume determined by magnetic resonance imaging at baseline was above the median value of the group; panels b, d and f show values observed in children whose thymic volume was below the median value. Each symbol represents a different child. Mean values and statistical differences are shown.

HAART-associated suppression of HIV replication is very similar in different patients. In contrast, the degree of HAART-associated immune reconstitution is variable among individuals. No established marker predicts the degree of immune reconstitution in HAART-treated patients. In particular, immune reconstitution in children is independent of age and pre-therapy immune status [1], and has been suggested, but not proved, to be correlated with thymic function [4–6]. We studied the immunovirological effect of HAART in 20 HIV-infected children of similar age and comparable viraemia who underwent the same therapeutic regimen, and observed that, as expected, although HAART resulted in the suppression of virus replication in all children but one, increases in CD4 cell counts were highly variable. We report here that the size of thymus at baseline predicts the degree of long-term immune reconstitution of HAART, independent of the virological effects of therapy. This observation is novel, and expands on a previous report in adults [7], which suggested that thymus volume, measured after 48 weeks of therapy, could be associated with a larger increase in the pool of circulating CD4 T cells. Naive T cells are thymic efferent. In adults, in whom physiological thymic regression has taken place, these cells could be generated in thymic residues, in extra-thymic compartments, or can stem from CD45RO cells of the CD45RA phenotype [3]. Our data confirm that, similar to what has been shown after intensive chemotherapy or bone marrow transplant [8], the thymic pathway is of pivotal importance in the repopulation of peripheral blood with T lymphocytes in HIV-infected children undergoing HAART. More aggressive antiviral regimens or the use of immune modulators might be considered in patients with smaller thymuses.

Departments of <sup>a</sup>Immunology, and <sup>b</sup>Pediatrics IV, Milan University, 20157 Milan, Italy; <sup>c</sup>Biology Laboratory/Department of Virology, Don C. Gnocchi, Foundation IRCCS, 20148 Milan, Italy; and <sup>d</sup>Department of Radiology, Ospedale Maggiore, 20145 Milan, Italy.

*Sponsorship:* This work was supported by grants from the Istituto Superiore di Sanita 'Programma Nazionale di Ricerca sull'AIDS 1999'.

Received: 30 May 2002; accepted: 12 June 2002.

## References

1. Van Rossum AMC, Scherpbier HJ, van Lochem EG, *et al.* Therapeutic immune reconstitution in HIV-1 infected children is independent of their age and pretreatment immune status. *AIDS* 2001, **15**:2267–2275.
2. Pakker NG, Nothermans DW, De Boer RJ, *et al.* Biphasic kinetics of peripheral blood T cells after triple combination therapy in HIV-1 infection: a composite of redistribution and proliferation. *Nat Med* 1998, **4**:208–214.

3. Mackall CL, Gress RE. **Pathways of T-cell regeneration in mice and humans: implications for bone marrow transplantation and immunotherapy.** *Immunol Rev* 1997, **157**:61–72.
4. Douek DC, Koup RA, McFarland RD, Sullivan JL, Luzuriaga K. **Effect of HIV on thymic function before and after antiretroviral therapy in children.** *J Infect Dis* 2000, **181**:1479–1482.
5. Gibb DM, Newberry A, Klein N, *et al.* **Immune repopulation after HAART in previously untreated HIV-1-infected children.** *Lancet* 2000, **355**:1331–1332.
6. Teixeira L, Valdez H, McCune JM, *et al.* **Poor CD4 T cell restoration after suppression of HIV-1 replication may reflect lower thymic function.** *AIDS* 2001, **15**:1749–1756.
7. Smith KY, Valdez H, Landay A, *et al.* **Thymic size and lymphocyte restoration in patients with HIV infection after 48 weeks of zidovudine, lamivudine, and zalcitabine therapy.** *J Infect Dis* 2000, **181**:141–147.
8. Haynes BF, Mackert ML, Sempowski GD, *et al.* **The role of thymus in immune reconstitution in aging, bone marrow transplantation, and HIV-1 infection.** *Annu Rev Immunol* 2000, **18**:529–560.

### The boosting of didanosine by allopurinol permits a halving of the didanosine dosage

Johan R. Boelaert<sup>a</sup>, Geneviève M. Dom<sup>b</sup>, Alwin D.R. Huitema<sup>c</sup>, Jos H. Beijnen<sup>c</sup> and Joep M.A. Lange<sup>d</sup>

**The pharmacokinetic boosting of didanosine by allopurinol was studied in four HIV-1-positive patients taking didanosine, hydroxyurea and chloroquine, in whom the didanosine dosage was halved and allopurinol was added at 300 mg/day. Didanosine plasma levels and HIV-1-RNA levels remained unchanged after 4 and 17–20 months, respectively. Halving the didanosine dosage with allopurinol reduces treatment costs, and may lend itself to once-daily combination therapies, which are of particular interest for HIV therapy in resource-poor countries.**

Pharmacokinetic interactions are important in antiretroviral therapy and are sometimes deliberately used to potentiate anti-HIV-1 drugs. For instance, several protease inhibitors are boosted by ritonavir, because of the inhibition of selected P450 isoenzymes by ritonavir, which represent the major elimination pathway of these drugs. Nucleoside reverse transcriptase inhibitors (NRTI) are not eliminated by the P450 system and, in general, are less prone to pharmacokinetic interactions than protease inhibitors and non-nucleoside reverse transcriptase inhibitors. The potentiation of NRTI, and in particular of didanosine by hydroxyurea, is not caused by a pharmacokinetic interaction but the cellular effects of hydroxyurea that favour the NRTI-induced inhibition of reverse transcriptase [1].

We wish to draw attention to the potential usefulness of the pharmacokinetic interaction between didanosine and allopurinol. This xanthine-oxidase inhibitor, used for decades to inhibit uric acid synthesis, increases the plasma levels of didanosine in both rats and humans,

suggesting that the purine nucleoside didanosine undergoes an important first-pass effect mediated by xanthine-oxidase, an enzyme present in both the intestinal wall and the liver [2]. In two oral single-dose studies in 14 healthy human volunteers and seven HIV-infected individuals, respectively, pretreatment with 300 mg allopurinol a day for 7 days doubled the peak plasma levels ( $C_{max}$ ) and the total area-under-the-plasma-concentration-time curves of didanosine, without affecting its terminal half-life [2,3]. This enhanced oral systemic bioavailability of didanosine by the concomitant administration of allopurinol led us to hypothesize that co-treatment with allopurinol may allow the dosage of didanosine to be halved in HIV-1-infected patients.

We investigated this hypothesis in four treatment-naïve patients (three men and one woman, two Caucasians and two black individuals, aged 29–42 years) who had initiated therapy with didanosine, hydroxyurea and chloroquine. This anti-HIV-1 drug combination is based on the enhancement of the antiretroviral effect of didanosine by hydroxyurea [1], and on the additive antiviral effect of chloroquine, observed *in vitro* [4,5]. In the four patients studied, the combination of didanosine (four chewable tablets of 100 mg a day), hydroxyurea (500 mg twice a day) and chloroquine (100 mg a day) had resulted in a good virological response, with HIV-1-RNA plasma levels of less than 400 copies/ml (Amplicor; Roche Diagnostic Systems, Inc., Branchburg, NJ, USA) at 4–20 months (Table 1, column 4). The patients volunteered to participate in the trial, approved by the Institutional Ethical Committee, which consisted of switching their current therapy to a half-dose didanosine scheme, supplemented with allopurinol: didanosine two chewable tablets of 100 mg a day, taken on an empty stomach, together with allopurinol 300 mg a day, chloroquine base 100 mg a day and hydroxyurea 500 mg twice a day. In a further effort to simplify therapy and improve adherence, the patients were asked at between 4 and 8 months after the switch to take all medication daily (including hydroxyurea) on an empty stomach. The plasma levels of didanosine at 0.75 ( $C_{0.75}$ ) and 4 ( $C_4$ ) hours after intake were assayed by high-performance liquid chromatography [6] on three occasions: before the switch (didanosine dose 400 mg a day), as well as 1 and (in two patients) 4 months after the switch (didanosine dose 200 mg a day plus allopurinol). Plasma HIV-1-RNA levels and CD4 cell counts were monitored before this switch and in the subsequent months, with a post-switch follow-up ranging between 17 and 20 months.

As hypothesized and as shown in Table 1, the addition of allopurinol to the halved dose of didanosine did not result in significant changes in didanosine plasma levels, as measured by  $C_{0.75}$ ,  $C_4$  or area-under-the-concentra-

**Table 1. Results of co-administration of allopurinol and halving the dose of didanosine.**

Patient no.		At start of therapy	Before switching	After switching
1	HIV-1 RNA (copies/ml)	11 400	< 50	163
	CD4 cell count (cells/ $\mu$ l)	400 (23%)	410 (29%)	560 (24%)
	Plasma didanosine (ng/ml) (45/240 min)		1186/77	1031/99 <sup>a</sup>
	Plasma didanosine AUC (h $\times$ mg/l)		2044	835/102 <sup>b</sup> 1984 <sup>a</sup> 1772 <sup>b</sup>
2	HIV-1 RNA (copies/ml)	31 100	66	50
	CD4 cell count (cells/ $\mu$ l)	680 (31%)	640 (37%)	350 (20%)
	Plasma didanosine (ng/ml) (45/240 min)		1445/91	1575/85 <sup>a</sup>
	Plasma didanosine AUC (h $\times$ mg/l)		2420	2032/102 <sup>b</sup> 2539 <sup>a</sup> 3161 <sup>b</sup>
3	HIV-1 RNA (copies/ml)	11 990	< 50	< 50
	CD4 cell count (cells/ $\mu$ l)	360 (11%)	280 (17%)	230 (12%)
	Plasma didanosine (ng/ml) (45/240 min)		2044/64	2480/90 <sup>a</sup>
	Plasma didanosine AUC (h $\times$ mg/l)		2969	3616 <sup>a</sup>
4	HIV-1 RNA (copies/ml)	118 000	192	391
	CD4 cell count (cells/ $\mu$ l)	210 (11%)	170 (12%)	210 (10%)
	Plasma didanosine (ng/ml) (45/240 min)		2759/115	1435/150 <sup>a</sup>
	Plasma didanosine AUC (h $\times$ mg/l)		4075	2731 <sup>a</sup>

AUC, Area-under-the-concentration-time curve.

<sup>a</sup>1 month after the switch.

<sup>b</sup>4 months after the switch.

tion-time curve ( $p > 0.5$ ) at 1 month or 4 months after the switch. The switch did not cause a significant change in the plasma HIV-1-RNA levels, which remained suppressed at less than 400 copies/ml in all patients. The course of the CD4 cell count was variable, as expected with the use of hydroxyurea [1]. The therapy switch did not result in any adverse effect.

Although this pilot study was performed on a limited number of patients, it confirms the hypothesis that allopurinol boosts didanosine plasma levels, which allows the use of a half dose of didanosine. Furthermore, it indicates that this boosting persists after several months of concomitant treatment.

The observed boosting of didanosine by allopurinol may have implications for the choice of antiretroviral therapy in resource-poor countries, where both the cost of drugs and the simplicity of drug regimens are of major importance. First, allopurinol, an inexpensive generic compound, may allow the dosage and hence the cost of didanosine to be halved. Second, half-didanosine plus allopurinol may lend itself to combination therapy with other drugs in a once daily regimen, to be used or not in directly observed therapy. In the present study, half-didanosine plus allopurinol was combined with hydroxyurea and chloroquine daily. As concerns have arisen about the long-term safety of hydroxyurea [7,8], other compounds may be combined with half-dose didanosine plus allopurinol in a daily regimen, such as (among others) lamivudine and one of the non-nucleoside reverse transcriptase inhibitor drugs

nevirapine or efavirenz, with or without chloroquine [4]. However, the potential toxicity of allopurinol is well known and should be taken into account [9]. It is not known whether HIV-1 infection may affect the incidence of hypersensitivity reactions to this drug. The drug's tolerance may be tested by the administration of allopurinol as a single compound before its use in combination therapy. Clinical trials are required to study the long-term efficacy, tolerance and applicability of these new combinations in resource-poor settings.

## Acknowledgements

The authors would like to thank the patients for their collaboration in the present study.

<sup>a</sup>Department of Internal Medicine and Infectious Diseases, Algemeen Ziekenhuis St Jan, Brugge, Belgium; <sup>b</sup>Department of Biology, Université Catholique de Louvain, Bruxelles, Belgium; <sup>c</sup>Department of Pharmacy and Pharmacology, Slotervaart Ziekenhuis, Amsterdam, the Netherlands; and <sup>d</sup>National AIDS Therapy Evaluation Centre, Academic Medical Centre, Amsterdam, the Netherlands.

Part of this study was presented in abstract form at the 5th International Congress on Drug Therapy in HIV Infection, Glasgow, UK, 22–26 October 2000 [Abstract P236].

Received: 19 April 2002; accepted: 29 May 2002.

## References

1. Lori F. **Hydroxyurea and HIV: 5 years later – from antiviral to immunomodulating effects.** *AIDS* 1999, **13**:1433–1442.
2. Liang D, Breaux K, Nornoo A, Phadungpojna S, Rodriguez-Barradas M, Bates TR. **Pharmacokinetic interaction between didanosine (ddl) and allopurinol in healthy volunteers.** In: *39th Interscience Conference on Antimicrobial Agents and Therapy*. San Francisco, CA, USA, 26–29 September 1999, p. 25 [Abstract A662].
3. Liang D, Breaux K, Rodriguez-Barradas M, Bates TR. **Allopurinol increases didanosine (ddl) absorption in HIV-infected patients.** In: *41st Interscience Conference on Antimicrobial Agents and Therapy*. Chicago, IL, USA, December 2001, p. 16 [Abstract A498].
4. Boelaert JR, Sperber K, Piette J. **Chloroquine exerts an additive in vitro anti-HIV-1 effect, when associated with didanosine and hydroxyurea.** *AIDS Res Hum Retroviruses* 1999, **114**:1241–1247.
5. Savarino A, Gennero L, Chen HC, Malavasi F, Boelaert JR, Sperber K. **Anti-HIV effects of chloroquine: mechanisms of inhibition and spectrum of activity.** *AIDS* 2001, **15**:2221–2230.
6. Beijnen JH, Meenhorst PL, Rosing H, et al. **Analysis of 2',3'-dideoxyinosine (ddi) in plasma by isocratic high performance liquid chromatography with ultraviolet detection.** *J Drug Dev* 1990, **3**:127–133.
7. Moore RD, Keruly JC, Chaisson RE. **Incidence of pancreatitis in HIV-1 infected patients receiving nucleoside reverse transcriptase inhibitor drugs.** *AIDS* 2001, **15**:617–620.
8. Barreiro P, Soriano V, Valencia E, Diaz B, Gonzales-Lahoz J. **Low risk of pancreatitis in HIV-infected patients on hydroxyurea and didanosine.** *AIDS* 2001, **15**:2469–2470.
9. Martindale. *The complete drug reference*, 32rd ed. Parfitt K (editor). London: Pharmaceutical Press; 1999.

## Utility of patch testing in patients with hypersensitivity syndromes associated with abacavir

Elizabeth J. Phillips<sup>a,b,c</sup>, John R. Sullivan<sup>d</sup>, Sandra R. Knowles<sup>a,c</sup> and Neil H. Shear<sup>c</sup>

**A diagnostic test would be useful to help eliminate the associated morbidity and mortality after full-dose rechallenge with abacavir in patients with suspected hypersensitivity. We describe seven patients with syndromes compatible with abacavir hypersensitivity who had positive patch tests. Immunohistochemistry on skin biopsies from the acute prospectively identified patients with rash (n=3) matched those from positive-patch patients (n=7), suggesting an identical pathophysiological process. No patients developed systemic symptoms or signs during patch testing.**

Abacavir is a nucleoside analogue used in combination with other antiretroviral drugs for the treatment of HIV. Approximately 2–5% of patients starting abacavir will experience a hypersensitivity syndrome, most commonly characterized by combinations of fever, rash, malaise, nausea, vomiting and diarrhoea. Severe reactions such as shock and even death have been described with full dose rechallenge after the occurrence of the hypersensitivity syndrome [1].

Patch testing is an 'in-vivo' test that involves the application of dilute, non-irritating concentrations of the substance or drug in a vehicle such as petrolatum to the surface of the skin. There is significant experience with patch testing for the diagnosis of T cell-mediated processes such as allergic contact dermatitis. Patch testing is simple and inexpensive to perform. Currently there is limited information as to the use of patch testing for other potentially cell-mediated processes such as drug reactions [2]. The rationale for use in these reactions is supported by the potential metabolism of the parent drug to reactive metabolite in skin and the presence of resident CD8 cells from skin biopsies of patients with acute drug-induced hypersensitivity syndromes [3].

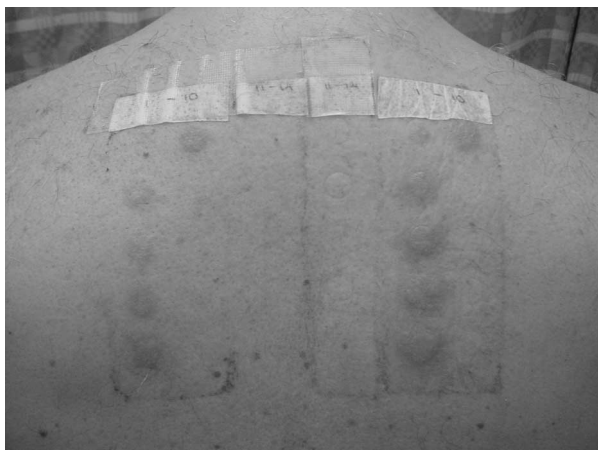
We describe seven patients who developed positive patch tests to abacavir within 4 months of a presumed abacavir hypersensitivity reaction (Table 1, Fig. 1). One patient (case 6) was identified 33 months after the initial reaction. Four patients were identified prospectively at the time of the reaction, and three were identified retrospectively after the initial reaction. All patients met a minimum case definition of probable abacavir hypersensitivity syndrome, defined as either having at least two intensifying symptoms of rash, fever, gastrointestinal complaints, headache and resolution within 24 h of stopping the drug without an alternative explanation or a positive rechallenge to abacavir. Rash occurred in three out of four prospectively identified patients as part of the acute reaction, with immunohistochemistry documented (Table 1). Patients and HIV-negative controls had one patch panel of 1% abacavir and 10% abacavir in a petrolatum base applied to the mid-back. All patches were taken off at 48 h. Reading took place at 48 and 96 h in cases 1 to 3. Cases 4 to 7 and four additional HIV-infected controls tolerating or known to have tolerated abacavir also had 0.1, 5, 15 and 25% abacavir added to the patch panel, with additional readings at 1, 24, 48 and 96 h. Two HIV-negative controls with no previous abacavir exposure and five HIV-positive controls with previous abacavir exposure matched for age, sex, race, CD4 cell count and viral load had negative patch tests at 48 and 96 h.

Patch testing was positive in seven patients with probable abacavir hypersensitivity and negative in seven controls. This may be an extremely useful diagnostic modality for identifying patients with true abacavir reactions. HIV patients are often started on multiple concurrent medications, making the implication of a single drug in a reaction difficult. The clinical diagnosis of abacavir hypersensitivity syndrome was further strengthened in our six out of seven patch test-positive patients by subsequent rechallenge and tolerance of other antiretroviral drugs that they were taking at the time of the initial reaction. The pathological

**Table 1. Clinical summary of patch test-positive patients.**

Case	Age/sex	Details of abacavir reaction	Concurrent drugs	Skin biopsy	Patch test	Patch test biopsy	Follow-up
1	32/M	Fever, myalgia and malaise 8 days after starting abacavir	d4T, 3TC, efavirenz, nelfinavir	N/A	Performed 4 months after acute reaction. Positive at all concentrations at 48 and 96 h	Lymphocytic vasculitis, CD4, CD8, HLA-DR, CD30-negative	Tolerating d4T, 3TC, nelfinavir, efavirenz
2	62/M	Fever, headache, malaise, nausea 9 days after starting abacavir, day 11 developed rash and hypotension	d4T, efavirenz	Lymphocytic vasculitis. CD4, CD8, HLA-DR, CD30-negative—	3 months after acute reaction. Positive at all concentrations at 48 and 96 h	Lymphocytic vasculitis. CD4, CD8, HLA-DR, CD30-negative	Tolerating d4T, 3TC, efavirenz
3	50/M	Fever, nausea, diarrhea, myalgias 5 days after starting abacavir. Day 7 developed generalized rash, cervical adenopathy and hypotension during an observed dose	d4T, 3TC efavirenz	Lymphocytic vasculitis. CD4, CD8, HLA-DR, CD30-negative—	2 months after acute reaction. Intense blistering reaction worse at 10% localized to patch test at 48 and 96 h	Lymphocytic vasculitis. CD4, CD8, HLA-DR+, CD30-negative	Tolerating d4T, 3TC, efavirenz, lopinavir/ritonavir
4	43/M	Fever, rash, anorexia and malaise 2.5 weeks after starting abacavir	ddl, nevirapine, amprenavir, lopinavir/ritonavir	N/A	2 months after acute reaction. Negative patch test at 1 h. Positive patch test at 24, 48 and 96 h (all concentrations)	Lymphocytic vasculitis. CD4, CD8, HLA-DR+, CD30-negative, CD23-positive	Tolerating amprenavir lopinavir/ritonavir, efavirenz, d4T, 3TC
5	47/M	Fever, nausea, skin rash 6 days after starting abacavir	ddl, amprenavir, delavirdine, combivir	N/A	2 months after acute reaction. Negative patch test at 1 h. Positive patch test at 24, 48 and 96 h (all concentrations)	Lymphocytic vasculitis. CD4, CD8, HLA-DR, CD30-negative	Tolerated rechallenge with tenofovir, ddl, amprenavir, delavirdine, Combivir (ZDV/3TC)
6	43/M	Fever, skin rash, myalgias 7 days after starting abacavir, which intensified	Abacavir, efavirenz, d4T, 3TC	N/A	33 months after acute reaction. Negative patch test at 1 h. Positive patch test at 24, 48 and 96 h (all concentrations)	Refused biopsy	On drug holiday
7	48/M	Fever, malaise, headache day 8, intensification and rash day 9,10	Abacavir, 3TC, efavirenz	Lymphocytic vasculitis, CD4, CD8, HLA-DR, CD30-negative	6 weeks after acute reaction. Negative patch test at 1 h. Positive patch test at 24, 48 and 96 h (all concentrations)	Lymphocytic vasculitis. CD4, CD8, HLA-DR, CD30-negative	Tolerating Combivir (ZDV/3TC), efavirenz

ddl, Didanosine; d4T, stavudine; 3TC, lamivudine; ZDV, zidovudine.



**Fig. 1. Patch testing at 24 h illustrating dose reponse (case 5).**

concordance between the two biopsies and patch testing further strengthens this, and sheds light on the pathophysiology of the acute skin reaction and positive patch tests. The immunohistochemistry on the acute skin rash biopsies and patch biopsies are in fact identical to previously presented data on skin biopsies from patients with acute abacavir hypersensitivity syndrome [4]. The absence of B cell markers and the presence of HLA-DR in all of the biopsies suggests a primarily cell-mediated, T helper cell type 1 response.

These preliminary results suggest that an inexpensive and safe procedure such as patch testing may be a useful adjunct to the clinical diagnosis of abacavir hypersensitivity syndrome. Cases 4 to 7 illustrates that patch testing can become positive within 24 h of applying the patch. It should be emphasized that this test is currently a research tool, and a negative patch test at this time cannot be interpreted as grounds for full-dose unsupervised rechallenge with abacavir. Case 6 illustrates that patch tests can be positive remote from the initial exposure. However, the exact time course of when the test becomes positive in relation to the hypersensitivity syndrome and the expected duration of positivity in these patients is currently unknown and is the subject of further investigation.

## Acknowledgements

The authors would like to acknowledge GlaxoSmith Kline US, Research Triangle, NC, USA, and the Canadian Infectious Disease Society for their support of this study; Dr Rodney Miller, ProPath Laboratories, Dallas TX, USA, who processed the skin biopsies; and Drs A. Rachlis, S. Walmsley and C. Kovacs for their contribution of patients.

Divisions of <sup>a</sup>Clinical Pharmacology, <sup>b</sup>Infectious Diseases and <sup>c</sup>Drug Safety Clinic, Sunnybrook and Women's Health Sciences Centre, University of Toronto, Toronto, Ontario, Canada; and <sup>d</sup>Skin and Cancer Foundation of Australia, Westmead, NSW 2145, Australia.

Received: 8 October 2001; revised: 21 May 2002; accepted: 10 June 2002.

## References

1. Escaut L, Lioteier JY, Albengres E, Cheminot N, Vittecoq D. **Abacavir rechallenge has to be avoided in case of hypersensitivity reaction.** *AIDS* 1999, **30**:1419–1420.
2. Wolkenstein P, Chosidow O, Flechet ML, *et al.* **Patch testing in severe cutaneous adverse drug reactions, including Stevens–Johnson syndrome and toxic epidermal necrolysis.** *Contact Dermat* 1996, **35**:234–236.
3. Mizukawa Y, Shiohara T. **Effector-type CD8+ intraepidermal T cells provide a source of early IFN- $\gamma$  drug eruption lesions.** *Allergologie* 2001, **24**:222.
4. Thurmond LM, Thorborn D, Ravitch J, *et al.* **Immunohistological characterization of skin rash observed in patients on abacavir who experience a hypersensitivity reaction.** *Antiretrovir Ther* 2000, **5** (Suppl. 5):53.

## Bilateral carotid stenosis in a young female HIV patient treated with highly active antiretroviral therapy

Simona Landonio<sup>a</sup>, Tiziana Quirino<sup>a</sup>, Angelo Pelucchi<sup>b</sup>, Carlo Magni<sup>a</sup>, Massimo Coen<sup>a</sup>, Tiziano Porretta<sup>b</sup>, Ivano Faggion<sup>a</sup>, Paolo Bonfanti<sup>a</sup> and Gian Marco Vigevani<sup>a</sup>

**In the past few years, some cases of vascular pathology in HIV-positive patients treated with highly active antiretroviral therapy (HAART) have been reported. We describe a case of severe and premature vascular disease, occurring in a young female patient, multiexperienced for HAART, who is part of a cohort of patients followed for drug-induced toxicity. After 6 years of treatment she suffered a bilateral carotid stenosis; the only risk factors were cigarette smoking and hypercholesterolemia.**

Among the long-term toxicity effects of antiretroviral therapy, lipid metabolism disorders and an increased risk of atherosclerosis constitute a problem of great interest [1,2]. Cases of premature vascular pathology in patients treated with highly active antiretroviral therapy (HAART) are reported with increasing frequency in the literature, even though the actual incidence of this phenomenon is still under study [3,4]. We describe a case of bilateral carotid stenosis in a young female patient. She is part of a cohort of 1480 patients treated with HAART, under observation since 1997 to assess the incidence of adverse reactions [5].

## Clinical case

An HIV-positive 37-year-old woman, known for heterosexual risk since 1987, was started on antiretroviral therapy with nucleoside reverse transcriptase inhibitors in 1993. Since 1998 the therapy was enhanced first with non-nucleoside reverse transcriptase inhibitors and then with protease inhibitors. In June 1999, as a result of unsatisfactory immunovirological control, a mega-HAART regimen with stavudine, abacavir, lamivudine, zidovudine and didanosine was introduced.

In July of the same year, the patient suffered occasional paresthesia in her fingers, each episode lasting only a few minutes. The symptoms got increasingly worse up to November 1999, when she showed weakness and reduced sensitivity in her left arm. The patient was hospitalized and a nuclear magnetic resonance imaging showed signal alteration in the right occipito-parietal region, which was not modified after contrast injection and was compatible with an ischaemic stroke. Tests for thrombophilic conditions: prothrombin time, platelet count, lupus anticoagulant, silica clotting time, factor pathway inhibitors to coagulation (C and S proteins) and antinuclear antibodies were negative. Doppler sonography showed soft plaque with less than 20% stenosis at the origin of the right internal carotid artery. The patient was introduced to antiplatelet therapy, resulting in a gradual remission of her neurological symptoms.

In June 2000, the patient suffered new episodes of paresthesia of the left hand as well as amaurosis fugax in the left eye. A brain computed tomography scan showed an ischaemic lesion in the right occipito-parietal region. The Doppler sonography led us to suspect severe stenosis in the right common carotid artery. A computed tomography angiography con-

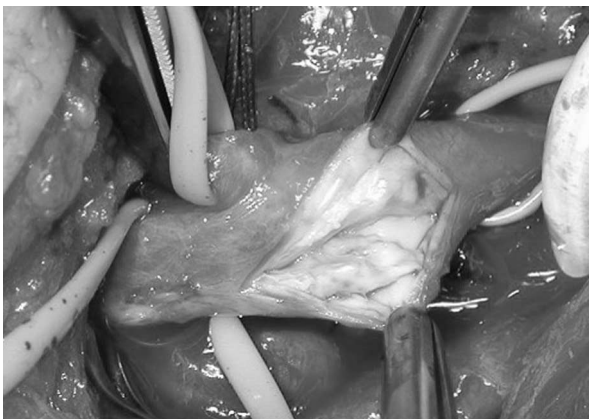

Fig. 1. Fibrous-calcific atheromatous plaque during endarterectomy.

firmed a total obstruction of the right carotid artery, as well as the presence of soft lipidic plaque causing stenosis of the left carotid bifurcation. The patient first underwent endarterectomy of the left carotid bifurcation (Fig. 1), later followed by a right subclavian-carotid by-pass. The patient currently remains symptom-free; she is proceeding with antiretroviral and antiplatelet therapy. The Doppler sonography shows normal blood flow in the carotid territory, bilaterally.

An analysis of cardiovascular risk factors showed that, from the early neurological symptoms, the patient's cholesterol levels were slightly high (maximum count: 275 mg/dl); her triglyceride levels were always normal. She never showed any hypertension and she has never taken oral contraceptives. She smokes approximately 20 cigarettes per day. There is no history of cardiovascular disease in her family.

## Conclusion

Bilateral carotid vascular disease in young women is a decidedly rare event in the general population. Such an event is generally correlated to major concomitant risk factors [6,7]. In this case, the only risk factors linked to cardiovascular disease are that the patient smokes and that her cholesterol was slightly too high. We must therefore consider the possibility that antiretroviral treatment may have contributed to the occurrence of vascular pathology.

Should such clinical data be further confirmed, periodical adverse event monitoring schemes for HIV-positive patients undergoing HAART therapy will probably need to be reassessed.

<sup>a</sup>Department of Infectious Diseases, and <sup>b</sup>Vascular Surgery Unit, Luigi Sacco Hospital, Milan, Italy.

Received: 2 May 2002; accepted: 19 June 2002.

## References

1. Carr A, Samaras K, Burton S, Law M, Freund J, Chisholm DJ, Cooper DA. A syndrome of peripheral lipodystrophy, hyperlipidaemia, and insulin resistance in patients receiving HIV protease inhibitors. *AIDS* 1998, **12**:F51-F58.
2. Jutte A, Schwenk A, Franzen C, Romer K, Diet F, Diehl V, et al. Increasing morbidity from myocardial infarction during HIV protease inhibitor treatment. *AIDS* 1999, **13**:1796-1797.
3. David MH, Hornung R, Fichtenbaum CJ. Ischemic cardiovascular disease in persons with human immunodeficiency virus infection. *Clin Infect Dis* 2002, **34**:98-102.
4. Depairon M, Chessex S, Sudre P, Rodondi N, Droser N, Chave JP, et al. Premature atherosclerosis in HIV-infected individuals - focus on protease-inhibitor therapy. *AIDS* 2001, **15**:329-334.



5. Bonfanti P, Valsecchi L, Parazzini F, Carradori S, Pusterla L, Fortuna P, *et al.* **Incidence of adverse reactions in HIV patients treated with protease inhibitors: a cohort study.** *J Acquir Immune Defic Syndr* 2000, **23**:236–245.
6. Stokes JL, Kannel WB, Wolf PA, D'Agostino RB, Cupples LA. **Blood pressure as a risk factor for cardiovascular disease: the Framingham Study: 30 years of follow up.** *Hypertension* 1989, **13**:113–118.
7. Joakimsen O, Bonna KH, Stensland-Bugge E, Jacobsen BK. **Age and sex differences in the distribution and ultrasound morphology of carotid atherosclerosis. The Tromso study.** *Arterioscler Thromb Vasc Biol* 1999, **19**:3007–3012.