



Divergence between CBCT and Optical Scans for Soft Tissue Analysis and Cephalometry in Facial Imaging: A cross-sectional study on healthy adults

Marco Farronato¹, Niccolò Cenzato¹, Roberta Crispino¹, Francesco Carlo Tartaglia², Roberto Biagi^{1,3}, Benedetta Baldini⁴, Cinzia Maspero^{1,3}

Available online:

1. Department of Biomedical, Surgical and Dental Sciences, School of Dentistry, University of Milan, 20100 Milan, Italy
2. Department of Biomedical Sciences, Humanitas University, Via Rita Levi Montalcini 4, 20072 Pieve Emanuele, Italy
3. UOC Maxillo-Facial Surgery and Dentistry, Fondazione IRCCS Cà Granda, Ospedale Maggiore Policlinico, 20100 Milan, Italy
4. Department of Electronics, Information and Bioengineering, Politecnico Di Milano, Via Ponzio 34/5, 20133 Milan, Italy

Correspondence:

Marco Farronato, Department of Biomedical, Surgical and Dental Sciences, School of Dentistry, University of Milan, 20100 Milan, Italy.
marcofarronato@msn.com

Keywords

Cephalometry
Facial imaging
Facial scan
Soft tissues analysis
3D imaging

Summary

Background > Facial soft tissue analysis is becoming increasingly emphasized in orthodontic diagnosis and treatment planning. While traditional cephalometry primarily focuses on hard tissues, recent non-invasive imaging techniques offer the potential to comprehensively evaluate three-dimensional (3D) facial soft tissues. The aim of the study was to establish the geometrical 3D and cephalometric divergence between Cone Beam Computed Tomography (CBCT) derived images and scanned soft tissues. Crucial for enhancing orthodontic diagnosis, minimizing patient exposure to ionizing radiation and providing facial cephalometric parameters.

Material and methods > A cross-sectional study was conducted from January 2020 to May 2023. CBCT and 3D facial scans were obtained simultaneously using a specialized imaging system. Reproducible landmark points were selected for both cephalometric and soft tissue analysis. Angular and linear measurements were recorded, and correlations between CT and facial scans were statistically assessed.

Results > Comparisons between 10 CBCT-derived and 10 facial scan-based soft tissue representations resulted into 1.8 mm mean root median square (RMS). Angular measurements, such as ANB, right gonial angle, and left gonial angle, exhibited a 0.9° of difference with their respective soft tissue variables. In contrast, linear measurements of total anterior facial height showed a lower correlation coefficient, equal to 0.51. The correlation between soft tissues and underlying hard tissues was more pronounced for gonial angles.

Conclusion > Facial soft tissue analysis using either 3D facial scans or CBCT-derived offers similar results for orthodontic diagnosis and treatment planning. These findings support the use of non-invasive diagnostic tools in orthodontics, although further investigations are needed to comprehensively understand the complexity of hard and soft tissue relationships.

Abbreviations

CBCT cone beam computed tomography
FOV Field of view
RMS root mean square

Introduction

The analysis of facial tissues plays an increasingly significant role in orthodontic diagnosis and treatment planning [1,2]. To evaluate the effects of dental and skeletal changes on the soft tissue profile during orthodontic treatment management in order to estimate facial changes digital three-dimensional data of the soft tissues have to be acquired [3–6]. However, the historical tradition of using two-dimensional cephalometric analysis is likely responsible for the secondary role of soft tissue analysis as a diagnostic tool compared to skeletal analysis. Even though non-invasive imaging techniques allow for accurate three-dimensional (3D) acquisition of facial soft tissues, and new standard values have been set [7,8]. The soft tissue profile reflects the underlying skeletal structures and its associated hard tissues, making it possible to estimate skeletal configuration through the study of the soft tissue profile alone [8,9]. However, to date, there is a lack of reference data reporting average values for 3D measurements of facial soft tissues compared to their correlation with "conventional" cephalometric parameters for hard tissue analysis, especially when in presence of fully 3D data [10–12]. Previous studies described the matching process between the CT and facial scans obtained by various facial scanners such as 3D Neo; Morpheus, Gyounggi, Korea assessing a surface discrepancy of 0.60 mm SD, 0.12 mm [13]. Further studies on the relationships between facial soft tissues and underlying hard tissues should be considered and studied further in order to improve non-invasiveness in orthodontic diagnosis and reduce patient exposure to ionizing radiation. Furthermore, establishing reliable correlations between facial soft tissues and cephalometric measurements is crucial for advancing orthodontic diagnosis and treatment planning [9].

Such correlations would provide valuable insights into the relationship between skeletal structures and their soft tissue manifestations, enabling clinicians to predict and evaluate the aesthetic outcomes of orthodontic interventions more accurately. Previous studies have emphasized the importance of soft tissue analysis in orthodontics [12–15], illustrating how asymmetry can be examined and evaluating the precision of optical

devices [7,8]. However, even though CT derived soft tissues demonstrated good reliability even in angular landmarks [16], the lack of standardized association between the CT-derived and optical scans still remains an area to be investigated.

The objectives of this study were to evaluate the differences between the two types of facial scans (CBCT-derived and facial scanner) by geometric computed analysis, and to ascertain the correspondence between hard and soft tissues cephalometric measurements.

Material and methods

A cross-sectional study was carried out in the orthodontic department of the Ospedale Maggiore Policlinico in Milan (Fondazione IRCCS Cà Granda and Università La Statale). The study was designed in accordance with the Helsinki Declaration, the study protocol was approved by the Ethical Committee of Fondazione IRCCS Cà Granda, Ospedale Maggiore Policlinico, Milan, Italy (protocol 573/15) and the methods and results are presented following the STROBE guidelines.

The sample size was calculated according to previous studies [17]. To detect a difference of 0.1 mm RMS with a standard deviation of 0.1 mm between the two meshes, a minimum of 19 samples is required to obtain a power of 0.80 and a significance level α of 0.05. The study sample consisted of a total of 20 facial and CBCT scans of 10 adult subjects (mean age 35.97 years).

All patients meeting the eligibility criteria were included from January 2020 to May 2023 according to the following inclusion criteria:

- caucasian ethnicity;
- age between 30 and 40 years;
- normal body mass index (BMI between 18.5 to 24.9 according to NIH);
- facial CBCT performed for orthodontic treatment evaluation;
- skeletal class I.

The following exclusion criteria were also applied:

- history of facial trauma;
- previous maxillofacial surgery interventions;
- craniofacial syndromes or anomalies;
- noticeable facial asymmetries;
- previous or ongoing orthodontic treatment.

Each participant in the study underwent the following diagnostic examinations for reasons unrelated to this study (orthodontic evaluation and treatment planning):

- cone beam computed tomography (CBCT) of the skull;
- 3D facial scanning of soft tissues.

Image acquisition methods

Both the CBCT and facial scans were obtained for all subjects using the Planmeca ProMax 3D ProFace (Planmeca®). This 3D imaging device, based on Cone Beam Volumetric Tomography (CBVT) and featuring an integrated 3D facial scanning system, enabled the simultaneous acquisition of CBCT images of the head and facial scans of the soft tissues. CBCT images were acquired using the following scanning protocol: 170 × 230 mm field of view (FOV), 4 mm slice thickness, 0.49 × 0.49 × 0.5 mm voxel size, 30-second scan time, 120 kVp, 3-8 mA. The distance between the subject and the scanner was set at 80 cm. Patients were placed in a seated position with their heads parallel to the floor, maintaining a natural head position facilitated by the use of

a mirror, as described by Ferrario et al. [18]. Furthermore, they were instructed to keep their mouths closed with relaxed lips and teeth in a neutral occlusion throughout the scanning process. CBCT images featuring major artifacts were discarded and excluded from the analysis. Moreover, any potential artifacts (known as scattering) in the CBCT images, which were not visibly noticeable, were corrected using the Planmeca CALM algorithm (Romexis® 6.4, Planck, Helsinki, Finland). The CBCT data obtained were saved in Digital Imaging and Communications in Medicine (DICOM) standard format. The soft tissue data were processed using Romexis software.

Image processing

The facial scan models and DICOM files obtained from CBCT were processed using Mimics Innovation Suite 19 (Materialise Interactive Medical Image Control System), a software for

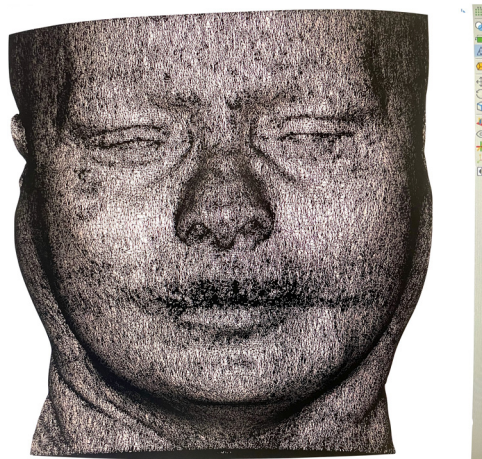

FIGURE 1
Facial reconstruction, Mimics Software®




FIGURE 2
Superimposition of CBCT and facial scan on Vam®

segmentation and three-dimensional reconstruction of clinical bioimages (figure 1). Using Mimics, 3D models were generated for both the facial scans and the reconstructions of facial soft tissues derived from CBCT data. These 3D models were further processed using VAM® software (Vectra Analysis Module, Canfield Scientific, Inc., Fairfield, NJ, USA) which allowed for the selection of corresponding facial areas of interest [19,20] on both types of 3D models for each patient. Ultimately, the respective areas of interest from the facial scans and the reconstructions of soft tissues from CBCT for each patient were overlapped (figure 2), and the root mean square (RMS) value (minimum average) of point-to-point distances between the entire 3D surfaces was calculated. This procedure was automatically performed by the VAM® software through iterative closest point (ICP) algorithm.

Measurements

The 3D landmarks described previously [21-23] were selected for hard tissue cephalometric analysis from these soft tissue landmarks (table I). One operator (N.C.) placed the landmarks

on the 3D images; to assess reproducibility, the placement of the landmarks was repeated in a different session on 2 randomly selected CBCT images and facial scans until consistency was achieved (SD < 0.1 mm).

After accurately locating the reference points (figure 3), linear and angular measurements were obtained for each scan (table II) automatically by the use of the Mimics software as previously described [21-23]. The operators did not know the origin of each facial scan, which was blind analysed.

A total of 6 angular measurements were recorded from CBCT and 5 from facial scans, while 5 linear measurements were taken from the CBCT tracings and 3 from the facial scans (table II). Subsequently, each skeletal measurement was paired with one soft tissue measurement to conduct a correlation analysis. The correspondence between soft tissue representations obtained from the facial scans and those obtained from CBCT was assessed by calculating the mean, standard deviation, and root mean square of point-to-point distances between the entire surfaces. These measurements were performed using VAM®.

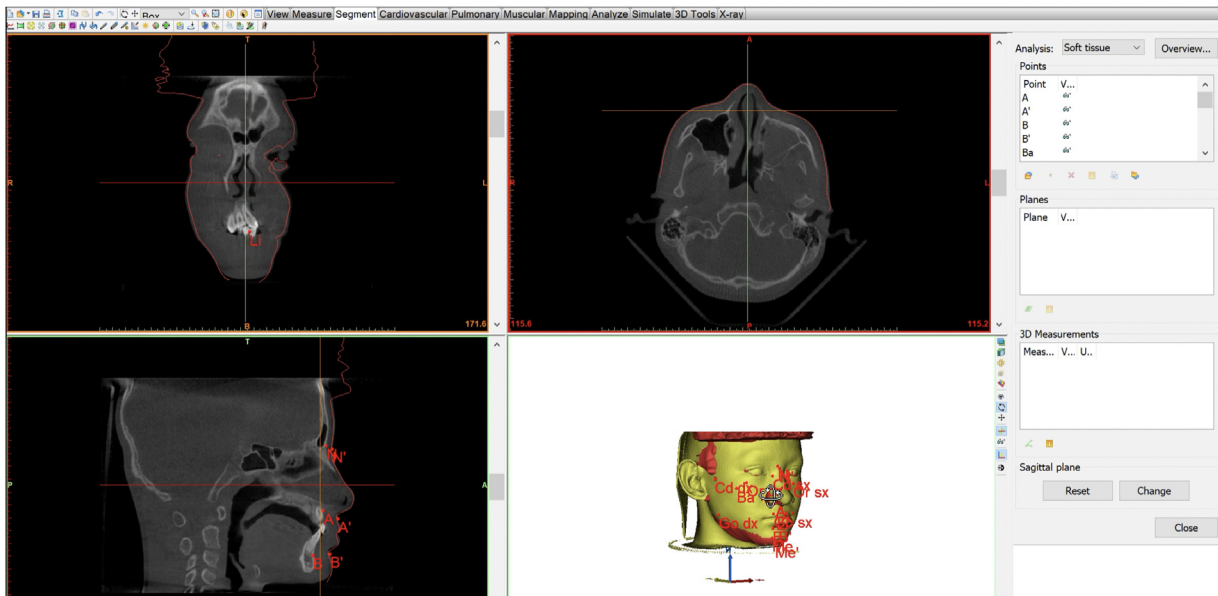


FIGURE 3
 Cutaneous and skeletal landmarks. Reference system: Midsagittal plane: a plane passing through Nasion (N), Sella (S), Basion (Ba). Points A, A', B, B', N' were traced on midsagittal plane

TABLE I
Landmarks

Hard tissue landmarks	Soft tissue landmarks
A	A'
B	B'
N	N'
Go(R)	Go'(R)
Go(L)	Go'(L)
Cd(R)	Tr'(R)
Cd(L)	Tr'(L)
Me	Me'
LI	Pg'
UI	LS
PNS	LI
ANS	G
Or(R)	-
Or(L)	-
Mx(R)	-
Mx(L)	-
Po(R)	-
Po(L)	-
Ba	-

Hard tissues: A: point A; B: point B; N: Nasion; Go: Gonion - L/R; Cd: condylyon - L/R; Me: Menton; LI: lower incisor; UI: upper incisor; PNS: posterior nasal spine; ANS: anterior nasal spine; Or: orbital - L/R; Mx: maxillar - L/R; Po: Porion - L/R; Ba: Basion. Soft tissues: A' (Point A), B' (Point B), N' (Nasion), Go' (Gonion - L/R), Tr' (Tragus - L/R), Me' (Menton), Pg' (Pogonion), LS (upper labial foremost point), LI (inferior labial foremost point), G (Glabella).

TABLE II
Hard and soft tissue measurements

	Hard tissue measurements	Soft tissue measurements
Angular measurements	ANB	A'N'B'
	Gonial angle (R)	Cutaneous gonial angle (R)
	Gonial angle (L)	Cutaneous gonial angle (L)
	Facial divergence (R)	-
	Facial divergence (L)	-
Linear measurements	Cd(R)-Go(R)	Tr'(R)-Go'(R)
	Cd(L)-Go(L)	Tr'(L)-Go'(L)
	Anterior facial height	Cutaneous anterior facial height
	Go(R)-Me	Go'(R)-Me'
	Go(L)-Me	Go'(L)-Me'
	Posterior facial height	-

Statistical analysis

IBM SPSS and Microsoft Excel were used for the statistical analysis of cephalometric data. The correlation between cephalometric measurements of hard and soft tissues was investigated for each measurement pair using Pearson correlation coefficient (Pearson's *r*). The significance level was set at $P < 0.05$.

Additionally, to provide a comprehensive evaluation of the cephalometric concordance the regression model between right gonial angle, left gonial angle, ANB and total anterior facial height was computed according to the following metrics:

- mean/median; standard deviation; range (subtraction between the maximum predicted value indicating the upper limit of the model's estimates and the minimum predicted value, to assess the spread of predictions);
- coefficient of determination (R^2 – R-squared) calculated as the proportion of the variance in the dependent variable (0–1). R^2 is computed by dividing the variance by the total variance. This metric serves as a measure of the goodness of fit of the regression model.

Results

In a total of 20 scans of 10 adult subjects, the overlap of the surfaces obtained by CBCT and those obtained by Planmeca ProFace 3D using VAM® showed no significant differences, considering the mean and standard deviation of the variable. The mean distance of the surfaces ranged from a minimum of –0.2 mm to a maximum of 5.4 mm. The mean R-squared was 1.8 and the min more than 0.6 is a very good value for showing the accuracy (*table III*).

The angular measurements ANB, right gonial angle, and left gonial angle were the variables which demonstrated high correlation coefficients with their respective soft tissue variables. On the other hand, the linear measurements of total anterior facial height exhibited the lowest correlation coefficients (defined as = 1 perfect correlation, between 0.7 and 0.9 strong between 0.4 and 0.7 moderate and weak below 0.4). All the correlation statistical results were resumed in *table IV*. Single values were visually represented in *figure 4*.

TABLE III
Difference between CBCT and facial scan soft tissue representation in mm

Stats	Min	Max	RMS	Mean	SD
Min	–9.7	4.0	0.6	–0.2	0.6
p50	–3.9	5.1	1.4	0.1	1.3
Mean	–5.1	7.0	1.8	1.2	1.9
Max	–2.2	6.7	6.3	5.4	5.7
SD	3.0	3.4	1.7	2.1	1.7

TABLE IV
Correlation between ANB right gonial angle, left gonial angle and total anterior facial height performed on CBCT and on facial scan

	ANB	RGA	LGA	TAFH
95% CI	0.777–1.022	0.118–0.659	0.124–0.687	–0.011–0.202
<i>P</i>	0.000*	0.005*	0.005*	0.080
SD	0.977	1.035	4.520	6.411
Pearson's <i>r</i>	0.923	0.902	0.890	0.510

* $P < 0.05$; Unit: mm.

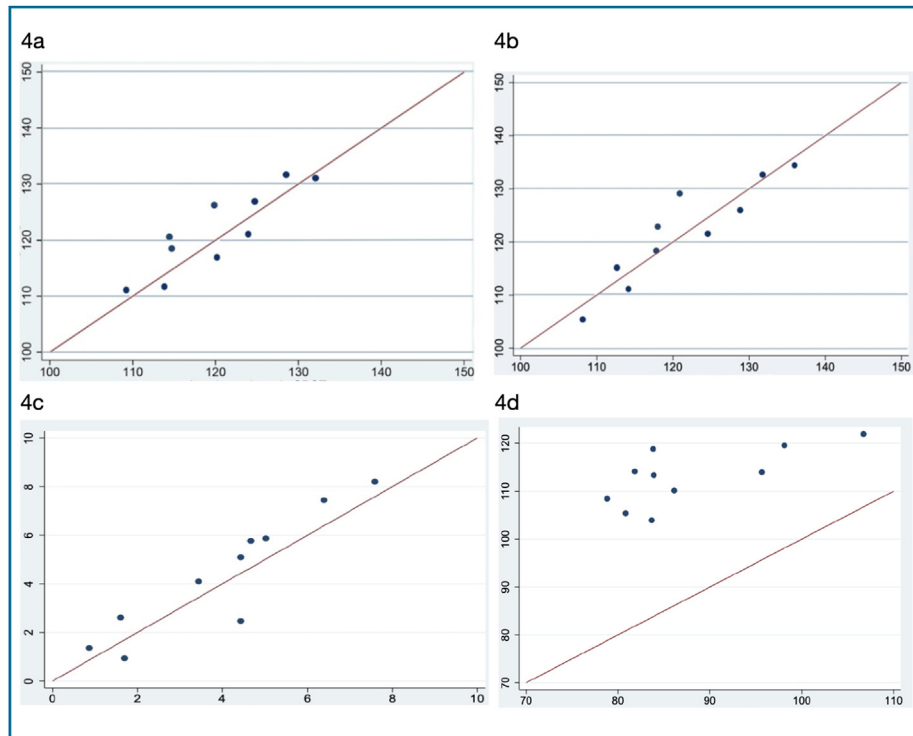


FIGURE 4

Correlation between right gonial angle (4a) left gonial angle (4b) ANB (4c) and total anterior facial height (4d)

Discussion

The goals of this study were to measure the difference between the facial surface reconstructions obtained from CBCT and the facial scans, and to compare the facial soft tissue analysis obtained from the facial scans with that gathered from the 3D cephalometric tracings from the CBCT acquisitions. The aim of this comparison was to highlight possible correspondences between hard and soft tissue diagnoses. The increasing role of non-invasive imaging tools could be of great help and importance in orthodontic diagnosis, as 3D facial soft tissues could be used as a first screening examination to guide clinicians through the diagnosis, reserving further skeletal investigations with radiographic examinations only when necessary. This approach is in line with the work of Plooj et al. who investigated the use of 49 soft tissue landmarks [24]. Previous research has also demonstrated the feasibility of integrating digital cast models into facial scanners [25]. The Planmeca ProFace 3D scanner showed good reliability and reproducibility in acquiring facial morphology. Furthermore, facial scans proved to be appropriate for the reference position.

The present results were organized in sagittal and vertical measurements. The sagittal parameters that showed strong correlation with their respective soft tissue variables were: ANB, right gonial angle, and left gonial angle (table IV). These

angles, fundamental in evaluating sagittal relationships between the maxilla and the mandible, are therefore of great importance for the diagnosis of skeletal malocclusion. The age range of 30 to 40 years was selected to exclude errors arising from increased soft tissue laxity associated with aging. Younger subjects were excluded to account for the potential of residual growth. Similarly, only subjects with a normal BMI (ranging between 18.5 to 24.9 according to N.I.H) were included in the study to prevent the inclusion of soft tissue alterations related to overweight. According to the current results, the diagnosis performed on soft tissues appeared to be reliable and consistent with the skeletal cephalometric outcomes, as the coefficients showed high values and attained statistical significance in most of the cephalometric parameters analysed [26].

The correlation between soft tissues and underlying hard tissues was observed to be high especially for cephalometric parameters investigating the lower third of the face; in fact, left and right gonial angle measurements performed on soft tissues proved to be highly consistent with those performed on skeletal structures (LGA: $r = 0.89$; RGA: $r = 0.902$). Total anterior facial height demonstrated a low correlation with the respective soft tissue variables ($r = 0.5$). This can potentially be attributed to the difficulty in locating corresponding landmark points on soft

tissues and to the different thicknesses of facial tissues which are dependent on age and gender [27,28].

In the present study, all facial scans were performed with relaxed lips. This position was considered accurate in terms of diagnosis and treatment planning, allowing for comparison with routinely performed CBCT cephalometric analyses with relaxed lips.

The proposed analysis of soft tissues based on 3D facial scans demonstrated good reliability and reproducibility. Further studies are needed to confirm the research findings.

A limitation of this study could be that the data analysis was performed by a single operator. In addition, the inclusion of only Caucasian patients could be considered a limitation of this study, since ethnic differences in facial soft tissue profile have been observed in previous research [29–31]. Although the results obtained in the present study are encouraging, they remain limited to our sample. In addition, the sample had a normal BMI, which can be considered the ideal condition for the present research. Indeed, it has been studied that, excessive BMI has significant effects on the relationship between the underlying skeleton and soft tissue [22,23]. Therefore, the results should not be extrapolated to conditions with altered BMI, where the correspondences between hard and soft tissues may be less accurate.

Further studies are needed to clarify the complex relationships between hard and soft tissues and assist clinicians and researchers in diagnosis and treatment planning using non-invasive tools.

Conclusions

From the results of this study, the following findings can be stated:

- facial soft tissue images recorded by the facial scanner are consistent with those reconstructed through CBCT, in terms of root mean square of difference between surfaces;
- angular measurements performed on facial scans show high concordance with those performed on CBCT images;
- vertical measurements of soft tissues showed a weaker correlation with the corresponding cephalometric tracing performed on CBCT;
- soft and hard tissues measurements' correlation is higher for gonial angle measurements.

Availability of data and material: The datasets used and/or analysed during the current study are available from the corresponding author on reasonable request.

Funding: The authors received no financial support for the research, authorship and publication of this article.

Authors' contributions: C.M. outlined the study design and supervised the research. N.C. and R.C. performed the measurements. B.B. performed the statistical analysis of the data. M.F. and F.C.T. contributed in writing the manuscript. R.B. and C.M. reviewed the manuscript. All authors read and approved the final version of the manuscript.

Disclosure of interest: The authors declare that they have no competing interest.

Declarations: Ethics approval and consent to participate: the protocol of the study was approved by the Ethical Committee of Fondazione IRCCS Ca' Granda, Ospedale Maggiore Policlinico, Milan, Italy (protocol 573/15).

References

- [1] Luyten J, Vierendeel M, De Roo NMC, Temmerman L, De Pauw GAM. A non-cephalometric three-dimensional appraisal of soft tissue changes by functional appliances in orthodontics: a systematic review and meta-analysis. *Eur J Orthod* 2022;44(4):458–67.
- [2] D'Ettorre G, Farronato M, Candida E, Quinzi V, Grippaudo C. A comparison between stereophotogrammetry and smartphone structured light technology for three-dimensional face scanning. *Angle Orthod* 2022;92(3):358–63.
- [3] Cevidanes LHS, Styner MA, Proffit WR. Image analysis and superimposition of 3-dimensional cone-beam computed tomography models. *Am J Orthod Dentofacial Orthop* 2006;129(5):611–8.
- [4] Lee C, Gu J, Millett D. Three-dimensional assessment of facial soft tissue changes after orthognathic surgery: cone beam computed tomography vs. stereophotogrammetry. *J Craniofac Surg* 2020;48(5):494–500.
- [5] Nervina J. Cone beam computed tomography use in orthodontics. *Aust Dent J* 2012;57(5):95–102.
- [6] Farronato G, Garagiola U, Dominici A, Periti G, de Nardi S, Carletti V, et al. "Ten-point" 3D cephalometric analysis using low-dosage cone beam computed tomography. *Prog Orthod* 2010;11(1):2–12.
- [7] Cappella A, Solazzo R, Yang J, Tartaglia G, Sforza C. Facial asymmetry of Italian children: a cross-sectional analysis of three-dimensional stereophotogrammetric reference values. *Symmetry* 2023;15(4):792.
- [8] Gibelli D, Dolci C, Cappella A, Sforza C. Reliability of optical devices for three-dimensional facial anatomy description: a systematic review and meta-analysis. *Int J Oral Maxillofac Surg* 2020;49(8):1092–106. doi: [10.1016/j.ijom.2019.10.019](https://doi.org/10.1016/j.ijom.2019.10.019) [Epub 2019 November 28. PMID: 31786104].
- [9] Maspero C, Cenzato N, Inchingolo F, Cagetti MG, Isola G, Sozzi D, et al. The maxilla-mandibular discrepancies through soft-tissue references: reliability and validation of the anteroposterior measurement. *Children* 2023;10(3):459.
- [10] Stratemann SA, Huang JC, Maki K, Miller AJ, Hatcher DC. Comparison of cone beam computed tomography imaging with physical measures. *Dentomaxillofac Radiol* 2008;37(2):80–93. doi: [10.1259/dmfr/31349994](https://doi.org/10.1259/dmfr/31349994) [PMID: 18239035].
- [11] Farronato G, Giannini L, Galbiati G, Morbellaro C, Maspero C. Presurgical virtual three-dimensional treatment planning. *J Craniofac Surg* 2015;26(3):820–3. doi: [10.1097/SCS.0000000000001510](https://doi.org/10.1097/SCS.0000000000001510) [PMID: 25901669].
- [12] Swennen GR, Pottel L, Haers PE. Custom-made three-dimensional-printed surgical guide for orthognathic surgery: design and validation. *J Oral Maxillofac Surg* 2016;74(4):849–55.
- [13] Nahm KY, Kim Y, Choi YS, Lee J, Kim SH, Nelson G. Accurate registration of cone-beam computed tomography scans to 3-dimensional facial photographs. *Am J Orthod Dentofacial Orthop* 2014;145(2):256–64. doi: [10.1016/j.ajodo.2013.10.018](https://doi.org/10.1016/j.ajodo.2013.10.018) [PMID: 24485741].
- [14] Choi JH, Kim YI, Lee KJ. Accuracy of soft tissue prediction for skeletal class III surgery. *J Craniofac Surg* 2019;47(2):334–40.

- [15] Kau CH, Cronin AJ, Lima KJ. The use of three-dimensional surface acquisitions in facial plastic surgery: an update. *Facial Plast Surg Clin North Am* 2017;25(3):403–15.
- [16] Xu W, Lu R, Hu Y, Cao L, Wang T, Tan H, et al. Reliability of cone beam CT for morphometry of nasolabial soft tissue in patients with skeletal class III malocclusion: a qualitative and quantitative analysis. *J Xray Sci Technol* 2022;30(1):195–206. doi: [10.3233/XST-211018](https://doi.org/10.3233/XST-211018) [PMID: 34719475].
- [17] Rudy HL, Wake N, Yee J, Garfein ES, Tepper OM. Three-dimensional facial scanning at the fingertips of patients and surgeons: accuracy and precision testing of iPhone X three-dimensional scanner. *Plast Reconstr Surg* 2020;146(6):1407–17.
- [18] Ferrario VF, Sforza C, Tartaglia G, Barbini E, Michielon G. New television technique for natural head and body posture analysis. *Cranio* 1995;13(4):247–55. doi: [10.1080/08869634.1995.11678076](https://doi.org/10.1080/08869634.1995.11678076).
- [19] Gibelli D, De Angelis D, Poppa P, Sforza C, Cattaneo C. A view to the future: a novel approach for 3D-3D superimposition and quantification of differences for identification from next-generation video surveillance systems. *J Forensic Sci* 2017;62(2):457–61.
- [20] Maggiordomo A, Farronato M, Tartaglia G, Tarini M. A method based on 3D affine alignment for the quantification of palatal expansion. *PLoS One* 2022;17(12):e0278301. doi: [10.1371/journal.pone.0278301](https://doi.org/10.1371/journal.pone.0278301).
- [21] Farronato G, Farronato D, Toma L, Bellincioni F. A synthetic three-dimensional craniofacial analysis. *J Clin Orthod* 2010;44(11):673–8 [quiz 688].
- [22] Farronato M, Maspero C, Abate A, Grippaudo C, Connelly ST, Tartaglia GM. 3D cephalometry on reduced FOV CBCT: skeletal class assessment through AF-BF on Frankfurt plane-validity and reliability through comparison with 2D measurements. *Eur Radiol* 2020;30(11):6295–302. doi: [10.1007/s00330-020-06905-7](https://doi.org/10.1007/s00330-020-06905-7) [Epub 2020 May 7. PMID: 32382843].
- [23] Farronato M, Baselli G, Baldini B, Favia G, Tartaglia GM. 3D cephalometric normality range: auto contractive maps (ACM) analysis in selected Caucasian skeletal class I age groups. *Bioengineering (Basel)* 2022;9(5):216. doi: [10.3390/bioengineering9050216](https://doi.org/10.3390/bioengineering9050216).
- [24] Plooij JM, Swennen GR, Rangel FA, Maal TJ, Schutyser FA, Bronkhorst EM, et al. Evaluation of reproducibility and reliability of 3D soft tissue analysis using 3D stereophotogrammetry. *Int J Oral Maxillofac Surg* 2009;38(3):267–73. doi: [10.1016/j.ijom.2008.12.009](https://doi.org/10.1016/j.ijom.2008.12.009) [Epub 2009 January 22. PMID: 19167191].
- [25] Galantucci LM, Percoco G, Lavecchia F, Di Gioia E. Noninvasive computerized scanning method for the correlation between the facial soft and hard tissues for an integrated three-dimensional anthropometry and cephalometry. *J Craniofac Surg* 2013;24(3):797–804. doi: [10.1097/SCS.0b013e3cc8123714883](https://doi.org/10.1097/SCS.0b013e3cc8123714883). [PMID: 23714883].
- [26] Fink M, Medelnic J, Strobel K, Hirschfelder U, Hofmann E. Metric precision via soft-tissue landmarks in three-dimensional structured-light scans of human faces. *J Orofac Orthop* 2014;75(2):133–43. doi: [10.1007/s00056-013-0201-9](https://doi.org/10.1007/s00056-013-0201-9) [Epub 2014 March 2. PMID: 24577017].
- [27] Chaimongkhon T, Mahakkanukrauh P. The facial soft tissue thickness related facial reconstruction by ultrasonographic imaging: a review. *Forensic Sci Int* 2022;337:111365.
- [28] Piombino P, Esposito E, Committeri U, Barone S, Arena A, Cataldo R, et al. Facial soft tissue thickness measurement method and relationship with BMI, age and sex. *J Stomatol Oral Maxillofac Surg* 2023;124(4):101420.
- [29] Hamdan AM. Soft tissue morphology of Jordanian adolescents. *Angle Orthod* 2010;80(1):80–5.
- [30] Hwang HS, Kim WS, McNamara Jr JA. Ethnic differences in the soft tissue profile of Korean and European-American adults with normal occlusions and well-balanced faces. *Angle Orthod* 2002;72(1):72–80.
- [31] Uysal T, Baysal A, Yagci A, Sigler LM, McNamara Jr JA. Ethnic differences in the soft tissue profiles of Turkish and European-American young adults with normal occlusions and well-balanced faces. *Eur J Orthod* 2012;34(3):296–301. doi: [10.1093/ejo/cjq165](https://doi.org/10.1093/ejo/cjq165) [Epub 2011 January 27. PMID: 21273287].