

# The Ocular Surface in Medically Controlled Glaucoma: An In Vivo Confocal Study

Edoardo Villani,<sup>1,2</sup> Matteo Sacchi,<sup>1,2</sup> Fabrizio Magnani,<sup>1,3</sup> Angelo Nicodemo,<sup>1,3</sup>  
Susan E. I. Williams,<sup>4</sup> Alessandro Rossi,<sup>1,3</sup> Roberto Ratiglia,<sup>1,3</sup> Stefano De Cillà,<sup>5,6</sup>  
and Paolo Nucci<sup>1,2</sup>

<sup>1</sup>Department of Clinical Sciences and Community Health, University of Milan, Milan, Italy

<sup>2</sup>Eye Clinic San Giuseppe Hospital, Milan, Italy

<sup>3</sup>Fondazione IRCCS Ca' Granda Policlinico, Milan, Italy

<sup>4</sup>Division of Ophthalmology, Department of Neurosciences, University of the Witwatersrand, Johannesburg, South Africa

<sup>5</sup>Eye Clinic Azienda Ospedaliero-Universitaria Maggiore della Carità, Novara, Italy

<sup>6</sup>Eye Clinic San Paolo Hospital, Milan, Italy

Correspondence: Edoardo Villani, Department of Clinical Sciences and Community Health, University of Milan, Eye Clinic San Giuseppe Hospital, via San Vittore 12, 20123 Milan, Italy; edoardo.villani@unimi.it.

Submitted: June 10, 2015

Accepted: February 2, 2016

Citation: Villani E, Sacchi M, Magnani F et al. The ocular surface in medically controlled glaucoma: an in vivo confocal study. *Invest Ophthalmol Vis Sci.* 2016;57:1003-1010. DOI:10.1167/iops.15-17455

**PURPOSE.** To study clinical and in vivo laser scanning confocal microscopy (LSCM) ocular surface findings in stable, medically controlled primary open-angle glaucoma (MCPOAG) patients.

**METHODS.** We recruited 100 consecutive patients with MCPOAG and 50 healthy controls. Patients had to have been treated with the same medical regimen without variation for the 18 months before enrollment and were excluded if there was a history of dry eye prior to glaucoma diagnosis. Each participant underwent ocular surface clinical and LSCM examination.

**RESULTS.** In MCPOAG patients, subbasal nerve length and tortuosity and dendritic cell density were increased compared to controls ( $P < 0.01$ ), but there were no clinical abnormalities. Patients treated with preserved drugs ( $n = 80$ ) had reduced tear film breakup time ( $P < 0.05$ , ANOVA), and those preserved with benzalkonium chloride ( $n = 72$ ) had reduced Schirmer test values ( $P < 0.001$ ). Patients ( $n = 50$ ) treated with two or more drugs had increased lissamine green conjunctival staining ( $P < 0.001$ , LSD post hoc test). Patients ( $n = 29$ ) treated with three or more eye drops daily had decreased Schirmer test values. Laser scanning confocal microscopy showed subbasal changes related to preservatives, type and number of drugs, and number of eye drops.

**CONCLUSIONS.** In stable MCPOAG patients without dry eye history, the ocular surface changes due to antiglaucoma medications are mostly subclinical. Active ingredients, preservatives, number of concomitant drugs, and number of eye drops instilled per day are all elements that can induce ocular surface changes. The clinical relevance of these changes remains to be determined.

**Keywords:** confocal microscopy, ocular surface, glaucoma medications, corneal epithelium, inflammation

Primary open-angle glaucoma is a progressive optic neuropathy that is often associated with an increased intraocular pressure (IOP) and that may cause progressive visual field loss leading to blindness.<sup>1</sup> A series of large, multicenter, randomized controlled studies demonstrated that IOP-lowering therapy can prevent glaucoma onset from ocular hypertension and prevent further progression in patients with confirmed diagnosis of glaucoma.<sup>1-3</sup> According to the European Glaucoma Society Guidelines,<sup>4</sup> the first-line approach to control IOP is with medical treatment. Because of the progressive nature of the disease, chronic treatment is required, with many patients needing to use more than one drug to achieve a target IOP.

A frequently reported side effect of long-term antiglaucoma topical treatment, occurring in up to 59% of patients,<sup>5-8</sup> is ocular surface disease. This is a symptomatic condition in which the homeostasis between the tear film and the components of the ocular surface morphofunctional unit is

disturbed.<sup>9</sup> The main symptoms are dryness, foreign body sensation, tearing, burning, and redness. The main signs are reduced tear stability and secretion, corneal and conjunctival staining, and meibomian gland dysfunction.<sup>5-8</sup> This condition may affect the patient's quality of life<sup>10,11</sup> and might influence compliance to therapy.<sup>12,13</sup>

Ocular surface disease related to antiglaucoma drugs may result from either an allergic or a toxic mechanism.<sup>14,15</sup> Allergic responses are relatively rare and more often evident in the early phase of therapy.<sup>15,16</sup> Thus toxicity is likely to be the prevalent cause of chronic ocular surface disease under these circumstances.<sup>14,15</sup> This response might be attributed to preservatives in topical medicines as well as to the active compounds, but the relative role of these components is still being debated.<sup>15,17</sup> Benzalkonium chloride (BAK) is the most commonly used preservative in topical drugs, and a large body of recent literature highlights its toxic effects on ocular tissues.<sup>14,18-22</sup>



Moreover, an increase in the ocular surface symptoms and signs is associated with the number of concomitant drugs and the number of eye drops instilled per day,<sup>12,23</sup> leading to the hypothesis that the simpler the regimen, the more likely the patient will tolerate and adhere to the therapeutic protocol.<sup>13</sup>

Drug-related ocular surface abnormalities may be identified, even in asymptomatic patients, by an abnormal expression of interleukins and inflammatory markers<sup>24-26</sup> and by advanced imaging techniques. In vivo laser scanning confocal microscopy (LSCM) is a technology that allows the study of living ocular surface structures at a microstructural level in a quick and nearly noninvasive way with a resolution comparable to that of histologic methods.<sup>27</sup> This technology showed promising results in discerning different pathogenic processes in several components of the ocular surface,<sup>27-32</sup> in studying subclinical changes,<sup>27,33</sup> and in monitoring ocular surface changes and responses to treatment.<sup>34-37</sup>

Current literature confocal data on glaucomatous patients<sup>38</sup> are heterogeneous; they have been obtained in different settings, sometimes retrospectively, and often provided by studies with a very specific a priori hypothesis, as well as important selection or confounding biases. Presumed anti-glaucoma medication-related confocal findings include conjunctival squamous metaplasia,<sup>39</sup> desquamation, keratinization,<sup>38,40</sup> dendritic cell activation,<sup>40</sup> inflammation,<sup>15</sup> goblet cell loss,<sup>15,41</sup> increase of corneal dendritic cells and activated keratocytes,<sup>38,42</sup> decrease of corneal superficial epithelial cell density,<sup>42</sup> subbasal nerve decreased density and increased tortuosity,<sup>42,43</sup> reduced Meibomian gland glandular density and area, increased reflectivity of the acinar secretion, ductal orifice dilation, and signs of inflammation of the glandular wall and interstice.<sup>44</sup>

We hypothesized that medically treated glaucoma patients, compared to healthy subjects, have a subclinical neuro-inflammatory process characterized by corneal nerve changes and increased number of dendritic cells.

We designed the present prospective, explorative, comprehensive research to identify and characterize clinical and confocal ocular surface changes in medically controlled patients with primary open-angle glaucoma (MCPOAG) compared to untreated, healthy control subjects and to investigate abnormalities determined by the characteristics of the therapeutic regimen.

## METHODS

We consecutively recruited a convenience sample of 100 Caucasian patients with MCPOAG and 50 untreated healthy controls who were referred to our Glaucoma Service as glaucoma suspects with family histories of glaucoma or optic disc cupping. To be included in the study, the MCPOAG patients had to have been treated with the same medical regimen without variation for the 18 months before enrollment. Participants were excluded from the study if they had a history of ocular or systemic diseases or treatments (except antiglaucoma medications for MCPOAG patients) within the last 12 months with known effects on the ocular surface. Other exclusion criteria were previous ocular surgery or trauma, end-stage glaucoma, pregnancy, contact lens wear, and a history of dry eye prior to glaucoma diagnosis.

Each participant completed an Ocular Surface Disease Index (OSDI) questionnaire.<sup>45</sup> The compliance of MCPOAG patients to therapy was assessed by the Morisky-Green medication adherence questionnaire, a validated self-reported instrument with four questions.<sup>46</sup> Each participant underwent a comprehensive eye examination including an assessment of the best corrected visual acuity, biomicroscopic examination of

the ocular surface, measurement of the tear film breakup time (BUT), corneal fluorescein and conjunctival lissamine green staining (Collaborative Longitudinal Evaluation of Keratoconus [CLEK] scheme),<sup>47</sup> Schirmer test without topical anesthesia, corneal apex sensitivity assessment (Cochet-Bonnet esthesiometer with nylon thread diameter of 0.08 mm; Luneau, Paris, France), Schirmer test with anesthesia, IOP measurement (Goldmann applanation tonometer), and meibomian gland dropout (meiboscopy) and expressivity grading. Meiboscopy of the lower eyelid was scored as follows: grade 0, no gland dropout; grade 1, gland dropout in less than one-third of the inferior tarsus; grade 2, gland dropout between one-third and two-thirds; and grade 3, dropout in more than two-thirds of the inferior tarsus.<sup>33,48</sup> Assessment of obstruction in the meibomian gland orifices was conducted by applying digital pressure on the lower eyelid margin. The degree of ease in expressing the meibum was evaluated semiquantitatively as follows: grade 0, clear meibum easily expressed; grade 1, cloudy meibum expressed with mild pressure; grade 2, cloudy meibum expressed with more than moderate pressure; grade 3, meibum not be expressed even with hard pressure.<sup>33,48</sup> All of the procedures were performed in the order suggested by the International Dry Eye WorkShop 2007 (DEWS).<sup>49</sup>

Following a previously published procedure, we also performed in vivo LSCM examination of several ocular surface components,<sup>32</sup> including cornea, temporal bulbar conjunctiva, inferior tarsal conjunctiva, meibomian glands, and eyelid margin. We used the HRT II with Corneal Rostock Module (Heidelberg Engineering, Dossenheim, Germany) with a scanning wavelength of 670 nm. Before each examination, a drop of oxybuprocaine chlorohydrate 0.4% and a drop of ophthalmic gel (polyacrylic gel 0.2%) were separately instilled in the lower conjunctival fornix of the patient. The objective lens ( $\times 63$  immersion; Zeiss, Oberkochen, Germany) was covered by a polymethacrylate sterile cap (Tomo-Cap; Heidelberg Engineering) and had a working distance of 0.0 to 2.0 mm. The examination area was  $400 \times 400 \mu\text{m}$ .

## Image Analysis

Confocal image analysis was performed, in a masked manner, as previously described.<sup>32</sup> For the cornea, we quantified superficial and basal epithelial cell density; anterior, posterior, and hyperreflective keratocyte density; subbasal dendritic cell density; subbasal nerve length per frame<sup>50</sup> and tortuosity<sup>51</sup>; density of beading formations; and endothelial cell density. For the bulbar and tarsal conjunctivas, we evaluated epithelial and immune cell density.<sup>52-54</sup> For the lower eyelid margin and meibomian glands, we quantified the following variables: epithelial cell density, meibomian gland density, acinar unit diameter, acinar unit area, meibum reflectivity, and inhomogeneous appearance of the interstices and walls of the acinar units.

Cell density was determined through the manual cell counting procedure present in the software, taking into consideration the whole area marked as available for the count. Cells partially contained in the area were counted only along the right and lower margins of the selected field. Results are expressed in cells per square millimeter. The same procedure was performed for acinar density. ImageJ software (available in the public domain at <http://imagej.nih.gov/ij/>) was used to manually calculate the length of nerves per frame, diameters of the acinar units (along the longest axis), and unit areas (automatically calculated after manual demarcation of the boundary).

Finally, using a comparison with previously published reference images, we evaluated nerve tortuosity,<sup>51</sup> meibum

**TABLE 1.** Subjects Included in the Study and Criteria Used for Group Analyses

	Number of Subjects	Criteria for Group Identification
MCPOAG	100	Treated/untreated
Untreated controls	50	
BAK-preserved drugs	72	Type of preservative
Polyquad-preserved drugs	8	
Preservative-free drugs	20	
Beta-blocker drops	36	Type of active ingredient
Prostaglandin analogue drops	14	
Combination drops	50	
1 drug	50	Number of drugs
2 drugs	36	
3 drugs	14	
1 drop	27	Number of daily instilled drops
2 drops	44	
3 or more drops	29	

secretion reflectivity, and inhomogeneous appearance of interstices and walls of acinar units.<sup>33</sup>

Informed consent was obtained from all patients, and the study was performed in accordance with the tenets of the declaration of Helsinki.

### Statistical Analysis

Data derived from the worse eye (defined as the eye with the higher fluorescein staining score or the higher lissamine green score, or the lower BUT, in that order) were used for statistical analysis. All data are expressed as means  $\pm$  standard deviations (SD).

We compared MCPOAG patients to controls using independent samples *t*-test for parametric variables and Mann-Whitney *U* test for nonparametric variables. For each parametric variable in which we found no significant difference between MCPOAG and controls, we calculated the minimum detectable difference (MDD;  $\alpha = 0.05$ ,  $\beta = 0.80$ ) for that variable.

Subsequently, we divided MCPOAG patients into subgroups based on the preservatives, active ingredients, number of antiglaucoma medications, and number of eye drops instilled per day. We compared clinical and confocal data among subgroups by analysis of variance (ANOVA) and by least significant difference (LSD) post hoc tests for parametric variables and by Kruskal-Wallis tests for nonparametric variables. Statistical significance was set at  $P < 0.05$ . Statistical analysis was performed with commercial software (SPSS for Windows v.19.0; SPSS Sciences, Chicago, IL, USA).

## RESULTS

There were no significant differences in the age and sex distributions between the MCPOAG patients (72 women and 28 men; average age  $57.3 \pm 7.5$  years, range, 44–77 years) and the control group (31 women and 19 men; average age  $54.6 \pm 6.2$  years, range, 41–75 years). All of the patients reported good compliance to treatment with a Morisky-Green medication adherence questionnaire score  $\geq 16$ ,<sup>46</sup> and demonstrated awareness of their therapeutic regimen. The treatment regimens of the patients included different preservatives, active ingredients, number of drugs, and number of instilled drops per day (Table 1).

There were no significant clinical differences between MCPOAG patients and control subjects (Table 2). Confocal

examination showed increased nerve length, nerve tortuosity, and dendritic cell density at the corneal subbasal level in MCPOAG patients (Fig. 1; Table 2).

The preservative-based subgroup analysis of MCPOAG patients identified three groups: patients treated with BAK-preserved drugs ( $n = 72$ ), patients treated with Polyquad-preserved drugs ( $n = 8$ ), and patients treated with unpreserved drugs ( $n = 20$ ). For eyes treated with BAK- and Polyquad-preserved drugs, the BUT was significantly lower than for eyes treated with preservative-free drugs (Fig. 2A). Further, the Schirmer test times for eyes treated with BAK-preserved drugs was lower than for eyes treated with Polyquad-preserved and preservative-free drugs (Fig. 2B). Confocal data revealed increased subbasal nerve tortuosity in both preserved groups compared to the unpreserved group (Fig. 2C).

The subgroup analysis of MCPOAG patients based on active ingredients identified three groups: patients treated with beta-blockers ( $n = 36$ ), patients treated with prostaglandin analogues ( $n = 14$ ), and patients treated with combination drops of beta-blockers and prostaglandin analogues ( $n = 50$ ). Lissamine green conjunctival staining was increased in the combination group compared to both of the other groups and was the only clinical parameter showing a significant difference among these groups (Fig. 3A). Laser scanning confocal microscopy examination found significant differences among the groups only at subbasal level of the corneal epithelium. The total length/frame and tortuosity of nerves was lowest in the beta-blocker group. This reached statistical significance for total length/frame when compared with the combination group (Fig. 3B) and for tortuosity when compared with both of the other groups (Fig. 3C). Moreover, patients treated with beta-blockers had lower dendritic cell density compared to both the prostaglandin analogue and combination groups (Fig. 3D). No significant differences were found among the different types of combinations.

The subgroup analysis based on the number of different types of drugs taken by each MCPOAG patient identified three groups: patients taking one drug ( $n = 50$ ), patients taking two drugs ( $n = 32$ ), and patients taking three or more drugs ( $n = 18$ ). Again, lissamine green conjunctival staining was the only clinical parameter that was significantly lower among the groups. It was lower in patients treated with one drug compared to either of the other groups (Fig. 4A). Confocal data at the subbasal level showed significantly lower total length/frame and tortuosity of nerves (Fig. 4B, 4C) and lower dendritic cell density (Fig. 4D) in patients treated with one drug compared to either of the other groups.

The subgroup analysis of MCPOAG patients based on the number of drops taken per day identified three groups: patients treated with one drop/day ( $n = 27$ ), patients treated with two drops/day ( $n = 44$ ), and patients treated with three or more drops/day (range, 3–5,  $n = 29$ ). The Schirmer test was decreased in the group treated with the higher number of daily drops (Fig. 5A), and the subbasal nerve tortuosity was lower in the group treated with two drops/day (Fig. 5B). No other variables showed significant differences in this subanalysis.

## DISCUSSION

Antiglaucoma medical treatment is a chronic therapy and exposes the ocular surface to the simultaneous actions of different potential triggers such as active compounds, preservatives, and repeated instillations. Despite a large body of literature on the topic, the clinical relevance and the specific ocular surface changes related to these triggers are not fully understood. The present study, performed in a clinical setting, excluded patients with a history of dry eye prior to glaucoma



TABLE 2. MCPOAG Patients Versus Controls: Ocular Surface Clinical and Confocal Data

	MCPOAG Patients	Control Subjects	P	MDD
OSDI	11.91 ± 12.72	12.76 ± 15.26	n.s.*	6.92
BUT, s	6.02 ± 2.80	6.56 ± 3.46	n.s.*	1.39
Corneal fluorescein staining, CLEK	0.56 ± 0.82	0.49 ± 0.73	n.s.†	n.d.
Conjunctival lissamine green staining, CLEK	0.24 ± 0.44	0.30 ± 0.47	n.s.†	n.d.
Schirmer test without topical anesthesia, mm/5 min	10.77 ± 3.64	12.08 ± 4.21	n.s.*	1.94
Corneal apex sensitivity, cm	5.45 ± 0.93	5.74 ± 0.72	n.s.*	0.42
Schirmer test with anesthesia, mm/5 min	9.94 ± 3.39	10.80 ± 3.25	n.s.*	1.57
Meibomian gland dropout, grade 0-3	0.89 ± 0.58	0.88 ± 0.67	n.s.†	n.d.
Meibomian gland expressibility, grade 0-3	1.27 ± 0.89	1.56 ± 0.92	n.s.†	n.d.
Corneal superficial epithelial cell density, cells/mm <sup>2</sup>	1747.23 ± 352.10	1694.88 ± 303.25	n.s.*	161.6
Corneal basal epithelial cell density, cells/mm <sup>2</sup>	5040.86 ± 422.28	5159.74 ± 290.81	n.s.*	194.84
Corneal anterior keratocyte density, cells/mm <sup>2</sup>	797.81 ± 102.43	824.30 ± 95.39	n.s.*	47.09
Corneal posterior keratocyte density, cells/mm <sup>2</sup>	537.63 ± 61.04	514.85 ± 51.81	n.s.*	28.16
Corneal hyperreflective keratocyte density, cells/mm <sup>2</sup>	47.45 ± 35.74	54.32 ± 52.37	n.s.*	20.31
Corneal subbasal dendritic cell density, cells/mm <sup>2</sup>	86.84 ± 44.60	41.01 ± 38.46	<0.01*	n.d.
Corneal subbasal nerve length, μm/frame	2814.74 ± 929.59	2077.68 ± 575.91	<0.01*	n.d.
Corneal subbasal nerve tortuosity, 0-4	2.00 ± 0.78	1.20 ± 0.40	<0.01†	n.d.
Corneal subbasal nerve beading, n/mm	167.59 ± 39.69	158.54 ± 42.25	n.s.*	19.39
Corneal endothelial cell density, cells/mm <sup>2</sup>	2675.50 ± 409.60	2788.56 ± 330.25	n.s.*	188.83
Bulbar conjunctival epithelial cell density, cells/mm <sup>2</sup>	1538.92 ± 301.26	1651.42 ± 265.48	n.s.*	143.13
Bulbar conjunctival immune cell density, cells/mm <sup>2</sup>	31.84 ± 27.73	28.37 ± 22.49	n.s.*	12.47
Tarsal conjunctival epithelial cell density, cells/mm <sup>2</sup>	2747.15 ± 543.97	2899.17 ± 364.25	n.s.*	251.16
Tarsal conjunctival immune cell density, cells/mm <sup>2</sup>	152.23 ± 112.78	187.58 ± 104.52	n.s.*	52.17
Eyelid margin epithelial cell density, cells/mm <sup>2</sup>	1924.54 ± 476.74	1910.64 ± 463.23	n.s.*	219.77
MG acinar density, n/mm <sup>2</sup>	103.64 ± 84.11	106.47 ± 61.33	n.s.*	38.78
MG acinar diameter, μm	77.36 ± 21.30	74.48 ± 19.91	n.s.*	9.70
MG acinar area, μm <sup>2</sup>	3126.56 ± 1314.18	3225.52 ± 1375.82	n.s.*	634.83
MG secretion reflectivity, grade 1-4	1.93 ± 0.92	2.12 ± 0.97	n.s.†	n.d.
Inhomogeneous appearance of MG walls, grade 1-4	2.02 ± 0.80	1.96 ± 0.84	n.s.†	n.d.
Inhomogeneous appearance of MG interstices, grade 1-4	1.62 ± 0.63	1.56 ± 0.58	n.s.†	n.d.

MG, meibomian glands; n.s., not significant; n.d., not determined.

\* Independent samples *t*-test.

† Mann-Whitney *U* test.

diagnosis and those with recent treatment changes. The consecutive enrollment allowed analysis of a relatively large sample of patients very similar to most of those seen in daily clinical practice. To limit selection biases, we consecutively recruited from the same clinical setting a control group of 50 untreated healthy subjects who were referred for family history of glaucoma or optic disc cupping. To limit confounding factors, due to the lack of a control group of untreated glaucomatous subjects, we limited our confocal study to parameters notoriously related to antiglaucoma medications and did not consider conjunctival microcysts and other features previously described in treated and also in untreated glaucoma patients.<sup>55,56</sup>

Moreover, we included only previously validated confocal parameters, and we adopted an approach, recently described

and applied to dry eye patients,<sup>32</sup> that obtained simultaneous optical samples of several components of the ocular surface morphofunctional unit. This kind of comprehensive confocal analysis is very complex and time-consuming, and therefore it is not suitable for daily clinical use. Nevertheless, it can provide important information to identify the type of ocular surface changes related to different conditions.

In this exploratory research to screen subtle abnormalities related to MCPOAG and to different treatment features, we adopted an approach highlighting the differences between groups, that is, selecting the worse eye per subject and using the least significant difference as the ANOVA post hoc test. Further, to reduce concerns regarding the power of the analysis, the MMD was calculated for each *t*-test that was statistically insignificant.

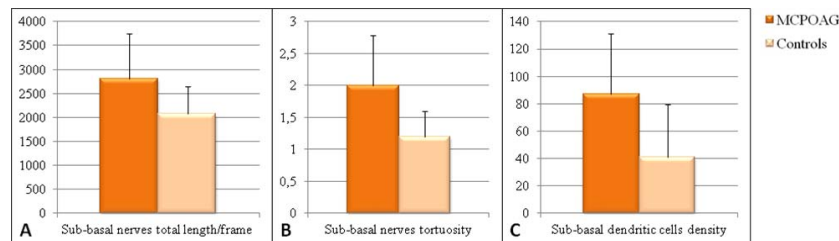
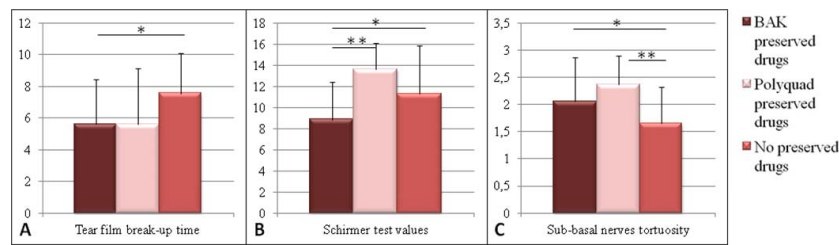


FIGURE 1. LSCM significant differences: MCPOAG patients versus control group. Data presented as mean ± standard deviation. (A) Subbasal nerve total length/frame (μm): MCPOAG: 2814.74 ± 929.59; control group: 2077.68 ± 575.91;  $P < 0.01$  from *t*-test. (B) Subbasal nerve tortuosity (grading 1-4): MCPOAG: 2.0 ± 0.8; control group: 1.2 ± 0.4;  $P < 0.01$  from Mann-Whitney *U* test. (C) Subbasal dendritic cell density (cell/mm<sup>2</sup>): MCPOAG: 86.84 ± 44.60; control group 41.01 ± 38.46;  $P < 0.01$  from *t*-test.



**FIGURE 2.** MCPOAG patients treated with BAK-preserved drugs, Polyquad-preserved drugs, and preservative-free drugs: clinical and confocal significant differences. (A) Tear film breakup time (seconds): BAK-preserved drugs:  $5.62 \pm 2.79$ ; Polyquad-preserved drugs:  $5.62 \pm 3.50$ ; preservative-free drugs:  $7.55 \pm 2.54$ ;  $P < 0.05$  from ANOVA; \*BAK-preserved drugs versus preservative-free drugs  $P < 0.001$ , LSD post hoc test. (B) Schirmer test without topical anesthesia (mm/5 min): BAK-preserved drugs:  $8.85 \pm 3.54$ ; Polyquad-preserved drugs:  $13.62 \pm 2.50$ ; preservative-free drugs:  $11.30 \pm 4.52$ ;  $P < 0.001$  from ANOVA; \*BAK-preserved drugs versus preservative-free drugs  $P < 0.001$ , LSD post hoc test; \*\*BAK-preserved drugs versus Polyquad-preserved drugs  $P < 0.05$ , LSD post hoc test. (C) Subbasal nerve tortuosity (grading 1–4): BAK-preserved drugs:  $2.06 \pm 0.81$ ; Polyquad-preserved drugs:  $2.37 \pm 0.52$ ; preservative-free drugs:  $1.65 \pm 0.67$ ;  $P < 0.05$  from Kruskal-Wallis test; \*BAK-preserved drugs versus preservative-free drugs  $P < 0.05$ , Mann-Whitney *U* test; \*\*Polyquad-preserved drugs versus preservative-free drugs  $P < 0.05$ , Mann-Whitney *U* test.

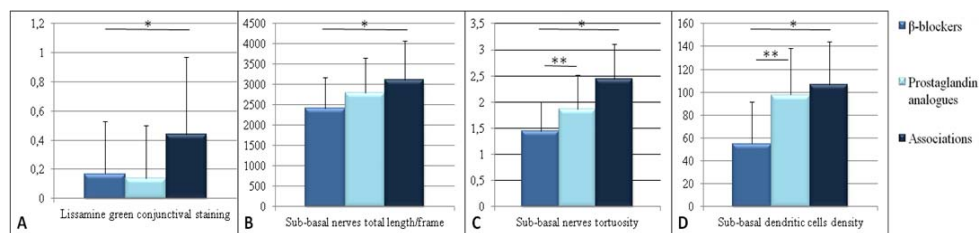
Initially, we compared MCPOAG patients to healthy controls and found significant results at the level of the corneal subbasal nerve plexus with increased total nerve length and tortuosity and with increased dendritic cell density. The increased length of nerves per frame is probably due to the increased tortuosity in absence of decreased nerve density. We decided to adopt this parameter to quantitatively assess the subbasal plexus because in previous research it showed the best interobserver and intervisit agreement compared to analysis of nerve and branch density.<sup>57</sup> Comparison of these results with the literature is not easily done because of the heterogeneity of methodologies adopted in previously published research. However, microscopic changes in the subbasal nerve plexus in glaucoma patients due to medical treatment have been described.<sup>38,42,58</sup> The coexistence of increased subbasal nerve tortuosity and increased dendritic cell density suggests the presence of neuroinflammatory processes in which the early changes in fiber morphology can occur even without evident nerve loss or clinically appreciable decrease of sensitivity. This kind of inflammatory neuropathy, never clearly described in glaucoma patients, has been recently reported, or at least hypothesized based on imaging, in dry eye, diabetes, and small-fiber neuropathies.<sup>32,59,60</sup>

We investigated the differences among the antiglaucoma treatment regimens in a posteriori subgroup analyses.

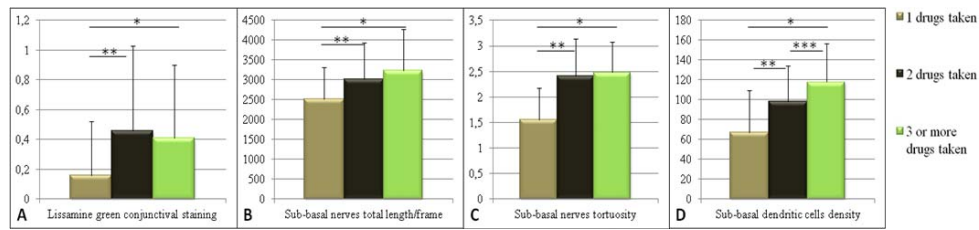
We compared MCPOAG patients treated with BAK-preserved, Polyquad-preserved, and unpreserved drugs. Concerns regarding toxic effects of preservatives, supported by a rapidly growing body of literature, appear to have persuaded

companies to develop and intensively market unpreserved antiglaucoma medications. These unpreserved drops may avoid the adverse effects of preservatives on the ocular surface; but they are more expensive, and the single-dose vials may be more difficult for an older patient to use. In addition, data from clinical trials, as discussed by Baudouin,<sup>15</sup> provide reassurance that long-term use of preserved antiglaucoma treatments is well tolerated and not harmful. The role of BAK has been recently investigated by numerous studies designed to evaluate the toxic effect of the preservative on the ocular surface and the risk-benefit ratio in glaucoma therapy.<sup>14,15,18–26</sup> Many *in vitro* and *in vivo* studies have established that BAK causes damage, characterized by inflammation and apoptosis, to corneal and conjunctival cells.<sup>24–26</sup> However, the clinical relevance of these findings is controversial because the toxic dose used is often greater than that used in clinical practice. Berdy et al.<sup>23</sup> reported that there are no significant adverse effects associated with the use of eye drops containing BAK up to four to six times daily in patients with mild dry eye disease.

We found significant preservative-related decreases in BUT and the Schirmer test without topical anesthesia and higher subbasal nerve tortuosity. Specifically, we found that the Schirmer test values in BAK-containing drugs were significantly lower than those of both Polyquad-preserved and unpreserved drugs. Further, nerve tortuosity was higher in eyes treated with both BAK- and Polyquad-preserved drugs compared to the unpreserved drugs. This is in contrast to an *in vivo* confocal study by Martone and colleagues<sup>42</sup> that described no significant subbasal differences between BAK-preserved and BAK-



**FIGURE 3.** MCPOAG patients treated with beta-blockers, prostaglandin analogues, and combinations of the two: clinical and confocal significant differences. (A) Lissamine green conjunctival staining. Beta-blocker drugs:  $0.17 \pm 0.36$ ; prostaglandin analogue drugs:  $0.14 \pm 0.36$ ; combination of beta-blocker and prostaglandin analogue drugs:  $0.44 \pm 0.53$ ;  $P < 0.05$  from ANOVA; \*beta-blockers drugs versus combination of drugs  $P < 0.001$ , LSD post hoc test. (B) Subbasal nerve total length/frame ( $\mu\text{m}$ ). Beta-blocker drugs:  $2411.42 \pm 757.35$ ; prostaglandin analogue drugs:  $2793.43 \pm 867.13$ ; combination of drugs:  $3111.10 \pm 963.04$ ;  $P < 0.001$  from ANOVA; \*beta-blocker drugs versus combination of drugs  $P < 0.001$ , LSD post hoc test. (C) Subbasal nerve tortuosity (grading 1–4). Beta-blocker drugs:  $1.44 \pm 0.56$ ; prostaglandin analogue drugs:  $1.86 \pm 0.66$ ; combination of drugs:  $2.44 \pm 0.67$ ;  $P < 0.001$  from Kruskal-Wallis test; \*beta-blocker drugs versus combination of drugs  $P < 0.001$ , Mann-Whitney *U* test; \*\*beta-blocker drugs versus prostaglandin analogue drugs  $P < 0.001$ , Mann-Whitney *U* test. (D) Subbasal dendritic cell density (cell/mm<sup>2</sup>): beta-blocker drugs:  $55.05 \pm 36.73$ ; prostaglandin analogue drugs:  $97.79 \pm 40.80$ ; combinations:  $106.67 \pm 37.88$ ;  $P < 0.001$  from ANOVA; \*beta-blocker drugs versus combinations  $P < 0.001$ , LSD post hoc test; \*\*beta-blocker drugs versus prostaglandin analogue drugs  $P < 0.05$ , LSD post hoc test.



**FIGURE 4.** MCPOAG patients with one, two, or three or more drugs: clinical and confocal significant differences. (A) Lissamine green conjunctival staining: 1 drug:  $0.16 \pm 0.36$ ; 2 drugs:  $0.46 \pm 0.57$ ; 3 or more drugs:  $0.41 \pm 0.49$ ;  $P < 0.05$  from ANOVA; \*1 drug versus 3 or more drugs  $P < 0.05$ , LSD post hoc test; \*\*1 drug versus 2 drugs  $P < 0.001$ , LSD post hoc test. (B) Subbasal nerves total length/frame ( $\mu\text{m}$ ): 1 drug:  $2518.38 \pm 799.52$ ; 2 drugs:  $3019.97 \pm 911.93$ ; 3 or more drugs:  $3236.95 \pm 1038.91$ ;  $P < 0.001$  from ANOVA; \*1 drug versus 3 or more drugs  $P < 0.001$ , LSD post hoc test; \*\*1 drug versus 2 drugs  $P < 0.05$ , LSD post hoc test. (C) Subbasal nerves tortuosity (grading 1–4): 1 drug:  $1.56 \pm 0.61$ ; 2 drugs:  $2.41 \pm 0.73$ ; 3 or more drugs:  $2.48 \pm 0.60$ ;  $P < 0.001$  from Kruskal-Wallis test; \*1 drug versus 3 or more drugs  $P < 0.001$ , Mann-Whitney  $U$  test; \*\*1 drug versus 2 drugs  $P < 0.001$ , Mann-Whitney  $U$  test. (D) Subbasal dendritic cell density (cell/ $\text{mm}^2$ ): 1 drug:  $67.01 \pm 42.20$ ; 2 drugs:  $98.49 \pm 35.65$ ; 3 or more drugs:  $117.97 \pm 38.80$ ;  $P < 0.001$  from ANOVA; \*BAK-preserved drugs versus no preserved drugs  $P < 0.001$ , LSD post hoc test; \*\*1 drug versus 2 drugs  $P < 0.001$ , LSD post hoc test; \*\*\*2 drugs versus 3 or more drugs  $P < 0.05$ , LSD post hoc test.

free drugs. In addition, a recent study evaluated the effects of prostaglandin analogues and BAK in different concentrations of the active compound and demonstrated that the active compound has a greater effect on the tolerability of the antiglaucoma therapy than the preservative.<sup>61</sup> It is our opinion that, in addition to research designed to demonstrate the toxicity of preservatives, there is a need for further research designed to assess the clinical impact of preservatives on the ocular surface health in glaucoma patients with and without dry eye.

Previous studies have demonstrated the detrimental clinical and microscopic effects of multidrug therapy compared with a single drug. These include a higher mean OSDI score,<sup>62</sup> subconjunctival inflammatory reaction, ocular surface squamous metaplasia,<sup>63</sup> and meibomian gland confocal alterations.<sup>44</sup> We identified MCPOAG subgroups based on the type of antiglaucoma drug they were using, that is, beta-blockers, prostaglandin analogues, or a combination of the two, and according to the number of antiglaucoma medications they were taking, that is, one, two, or three or more drugs. Lissamine green staining of the conjunctiva was higher in patients treated with combinations and in patients taking two or more different drugs. Subbasal nerve length was lower in patients treated with beta-blocker drugs and in patients taking only one drug. Subbasal nerve tortuosity was lower in patients taking beta-blocker drugs and in patients taking only one drug.

Subbasal dendritic cell density was lower in patients taking beta-blocker drugs and in those taking only one drug. In general, the post hoc tests showed that the differences were greater when effects of a single drug were compared to the effects of two or more drugs.

The subgroup analysis based on the number of eye drops instilled per day showed a significant and interesting reduction of Schirmer test values in patients treated with three or more drops per day. Our data suggest that in addition to the ocular surface effects of the topical antiglaucoma medications themselves and the preservatives used, effects are also associated with the number of different types of drugs and even the number of drops instilled into the eyes.

Limitations of the present study include the lack of a group of untreated glaucomatous subjects, its exploratory design based on a rather general hypothesis, and the limited number of patients. Moreover, the study design and the sample size allowed us to perform interesting subgroup analyses but not to provide final information on the relative impact of each therapeutic regimen on the ocular surface.

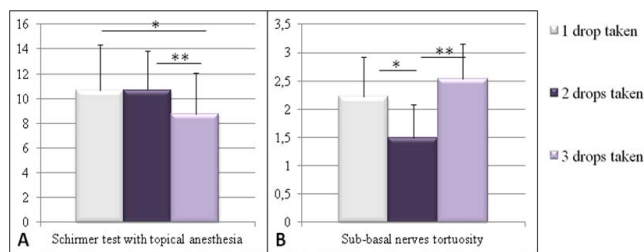
In conclusion, in stable, medically treated glaucoma patients with good compliance to therapy and no dry eye history, the ocular surface changes due to antiglaucoma medications are mostly subclinical. Active ingredients, preservatives, the number of concomitant drugs, and the number of eye drops instilled per day are all elements that are able to induce different ocular surface changes, potentially with synergistic effects. The clinical relevance of these changes is not clear, but the results of this study suggest that the ocular surface concerns regarding antiglaucoma medication may have been overestimated. Data provided by this explorative research may be important to planning future well-designed studies, based on specific hypotheses and confirmatory data analysis.

### Acknowledgments

Disclosure: E. Villani, Allergan (C); M. Sacchi, None; F. Magnani, None; A. Nicodemo, None; S.E.I. Williams, None; A. Rossi, None; R. Ratiglia, None; S. De Cillà, None; P. Nucci, None

### References

1. Tuulonen A, Airaksinen PJ, Erola E, et al. The Finnish evidence-based guideline for open-angle glaucoma. *Acta Ophthalmol Scand.* 2003;81:3–18.
2. Lindblom B, Nordmann JP, Sellem E, et al. A multicentre, retrospective study of resource utilization and costs associated



**FIGURE 5.** MCPOAG patients treated with 1, 2, or 3 or more drops per day: clinical and confocal significant differences. (A) Schirmer test with topical anesthesia (mm/5 min): 1 drop per day:  $10.67 \pm 3.68$ ; 2 drops per day:  $10.69 \pm 3.17$ ; 3 or more drops per day:  $8.77 \pm 3.29$ ;  $P < 0.05$  from ANOVA; \*1 drop per day versus 3 or more drops per day  $P < 0.05$ , LSD post hoc test; \*\*2 drops per day versus 3 or more drops per day  $P < 0.05$ , LSD post hoc test. (B) Subbasal nerve tortuosity (grading 1–4): 1 drop per day:  $2.22 \pm 0.70$ ; 2 drops per day:  $1.49 \pm 0.59$ ; 3 or more drops per day:  $2.53 \pm 0.63$ ;  $P < 0.001$  from Kruskal-Wallis test; \*1 drop per day versus 2 drops per day  $P < 0.001$ , Mann-Whitney  $U$  test; \*\*2 drops per day versus 3 or more drops per day  $P < 0.001$ , Mann-Whitney  $U$  test.



- with glaucoma management in France and Sweden. *Acta Ophthalmol Scand.* 2006;84:74-83.
3. Kass MA, Heuer DK, Higginbotham EJ, et al. The Ocular Hypertension Treatment Study: a randomized trial determines that topical ocular hypotensive medication delays or prevents the onset of primary open-angle glaucoma. *Arch Ophthalmol.* 2002;120:701-713.
  4. European Glaucoma Society Guidelines, 4th ed. European Glaucoma Society. Available at [http://www.eugs.org/eng/EGS\\_guidelines4.asp](http://www.eugs.org/eng/EGS_guidelines4.asp). Accessed June 1, 2015.
  5. Leung EW, Medeiros FA, Weinreb RN. Prevalence of ocular surface disease in glaucoma patients. *J Glaucoma.* 2008;17:350-355.
  6. Garcia-Feijoo J, Sampaolesi JR. A multicenter evaluation of ocular surface disease prevalence in patients with glaucoma. *Clin Ophthalmol.* 2012;6:441-446.
  7. Ghosh S, O'Hare F, Lamoureux E, et al. Prevalence of signs and symptoms of ocular surface disease in individuals treated and not treated with glaucoma medication. *Clin Experiment Ophthalmol.* 2012;40:675-681.
  8. Pisella PJ, Pouliquen P, Baudouin C. Prevalence of ocular symptoms and signs with preserved and preservative free glaucoma medication. *Br J Ophthalmol.* 2002;86:418-423.
  9. The definition and classification of dry eye disease: report of the Definition and Classification Subcommittee of the International Dry Eye WorkShop (2007). *Ocul Surf.* 2007;5:75-92.
  10. Skalicky SE, Goldberg I, McCluskey P. Ocular surface disease and quality of life in patients with glaucoma. *Am J Ophthalmol.* 2012;153:1-9.
  11. Rossi GC, Tinelli C, Pasinetti GM, et al. Dry eye syndrome-related quality of life in glaucoma patients. *Eur J Ophthalmol.* 2009;19:572-579.
  12. Fechtner RD, Godfrey DG, Budenz D, et al. Prevalence of ocular surface complaints in patients with glaucoma using topical intraocular pressure lowering medications. *Cornea.* 2010;29:618-621.
  13. Tsaj JC, McClure CA, Ramos SE, et al. Compliance barriers in glaucoma: a systematic classification. *J Glaucoma.* 2003;12:393-398.
  14. Anwar Z, Wellik SR, Galor A. Glaucoma therapy and ocular surface disease: current literature and recommendations. *Curr Opin Ophthalmol.* 2013;24:136-143.
  15. Baudouin C. Detrimental effect of preservatives in eyedrops: implications for the treatment of glaucoma. *Acta Ophthalmol.* 2008;86:716-726.
  16. Baudouin C. Allergic reaction to topical eyedrops. *Curr Opin Allergy Clin Immunol.* 2005;5:459-463.
  17. Wilson LA. To preserve or not to preserve, is that the question? *Br J Ophthalmol.* 1996;80:583-584.
  18. Baudouin C, Labbé A, Liang H, et al. Preservatives in eyedrops: the good, the bad and the ugly. *Prog Retin Eye Res.* 2010;29:312-334.
  19. Tressler CS, Beatty R, Lemp MA. Preservative use in topical glaucoma medications. *Ocul Surf.* 2011;9:140-158.
  20. Li C, Song Y, Luan S, et al. Research on the stability of a rabbit dry eye model induced by topical application of the preservative benzalkonium chloride. *PLoS One.* 2012;7:e33688.
  21. Kim JR, Oh TH, Kim HS. Effects of benzalkonium chloride on the ocular surface of the rabbit. *Jpn J Ophthalmol.* 2011;55:283-293.
  22. Liang H, Brignole-Baudouin F, Pauly A, et al. Polyquad-preserved travoprost/timolol, benzalkonium chloride (BAK)-preserved travoprost/timolol, and latanoprost/timolol in combinations: a rabbit ocular surface study. *Adv Ther.* 2011;28:311-325.
  23. Berdy GJ, Abelson MB, Smith LM, et al. Preservative-free artificial tear preparations. Assessment of corneal epithelial toxic effects. *Arch Ophthalmol.* 1992;110:528-532.
  24. Baudouin C, Hamard P, Liang H, et al. Conjunctival epithelial cell expression of interleukins and inflammatory markers in glaucoma patients treated over the long term. *Ophthalmology.* 2004;111:2186-2192.
  25. Baudouin C, Pisella PJ, Fillacier K, et al. Ocular surface inflammatory changes induced by topical antiglaucoma drugs: human and animal studies. *Ophthalmology.* 1999;106:556-563.
  26. Baudouin C, Liang H, Hamard P, et al. The ocular surface of glaucoma patients treated over the long term expresses inflammatory markers related to both T-helper 1 and T-helper 2 pathways. *Ophthalmology.* 2008;115:109-115.
  27. Villani E, Baudouin C, Efron N, et al. In vivo confocal microscopy of the ocular surface: from bench to bedside. *Curr Eye Res.* 2014;39:213-231.
  28. Niederer RL, McGhee CN. Clinical in vivo confocal microscopy of the human cornea in health and disease. *Prog Retin Eye Res.* 2010;29:30-58.
  29. Patel DV, McGhee CN. Quantitative analysis of in vivo confocal microscopy images: a review. *Surv Ophthalmol.* 2013;58:466-475.
  30. Petroll WM, Robertson DM. In vivo confocal microscopy of the cornea: new developments in image acquisition, reconstruction, and analysis using the HRT-Rostock Corneal Module. *Ocul Surf.* 2015;13:187-203.
  31. Kymionis GD, Diakonis VF, Shehadeh MM, Pallikaris AI, Pallikaris IG. Anterior segment applications of in vivo confocal microscopy. *Semin Ophthalmol.* 2015;30:243-251.
  32. Villani E, Magnani F, Viola F, et al. In vivo confocal evaluation of the ocular surface morpho-functional unit in dry eye. *Optom Vis Sci.* 2013;90:576-586.
  33. Villani E, Canton V, Magnani F, et al. The aging Meibomian gland: an in vivo confocal study. *Invest Ophthalmol Vis Sci.* 2013;54:4735-4740.
  34. Villani E, Garoli E, Termine V, Pichi F, Ratiglia R, Nucci P. Corneal confocal microscopy in dry eye treated with corticosteroids. *Optom Vis Sci.* 2015;92:e290-e295.
  35. Villani E, Garoli E, Canton V, et al. Evaluation of a novel eyelid-warming device in meibomian gland dysfunction unresponsive to traditional warm compress treatment: an in vivo confocal study. *Int Ophthalmol.* 2015;35:319-323.
  36. Qazi Y, Aggarwal S, Hamrah P. Image-guided evaluation and monitoring of treatment response in patients with dry eye disease. *Graefes Arch Clin Exp Ophthalmol.* 2014;52:857-872.
  37. Villani E, Galimberti D, Del Papa N, et al. Inflammation in dry eye associated with rheumatoid arthritis: cytokine and in vivo confocal microscopy study. *Innate Immun.* 2013;19:420-427.
  38. Mastropasqua L, Agnifili L, Mastropasqua R, et al. In vivo laser scanning confocal microscopy of the ocular surface in glaucoma. *Microsc Microanal.* 2014;20:879-894.
  39. Ciancaglini M, Carpineto P, Agnifili L, Nubile M, Fasanella V, Mastropasqua L. Conjunctival modifications in ocular hypertension and primary open angle glaucoma: an in vivo confocal microscopy study. *Invest Ophthalmol Vis Sci.* 2008;49:3042-3048.
  40. Mastropasqua L, Agnifili L, Mastropasqua R, Fasanella V. Conjunctival modifications induced by medical and surgical therapies in patients with glaucoma. *Curr Opin Pharmacol.* 2013;13:56-64.
  41. Pisella PJ, Debbasch C, Hamard P, et al. Conjunctival proinflammatory and proapoptotic effects of latanoprost and preserved and unpreserved timolol: an ex vivo and in vitro study. *Invest Ophthalmol Vis Sci.* 2004;45:1360-1368.

42. Martone G, Frezzotti P, Tosi GM, et al. An in vivo confocal microscopy analysis of effects of topical antiglaucoma therapy with preservative on corneal innervation and morphology. *Am J Ophthalmol*. 2009;147:725-735.
43. Labbé A, Alalwani H, Van Went C, et al. The relationship between subbasal nerve morphology and corneal sensation in ocular surface disease. *Invest Ophthalmol Vis Sci*. 2012;53:4926-4931.
44. Agnifili L, Fasanella V, Costagliola C, et al. In vivo confocal microscopy of meibomian glands in glaucoma. *Br J Ophthalmol*. 2013;97:343-349.
45. Schiffman RM, Christianson MD, Jacobsen G, Hirsch JD, Reis BL. Reliability and validity of the Ocular Surface Disease Index. *Arch Ophthalmol*. 2000;118:615-621.
46. Morisky DE, Green LW, Levine DM. Concurrent and predictive validity of a self-reported measure of medication adherence. *Med Care*. 1986;24:67-74.
47. Barr JT, Schechtman KB, Flink BA, et al. Corneal scarring in the Collaborative Longitudinal Evaluation of Keratoconus (CLEK) Study: baseline prevalence and repeatability of detection. *Cornea*. 1999;18:34-46.
48. Shimazaki J, Sakata M, Tsubota K. Ocular surface changes and discomfort in patients with meibomian gland dysfunction. *Arch Ophthalmol*. 1995;113:1266-1270.
49. Methodologies to diagnose and monitor dry eye disease: report of the Diagnostic Methodology Subcommittee of the International Dry Eye WorkShop (2007). *Ocul Surf*. 2007;5:108-152.
50. Villani E, Garoli E, Bassotti A, et al. The cornea in classic type Ehlers-Danlos syndrome: macro- and microstructural changes. *Invest Ophthalmol Vis Sci*. 2013;54:8062-8068.
51. Oliveira-Soto L, Efron N. Morphology of corneal nerves using confocal microscopy. *Cornea*. 2001;20:374-384.
52. Wakamatsu TH, Sato EA, Matsumoto Y, et al. Conjunctival in vivo confocal scanning laser microscopy in patients with Sjögren syndrome. *Invest Ophthalmol Vis Sci*. 2010;51:144-150.
53. Villani E, Beretta S, Galimberti D, Viola F, Ratiglia R. In vivo confocal microscopy of conjunctival roundish bright objects: young, older, and Sjögren subjects. *Invest Ophthalmol Vis Sci*. 2011;52:4829-4832.
54. Qazi Y, Kheirkhah A, Blackie C, et al. In vivo detection of clinically non-apparent ocular surface inflammation in patients with meibomian gland dysfunction-associated refractory dry eye symptoms: a pilot study. *Eye (Lond)*. 2015;29:1099-1110.
55. Mastropasqua L, Agnifili L, Fasanella V, et al. Conjunctival goblet cells density and preservative-free tafluprost therapy for glaucoma: an in vivo confocal microscopy and impression cytology study. *Acta Ophthalmol*. 2013;91:e397-e405.
56. Mastropasqua R, Fasanella V, Pedrotti E, et al. Trans-conjunctival aqueous humor outflow in glaucomatous patients treated with prostaglandin analogues: an in vivo confocal microscopy study. *Graefes Arch Clin Exp Ophthalmol*. 2014;252:1469-1476.
57. Petropoulos IN, Manzoor T, Morgan P, et al. Repeatability of in vivo corneal confocal microscopy to quantify corneal nerve morphology. *Cornea*. 2013;32:e83-e89.
58. Ranno S, Fogagnolo P, Rossetti L et al. Changes in corneal parameters at confocal microscopy in treated glaucoma patients. *Clin Ophthalmol*. 2011;5:1037-1042.
59. Leppin K, Behrendt AK, Reichard M, et al. Diabetes mellitus leads to accumulation of dendritic cells and nerve fiber damage of the subbasal nerve plexus in the cornea. *Invest Ophthalmol Vis Sci*. 2014;55:3603-3615.
60. Bucher F, Schneider C, Blau T, et al. Small-fiber neuropathy is associated with corneal nerve and dendritic cell alterations: an in vivo confocal microscopy study. *Cornea*. 2015;34:1114-1119.
61. Figus M, Nardi M, Piaggi P, et al. Bimatoprost 0.01% vs bimatoprost 0.03%: a 12-month prospective trial of clinical and in vivo confocal microscopy in glaucoma patients. *Eye (Lond)*. 2014;28:422-429.
62. Rossi GC, Pasinetti GM, Scudeller L, et al. Risk factors to develop ocular surface disease in treated glaucoma or ocular hypertension patients. *Eur J Ophthalmol*. 2013;23:296-302.
63. Hong S, Lee CS, Seo KY, et al. Effects of topical antiglaucoma application on conjunctival impression cytology specimens. *Am J Ophthalmol*. 2006;142:185-186.