
SHORT COMMUNICATION

Case report

Ectopia lentis et pupillae with patchy depigmentation of the skin, hair and lashes: a new association

M.P. MANITTO¹, R. BRANCATO¹, N. LOMBARDO², M. ZARRELLA², P. NUCCI¹

¹ Department of Ophthalmology and Visual Sciences, Scientific Institute San Raffaele Hospital, University of Milano, Milano

² Department of Dermatology, Asti General Hospital, Asti - Italy

ABSTRACT: *We describe a case of a four year-old boy, with congenital ectopia lentis et pupillae, who developed patchy unilateral depigmentation of the skin, hair and lashes. The association between ectopia lentis et pupillae and transillumination of the iris is well documented in the literature, but it has never been reported with skin hypopigmentation. (Eur J Ophthalmol 1998; 8: 188-90)*

KEY WORDS: *Ectopia lentis, Iris transillumination, Vitiligo*

Accepted: March 30, 1998

INTRODUCTION

Ectopia lentis et pupillae, finely described by Cross in 1979 (1), is a rare congenital disorder characterized by displacement of the lens and pupil in opposite directions. This anomaly is usually bilateral and has been described as a hereditary condition with an autosomal recessive pattern (2,3) without systemic abnormalities. The etiology is unknown. These patients frequently have pupils deformed in a slit like or oval shape, axial myopia and transilluminant irides (3). Cataract formation, glaucoma and retinal detachment may occur (4,5).

We describe a case of a four year-old boy, with congenital ectopia lentis et pupillae, who developed patchy unilateral depigmentation of the skin, hair and lashes.

CASE REPORT

A five-month-old boy with mild facial dysmorphisms was referred to our institution for evaluation of corectopia and subluxation of the lens in both eyes. His history was remarkable for congenital zonular opacity of the lens in the father's family. He was the first-

born male of unrelated parents. The patient's mother had had no rashes or illness during pregnancy, but she had taken medication for threatened premature delivery. He was born at 35 weeks of gestation, by spontaneous vaginal delivery, and his birth weight was 2240 g. Just after birth he developed respiratory distress and CID, and received a not specified oxygen therapy. During the neonatal period, the abnormal appearance of the child's skull prompted a radiological examination, which showed premature fusion of the metopic suture. Neurological findings were within normal limits. Ocular evaluation was remarkable for bilateral ectopia of the lens and corectopia. Anterior segment examination of both eyes revealed, posterior synechiae and pigment clumping on the anterior lens capsule and cataract, more apparent in the left eye. These findings were thought to be consistent with remnants of the pupillary membrane. Irides transillumination was also found. The vitreous, optic nerve head and retina were normal.

General physical examination showed no evidence of other anomalies. Results of high-resolution chromosome examinations were normal. Laboratory evaluation, including VDRL and TORCH, was normal. Over the following years the child's developmental mile-

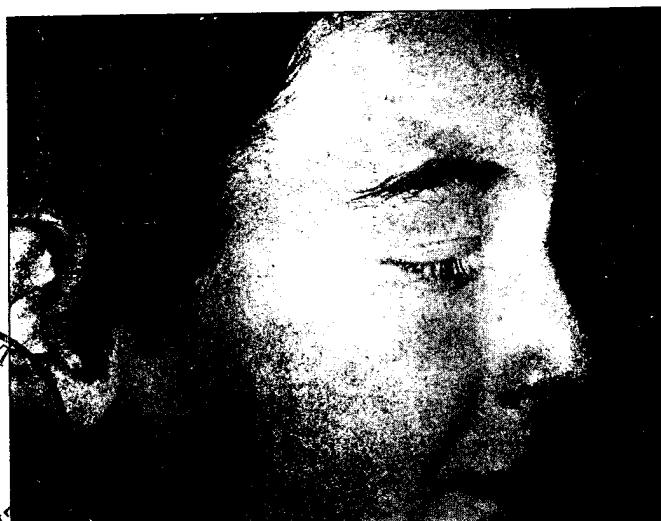

Fig. 1 - Loss of pigment in the right eye.

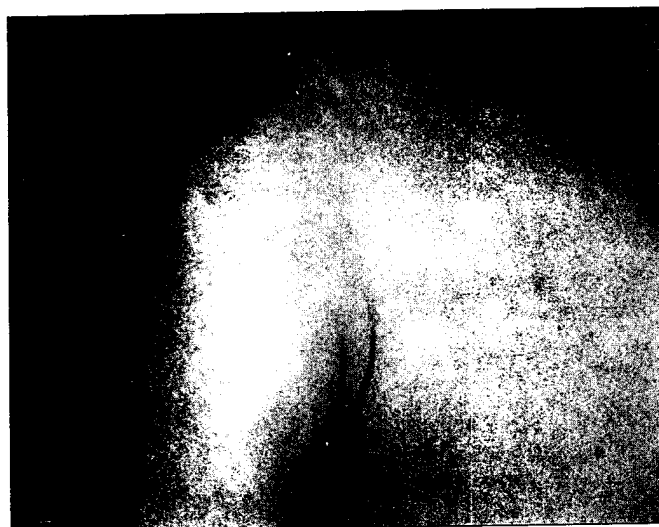


Fig. 2 - Pigment loss confined to the right part of the body.

stones were regular.

The patient was followed at six-month intervals until the age of three, when his best visual acuity was OD 6/20 (-5.50 sph) and OS 2/20 (-4.50 sph = -0.75 cyl 90). Magnetic resonance imaging showed occipital cortical alterations consistent with neonatal hypoxia.

Approximately four years after his initial presentation the patient developed slowly progressive depigmentation of the skin, and poliosis (Fig. 1). The localized hypopigmented patches initially involved the head, hair and lashes, then extended to the right arm and trunk. Pigment loss was confined to the right part of the body (Fig. 2).

DISCUSSION

A subluxated lens may occur as an ocular sign of many systemic disorders.

It has been described in Marfan syndrome, in homocystinuria, in Weill-Marchesani syndrome and less frequently in aniridia, sulphite oxidase deficiency, hyperlysinemia, xanthine oxidase deficiency, syphilis, Rieger's syndrome, Stickler syndrome, facial dysostosis, megalocornea, trauma and congenital glaucoma (5). Ectopia lentis et pupillae is an autosomal recessive disorder, with the lens and pupil dislocated in opposite directions, and has been reported to oc-

cur without any systemic defects.

Several syndromes have been described in which generalized or patchy skin and hair hypopigmentation is associated with ocular anomalies. The disturbance in melanin metabolism resulting in hypomelanosis may have a genetic etiology. Hereditary syndromes involving an enzymatic defect of melanogenesis or a failure of melanocyte migration, are distinguished by the complete or partial absence of pigment in skin, hair, lashes and eyes, evident at birth.

We describe a four-year-old boy with ocular malformation who showed progressive patchy loss of pigment in the skin, lashes and hair. He did not present the typical findings to allow a diagnosis of any previously described syndrome. To our knowledge this is the first case of ectopia lentis et pupillae, complicated by cutaneous depigmentation and poliosis. The association of ectopia lentis et pupillae and transillumination of the iris is well documented. The majority of anomalous cutaneous pigmentation conditions associated with ocular malformation are congenital and not progressive, such as albinism or piebaldism. Only the loss of pigment described in vitiligo, as in Vogt-Koyanagi-Harada syndrome, seems to be progressive. Our propositum showed a peculiar pattern of depigmentation. Like vitiligo it was progressive, but it differs in that it is confined to one half of the body and the hyperpigmented ring is absent.

Ectopia lentis et pupillae

The ectopia lentis and cutaneous defect may have occurred together by pure chance, but we assume that the mechanism responsible for the iris transillumination and the skin hypopigmentation may be common reflecting a neural crest cell degeneration.

Reprint requests to:
Prof. Rosario Brancato
Dipartimento di Oftalmologia e Scienze della Visione
Istituto Scientifico Ospedale S. Raffaele
Università di Milano
Via Olgettina, 60
20132 Milano, Italy

REFERENCES

1. Cross HE. Ectoplasia lentis et pupillae. *Am J Ophthalmol* 1979; 88: 381.
2. McKusick V. A Mendelian inheritance in man. 10th Edition, Baltimore and London: The Johns Hopkins University Press, 1992.
3. Lambert S, Hoyt C. Lens in Taylor D.S.I. *Pediatric ophthalmology*. London: Ed Blackwell Scientific Publication Inc, 1980; chapter 24, 306.
4. Nelson LB, Maumenee IH. Ectopia lentis. In: Renie WA ed. *Goldberg's genetic and metabolic eye disease* (2nd Ed) Boston, Toronto: Little Brown & Co 1986; 392.
5. Gressel MG. Lens induced glaucoma. In: Tasman W, Jaeger EA eds. *Duane's Clinical Ophthalmology*, Vol. 3. Philadelphia: JB Lippincott Ed, 1996; 6.

